

The Ten-Step Vaginal Hysterectomy – A Newer and Better Approach

I BINA^a, D AKHTER^b

Summary:

Aims and Objectives: This study was undertaken to compare with the traditional Heaney's method of vaginal hysterectomy and the newer Ten-Step Vaginal Hysterectomy and to emphasize that this is a safe procedure with lesser blood loss, shorter operation time and shorter requirements of analgesia.

Study Design: 110 Patients with non descent, first, second and third degree prolapsed uterus from 45 to 72 years of age were subjected to this study in Khalishpur Clinic. Those women were randomly selected. Among them 54 women had the traditional Heaney's Methods of Vaginal Hysterectomy and 56 women had the Ten-Step Vaginal Hysterectomy (TSVH). The blood loss was measured by hemoglobin assessment before and 3 days after operation.

Material and Methods: In Ten-Step Vaginal Hysterectomy the vaginal wall was incised by drop-like incision starting under the urethra, continuing laterally and down, encircling the cervix from behind and returning back to the starting point from the other side, then separation was done laterally to the side to the uterus. Bladder is detached from the uterus, and the posterior peritoneum is opened. The sacro-uterine

ligaments and the paracervical ligaments are clamped together, cut and ligated in both sides. Next the uterine arteries are clamped, cut and ligated. Uterus is pulled down and two fingers are introduced behind the fundus to lift anterior peritoneum and opened under supervision. The round and ovarian ligaments and blood vessels are clamped together and ligated in both side. The peritoneum is left open, then reconstruction of the pelvic floor is done and the vaginal wall is closed continuously.

Results: It was found that in comparison of traditional methods with the ten steps vaginal hysterectomy, there are lesser blood loss (400ml vs 80ml; $P<0.05$) with lower complications, shorter operation time (52.5min vs 30.3min; $P<0.05$), lesser pain and lesser requirements of analgesia (5.8 vs 3.9 days; $P<0.05$) and shorter period of convalescence. Hospital stay remains same for both groups.

Conclusion: The Ten-Step Vaginal Hysterectomy is a better operation than traditional method of vaginal hysterectomy, Abdominal Hysterectomy and LAVH. At the same time this method is logical and easy to learn, to perform and to teach.

(J Bangladesh Coll Phys Surg 2012; 30: 71-77)

Introduction:

Vaginal hysterectomy was done for many centuries before abdominal hysterectomy. First vaginal hysterectomy was done in the 5th century BC, in the time of Hippocrates¹. Next it was done in the 2nd century AD by Soronus. Then earliest hysterectomies were done for prolapsed uterus. Though vaginal hysterectomy was

done sporadically through the 17th and 18th centuries, the first successful vaginal hysterectomy was done in 1813 by Langenbeck,^{1,2} a German surgeon. After that successful abdominal hysterectomy was done by John Bellinger¹ of South Carolina in 1846. Since then abdominal hysterectomy had gain its popularity for the last century. Surprisingly, in the last three decades with the introduction of Laparoscopically Assisted Vaginal Hysterectomy (LAVH), vaginal hysterectomy has regained its popularity.

Now a days, when hysterectomy is indicated, vaginal route should always be considered because of quick recovery, lack of abdominal scar and shorter hospital stay. It seems that LAVH should not replace the vaginal but the abdominal hysterectomy except some relative contraindications for vaginal hysterectomy. There are less and less contraindications for vaginal hysterectomy

- Dr. Ismatara Bina, MD, DGO, MCPS, FCPS (Obstetric & Gynae), MRCOG (London), Consultant Obstetrician and Gynecologist, Khalishpur Clinic.
- Dr. Dalia Akhter, MBBS, FCPS (Obstetric & Gynae), Asst. Professor, Khulna Medical, College Hospital. Khulna, Bangladesh

Address of Correspondence: Khalishpur Clinic, Plot # 41, Road. # 101, Khalishpur H/E, Khulna – 9000, Bangladesh, Mob: 008801711547954

Received: 16 March, 2011

Accepted: 04 March, 2012

and the operation can be performed in nulliparity and women with enlarged uterus. Michael Stark from Germany has introduced “Ten-Step Vaginal Hysterectomy”³ which is logical, easy to learn, perform and teach. He has optimized this method by reevaluating the six methods used today: the Porges⁴, Falk⁵, von Theobald⁶, Heaney⁷, Joel-cohen and the Chicago⁸ methods. All common steps in these methods were defined and analyzed, the unnecessary steps were excluded, and the way of their performance was revised.

Materials and Methods:

110 Patients with non descent, first, second and third degree prolapsed uterus from 45 to 72 years of age were subjected to this study in Khalishpur Clinic during the period of December-2006 to December-2010. It was a prospective study and those women were randomly selected. Among them 54 women had the traditional Heaney’s Method of vaginal hysterectomy and 56 women had the Ten-Step Vaginal Hysterectomy.

Inclusion criteria: Women with uterine pathology like prolapsed uterus, Leiomyoma less than 12 weeks size, Adenomyosis, DUB were included in the study.

Exclusion criteria: Women with Uterine Leiomyoma more than 12 weeks size, severe Endometriosis, severe Pelvic Inflammatory Disease, Carcinoma Cervix, Endometrial Carcinoma and any Ovarian tumor (benign or malignant) were excluded from the study.

The Blood loss was measured by two parameters:

a) Hemoglobin assessment before and 3 days after operation.

b) Measurement by weighting the Mops, Sheets and lost blood in the tray: The Mops and operating sheets and tray were measured before and after operation and deducted. Thus the amount of blood loss was measured.

Analgesic requirements: Diclofenac sodium injectable, suppository or oral tablet form were used routinely and accordingly in both groups. Sometimes Inj Pethidine was needed. At the same time, the types, doses, amounts of analgesics were noted.

Method description: The revised operation steps are as follows:

1. Incision of the vaginal wall: In traditional method, where prolapse exists, an inverted T incision is given with circumcision around the cervix, extension towards the orificium urethrae externum and separation of the vaginal wall laterally, away from the bladder are done. The cervix is grasped with two single-toothed tenaculi. In our case, in prolapsed uterus, the incision will be drop-like starting under the urethra, continuing laterally and down, encircling the uterine cervix behind and returning back to the starting point from the other side (Fig: 1 & 2). If the depth of the initial incision is correct and the right cleavage is reached, the vaginal wall will be easily separated laterally to the side of the uterus

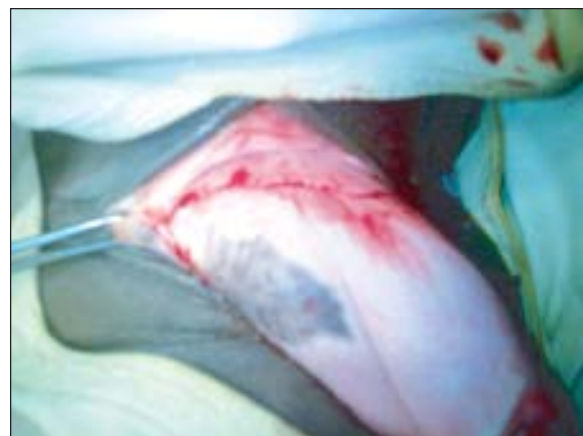
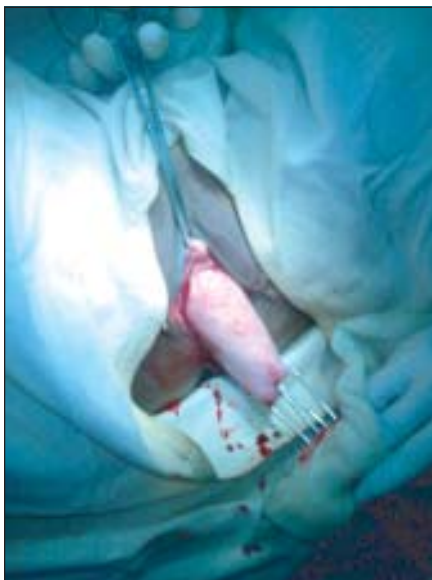


Fig.-1 & Fig.-2: A Drop like incision around the cervix (Step1)

and downwards below the cervix by a gentle use of surgical forceps. This should be nearly bloodless and easier than separating the vaginal wall in the described traditional way. Doing so, the vaginal wall is already ready for the anterior wall colporrhaphy. After this, the tip of the “drop” still covering the bladder is pulled down, separating the vaginal wall from the bladder. Being in the right cleavage will prevent unnecessary bleeding. This procedure, besides being logical, is performed in three main movements compared to six in all other methods.

In a patient without prolapsed:

The cervix is grasped with two single-toothed tenaculi. A circular incision is given around the cervix about 5mm above the external os, and then, being in the right cleavage, the vaginal wall should be separated from the cervix using surgical forceps or simply by gauze. More vaginal retractors are sometimes needed in order to allow the surgeon to perform this manipulation under good vision.

This approach is easy and logical both in prolapsed and non-prolapsed uteri.

2. Detaching bladder from the uterus: After identification of the border between the anterior wall of the uterus and the bladder, it is cut. Sometimes curved scissors are needed. The bladder is pushed up close to the uterus

and separate from the uterus until the anterior peritoneum is exposed. The anterior peritoneum is not recommended to open because it will disturb the dynamics of the operation and interrupts its continuity, and also might cause for damage to the bladder whenever the intra-anatomical relations between it and peritoneum is not clear and now Previous Caesarean Sections are not considered a contraindication for vaginal hysterectomy.

3) Opening posterior peritoneum: The tenaculi holding the uterus should be pulled up and the peritoneum should be grasped with surgical forceps and opened with scissors. The scissors are then introduced into the Douglas cavity, and holding each blade with one hand, pulled out open, so that the back sides of the blades expose the insertions of the sacrouterine ligaments Fig: 3.

4) Dissection of the lower part of the uterus: The sacrouterine ligaments and the paracervical tissue are clamped together (Fig-4). This is done by a designed manoeuvre: one blade of an open clamp is placed under the insertion of the sacro-uterine ligament, the instrument rotates towards the uterus while the uterus is being contra-rotated. Both anatomical structures are included between the blades of the instrument while it is being closed. Both structures, the relatively bloodless sacro-uterine ligaments and the paracervical tissues, are cut and ligated leaving the suture material in its full length. This is

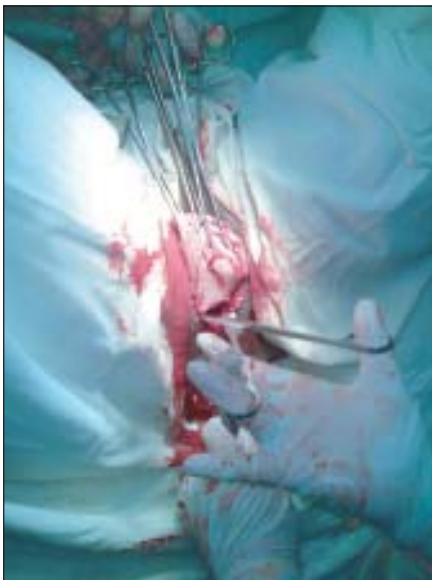

Fig.-3: *Opening the post peritoneum (Step-3)*

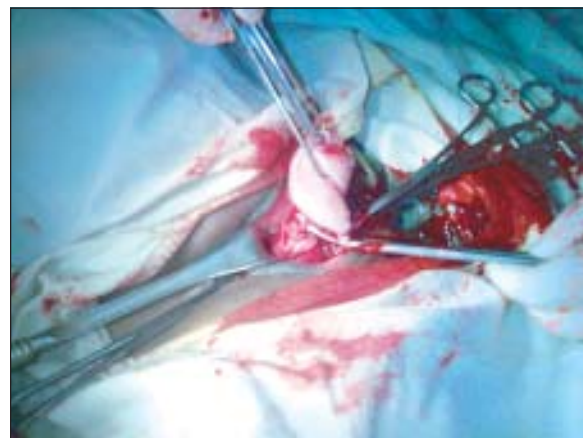


Fig.-4: *Grasping the sacro-uterine lig. and Paracervical tissue (Step-4)*

repeated on the contralateral side. In patients without prolapsed uterus, this manoeuvre will instantly produce a significant descensus.

5) Cutting and ligating the uterine arteries: Both uterine arteries are clamped, cut and ligated.

6) Opening the anterior peritoneum: After cutting and ligating both uterine arteries, the uterus is pulled down and two fingers are introduced behind the fundus to lift the anterior peritoneum and opened under good vision with scissors. The access to the fundus in a myomatous uterus is sometimes difficult. In such a case, the surgeon should hold both tenaculi with his left hands while continuously and slowly pull them down with rotating movements. Morcellation of the uterus may be performed when needed⁹.

7) Dissection of the upper part of the uterus (and appendages): The round and ovarian ligaments and the blood vessels are clamped together and ligated. The ligature should be placed as lateral as possible away from the clamp, leaving the ovarian ligaments as long as possible. The uterus is cut away with scissors medial to the instrument. A transfexion suture is placed between the clamp and the ligature keeping the full length of the suture material. The ligature, which is placed before and lateral to the transfexion, will prevent bleeding, should this transfexion suture slip away or tear by traction. The same procedure is to be done on the contra lateral side.

8) The “non stage” leaving the peritoneum open: In 1980, Harold Ellis showed that closing the peritoneum at the end of abdominal surgery is not necessary^{10,11,12}. The British Royal College of Obstetrics and Gynecology recommended in its guideline No.15 from July 2002 to leave peritoneum open¹³.

If an enterocele has to be prevented or repaired, it should be done at this stage¹⁴.

9) Reconstruction of the pelvic floor: The left and right sacrouterine ligaments with the paracervical tissues as well as the ovaries ligaments are ligated to each other respectively.

10) Closing the vaginal wall: The vaginal wall is sutured continuously. In sexual active women I’ve done an inverted T suture (Fig-5).

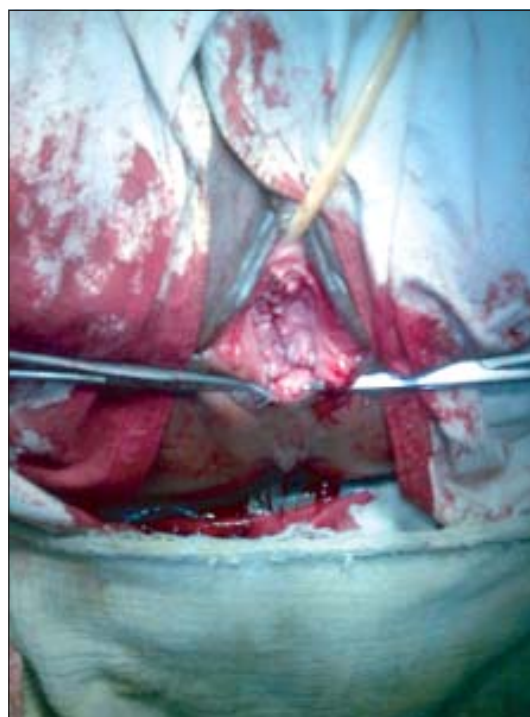


Fig.-5: *Closing the vaginal wall*

The data were stored in a database. The Evaluation was done using SPSS for Windows-7. Frequencies and standard differences were calculated as mean variations. Chi square analysis was done where needed.

Instruments: Speculum two single-toothed tenaculi, scalpel, surgical forceps.

Swabs, Allis clamp, scissors, Wertheim or Heaney clamp, Needle holder.

Result:

This study was done in Khalishpur Clinic from December 2006 to December 2010, where 110 women with non-prolapse I, II, or III underwent vaginal hysterectomy were recruited, among them 54 patient had vaginal hysterectomy with the Heaney methods and 56 patient had Ten-Step Vaginal Hysterectomy.

The characteristics of both groups were shown in Table – 1. The table shows the differences between the groups with regard to patient’s demographics characteristics like age, parity, Non-prolapsed and prolapsed cases.

Table-I

<i>Demographics of the patients</i>		
Characteristics	Heaney's Method(n =54)	Ten Step Vag. Hyst.(n =56)
Age	55.6 (45 -70.4)	56.1 (46 – 71.6)
Parity	5.25 (4.0 – 8.0)	5.5 (5.0 – 9.0)
Non Prolapse	2 (3.7%)	2 (3.5%)
Prolapse – I	5 (9.2%)	4 (7%)
Prolapse – II	46 (85%)	47 (84%)
Prolapse – III	1 (1.9%)	1 (1.8%)

Data in parameters of percentage (%)

P – Value not significant

Table-II

<i>Comparison of the heaney methods and ten-step vaginal hysterectomy</i>			
Characteristics	Heaney methodsN = 54	Ten-Step Vag. Hyst. N = 56	P – Value(P<0.05)
Age (years)	55.6 (45-70.4)	56.1 (46 -71.6)	P>0.05(NS)
Operation time (min)	52.5(30.2-90)	30.2(23.5-45.0)*	P>0.05(NS)P<0.05
Average Blood loss (ml)	400 (200-600)	80- (30-200)*	P<0.05
Uterine weight (gm)	210 (180-300)	215 (175-320)	P>0.05(NS)
Pain Killers needed (days)	5.8 (4.0-8.3)	3.9 (3.0-6.5)*	P<0.05
Average hospital stay (range)	5.9 (4-8)	5.9 (4.-8))	P>0.05(NS)

* Statistically significant (P<0.05)

In our study of 110 women with non-prolapsed, prolapse I, II or III underwent vaginal hysterectomy. There was no significant difference in both groups regarding age, parity, uterine weight, and average hospital stay. The women undergoing the Ten-Step Vaginal Hysterectomy had a significantly minimum blood loss five times less (400ml vs 80ml; P<0.05) with lower complications, shorter operation time; almost half (52.5min vs 30.3min; P<0.05) and lesser requirements of analgesia also half (5.8 vs 3.9 days; P<0.05), lesser pain, and shorter period of convalescence. Hospital stay remains same for both groups (Table-II). Uterine weights are also same for both groups. Interestingly, the women with Ten-Step Vaginal Hysterectomy had also speedier return to normal activities and Blood transfusion was not needed for those patients.

Discussion:

In true sense, it is told that the fashion of the surgery is changing more rapidly and faster than the fashion of the dresses. Though some surgeons like to stay close

with the traditional methods of operation, but it is wise to develop the new thinking and reevaluation of the surgical developments. So for the best patient outcome in any surgical procedure, each steps with its combinations and sequences should be evaluated, the necessity of these steps and way of performances should be critically assessed and compared to the alternatives. At the same time, the complications and outcomes both early (febrile morbidity, analgesics needed, infections, mobility) and late (chronic pains, organ dysfunctions, post operative adhesions and return to normal activities e.g. life quality, costs) should be taken into account to assess which one is best surgical procedures.

In general, based on the medical evidence vaginal hysterectomy is associated with better outcomes and fewer complications than either laparoscopic or abdominal hysterectomy. There were many studies comparing the outcome of vaginal hysterectomy to laparoscopic or abdominal hysterectomy. According to new Committee Opinion released by The American

College of Obstetrician and gynecologists (ACOG) and published in the November issue of *Obstetrics & Gynecology*, Vaginal Hysterectomy is the safest and most cost-effective method to remove the uterus for noncancerous reasons¹⁵.

Campbell et al.¹⁶ compared the three methods in 33,792 operations, analyzing the duration of the hospital stay and the involved costs and concluded that “vaginal hysterectomy provides the best patient outcomes with the shortest hospital stays and lowest complication rates at the lowest cost”. Drahonovsky et al had studied that vaginal hysterectomy had the shortest operating time and least drop in hemoglobin. So this is suitable method of operation for women who are not fit for the longer duration of surgery and anesthesia as well.¹⁷

Recent findings: Recent research like Candiani M et al had established that “Vaginal hysterectomy seems to be the gold standard in case of benign pathologies and should be performed in preference to abdominal hysterectomy wherever possible. Laparoscopic hysterectomy is to be preferred to abdominal hysterectomy, when vaginal hysterectomy is not technically possible. Vaginal and laparoscopic hysterectomies have been clearly associated with decreased blood loss, shorter hospital stay, speedier return to normal activities, and fewer abdominal wall infections when compared with abdominal hysterectomy. In this review, the authors outline the ten steps to a successful laparoscopic hysterectomy.¹⁸ ACOG also mentioned that LAVH is considered an alternative to abdominal hysterectomy, not vaginal.¹⁹

In another study, Meikle SF et al showed that though shorter hospital stay and lesser need for analgesia was reported in LAVH but there are no other advantages of laparoscopic hysterectomy could be found over vaginal hysterectomy. In addition, laparoscopic hysterectomy is associated with a higher rate of complications, especially, bladder and ureteral injuries.²⁰ Wolfgang Z et al had done a newer method of vaginal hysterectomy by using bicoagulation forceps without sutures for routine vaginal hysterectomy. He mentioned that it is a technically feasible and safe alternative to the traditional approach. Complication rates and patient satisfaction are similar. There is lesser blood loss and need for pain killer and shorter stay of hospital in the coagulation group.²¹ So this method may be another alternative to

Hysterectomy. Unfortunately, the special instruments (bicoagulation forceps) are costly and not available in Bangladesh.

In one study by Balfour RP was stated that the vaginal route should always be considered when hysterectomy is indicated, because of quicker recovery, avoiding abdominal scar, leading to a reduced length of hospitalization. He also mentioned that there is no justification for LAVH in significant uterine prolapsed.²²

Conclusion:

In conclusion, I would like to thank Mr. Michel Stark for his invention of the Ten-Step Vaginal Hysterectomy which results from his analyses of surgical steps used in different methods depending on anatomical considerations and physiological principles. Then the operation becomes simple, easy and rational by avoiding unnecessary movements and following rules of aesthetics and functional minimalism. The study also showed that this operation reduces the operation time, blood losses and the use of pain killers. Here only ten instruments and ten sutures are needed. In fact, to evaluate the late outcome of this method more rational, randomized and prospective studies will be needed.

References:

1. John A R, John D T, Te Linde's Operative Gynaecology: Edition Lippincott-Raven Publishers: Philadelphia-Newyork:1997; 33:771-775.
2. Leodolter S. The transvaginal surgical school in Austria. Retrospect-present-future. *Gynaekol Geburtshilfliche Rundsch* 1995; 35: 142-148.
3. Stark M, Gerli S, Di Renzo GC. An example for an optimized technique: The Ten-Step Vaginal Hysterectomy, in: *Progress in Obstetric and Gynecology* (2006) 17, 358-368.
4. Paldi E, Fimar S, Naiger R, Weisseman A, Feldman EJ. Vaginal hysterectomy using the Porges method. Report on 100 cases. *J Gynecol Obster Biol Reprod* 1988; 17 (2): 233-236.
5. Falk HC, Soichet S. The technique of vaginal hysterectomy, *Clin Obstet Gynecol* 1972; 15 (3): 703-754.
6. Von Theobald P. Simplified vaginal hysterectomy. *J Chir* 2001; 138 (2):93-98.
7. Kalogirou D, Antoniou G, Zioris C, Folopoulos S, Karakitsos P. Vaginal hysterectomy: technique and results in the last twenty years. *J Gynecol Surg* 1995; 11 (4): 201-207.
8. Lash AF, Stepto RC. Chicago technique for vaginal hysterectomy at the Cook County Hospital. *Clin Obstet Gynecol* 1972; 15(3): 755-768.

9. Taylor SM, Romero AA, Kammerer-Doak DN, Qualls C, Rogers RG. Abdominal hysterectomy for the enlarged myomatous uterus compared with vaginal hysterectomy with morcellation. *Am J Obstet Gynecol* 2003; 189 (6): 1579-1582.
10. Ellis H. Internal overhaling: the problem of intraperitoneal adhesions. *World J Surg* 1980; 4: 303-306.
11. Janschek FC, Hohlagschwandtner M, Nather A, Schindl M, Joura EA. A study of non-closure of the peritoneum at vaginal hysterectomy. *Arch Gynecol Obstet* 2003; 267 (4): 213-216.
12. Lipscomb GH, Ling FW, Stovall TG, Simmitt RL jr. Peritoneal closure at vaginal hysterectomy: a reassessment. *Obstet Gynecol* 1996; 87 (1): 40-43.
13. Royal College of Obstetricians and Gynaecologists: Peritoneal Closure Guideline No. 15. 2002.
14. Cruikshank SH, Kovac SR. randomized comparison of three surgical methods used at the time of vaginal hysterectomy to prevent posterior Entrocele. *Am J Obstet Gynecol* 1999; 180 (4): 859-865.
15. The American College of Obstetricians and Gynecologists (ACOG) Abdominal or laparoscopically assisted vaginal hysterectomy. ACOG Recommends Vaginal Hysterectomy November issue of Obstetrics & Gynecology, 22.10.09.
16. Campbell ES, Xiao H, Smith MK. Types of hysterectomy. Comparison of characteristic, hospital costs, utilization and outcomes. *J Repond Med* 2003; 48: 943-949.
17. Drahonovsky J, et al, A prospective randomized comparison of vaginal hysterectomy, laparoscopically assisted vaginal hysterectomy and total laparoscopic hysterectomy in women with benign uterine disease. *Eur J Obstet Gynecol Reprod Biol.* 2010 Feb; 148(2): 172-6. Epub 2009 Nov 18.
18. Candiani M, Izzo S, Bulfoni A, Riparini J, Ronzoni S, Marconi A. Laparoscopic vs vaginal hysterectomy for benign pathology. *Am Obstet Gynecol.* 2009 Apr; 200(4): e1-6.
19. American College of Obstetricians and Gynecologists: Appropriate use of laparoscopically assisted vaginal hysterectomy. *Obstet Gynecol* 2005; 105: 929-930.
20. Meikle SF, Nugent EW, Orleans M. Complications and recovery from laparoscopy assisted vaginal hysterectomy compared with abdominal and vaginal hysterectomy. *Obstet Gynecol* 1997; 89: 304-311.
21. Wolfgang Zubke, Sven Becker, Bernhard Karmner and Diethelm Vallwiener Vaginal hysterectomy: a new approach using bicoagulation forceps *Am K Obstet Gynecol.* 2009 Apr; 200(4): 368. e18. Epub 2009 Jan 10.
22. Balfour RP. Laparoscopic assisted vaginal hysterectomy – 190 cases: Complications and training. *J.Obstet Gynecol* 1999;19: 164-166.