

The Use of Periosteal Flaps in the Repair of Clefts of the Primary Palate

TORD SKOOG, M.D.
Uppsala, Sweden

In recent years, the repair of the maxillary defect in cleft lip and palate deformity has attracted an increasing interest, resulting in the development of elaborate and tedious programs for correction. In this paper, a new principle for primary repair is presented. The principle involves the use of periosteal flaps for the purpose of creating bony continuity, preventing maxillary collapse, and contributing to the restoration of symmetry of the alveolar arch.

The facial bones are, for the most part, of intramembranous origin and their early development is well known from histogenetic studies. After a mass of primary cancellous bone has been laid down, there appears a peripheral concentration of mesenchyme. This periosteal layer has great bone-forming potentiality and deposits parallel lamellae about the cancellous center of the growing bone. One would expect the osteogenetic capacity of the periosteum to be most pronounced during the period of growth. The formation at an early age of new bone arising from the periosteum of the facial skeleton may in fact be deduced from clinical observations. Some cases treated at this department are particularly instructive in this respect: two of them will be reported briefly.

Case 1. A 4-month-old girl referred because of a melanotic progonoma involving the maxillary bone required unilateral, subtotal removal of the maxilla. The resection was performed leaving all the periosteum *in situ*. Complete bone regeneration took place and x-ray films two years after the operation revealed, except for the missing teeth and dental anlagen, a normal looking maxilla with a maxillary sinus. This case has been more extensively reviewed by Körlof (1).

Case 2. In a boy with a congenital cleft of the primary palate, maxillary collapse occurred following soft tissue repair. During orthodontic expansion, at the age of five years, a substantial bone bridge developed spontaneously between the premaxilla and the lateral maxillary segment. The possible explanation, suggested in a previous report of this case (5), was that in the primary repair the periosteal membranes had united across the cleft.

Based on these observations, suggestive in regard to the osteogenetic capacity of the periosteum of facial bones in children, a new principle has been adopted in the repair of the maxillary defect in cleft primary palate. The details of surgical technique and a preliminary report on results are included in this paper.

Dr. Skoog is Professor of Plastic Surgery, University of Uppsala.

Operative Technique

Closure of the cleft primary palate within the alveolar region has become a fairly standardized procedure based on the original description by Veau (6). The technique we use to accomplish lining on the nasal aspect is illustrated in Figure 1, upper left and right. On the lateral side, the incision made along the border of the cleft is extended in front between the upper and lower nasal cartilages: posteriorly it reaches about 2 cm behind the alveolus. The incision is carried through mucous membrane and periosteum down to bone. The lateral border of the piriform aperture and the maxillary cleft are exposed and a mucoperiosteal flap is raised from the inner aspect of the bone. By extensive subperiosteal elevation, this flap can easily be advanced medially. On the medial border of the cleft, an incision is made along the vomer and carried over the anterolateral aspect of the premaxilla towards the anterior edge of the septum. The surface of the premaxilla bordering the cleft is completely denuded of its rather thin

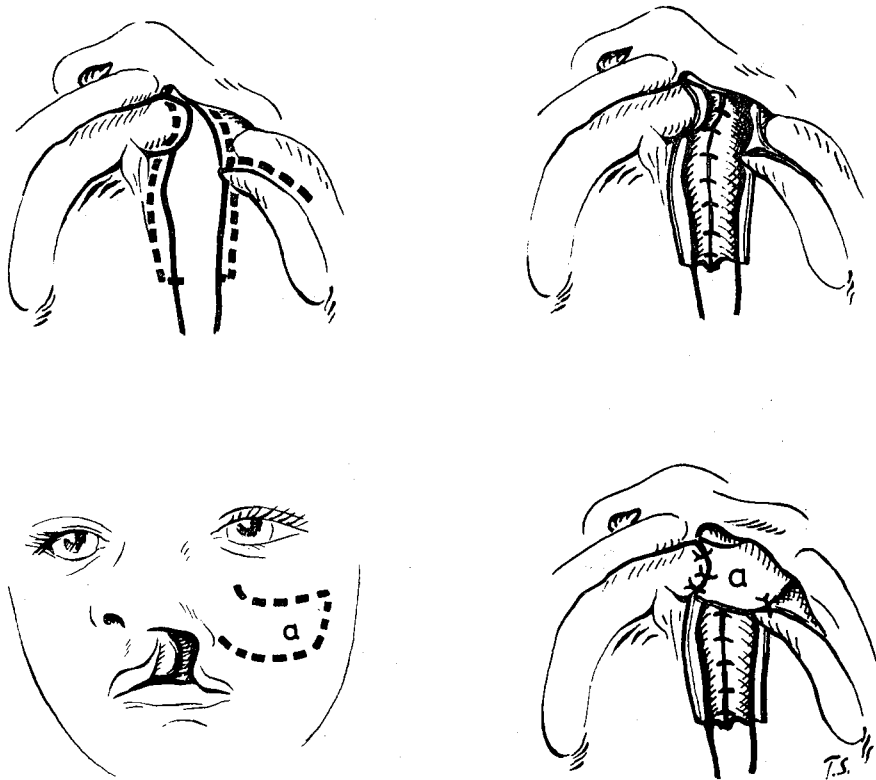


FIGURE 1. Operative procedure designed for the creation of periosteal continuity across the maxillary cleft. Upper left and right shows lining of the nasal aspect. Lower left and right shows that the periosteal flap (a) is raised on the anterior aspect of the maxilla and rotated 180° into position across the bony cleft. For details, see text.

and firmly adherent periosteum, with care being taken not to injure the delicate bone structures. The periosteal elevation is continued on the vomer and the mucoperiosteal-perichondrial flap thus mobilized is then approximated to the corresponding lateral flap with 3-0 chromic catgut sutures, tied on the nasal side. In this closure, broad apposition of the periosteal surfaces is attempted and for that purpose a second row of sutures may, if possible, be placed on the oral side. Should there be any tension on the suture line, relaxing incisions are made on the lateral flap in an area of overlying bone.

It is a well-known fact that a nasal floor reconstructed in this fashion, which is left for epithelialization on the oral side or covered with a mucosal flap taken from the buccal sulcus, is not capable of laying down bone within the alveolar cleft. In order to make use of the phenomenon of subperiosteal bone formation, this repair of the nasal floor has been supplemented to provide within the alveolar region a second layer of periosteal lining brought in on the anterior aspect; that is, periosteal continuity is created on both aspects of the maxillary cleft.

At the age of between three and six months, when the initial repair of the cleft primary palate is generally performed, the periosteum investing the lateral segment of the maxilla forms a substantial membrane which is easily stripped off on the facial as well as on the palatal aspect. After trials with different sizes and shapes of flap, it was found that the periosteum covering most of the anterolateral aspect of the maxilla had to be mobilized to provide a flap that in a complete cleft would give good cover and bridge the gap to reach the premaxilla without tension (Figure 1, lower left and right). In the planning, one must remember that the periosteal membrane has an outer layer composed of coarse fibrous connective tissue which lacks elasticity and therefore is not easily adjusted in flap transfer. The flap is based medially along the infraorbital margin and on the lateral aspect of the nasal pyramid. From this location, a periosteal flap is raised by incising in a lateral direction below the infraorbital foramen, and the original incision for exposure in the vestibulum is extended laterally to meet this upper border. The dissection to expose the flap is carried out in the tissue plane immediately superficial to the periosteum and the infraorbital nerve is not injured. The flap is then rotated through almost 180° to its new position across the cleft and sutured to the periosteal edge on the anterior aspect of the premaxilla. The upper border of the flap may also be sutured to the periosteal flaps of the previously reconstructed floor of the nose. It is possible that the degree of rotation and the proportions of this flap will occasionally impair the blood supply to the extent that the distal part may only survive as a free graft.

In incomplete clefts, regularly characterized by a wide piriform aperture and a depressed nasal floor, correction was attempted according to the same principle. Laterally, the periosteum on both the inner and outer aspect of the bone was advanced; in addition, a periosteal flap was placed

across the anterior, denuded part of the nasal floor at a level considered normal.

In the present series of cases, repair of the cleft lip was performed in conjunction with the creation of periosteal continuity within the maxillary cleft. The single clefts were repaired according to a method described in 1957 and modified in 1963 (3, 4). The bilateral clefts were repaired according to a technique reported in 1965 (5).

Results

Altogether eight cases have been operated upon according to the principle described. In none of them did complications occur following surgery. The series includes four patients with complete clefts of the primary palate, two with bilateral clefts, and two with unilateral clefts. One of the bilateral cases had a periosteal flap repair on one side only. Since the complete clefts are of particular interest in the evaluation of postoperative results, they are reported in more detail in order to illustrate the different stages of repair and the observations made (Figures 2 to 5).

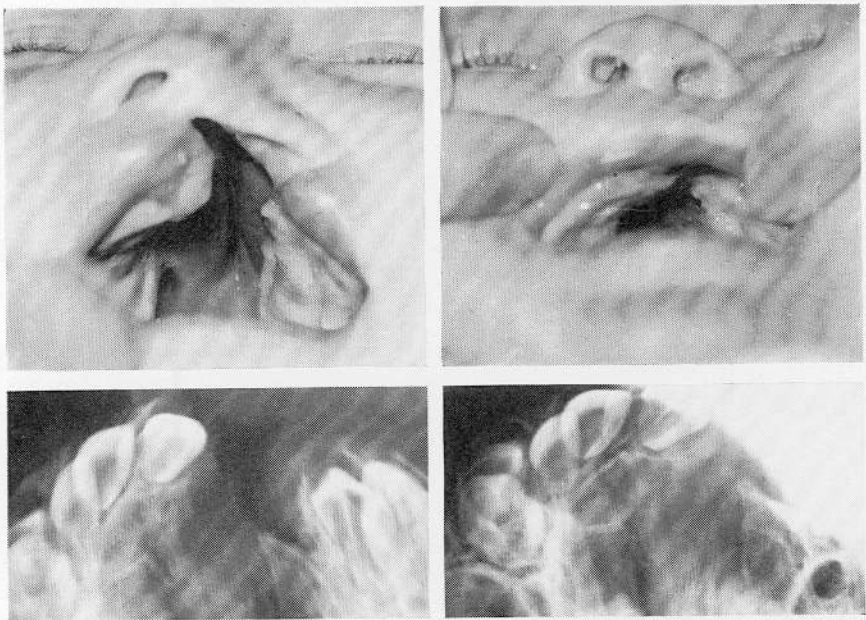


FIGURE 2. Upper left, a three-month-old girl at the time of repair of the cleft primary palate. A large periosteal flap was placed across the maxillary cleft as illustrated in Figure 1. Upper right, 2½ months postoperatively, the alveolar arch has become symmetrical and there is no tendency to collapse. Lower left and right, x-ray films, taken 2½ and 3½ months, respectively, after the operation, show new bone extending from both the lateral and the medial borders of the maxillary cleft. At the later stage (right), the formation of bone is more widespread within the cleft and bone structures are more dense.

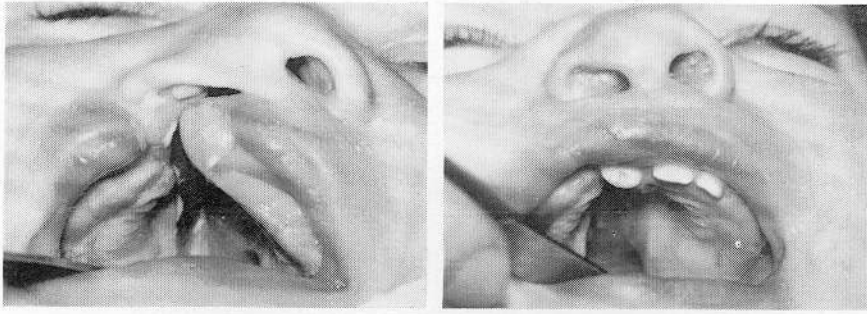


FIGURE 3. Left, a three-month-old boy, when the cleft of the primary palate was repaired (June, 1964) using periosteal flaps as described in text. Right, condition 10 months after the operation. Note accurate alignment of maxillary segments. X-rays show that the abnormal position of 1+ was present already before eruption and prior to surgery.

On examination, there was less depression of the cleft side than is normally found following simple soft tissue repair (Figure 2). The regular finding of a marked step in the maxillary framework corresponding to the alveolar cleft was also less noticeable.

In both cases of complete bilateral clefts, the premaxilla became firmly consolidated into the alveolar arch, and this applied to the case in which a periosteal flap was used on only one side. These clinical findings can most reasonably be interpreted as the result of bone formation within the clefts.

The effect of the surgical procedure described on the maxillary configuration at the level of the alveolar processes was carefully studied. In three out of five complete clefts, there was an approximation of the alveolar segments into end-to-end contact, producing a symmetrical arch form. In two clefts, good contact was achieved within the arch but there was slight, insignificant overlapping of the premaxillary segment. In the latter cases, examination of the preoperative maxillary casts revealed that collapse was present to the same degree prior to soft tissue repair. Though pre- and postoperative variations in this respect are great, as has been demonstrated by Pruzansky and Aduss (2), the dynamic effects of soft tissue repair, themselves related to methods of closure and surgical technique, are of fundamental importance for the final arch form. Scarring and the creation of unphysiological mechanical conditions can only increase the incidence and degree of maxillary collapse and deformity. The observations made are therefore of interest even in a limited number of clefts because of their uniform character, showing that in no case did maxillary collapse occur following surgery. The modelling influence of the surgical procedure used was found to be excellent, both in the unilateral and the bilateral clefts. In fact, the relationship of the maxillary segments obtained in this series of cases by soft tissue repair only compared favorably with the best to be obtained by pre- or postsurgical orthopedies. An evaluation of the

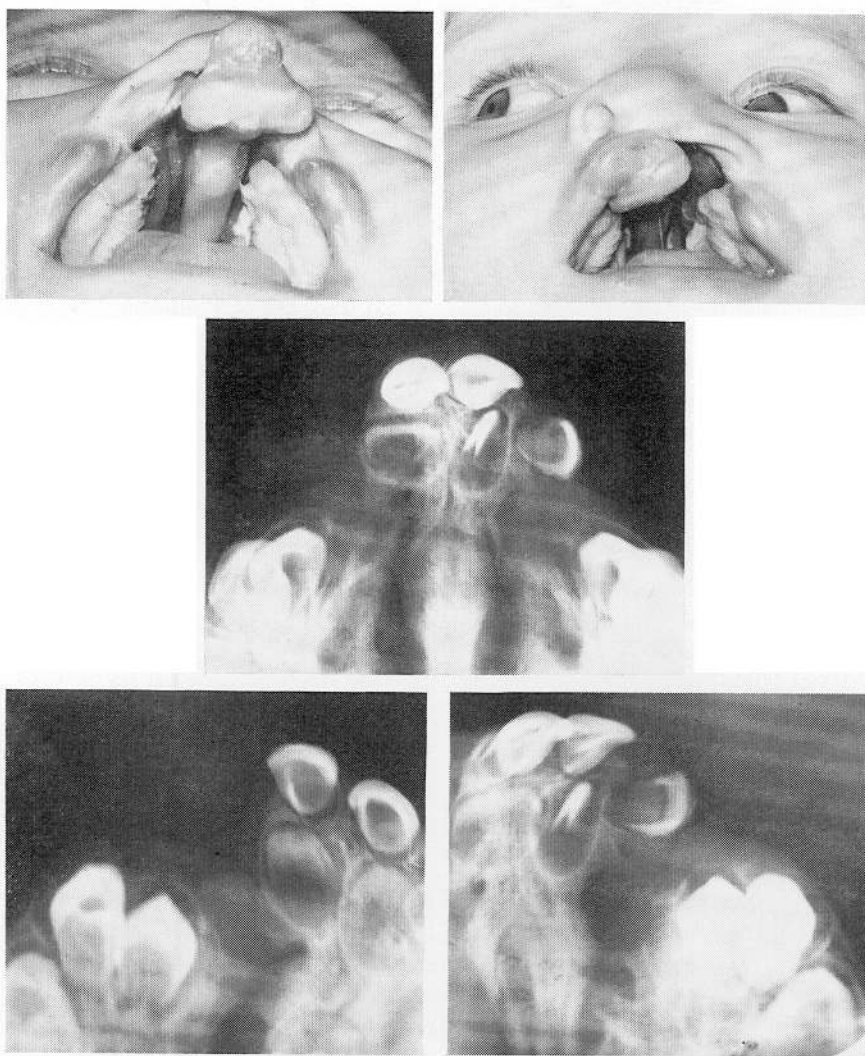


FIGURE 4. Condition in a boy at the age of three months when the primary cleft was repaired on the right side (upper left), and at the age of six months when closure of the left side was performed (upper right). Middle and lower, right and left, x-ray films at the age of 11 months show excellent relationship of maxillary segments. In special projections (lower), well-defined bone structures are clearly demonstrated bridging the maxillary cleft on both sides.

postoperative development after six months and later indicated normal growth of the lateral segment and also that this segment had moved forward to a more normal position following operation.

In the case shown in Figure 4, the right alveolar cleft was exposed three months following surgery in conjunction with closure of the cleft on the left side. Extending from the lateral border of the maxillary cleft was a

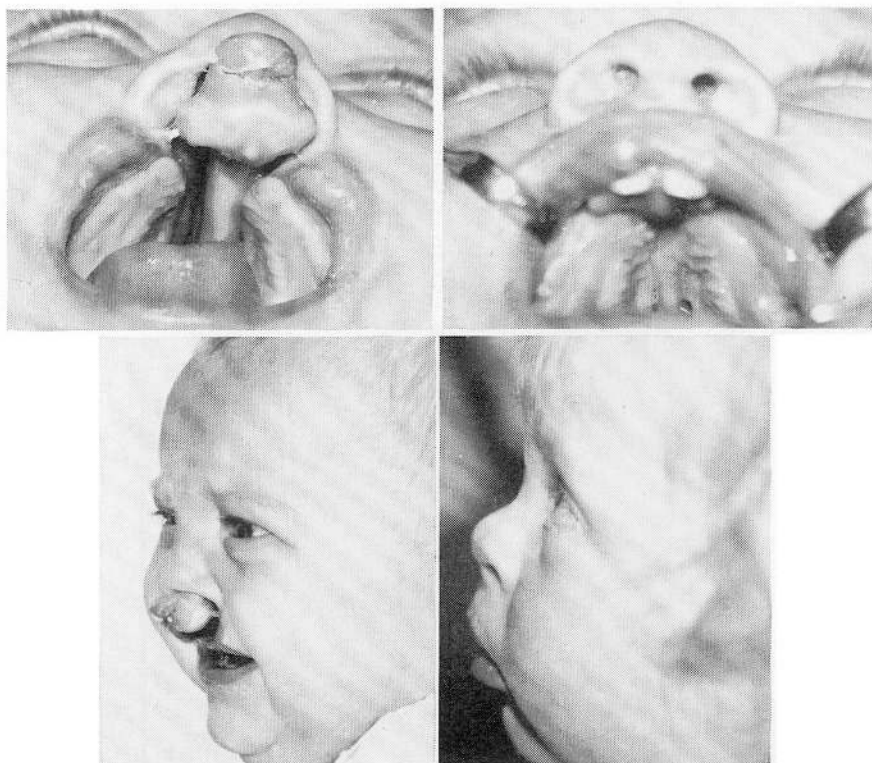


FIGURE 5. Left, complete bilateral cleft in a girl, aged three months, at the time of repair on the left side. The right side was repaired three months later. A lateral periosteal flap for cover was used on the latter side only. Right, the result nine months following the second operation. The premaxilla was then firmly consolidated into the alveolar arch.

narrow bridge of bone, corresponding in size and shape to the periosteal flap that had been shifted from the lateral segment at the time of repair. In this early case of the series, a fairly small triangular flap had been used which just reached the medial border, as did the newly formed bone. A distinct periosteal layer enclosed the new bone; it was easily stripped off, but appeared thinner than periosteum normally found in this region at that age. At the donor site for the periosteal flap, complete regeneration had taken place and the new periosteum was almost indistinguishable from the surrounding periosteal layer except that it was more adherent to the bone. In closing the wound, the periosteum within the cleft was partly separated from the new bone by subperiosteal packing with hemostatic sponge. This may explain why more bone had formed when x-ray films were taken three months later.

Roentgenograms taken three and six months postoperatively were not always easy to interpret because of the fineness of the structures and the lack of density of the new bone. Well-defined bridges across the cleft and/or processes extending from both the medial and lateral borders were most

easily distinguished (Figure 4). For the rest, the maxillary cleft contained tissue that radiologically could not be differentiated with certainty from nonspecific soft tissue apart from minor spots and streaks of greater density. The case illustrated in Figure 2 shows how such tissue is transformed into typical bone structure at a later stage.

In a case of incomplete cleft with a depressed nasal floor, a solid subcutaneous ridge could be felt corresponding to the periosteal flap three months following operation. X-ray laminography revealed symmetrical conditions and a not sharply defined bone contour within this area.

Naturally, follow-up studies of these cases have to be continued over the entire growth period to provide conclusive evidence. Comments with regard to the applicability of this new principle in the repair of maxillary deformity in clefts of the primary palate, its biological nature and anticipated late effects, will not be included in this preliminary report. Nor will suggestions on the many possible variations in surgical techniques be presented until further experience is gained.

Summary

This report suggests a new surgical approach to maxillary restoration in patients with cleft primary palate. An operative technique for primary repair of complete clefts has been developed utilizing periosteal flaps for the purpose of creating bony continuity between the premaxilla and the lateral maxillary segment, preventing maxillary collapse, and contributing to the restoration of symmetry of the alveolar arch. In incomplete clefts, the same principle has been applied to reduce the bony deficiency. Eight cases treated according to the technique described were examined three and six months postoperatively with regard to the maxillary configuration, especially approximation of the alveolar segments, and the formation of new bone. Though it is not yet possible to make an assessment concerning the long term advantages of the procedure proposed in this paper, the early results are promising in all respects, and the principle evolved appears to be of great value in restoring anatomical and functional continuity to the cleft primary palate.

*Akademiska sjukhuset
Uppsala, Sweden*

References

1. KÖRLOF, B., and BERGSTRÖM, R., Melanotic progonoma of the maxilla. *Acta chir. Scand.*, 129, 292-299, 1965.
2. PRUZANSKY, S., and ADUSS, H., Arch form and the deciduous occlusion in complete unilateral clefts. *Cleft Palate J.*, 1, 411-418, 1964.
3. SKOOG, T., A design for the repair of unilateral cleft lips. *Amer. J. Surg.*, 95, 223-226, 1958.
4. SKOOG, T., Porous tape in wound closure, skin grafting and wound dressing. *Acta chir. Scand.*, 126, 383-387, 1963.
5. SKOOG, T., The management of the bilateral cleft of the primary palate. *Plastic reconstr. Surg.*, 35, 140-147, 1965.
6. VEAU, V., *Bec-de-lièvre*. Paris: Masson & Cie, 1938.