

The Use of TKM-100802 and Convalescent Plasma in 2 Patients With Ebola Virus Disease in the United States

Colleen S. Kraft,^{1,2,a} Angela L. Hewlett,^{3,a} Scott Koepsell,⁴ Anne M. Winkler,¹ Christopher J. Kratochvil,⁵ LuAnn Larson,⁶ Jay B. Varkey,² Aneesh K. Mehta,² G. Marshall Lyon III,² Rachel J. Friedman-Moraco,² Vincent C. Marconi,² Charles E. Hill,¹ James N. Sullivan,⁷ Daniel W. Johnson,⁷ Steven J. Lisco,⁷ Mark J. Mulligan,² Timothy M. Uyeki,⁸ Anita K. McElroy,⁸ Tara Sealy,⁸ Shelley Campbell,⁸ Christina Spiropoulou,⁸ Ute Ströher,⁸ Ian Crozier,⁹ Richard Sacra,¹⁰ Michael J. Connor Jr,^{11,12} Viranuj Sueblinong,¹¹ Harold A. Franch,¹² Philip W. Smith,³ and Bruce S. Ribner²; for the Nebraska Biocontainment Unit and the Emory Serious Communicable Diseases Unit^b

¹Department of Pathology and Laboratory Medicine, and ²Division of Infectious Diseases, Department of Medicine, School of Medicine, Emory University, Atlanta, Georgia; ³Division of Infectious Diseases, Department of Internal Medicine, ⁴Department of Pathology and Microbiology, ⁵Office of the Vice Chancellor for Research, ⁶Center for Clinical and Translational Research, and ⁷Division of Critical Care, Department of Anesthesiology, University of Nebraska Medical Center, Omaha; ⁸Centers for Disease Control and Prevention, Atlanta, Georgia; ⁹World Health Organization, Kenema Hospital, Sierra Leone; ¹⁰University of Massachusetts Medical School, Worcester; and Divisions of ¹¹Pulmonary, Allergy and Critical Care, and ¹²Renal Medicine, Department of Medicine, Emory University, Atlanta, Georgia

(See the Editorial Commentary by Schooley on pages 503–5.)

Background. The current West Africa Ebola virus disease (EVD) outbreak has resulted in multiple individuals being medically evacuated to other countries for clinical management.

Methods. We report two patients who were transported from West Africa to the United States for treatment of EVD. Both patients received aggressive supportive care measures, as well as an investigational therapeutic (TKM-100802) and convalescent plasma.

Results. While one patient experienced critical illness with multi-organ failure requiring mechanical ventilation and renal replacement therapy, both patients recovered without serious long-term sequelae to date.

Conclusions. It is unclear what role the experimental drug and convalescent plasma had in the recovery of these patients. Prospective clinical trials are needed to delineate the role of investigational therapies in the care of patients with EVD.

Keywords. TKM-Ebola; convalescent plasma; convalescent serum; Ebola virus; Ebola virus disease.

Historically, outbreaks of Ebola virus disease (EVD) have been contained within rural regions of Africa, and limited in scope to a few hundred cases. This pattern changed, however, with the EVD outbreak that

started in Guinea in December of 2013, resulting in an unprecedented widespread epidemic [1].

Signs and symptoms of EVD appear within 2–21 days after Ebola virus (EBOV) infection [2]. EVD typically begins with fever, malaise, weakness, headache, and sometimes delirium [3]. A gastroenteritis and hepatitis phase follows, which has been predominant in this current outbreak [4]. This phase can result in multiorgan system failure, either as a result of excessive proinflammatory cytokine production [5] or as a direct effect of the viral invasion of affected organs [2]. A higher level of EBOV viremia is associated with higher mortality [6]. Moreover, the extent of acute organ failure influences the prognosis of recovery from EVD [7]. In some West African settings, aggressive volume repletion and

Received 9 February 2015; accepted 21 March 2015; electronically published 22 April 2015.

^aC. S. K. and A. L. H. contributed equally to this work.

^bThe members of the Nebraska Biocontainment Unit and the Emory Serious Communicable Diseases Unit Group are listed in the Appendix.

Correspondence: Colleen S. Kraft, MD, MSc, Department of Pathology and Laboratory Medicine, Division of Infectious Diseases, Emory University, 1364 Clifton Rd NE, F-145C, Atlanta, GA 30322 (colleen.kraft@emory.edu).

Clinical Infectious Diseases® 2015;61(4):496–502

© The Author 2015. Published by Oxford University Press on behalf of the Infectious Diseases Society of America. All rights reserved. For Permissions, please e-mail: journals.permissions@oup.com.

DOI: 10.1093/cid/civ334

minimal laboratory monitoring has improved survival, but mortality remains >40% [8].

Although several investigational therapies are being considered for treatment of EVD, all are in early stages of development with most in the preclinical stages [9]. Current approaches include (1) small-molecule inhibitors of virus entry and endosomal escape, (2) compounds that block viral replication, and (3) compounds aimed at symptoms of inflammation and coagulopathy [4, 10]. Only limited preclinical *in vivo* data are available, and few of these treatments have progressed to phase 1 clinical trials. The current outbreak has highlighted the need for proven treatments for patients with EVD [11]. As underscored in many reports, optimizing clinical supportive care for EVD patients may sustain survival until their native immune systems can clear EBOV viremia, promoting recovery [12, 13]. Improved supportive care may be contributing to the substantially lower mortality in EVD patients managed outside West Africa compared with resource-limited settings [3].

One investigational antiviral is a lipid-bound small interfering RNA (siRNA) [14, 15] known as TKM-100802, which targets the L polymerase, viral protein 24, and viral protein 35 [16]. In guinea pig models of EVD, TKM-100802 was found to be more efficacious and protective than the siRNAs carried by polyethylenimine polyplexes [17]. Additionally, in this experiment, treatment with 1 of the 4 siRNAs directed against the L polymerase protected guinea pigs from lethal EBOV challenge [17]. Furthermore, a combination of the modified siRNAs given for 7 days protected nonhuman primates (NHPs) after lethal challenge [16]. In NHPs, lipid nanoparticle delivery of an siRNA directed against the nucleoprotein of Marburg virus, a filovirus related to EBOV, was protective against lethal Marburg virus challenge [14].

Antibody production in individuals with EVD is associated with EBOV clearance; therefore, supporting the patient until initiation of robust antibody production is essential. Numerous studies have focused on the delivery of protective antibodies to patients during acute viremia before they mount an immune response, although few studies have been conducted with EVD [18, 19]. Convalescent plasma has been used to treat other viral diseases that are associated with high mortality, such as highly pathogenic avian influenza A(H5N1) [20]. In a limited study, whole blood from convalescent patients was used to treat 8 patients with EVD in 1995, with a reported mortality of 12.5% compared with 80% in controls [21]. However, the convalescent whole blood transfusion recipients received a higher level of supportive care than other EVD patients in the outbreak. In addition, the 7 patients who survived all had received the transfusion during the second week of illness, whereas the 1 patient who died received it on day 4, and a retrospective analysis reported that convalescent whole blood transfusion was not associated with survival from EVD. Another study did not find survival benefit of convalescent whole

blood transfusion in rhesus macaques when administered soon after lethal EBOV challenge and before symptom onset, compared with untreated animals. In 2012, Dye et al demonstrated protection of EBOV-challenged macaques from multiple administrations of purified, polyclonal, species-matched immunoglobulin G preparations obtained from vaccinated animals [22], suggesting that administration of high levels of species-matched antibodies may increase survival. At this time, the use of convalescent plasma derived from apheresis collections for treatment of EVD has not been systematically investigated.

Herein we report 2 individuals who were managed in the United States after contracting EVD in West Africa. Following informed consent in both patients, TKM-100802 was given under emergency use protocols filed to the Sponsor's Investigational New Drug (IND) application and approved by the US Food and Drug Administration, with the goal of 7 daily infusions: beginning with 0.3 mg/kg on day 1 of treatment, then 0.4 mg/kg on day 2, and 0.5 mg/kg on days 3–7. Similarly, after emergency IND and institutional review board approvals and patient consent, these patients also received convalescent plasma at a dose and frequency determined by the clinicians at each institution. The University of Nebraska Medical Center (UNMC) and Emory University Hospital (EUH) used the same plasma collection protocol, which did not include pathogen inactivation, initiated at UNMC and based on World Health Organization guidelines (<http://www.who.int/csr/resources/publications/ebola/convalescent-treatment/en/>) (Supplementary Data).

CASE REPORTS

Patient 1

The first patient was a previously healthy 51-year-old male physician who was working in a hospital near Monrovia, Liberia, when he developed persistent fever (temperature range, 37.7°C–39.0°C) on 29 August 2014 (day 1 of illness). He tested positive for EBOV by reverse transcription polymerase chain reaction (RT-PCR) on day 4 of illness and was admitted to an Ebola treatment unit in Monrovia, Liberia. On day 5 of illness, he developed nausea, vomiting, and diarrhea, and a diffuse pruritic rash. The patient was medically evacuated to the United States on day 7.

He arrived at the Nebraska Biocontainment Unit on 5 September 2014 (day 8 of illness). On arrival, he complained of nausea and exhibited vomiting along with watery diarrhea. His initial temperature was 36.9°C, blood pressure was 127/73 mm Hg, pulse was 85 beats/minute, respiratory rate was 16 breaths/minute, and oxygen saturation was 84% on room air. He was placed on 2 L/minute oxygen via nasal cannula, with improvement in oxygen saturation to 94%. On exam, he appeared extremely fatigued. He was able to answer questions but exhibited delirium. Physical examination was remarkable

for bilateral conjunctivitis, dry mucous membranes with mild oropharyngeal erythema, and diffuse macular rash that was pruritic. Initial laboratory studies demonstrated a white blood cell (WBC) count of 9.5×10^3 cells/ μ L, hemoglobin of 12.5 g/dL, and a platelet count of 32×10^3 platelets/ μ L. A coagulation profile and basic metabolic panel were within normal limits except for a potassium level of 3.2 mmol/L. Liver function tests revealed elevated aspartate aminotransferase (AST) (651 U/L), alanine aminotransferase (ALT) (203 U/L), γ -glutamyl transferase (GGT) (112 U/L), and normal total bilirubin (0.6 mg/dL). Aerobic and anaerobic blood cultures were negative.

An internal jugular central venous catheter was placed, and lactated Ringer's solution was administered at 100 mL/hour. The patient's oxygen saturation decreased to 88% on 2 L oxygen via nasal cannula, and a chest radiograph demonstrated findings suggestive of pulmonary edema; his condition improved after administration of 20 mg of intravenous furosemide. The patient was given the first TKM-100802 infusion (0.3 mg/kg) on the evening of day 8 of illness, and daily for the next 6 days (0.4 mg/kg on illness day 9, and 0.5 mg/kg on illness days 10–14). After the first 3 infusions, he experienced fever (maximum temperature [T_{\max}], 39.5°C) and rigors 30 minutes, 2.5 hours, and 5

hours after infusion, respectively. He also experienced rigors following the seventh infusion (T_{\max} , 37.9°C). One liter of type-specific convalescent plasma from a recovered EVD patient was infused in two 500-mL transfusions on days 9 and 10 of illness without evidence of a transfusion reaction. He was initiated on total parenteral nutrition on day 10 of illness, and as his gastrointestinal symptoms improved, he was able to tolerate small amounts of food beginning on day 12 of illness. The platelet count normalized to 153×10^3 platelets/ μ L on day 11 of illness. Aminotransferases trended upward to a peak AST of 1158 U/L and ALT of 351 U/L on day 9 of illness, then gradually trended downward, normalizing on day 24 of illness. His clinical status gradually improved; however, he continued to have significant weakness and marked fatigue. Throughout his stay, plasma samples were sent to the Centers for Disease Control and Prevention (Atlanta, Georgia) for monitoring of EBOV RNA levels. The lowest quantitative RT-PCR cycle threshold (Ct) value (reflecting highest EBOV RNA level) of 25.6 was recorded on admission, followed by a linear increase in Ct values during his hospitalization (Figure 1). Plasma tested negative for EBOV RNA on illness days 22, 24, and 25. He was discharged from the Nebraska Biocontainment Unit on day 28.

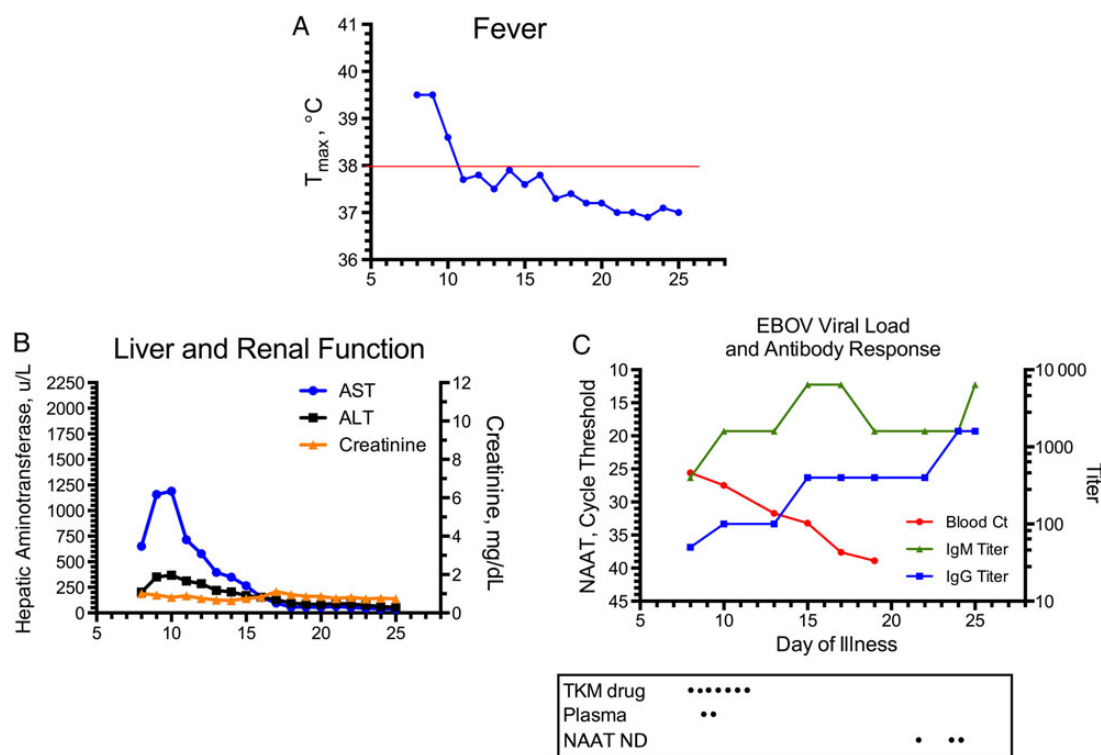


Figure 1. Temperature curve denoting fever (A), hepatic and renal function (B), and Ebola virus RNA level and antibody response (C) for patient 1 (Nebraska Biocontainment Unit). Abbreviations: ALT, alanine aminotransferase; AST, aspartate aminotransferase; Ct, cycle threshold; EBOV, Ebola virus; IgG, immunoglobulin G; IgM, immunoglobulin M; NAAT, nucleic acid amplification testing; ND, not detected; T_{\max} , maximum temperature.

Patient 2

The second patient was a previously healthy 43-year-old male physician who contracted EVD in Sierra Leone while treating patients in an Ebola treatment unit. On day 1 of illness he developed fever, generalized malaise, fatigue, and a bifrontal headache; EVD was confirmed on day 2 of illness. A petechial rash predominant over the trunk developed on day 3. He was medically evacuated to the United States and admitted to the Emory University Hospital Serious Communicable Diseases Unit (SCDU) on 9 September 2014 (day 4). Vital signs on admission included a temperature of 36.9°C, blood pressure 126/73 mm Hg, pulse 51 beats/minute, respiratory rate 12 breaths/minute, and oxygen saturation 98% on room air. He complained of a headache and anorexia, but was alert and oriented. Physical examination revealed an increased work of breathing and a petechial rash. Shortly after arrival he developed delirium. Within 10 hours of admission, his temperature rose to 40.0°C. An internal jugular central venous catheter was placed on admission.

Initial laboratory values included a WBC count of 2.6×10^3 cells/ μ L, hemoglobin level 13.1 g/dL, platelet count 62×10^3 platelets/ μ L, and international normalized ratio 1.2. A basic metabolic panel was within normal limits except for a potassium level of 3.7 mmol/L. Liver function tests were notable for

AST 155 U/L, ALT 40 U/L, GGT 55 U/L, and total bilirubin 0.5 mg/dL. Rapid malaria test on admission was negative.

The patient was given an initial TKM-100802 infusion (0.3 mg/kg) on the evening of day 3 of illness just prior to being medically evacuated, 0.4 mg/kg on day 4, and 0.5 mg/kg on days 5–8. The patient's blood had suspected lipemia as demonstrated by the chemistry analyzer reading on admission to EUH after the first infusion with TKM-100802; the lipemia worsened during the initial days of his hospital stay and interfered with the laboratory monitoring (Figure 2). He developed significant gastroenteritis and hepatitis on illness day 6, producing approximately 10 L of stool in a 24-hour period. Loperamide was given and stool output decreased. Stool testing on a multiplex PCR for gastrointestinal pathogens on day 7 of illness demonstrated the presence of enteropathogenic *Escherichia coli* that was treated empirically from days 7–9 with intravenous ceftriaxone.

On illness day 8, he developed oliguric acute kidney injury (AKI) with the visualization of muddy-brown casts in urine sediment, most likely secondary to acute tubular necrosis. His creatinine value peaked at 10.4 mg/dL on day 11. Progressive hypoxic acute respiratory failure developed that required invasive mechanical ventilation starting on illness day 9. Chest radiography

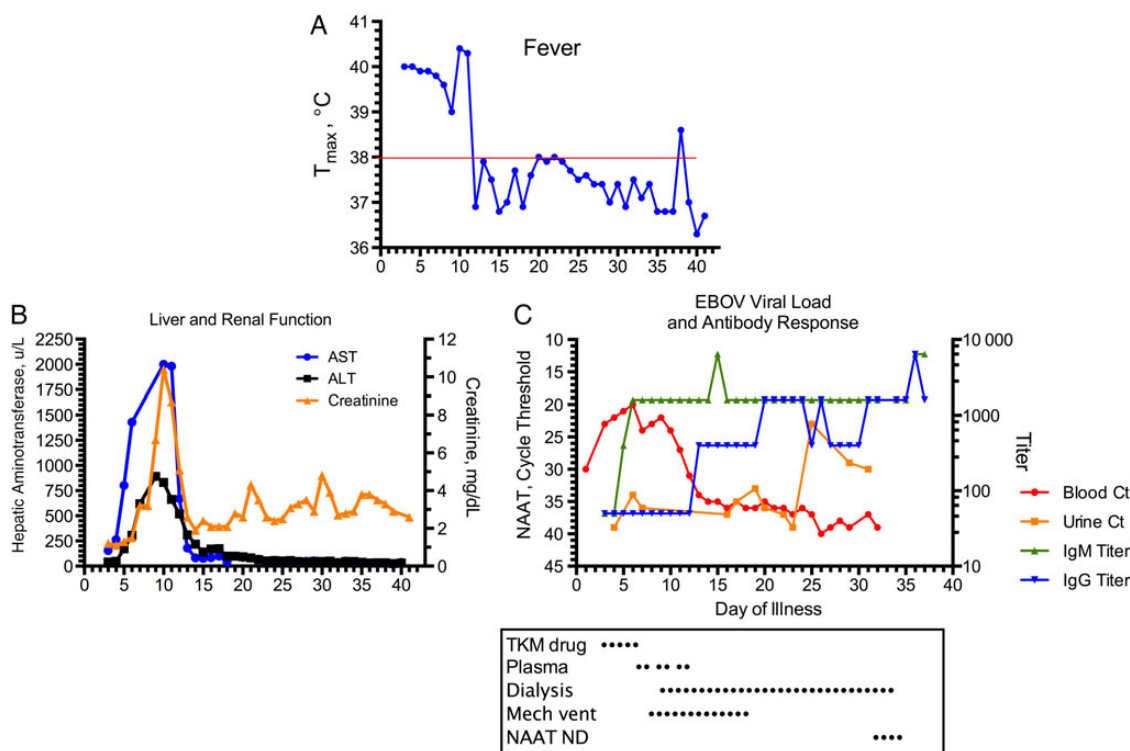


Figure 2. Temperature curve denoting fever (A), hepatic and renal function (B), and Ebola virus RNA level and antibody response (C) for patient 2 (Emory Serious Communicable Diseases Unit). Abbreviations: ALT, alanine aminotransferase; AST, aspartate aminotransferase; Ct, cycle threshold; EBOV, Ebola virus; IgG, immunoglobulin G; IgM, immunoglobulin M; Mech vent, mechanical ventilation; NAAT, nucleic acid amplification test; ND, not detected; T_{max} , maximum temperature.

performed per the Emory SCDU protocol [23] on that day demonstrated multifocal interstitial infiltrates consistent with acute respiratory distress syndrome (ARDS). TKM-100802 was discontinued after the fifth dose because of concern that this treatment was contributing to overall clinical deterioration. He developed worsening metabolic acidosis and atrial fibrillation with rapid ventricular response that responded to intravenous amiodarone. He was started on continuous renal replacement therapy (CRRT) on illness day 11 [24]. Six doses of convalescent plasma (500 mL each) from a recovered EVD patient were administered on days 8, 9, 11, 12, 14, and 15. Transfusion of the initial 500 mL was associated with worsening shortness of breath and increasing oxygen requirements. This event coincided with development of AKI and ARDS, requiring intubation. Transient vasopressor support with norepinephrine was required after initiation of CRRT. He was placed on low tidal volume ventilation for presumptive ARDS. The patient developed a paralytic ileus and had an increasing WBC to 22.6×10^3 cells/ μ L. Due to concerns for enteric bacterial translocation and sepsis on day number 13, ceftriaxone was replaced by meropenem for broad gram-negative coverage and ceftaroline was added for methicillin-resistant *Staphylococcus aureus* coverage as serum vancomycin levels could not be measured [12].

The patient's respiratory status slowly improved and he was extubated on day 21 of illness. After extubation, the patient remained delirious until day 30 of illness. The course of CRRT and renal outcomes has been described elsewhere [24], but the patient required CRRT for 24 total days and experienced renal recovery and liberation from dialysis.

His RT-PCR Ct values are detailed in Figure 2. On days 37 and 38 of illness, the patient had 2 blood specimens collected >24 hours apart that were negative for EBOV RNA, and he was transferred out of isolation in the biocontainment unit. He was discharged on illness day 44. Sequelae of illness included generalized deconditioning, proximal muscle weakness, difficulty ambulating, word-finding difficulties, and residual left shoulder capsulitis.

DISCUSSION

The treatment of patients with EVD in the United States presents an opportunity to evaluate investigational therapeutics in settings with close clinical and laboratory monitoring. However, it is unknown whether the uncontrolled use of any specific experimental treatment modality or combinations thereof may have altered the clinical course of these EVD survivors.

Aggressive supportive care likely contributed to the recovery of these patients, which has also been observed in patients treated in Europe [4, 12]. In both of the patients described in this report, anorexia and severe gastroenteritis were dominant symptoms, and early nutritional replacement was provided with total parenteral nutrition. Fluid replacement and

electrolyte monitoring with supplementation were important in the supportive care for both patients, consistent with earlier reports [11]. Empiric antibiotics were given to patient 2 for possible secondary bacterial septicemia; however, all blood cultures were negative. We have also described that invasive mechanical ventilation and CRRT can be safely performed in facilities with training and experience in caring for these highly infectious patients [24], which can provide an additional level of supportive care until their viremia diminishes and organ injury or failure resolves. It is also apparent that when the viremia resolves, the direct and indirect effects of EBOV infection improve.

These 2 EVD patients were the first to receive both TKM-100802 and convalescent plasma derived from an apheresis collection. The deteriorating clinical course of patient 2 was attributed to EVD, but the possibility that the experimental treatments played some role cannot be excluded. In prior clinical studies for TKM-100802 regarding the safety and efficacy of siRNA for treatment of transthyretin amyloidosis, there were no significant changes in hematologic, hepatic, or renal measurements or in thyroid function, and there were no drug-related serious adverse events or any study-drug discontinuations because of adverse events [25]. Patient 1 completed 7 days of TKM-100802 and experienced fever and rigors, which are not unexpected adverse events with an siRNA product. In patient 2, TKM-100802 was discontinued after 6 days because of clinical decline, resulting in multiorgan system failure. Activation of inflammatory pathways can predispose to pathology including AKI, but it is unclear what role, if any, TKM-100802 played in the course of illness in these 2 patients. Future studies with siRNA products should direct attention to the possibility of adverse effects by the mechanism of immune activation.

Regarding the utility of convalescent plasma, it is similarly unclear if the anti-Ebola immunoglobulins or other plasma components contributed to the patients' recoveries. Endothelial activation and associated damage are associated with EBOV infection and may be similar to trauma situations where there is massive endothelial disruption. Therefore, replenishing plasma coagulation factors may be a beneficial therapy [26]. There are also active components in human plasma or whole blood that may help treat diseases associated with vascular leakage via endothelial stabilization and colloid support [27]. Convalescent plasma is not a standardized product, and further investigation regarding levels of neutralizing antibodies, as well as polyfunctional antibodies, is necessary. It is unclear what the therapeutic regimen should be for convalescent plasma (eg, number of doses, volume, timing) and what constitutes an effective donor by EBOV-specific antibody testing. Finally, the 2 patients we have described received type-specific convalescent plasma, but ABO-incompatible convalescent plasma transfusions could be considered if a compatible type were not available.

Both of these patients received TKM-100802 followed by convalescent plasma for the treatment of EVD. Both patients survived; however, the contribution of the investigational therapies to clinical recovery is unknown. Controlled trials are needed to determine the effects that such therapies have on the clinical course of EVD.

Supplementary Data

Supplementary materials are available at *Clinical Infectious Diseases* online (<http://cid.oxfordjournals.org>). Supplementary materials consist of data provided by the author that are published to benefit the reader. The posted materials are not copyedited. The contents of all supplementary data are the sole responsibility of the authors. Questions or messages regarding errors should be addressed to the author.

Notes

Acknowledgments. We acknowledge the support of the patients' family and friends. We acknowledge the US Food and Drug Administration for support in the obtaining of the emergency Investigational New Drugs to treat these patients, in Center for Drug Evaluation and Research, Drs Debra Birnkrant and Robert Kosko and the staff at the Division of Antiviral Products and Center for Biologics Evaluation and Research, Dr Nisha Jain and her staff; the institutional review boards at the University of Nebraska Medical Center and Emory University Hospital, as well as the research pharmacies at both institutions; Dr Rob Fowler, Dr Shevin Jacob, Dr Caroline Cross, and Mr Will Pooley with the World Health Organization; Drs Ian MacLachlan and Mark Kowalski at Tekmira; Dr Stuart Nichol, Aridth Gibbons, Bobbie Rae Erickson, and Deborah Cannon at the Viral Special Pathogens Branch of the Centers for Disease Control and Prevention (CDC); Dr Monica Farley at the Division of Infectious Diseases at the Emory University School of Medicine; and Dr Tristram Parslow at the Department of Pathology and Laboratory Medicine at the Emory University, Atlanta, Georgia.

Disclaimer. The views expressed in this article are those of the authors and do not necessarily represent the official position of the CDC.

Financial support. Emory's participation was supported by the National Center for Advancing Translational Sciences of the National Institutes of Health under award number UL1TR000454 (Atlanta Clinical and Translational Science Institute).

Potential conflicts of interest. C. E. H. has served on the advisory board for Molecular Diagnostics and the Roche Diagnostics Corporation. U. S. has worked at the Public Health Agency of Canada and co-invented 2 of the monoclonal antibodies ZMapp is based on. All other authors report no potential conflicts.

All authors have submitted the ICMJE Form for Disclosure of Potential Conflicts of Interest. Conflicts that the editors consider relevant to the content of the manuscript have been disclosed.

References

1. Del Rio C, Mehta AK, Lyon GM 3rd, Guarner J. Ebola hemorrhagic fever in 2014: the tale of an evolving epidemic. *Ann Intern Med* **2014**; 161:746–8.
2. Fletcher TE, Fowler RA, Beeching NJ. Understanding organ dysfunction in Ebola virus disease. *Intensive Care Med* **2014**; 40:1936–9.
3. Chertow DS, Kleine C, Edwards JK, Scaini R, Giuliani R, Sprecher A. Ebola virus disease in West Africa—clinical manifestations and management. *N Engl J Med* **2014**; 371:2054–7.
4. Yazdanpanah Y, Arribas JR, Malvy D. Treatment of Ebola virus disease. *Intensive Care Med* **2015**; 41:115–7.
5. McElroy AK, Erickson BR, Flietstra TD, et al. Ebola hemorrhagic fever: novel biomarker correlates of clinical outcome. *J Infect Dis* **2014**; 210:558–66.
6. Towner JS, Rollin PE, Bausch DG, et al. Rapid diagnosis of Ebola hemorrhagic fever by reverse transcription-PCR in an outbreak setting and assessment of patient viral load as a predictor of outcome. *J Virol* **2004**; 78:4330–41.
7. Rollin PE, Bausch DG, Sanchez A. Blood chemistry measurements and D-dimer levels associated with fatal and nonfatal outcomes in humans infected with Sudan Ebola virus. *J Infect Dis* **2007**; 196(suppl 2): S364–71.
8. Bah EI, Lamah MC, Fletcher T, et al. Clinical presentation of patients with Ebola virus disease in Conakry, Guinea. *N Engl J Med* **2015**; 372:40–7.
9. Cox E, Borio L, Temple R. Evaluating Ebola therapies—the case for RCTs. *N Engl J Med* **2014**; 371:2350–1.
10. Choi JH, Croyle MA. Emerging targets and novel approaches to Ebola virus prophylaxis and treatment. *BioDrugs* **2013**; 27:565–83.
11. Lyon GM, Mehta AK, Varkey JB, et al. Clinical care of two patients with Ebola virus disease in the United States. *N Engl J Med* **2014**; 371: 2402–9.
12. Kreuels B, Wichmann D, Emmerich P, et al. A case of severe Ebola virus infection complicated by gram-negative septicemia. *N Engl J Med* **2014**; 371:2394–401.
13. Wolf T, Kann G, Becker S, et al. Severe Ebola virus disease with vascular leakage and multiorgan failure: treatment of a patient in intensive care. *Lancet* **2015**; 385:1428–35.
14. Thi EP, Mire CE, Ursic-Bedoya R, et al. Marburg virus infection in non-human primates: therapeutic treatment by lipid-encapsulated siRNA. *Sci Transl Med* **2014**; 6: 250ra116.
15. Ursic-Bedoya R, Mire CE, Robbins M, et al. Protection against lethal Marburg virus infection mediated by lipid encapsulated small interfering RNA. *J Infect Dis* **2014**; 209:562–70.
16. Geisbert TW, Lee AC, Robbins M, et al. Postexposure protection of non-human primates against a lethal Ebola virus challenge with RNA interference: a proof-of-concept study. *Lancet* **2010**; 375:1896–905.
17. Geisbert TW, Hensley LE, Kagan E, et al. Postexposure protection of guinea pigs against a lethal Ebola virus challenge is conferred by RNA interference. *J Infect Dis* **2006**; 193:1650–7.
18. Audet J, Wong G, Wang H, et al. Molecular characterization of the monoclonal antibodies composing ZMAB: a protective cocktail against Ebola virus. *Sci Rep* **2014**; 4:6881.
19. Wang Y, Liu Z, Dai Q. A highly immunogenic fragment derived from Zaire Ebola virus glycoprotein elicits effective neutralizing antibody. *Virus Res* **2014**; 189:254–61.
20. Zhou B, Zhong N, Guan Y. Treatment with convalescent plasma for influenza A (H5N1) infection. *N Engl J Med* **2007**; 357:1450–1.
21. Mupapa K, Massamba M, Kibadi K, et al. Treatment of Ebola hemorrhagic fever with blood transfusions from convalescent patients. International Scientific and Technical Committee. *J Infect Dis* **1999**; 179(suppl 1): S18–23.
22. Dye JM, Herbert AS, Kuehne AI, et al. Postexposure antibody prophylaxis protects nonhuman primates from filovirus disease. *Proc Natl Acad Sci U S A* **2012**; 109:5034–9.
23. Auffermann WF, Kraft CS, Vanairsdale S, Lyon GM 3rd, Tridandapani S. Radiographic Imaging for patients with contagious infectious diseases: how to acquire chest radiographs of patients infected with the Ebola virus. *AJR Am J Roentgenol* **2015**; 204:44–8.
24. Connor MJ Jr, Kraft C, Mehta AK, et al. Successful delivery of RRT in Ebola virus disease. *J Am Soc Nephrol* **2015**; 26:31–7.
25. Coelho T, Adams D, Silva A, et al. Safety and efficacy of RNAi therapy for transthyretin amyloidosis. *N Engl J Med* **2013**; 369:819–29.
26. Pati S, Matijevic N, Doursout MF, et al. Protective effects of fresh frozen plasma on vascular endothelial permeability, coagulation, and resuscitation after hemorrhagic shock are time dependent and diminish between days 0 and 5 after thaw. *J Trauma* **2010**; 69(suppl 1):S55–63.
27. Urner M, Herrmann IK, Buddeberg F, et al. Effects of blood products on inflammatory response in endothelial cells in vitro. *PLoS One* **2012**; 7: e33403.

APPENDIX

Nebraska Biocontainment Unit team: *NBU Leadership Team*: Philip Smith (Medical Director), Angela Hewlett (Associate Medical Director), Shelly Schwedhelm (Nursing Director), Kate Boulter (Lead Nurse), Elizabeth Beam (Nursing Educator), Shawn Gibbs (Decontamination Specialist), John Lowe (Transport Specialist), Chris Kratochvil (Clinical Research); *Critical Care*: James Sullivan, Dan Johnson, Steve Lisco, Craig Piquette, Kristina Bailey, Joseph Auxier, Brian Boer, Travis Hanson, Julia Kaseman, M. Salman Khan, Ji Hyun Rhee, Adam Wells; *Infectious Diseases*: Diana Florescu, Andre Kalil, Mark Rupp; *Nursing*: Valerie Becker, Bridget Boeckman, Erica Elder, Abby Fitch, Elizabeth Flood, Meagan Freml, Roman Frigge, Kelly Ann Hanzlik, Lois Jensen, Nicole Kraus, Drew Molacek, Jerry Nevins, Alicia Parker, Jeff Peters, Cheryl Rand, Karen Roesler, Kendall Ryalls, Morgan Shradar, Amanda Strain, Timothy Sunderman, Jennifer Sundermeier, John Swanhorst, Angela Vasa; *Respiratory Therapy*: Jean Bellinghausen, Frank Freihaut, Susan Denny, Lauren Mainelli, Dee Pinkney, Deborah Ray; *Patient Care Technicians*: Jay Jevne, Kalen Knight, Derrick McCroy, Ralph Nadeau, Anna Nightser; *Laboratory*: Pete Iwen, Tony Sambol, Vicki Herrera, David Morgan, Sarah Trotter, Amy Kerby, Sue Peters, Timothy Southern, Caitlin Murphy; *Administration*: Rosanna Morris, Sue Nuss, Theresa Franco, Connie Ogden, Julie Lazure, Dawn Straub; *Blood Bank*: Scott Koepsell; *Pathology*: Steve Hinrichs; *Nephrology/Dialysis*: Troy Plumb, Marius Florescu, John Becker, Jenna Soucek; *Pharmacy*: Jon Beck; *Clinical Research Center*: Luann Larson, Peggy Heires; *Institutional Review Board*: Bruce Gordon, Gail Paulsen; *Occupational Health*: Barb Wolford, Jill Petersen; *Infection Control*: Nedra Marion, Kim Hayes, Kate Tyner; *Communications/Media Relations*: Taylor Wilson, Paul Baltes, Jenny Nowatzke; *Environmental Services*: Jonathan Nguyen, Paul Turner; *Supplies/Logistics*: Barb Boonstra, Katelyn Jelden, Randy Portrey, Doug Stringfield; *Security*: Bryan Scofield, Gary Svanda; *Radiology*: Jolene Horihan, Chris Dahl, Megan Bruno, Kelsey Malm, Ron Litz, Jessica Fehringer, Katie Paladino, Tammy Opp. Emory Serious Communicable Diseases Unit team: *SCD Unit*

Coordinator: Sonia Bell; *Administration*: Anne Adams, Mary Beth Allen, Robert Bachman, William Bornstein, Dee Cantrell, Pam Cosper, Nancy Feistritz, John Fox, Bryce Gartland, Jen Goodman, Susan Grant, Dallis Howard-Crow, Ira Horowitz, David Pugh, Chad Ritenour; *Nursing*: Toni Ash, Christopher Barnes, Jason Calhoun, Lauren Chapman, Tracey Daye, Haley Durr, Shunasee Evans, Janice Gentry, Jan Ginnane, Susan Grant, Chris Haynes, Carolyn Hill, Dustin Hillis, Crystal Johnson, Jessica Loomis, Josia Mamora, Laura Mitchell, Jill Morgan, Nancy Osakwe, Jacqueline Owen, Sarah Piazza, Kristina Shirley, Jodi Siddens, Carrie Silas, Jason Slabach, Elaina Tirador, Donnette Todd, Sharon Vanairsdale; *Emory Medical Labs*: Nicole Brammer, Juli Buchanan, Eileen Burd, John Cardella, Brenda Eaves, Crystal Evans, Krista Hostetler, Karen Jenkins, Maureen Lindsey, Jordan Magee, Randall Powers, James Ritchie, Emily Ryan, Shannon Bonds; *Pharmacy*: Amir Emamifar, Tish Kuban, Jan Pack, Susan Rogers; *Emory Health and Safety*: George Golston, Sean Kaufman, Patricia Olinger, Sean Olinger, Kalpana Rengarajan, Scott Thomaston; *Occupational Health*: Emily Beck, Paula Desroches, Cynthia Hall, Celeste Walker; *Infection Control*: Connie Bryant, Betsy Hackman, Regina Howard, Marolyn Jones; *Environmental Services*: Jeff Broughton, Brian Frisle, Robert Jackson, Jerry Lewis; *Pastoral Care*: Robin Brown-Haithco, Miranda Lynn Gartin, Erica Gerald-Washington, Rhonda James-Jones, Donald Miller, Dan Stark; *Supplies/Logistics*: Gentrice McGee, Porcia Jones; *EUH Security*: Linda Scott-Harris, James Cain, Roderick Davis, Tyrone Johnson, Tyrone Pickett, Anthony Shaw, Tenina Truesdale; Emory Center for Critical Care Medicine: Jim Blum, Lauren Hill, Jon Sevransky, Joel Zivot, Seth Walker; Department of Anesthesia: Matthew Klopman, Ricky Matkins, Cathy Meechan, Paul Meechan, Kathy Schwock, Jen Schuck, Kathy Stack, Francis Wolf, *Respiratory Therapy*: Bruce Bray, *Emergency Medicine*: Alex Isakov, Sam Shartar, Wade Miles, Aaro Jamison, John Arevalo, Gail Stallings; *Communications/Media Relations*: Janet Christenbury, Vince Dollard, Melanie De Gennaro, Holly Korschun, Nancy Seideman; *Nutrition*: Tom Ziegler, Daniel P. Griffith, Nisha Dave; *Renal Medicine*: Susan Wall, Melida Hall; *Radiology*: Dwania McGhee, Tim Clarke, Rachel Vaught, Katrina Peterson-Pileri.