

## REVIEW ARTICLE

# The use of visual feedback, in particular mirror visual feedback, in restoring brain function

V. S. Ramachandran<sup>1</sup> and Eric L. Altschuler<sup>1,2</sup>

1 Center for Brain and Cognition, University of California, San Diego, La Jolla, CA 92093-0109, USA

2 Department of Physical Medicine and Rehabilitation, University of Medicine and Dentistry of New Jersey, Newark, NJ 07103, USA

Correspondence to: V. S. Ramachandran,  
Center for Brain and Cognition,  
University of California,  
San Diego, 9500 Gilman Drive,  
0109, La Jolla,  
California 92093-0109, USA  
E-mail: vramacha@ucsd.edu

This article reviews the potential use of visual feedback, focusing on mirror visual feedback, introduced over 15 years ago, for the treatment of many chronic neurological disorders that have long been regarded as intractable such as phantom pain, hemiparesis from stroke and complex regional pain syndrome. Apart from its clinical importance, mirror visual feedback paves the way for a paradigm shift in the way we approach neurological disorders. Instead of resulting entirely from irreversible damage to specialized brain modules, some of them may arise from short-term functional shifts that are potentially reversible. If so, relatively simple therapies can be devised—of which mirror visual feedback is an example—to restore function.

**Keywords:** mirror visual feedback; phantom limb; phantom pain; hemiparesis; complex regional pain syndrome

**Abbreviations:** CRPS=Complex regional pain syndrome; MVF=mirror visual feedback; RSD=reflex sympathetic dystrophy

## Introduction

Three somewhat artificial dichotomies have bedeviled neurology since its origins. First, there was a debate over whether different mental capacities are sharply localized ('modularity') or are they mediated in a holistic manner? Second, if specialized modules do exist, do they function autonomously or do they interact substantially? Third, are they hardwired or can they be modified by changing inputs, even in adult brains? (And, as a corollary, is damage to the brain irreversible in the adult or is any recovery possible?)

Countless generations of medical students had been taught that functions are localized, hardwired and damage is usually permanent; although there had always been dissenting voices.

But a paradigm shift is now underway in neurology with an increasing rejection of the classical dogma. The shift had its early

beginnings in the work of the late Patrick Wall, and evidence for the 'new' view of brain function was marshaled by a number of groups, most notably by Merzenich *et al.* (1983), Bach-y-Rita *et al.* (1969), Fred Gage (Suhonen *et al.*, 1996) and Alvaro Pasqua Leone (Kauffman *et al.*, 2002). Their studies provided evidence both for strong intersensory interactions as well as plasticity of brain modules. It is noteworthy that all of these studies were on adult brains; contradicting the dogma of immutable brain connections.

In 1992, we introduced the use of mirror visual feedback (MVF) a simple non-invasive technique for the treatment of two disorders that have long been regarded as permanent and largely incurable; chronic pain of central origin (such as phantom pain) and hemiparesis following a stroke. A host of subsequent studies were inspired by these findings—utilizing visual feedback conveyed through mirrors, virtual reality or, to some extent,

even through intense visualization (which would be expected to partially stimulate the same neural circuits as the ones activated by MVF). We will review the efficacy of MVF—based on recent clinical trials—followed by speculations on why the procedure works, what future applications it might have, and what its broader implications are for neurology.

The procedure is not miracle cures by any means, but even if only a small proportion of patients is helped, they would be of enormous value given the high incidence of phantom pain and stroke; one-tenth of mankind will suffer from stroke-related paralysis and more than two-thirds of patients suffer from phantom pain after loss of a limb. Moreover, even if the procedure benefits a minority of patients, it is likely to pave the way for future more completely effective therapies once we understand the variables involved.

## Phantom limbs

When an arm or leg is amputated, many patients continue to experience the vivid presence of the limb; hence the evocative term ‘phantom limb’ coined by Mitchell (1872). In addition, a large proportion of them also experience severe intractable pain in their phantom that can persist for years after amputation. The pain can be burning, cramping, crushing or lancinating. It can be intermittent or unrelenting, severely compromising the patient's life. Some patients become depressed and even contemplate suicide. Over 30 procedures have been tried for phantom pain ranging from ineffective but harmless procedures like hypnosis, to invasive brain surgery. Typically, these therapies are either ineffective or only slightly effective. Most have never been evaluated in placebo-controlled clinical trials (e.g. sham surgery) despite the fact that pain is notoriously susceptible to placebo.

In the early 1990s, we performed two experiments to explore the nature of phantom limbs and the origin of phantom pain

(Ramachandran *et al.*, 1992; Yang *et al.*, 1994). The results of such experiments paved the way for the discovery of MVF.

## Plasticity of connections

In one of our early experiments, we recruited a 19-year-old man who had lost his left forearm in a car accident 3 weeks prior to our seeing him. He was mentally lucid and neurological examination was unremarkable. He experienced a vivid phantom arm which was intermittently painful.

We then had the patient seated on a chair blindfolded and simply touched him with a Q-tip on different parts of his body (Ramachandran *et al.*, 1992).

We asked him to report what he felt and where. For most parts of the body he reported the location of the sensation accurately. But when we touched his ipsilateral face, he reported with considerable surprise that he felt the touch not only on his face—as expected—but also on his missing phantom hand. Touching different parts of the face elicited precisely localized sensations on different parts of the phantom arm. The margins of different fingers were clearly delineated and there was a crudely topographic organization. Stroking the cheek was felt as stroking on the phantom and tapping was felt as tapping.

Inspired, in part, by physiological work on primates demonstrating an extraordinary malleability of topographically organized maps in S1, we came up with a conjecture to explain why VQ (and other patients like him) experience their phantom being touched when their ipsilateral face was touched.

There is a complete topographic map of the contralateral skin surface on the post-central sensory strip (S1) of the parietal lobe as depicted in the famous Penfield homunculus (Fig. 1) (Penfield and Boldrey, 1937). This map provides the vital clue for it shows that the face representation in the map is right next to the hand representation. When the arm is amputated the hand region of the cortex does not receive sensory input so it is possible that the

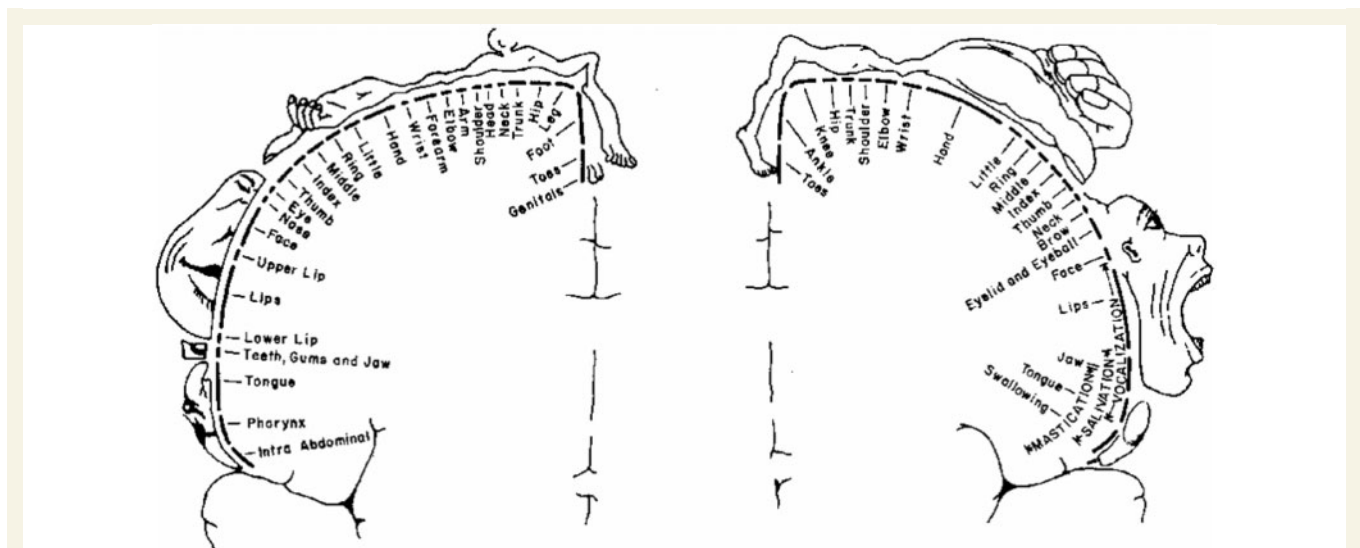
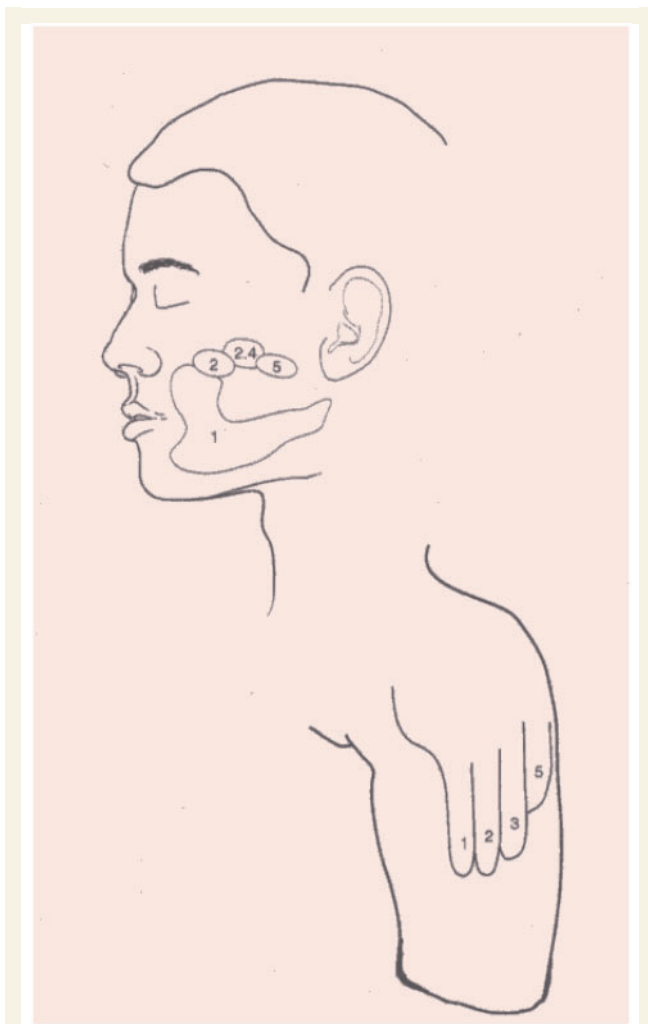


Figure 1 Penfield sensory (left) and motor (right) homunculi (Penfield and Boldrey, 1937).



**Figure 2** Topographic map of the hand onto the face (and stump) (from Ramachandran and Hirstein, 1998).

sensory input from the face ordinarily destined to go exclusively to the face area of cortex now 'invades' the deafferented hand region. As a result, touching the face not only activates cells in the face area as it should but also activates the hand area, which is then interpreted by higher brain centers as arising from the phantom hand (Fig. 2).

The referral was also modality specific in some patients: Water trickling down the face was felt as 'trickle' down the phantom. A drop of hot water on the face elicited highly localized heat in the phantom; an ice cube felt cold on the phantom and the phantom vibrated if a vibrator was placed on the jaw. In other patients, however, touch alone is referred but not temperature suggesting that different tactile modalities can sometimes be uncoupled during reorganization.

We tested these ideas by using magnetoencephalography (MEG) to map out S1 topography on the side contralateral to the amputation compared with the ipsilateral hemisphere. As expected there was a massive invasion from the face area to the hand zone (Ramachandran, 1993; Yang *et al.*, 1994). For further discussion of neural plasticity and phantom limbs see Ramachandran and Rogers-Ramachandran (2000).

**Table 1** Remapping and cortical plasticity in human amputees/phantom limbs and other conditions

|                                   |   |
|-----------------------------------|---|
| Ramachandran <i>et al.</i> (1992) | Arm amputees touched on the face note sensation in amputated hand.  |
| Yang <i>et al.</i> (1994)         | Magnetoencephalogram (MEG) demonstrates cortical remapping consistent with clinical findings.                                 |
| Aglioti <i>et al.</i> (1994)      | Referred sensations from genital area to amputated leg.   |
| Clarke <i>et al.</i> (1996)       | Remapping of sensations of face referred to hand after trigeminal nerve resection.  |
| Aglioti <i>et al.</i> (1997)      | Referred sensation from face to an amputated index finger.  |
| Kew <i>et al.</i> (1997)          | Positron emission tomography PET imaging indicates functional neurophysiologic correlates of cortical and clinical remapping. |
| Turton and Butler (2001)          | Referred sensations following stroke.   |
| McCabe <i>et al.</i> (2003a)      | Referred sensations in patients with CRPS.  |

This result was the first demonstration of large-scale reorganization of topography in the adult human brain with highly specific perceptual consequences.

These psychophysical and brain-imaging results were replicated by several groups and additional evidence was also marshaled to support what we have called the 'Remapping theory of referred sensations' (Table 1).

- (i) After leg amputation, sensations are referred from genitals to phantom foot (Ramachandran, 1993; Aglioti *et al.*, 1994). This is consistent with the anatomical proximity of foot and genitals in the map (Penfield and Boldrey, 1937).
- (ii) After amputation of a finger, sensations are referred from the adjacent fingers to the phantom, and intriguingly, a reference field of a single finger was found on the ipsilateral cheek (Agliotti *et al.*, 1997).
- (iii) Imaging studies (e.g. Kew *et al.*, 1997) find functional connectivity in adjacent somatotopic sensory map cortical regions correlating with clinically reported referred sensation.
- (iv) After severing the trigeminal nerve (which supplies the face), a map of the FACE was found on the hand; the exact converse of our effect and a striking vindication of what we dubbed the 'remapping hypothesis' of referred sensations (Clarke *et al.*, 1996).
- (v) Face to hand referral is also seen after cortical deafferentation of the hand caused by stroke damaging the internal capsule and thalamus (Turton and Butler, 2001). This implies that remapping can occur in the cortex but it does not prove that it cannot occur in the thalamus.
- (vi) Very soon after arm amputation topographically organized referral is seen from hand to hand in some patients implicating plasticity of interhemispheric transcallosal connections. Again, this requires cortical involvement—although it does not rule out the possibility of additional thalamic plasticity.

- (vii) With time there can be disorganization of previously precisely topographically mapped referred sensations (Halligan *et al.*, 1994).
- (viii) The number of sites from which phantom sensations—especially pain—are referred correlates with the extent of cortical reorganization (Knecht *et al.*, 1996).
- (ix) After damage to the acoustic nerve, some patients develop a curious syndrome called gaze tinnitus; lateral eye gaze causes them to hear a sound. Consistent with our remapping hypothesis Cacace *et al.* (1994) suggested that the deafferentation of the acoustic nerve nucleus causes corticofugal fibers destined to the abducens nucleus (involved in lateral gaze) to cross-innervate the adjacent auditory nucleus causing sounds to be heard every time a lateral eye gaze command is sent.
- (x) Referred sensations in limbs to areas adjacent on the Penfield homunculus have been found in patients with complex regional pain syndrome (McCabe *et al.*, 2003a).

## Phantom pain

Apart from their intrinsic interest, phantom limbs are clinically important because up to 50–80% of patients (Jensen and Nikolajsen, 1999) suffer from often severe unremitting pain. Many patients can move their phantoms but almost an equal number claim that their phantom is immobile and paralysed, often occupying a highly awkward position. The pain can last for years and can either be continuous or intermittent, as when the fingers go into a clenching spasm 'with nails digging into the palm.' The patient is usually unable to unclench the fist or move the hand volitionally to relieve the pain.

The origin of phantom pain is poorly understood and since it has already been reviewed elsewhere (Ramachandran and Hirstein, 1998) we will be brief. We can speculate that there are at least five origins.

- (i) Irritation of curled up nerve endings (neuromas) and scar tissue in the amputation stump.
- (ii) While central remapping (leading to referred sensations) is usually topographically organized and modality specific, it is pathological—almost by definition. Consequently some low threshold touch input might cross-activate high threshold pain neurons
- (iii) The pathological 'remapping' can lead to a chaotic 'junk' output which, in itself, might be interpreted as both paresthesias and pain by higher brain centers. This is supported by the observations of Flor and her colleagues (1995) who found that the magnitude of phantom pain correlates with degree of reorganization. See also Maclver *et al.* (2008).
- (iv) The mismatch between motor commands and the 'expected' but missing visual and proprioceptive input may be perceived as pain.
- (v) The tendency for the pre-amputation pain whether brief (e.g. a grenade blast, car accident) or chronic (cancer) to persist as a 'memory' in the phantom.

Of these presumed causes (i)—neuromas—are probably the least important even though they are the prime targets for surgeons. On the other hand, the combined emergence of abnormal patterns of impulses from (ii) and (iii) might lead to the excruciating pain of phantoms.

Many patients with a phantom make the oxymoronic claim that the phantom is paralysed—'as if stuck in cement' or 'frozen in a block of ice'. We noticed that these were often, though not invariably, patients whose arm had been intact but actually paralysed by peripheral nerve injury—such as a brachial avulsion—for months prior to amputation. When the arm was intact, every time a motor command was sent to the intact arm the visual (and proprioceptive) signals came back informing the brain that the arm was NOT moving. Perhaps this association becomes 'stamped' in the brain as a form of 'learned paralysis'—which then carries over into the phantom. If this argument is correct would it be possible to 'unlearn' the learned paralysis, whether in phantom pain or paralysis from stroke? (Which may also partially involve a form of learned paralysis; see below.)

The concept of 'learned paralysis' has also been applied by us to partially account for the hemiparesis that follows stroke and we demonstrated that MVF can accelerate recovery of limb function in many patients (see below). This idea is different from the important notion of learned 'non-use' proposed by Taub (1980) for post-stroke paralysis, which simply involves postulating a long period of non-use of the paralysed arm leading to reversible loss of neural function. Taub's model also differs from ours in that it does not invoke visual feedback or mismatched signals. This makes our therapeutic intervention (using 'false' visual feedback) radically different from theirs (restricting the use of the good arm).

Taub's technique (Wolf *et al.*, 2006) involves the intact arm being restrained and restricted from use by a mitt for at least 90% of a patient's waking hours for a 2 week period. During this time the patient tries to use the paralysed arm to the extent possible with up to 6h of practice a day, the movements being partially guided by a therapist. (Whereas, in MVF studies patients only used the mirror for about half an hour a day and, in some studies was self-administered by the patient.) It is conceivable if MVF is instituted for equivalently long periods the extent of recovery would be even more complete than has been shown to be the case so far. It may well turn out that different treatments—or combinations of them in different ratios—are suitable for different patients.

The observations on remapping suggest that connections in the adult human brain are extraordinarily malleable, but can the malleability be exploited clinically? This question set the stage for our next set experiments which employed an optical trick to see if visual feedback can modulate somatic sensations—including pain—in the phantom.

One contributing factor in phantom pain, we have seen, might be a mismatch between motor output and visual feedback from the arm. But what if one were to restore the visual feedback in response to the motor command? This would seem logically impossible but one could conceivably use virtual reality—monitoring motor commands to guide a virtual image of the hand seen through goggles. But at that time virtual reality



technology was cumbersome, sluggish and expensive so we decided to use a regular plane mirror.

## Mirror therapy

The 'mirror box' consists of a 2 × 2 foot mirror vertically propped up sagittally in the middle of a rectangular box (Fig. 3). The top and front sides of the box are removed. The patient then places (say) his paralysed left phantom on the left side of the mirror and the intact normal hand on its right. He then looks into the (shiny) right side of the mirror at the reflection of the intact right hand so that its reflection seems visually superimposed on the felt location of the phantom; thereby creating the illusion that the phantom has been resurrected. While still looking into the mirror if he sends motor commands to both hands to make symmetrical movements such as conducting an orchestra or opening and closing the hand, he gets the visual impression that his phantom hand is 'obeying' his command.

Our first patient was seen in 1993. He had a brachial avulsion in 1982, a year following which he had his left arm amputated above his elbow. For the 11 years following the amputation he had a vivid extended (i.e. not 'telescoped') phantom arm and hand that were excruciatingly painful on an almost continuous basis. He followed our instructions and remarked with considerable surprise that he could not only see his phantom moving but also feel it moving as well—for the first time in 11 years. Remarkably he also noted that the pain was instantly reduced and that it felt good to be able to control the phantom again. By having him repeat the procedure several times with his eyes closed or open we verified that the effect required visual feedback (Ramachandran *et al.*, 1995; Ramachandran and Hirstein, 1998; Ramachandran, 2005). Prompted by these findings other groups have explored different types of visual feedback (e.g. virtual reality technology, left/right reversing prisms) and shown them to be at least partially effective in ameliorating pain (see below.)

Would repeated practice with the mirror eventually lead to a reversal of learned paralysis so that DS could voluntarily move

the phantom without the mirror? He took the box home and continued the training sessions for 2 weeks; about 10 min each day. He reported that during the 2 weeks each time he followed the procedure the phantom moved temporarily and there was a striking reduction of pain. Another week later he noted, with surprise, that his phantom arm disappeared along with the pain in the elbow and forearm. The phantom fingers, however, were still present 'dangling from the shoulder' (i.e. telescoped) and they were still painful. This 'disappearance' of the phantom or its shrinkage probably results from the brain 'gating' conflicting sensory inputs and has also been seen in other recent studies (Flor *et al.*, 2006) which have elegantly combined the use of MVF with brain imaging studies. Similarly when a grotesquely 'enlarged' and painful phantom was viewed in a mirror box the phantom shrank instantly for the first time in years with associated 'shrinkage' of pain (Gawande, 2008). Even the chronic itch in the phantom vanished.

In the early days and weeks after amputation amputees often report that the phantom hand goes into an extremely painful clenching spasm; some of them feel their 'nails digging into the palm'. Such remarks are heard often enough—and independently from different patients—that they are unlikely to be confabulatory. We all have clenched our fists one time or another and have Hebbian memory associations between brain commands to clench fists and the sense of nails digging into palms. But since the receptors in our intact skin signal the absence of pain, we do not literally feel pain when we simply retrieve our clenching-fist (and associated nails-digging) memories. In the absence of feedback from the missing arm, however, these pain memories emerge to the surface of consciousness and are experienced literally in the phantom (Ramachandran and Hirstein, 1998). Furthermore, the absence of proprioceptive negative feedback may lead to pathological 'positive feedback' amplification of the motor commands which in turn may amplify associated Hebbian links—including pain memories.

We tried the mirror procedure on an additional six patients who had been amputated just a few weeks prior to our seeing them. When they had a clenching spasm, the pain usually lasted for several (e.g. 5–20) min. At the beginning of a spasm they viewed the reflection of their clenched intact hand in the mirror and sent motor commands to unclench both hands. In three of them the procedure resulted in immediate relief from spasm and associated pain, which was consistent across trials. Applying a self-controlled shock from a TENS unit (placebo) during the pain produced no pain reduction. The fact that a mere optical trick could reduce pain instantly was of considerable theoretical interest at the time when it was first reported.

Partly prompted by these studies, it was proposed by Harris (2000) that phantom pain is—at least in part—a response to the DISCREPANCY between different senses such as vision and proprioception. If so, perhaps MVF acts by restoring the congruence between motor output and sensory input.

Although Harris' theory makes good phylogenetic sense one potential objection might be that not EVERY discrepancy leads to pain. For example, visual/vestibular discrepancy—as during caloric nystagmus—can cause an aversive queasiness but not pain. So discrepancy cannot be the sole reason for pain.



Figure 3 The mirror box.

**Table 2 Clinical studies of mirror therapy**

|   |  |
|---|--|
| Ramachandran <i>et al.</i> (1995)       | Series of cases of mirror therapy for phantom limb pain and immobility in upper limb amputees.   |
| MacLachlan <i>et al.</i> (2004)         | Case study of mirror therapy for a lower limb amputee with phantom pain.   |
| Chan <i>et al.</i> (2007)               | Randomized controlled trial of mirror therapy for phantom limb pain.   |
| Sumitani <i>et al.</i> (2008)           | Series of cases examining the effect of mirror visual feedback on qualitative aspects of pain patients with phantom limb pain after amputation, brachial plexus or other nerve injury. |
| Darnall (2009)                          | Case study of mirror therapy for phantom limb pain.  |
| Altschuler <i>et al.</i> (1999)         | Pilot study of mirror therapy for hemiparesis following stroke.  |
| Sathian <i>et al.</i> (2000)            | Case study of mirror therapy in a patient with hemiparesis and sensory loss following stroke.  |
| Stevens and Stoykov (2003)              | Two case studies of mirror therapy for patients with hemiparesis following stroke.   |
| Stevens and Stoykov (2004)              | Case study of mirror therapy in hemiparesis following stroke.  |
| Sütbeyaz <i>et al.</i> (2007)           | Randomized controlled trial of mirror therapy for lower extremity hemiparesis following stroke.  |
| Yavuzer <i>et al.</i> (2008)            | Randomized controlled trial of mirror therapy for upper extremity hemiparesis following stroke.  |
| McCabe <i>et al.</i> (2003b)            | Controlled pilot study of mirror therapy for CRPS.   |
| Karmarkar and Lieberman (2006)          | Case study of mirror therapy for pain in CRPS.   |
| Vladimir Tichelaar <i>et al.</i> (2007) | Case studies of mirror therapy for CRPS.   |
| Selles <i>et al.</i> (2008)             | Case studies of mirror therapy for CRPS.   |
| Sumitani <i>et al.</i> (2008)           | Series of cases examining the effect of mirror visual feedback on qualitative aspects of pain patients with phantom limb pain after amputation, brachial plexus or other nerve injury. |
| Rosén and Lundborg (2005)               | Mirror therapy for hand surgery patients with nerve injuries.  |
| Altschuler and Hu (2008)                | Mirror therapy for patient after a wrist fracture with good passive, but no active range of motion.  |

(This is to be expected of course; after all some pain is caused simply by c-fiber activation.) But it may none the less be an important contributing factor.

There is another way in which the mirror might act. Ordinarily the patient feels intense pain in an arm he cannot see (his phantom). Since nothing is seen or felt other than the pain, there is nothing directly CONTRADICTING it. After all the visceral pain of internal organs is only vaguely localizable, yet can be felt intensely. (Of course, the patient recognizes at a higher intellectual level that the pain cannot be real but that does not reduce the pain; the pain mechanisms are partially immune from intellectual correction.) When the patient looks at the visual reflection of the real hand, however, he sees that there is no external object CAUSING the pain in the optically resurrected phantom, so his brain rejects the pain signal as spurious; it is a matter of how different signals are weighted and integrated—or gate each other—in the construction of body image and attribution of pain. This hypothesis would predict that the mere act of seeing the mirror image—even without seeing it move—might provide partial relief. We have seen hints of this but not studied it formally.

The striking beneficial effects of MVF on phantom pain has now been confirmed in several studies (e.g. MacLachlan *et al.*, 2004; Chan *et al.*, 2007; Sumitani *et al.*, 2008; Darnall, 2009) (Table 2). The most recent thorough demonstration was by Tsao and colleagues (Chan *et al.*, 2007) who tested MVF on 22 patients, 18 completing their study: six initially treated with mirror therapy, six who were instructed to watch a covered mirror and six who were trained in visual imagery. After 4 weeks, the mean visual-analogue scale (VAS) pain rating fell from approximately 30/100 initially to 5/100 in the mirror therapy group, remained at about 30/100 for the covered mirror group ( $P=0.04$  compared with mirror therapy group), and actually rose from about 40/100 to 60/100 in the visual imagery group ( $P=0.002$  compared with

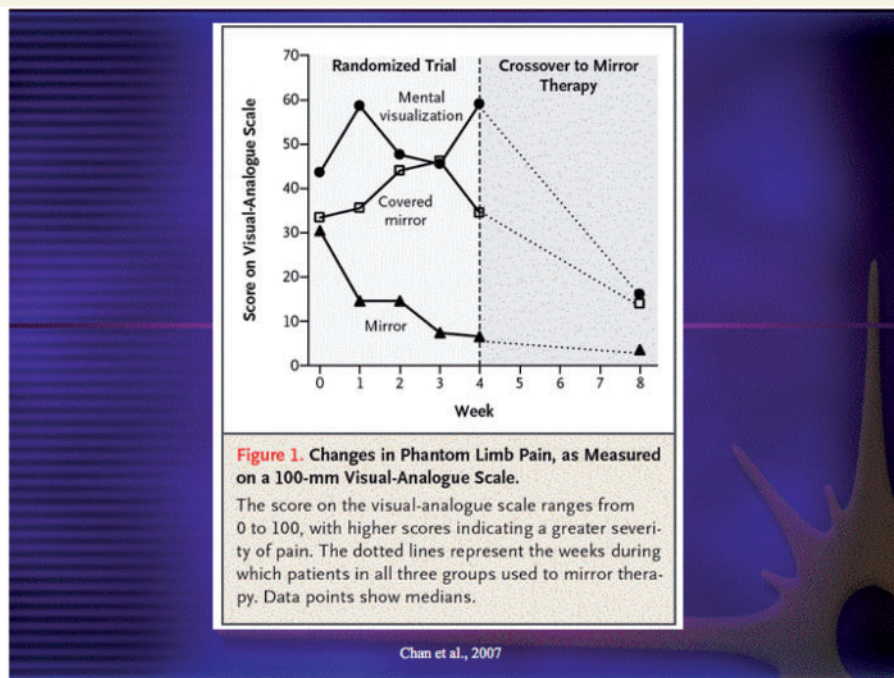
mirror therapy group). Nine subjects from the covered mirror and visual imagery groups then crossed over to mirror therapy with a mean 75% reduction in pain ( $P=.008$  for VAS score after 4 weeks on mirror therapy compared with prior 4 weeks on covered mirror therapy or visual imagery). See Fig. 4.

The alleviation of phantom pain with MVF has also been studied using brain imaging showing that the degree of phantom pain correlates well with the degree of maladaptive reorganization of somatosensory pathways (Flor *et al.*, 1995), and that the reorganization is partially reversed by MVF with corresponding reduction of pain (Flor *et al.*, 2006). This suggests that the mirror might produce its effects at least partially by influencing long-term cortical reorganization of brain maps.

Yet, this cannot be the sole mechanism because, as we have seen, MVF sometimes acts virtually immediately—if only temporarily—to eliminate pain as when the patient has a clenching spasm and views the reflection of his normal hand opening and closing. A similar modulation of pain is also seen when the patient merely watches the experimenter massaging a third person's intact hand (see Mirror neurons and phantom limbs section). Such effects suggest that, in addition to its long term benefits, visual feedback can powerfully modulate current on-going pain in a limb.

## Visual modulation of pain in normal individuals

The notion that powerful intersensory interactions can occur had already been evident from the work of Gestalt psychologists from the early 20th century. A particularly compelling example was discovered by the pioneering experimental psychologist Rock and Victor (1964). They found that vision dominates touch and proprioception; if an object was made to merely LOOK large using



**Figure 4** Beneficial effect of mirror therapy in phantom pain (from Chan et al., 2007).

a lens, while it was being palpated, it also FELT large. Rock coined the phrase 'visual capture' to describe the phenomenon. Such 'capture' occurs when integrating information from different senses because the brain assigns different weights to different sensory inputs depending on their statistical reliability. Vision in most cases dominates touch (Gibson, 1962).

Evidence of objective skin changes caused by a purely visual input was provided by Armel and Ramachandran (2003) who took advantage of a striking illusion originally discovered by Botvinick and Cohen (1998). A rubber right hand is placed on a table in front of a student. A partition separates the rubber hand from her real right hand which is hidden from view, being behind the partition. Her left hand is left dangling from her side. As the subject intently watches the rubber hand the experimenter—using his left hand—repeatedly taps, jabs and strokes it in random sequence—and randomly chosen directions. He also simultaneously uses his right hand to tap, jab and stroke her real right hand—that is hidden from view—in perfect synchrony. After several seconds, the subject remarks (often without prompting and with considerable astonishment) that the tactile sensations are being felt on the rubber hand instead of the hidden real hand. This is because the brain—especially sensory systems—is essentially a machine that has evolved to detect statistical correlations in the world. 'it' says, in effect, 'What's the likelihood that the exact sequence of strokes and taps is being simultaneously seen on the dummy and FELT in the real hand?' Zero. Therefore, the sensations must be emerging from the dummy. (The effect is not, in principle, different from ventriloquism where the precise synchrony of the dummy's lip movements and the vocalizations of a real person (hidden from view at a distance) are misattributed to the dummy.)

But can this perceptual misattribution of sensations to the dummy hand actually lead to physiological changes? Armel and Ramachandran (2003) measured the SCR (skin conductance response; an objective index of limbic/autonomic arousal that cannot be 'faked') to answer this question. They found that when they suddenly hyperextended or viciously poked the dummy hand after the subject had 'identified' with it, there was a clearly measurable decrease in SCR in the real hand caused by increased sweating resulting from autonomic arousal. Apparently the dummy hand not only has sensations referred to it but also it is now assimilated into the subject's limbic system so a visually perceived 'pain' in the dummy causes physiological changes in the subject. This was the first demonstration that physical changes—skin vascularization and sweating—can be modulated by visual input delivered to an external object that is temporarily incorporated into one's body image.

A number of other studies have also provided compelling evidence of such interactions:

- (i) McCabe *et al.* (2005) have shown, in normal subjects, that if you view the reflection of your (say) right hand superposed on the felt location of the hidden left hand, then moving the right hand can result in the perception of a tingling sensation, discomfort, and sometimes even pain, in the left with the greatest sensory anomalies occurring when the two hands moved asynchronously.
- (ii) The fact that visual feedback can also modulate temperature in a hand has recently been demonstrated in an ingenious study by Moseley *et al.* (2008a) who also took advantage of the rubber hand effect. After the subject had started projecting the tactile sensations to the dummy



(right) hand, the temperature of the real hand actually became lower.

- (iii) The important role of the convergence of different signals on to a complex 'neuromatrix' in the construction of body image has also long been emphasized by Melzack (1992).
- (iv) Studies by Holmes, Spence and colleagues (Holmes and Spence, 2005; Holmes *et al.*, 2004, 2006) using MVF in normal subjects have shown that seeing the reflection of a limb can profoundly alter the sensed position and the perceived location of other sensations in the contralateral limb. Furthermore, we have noticed that optically induced 'shrinking' of the image of one's hand even leads to a curious alienation or disembodiment of the limb—as though it does not belong to you (see Ramachandran and Altschuler in Ramachandran and Rogers-Ramachandran, 2007). We find the effect is especially pronounced when you see your fingers wiggling because of the mismatch between motor commands and extent of observed finger movements.
- (v) Another remarkable observation deserves mention. Using an optical system that uses a parasagittal mirror combined with a minimizing lens we created the visual impression in a patient that his painful phantom arm had shrunk. This caused an immediate shrinkage of pain from 8 to 2. No increase in pain was seen with a magnifying lens, strongly suggesting that these are not merely the effect of suggestion. It was as though the felt size was 'captured' by visual size and this in turn caused the pain to shrink as well.

On the face of it this seems absurd but if proprioception (conveying felt size through muscle spindles and tendons) can be captured by visual size—as originally shown by Rock in normal people—then why is it any more surprising that pain should be captured as well? Here, then, is yet another example of a rather esoteric visual phenomenon (visual capture) being used to reduce pain in a clinical context.

A similar observation was made by Gawande (2008). He describes a patient who had a phantom arm that was painfully 'swollen'—being felt as much larger than a normal arm. When the patient looked at the reflection of his normal hand superposed optically (using the mirror) on his phantom, the phantom shrank instantly and the pain and itch shrank correspondingly. No lens was required because the phantom itself was 'swollen.'

- (vi) We have used (Altschuler and Ramachandran, 2007) two very large standing mirrors facing each other to create a discrepancy between vision and proprioception of the whole body. This creates the feeling that one is standing outside oneself. Two other groups have found similar effects using virtual reality set ups (Ehrsson, 2007; Lenggenhager *et al.*, 2007). Effects are variable and seen in about three out of four subjects.

Taken collectively, these findings add to the growing body of evidence that the senses interact much more powerfully than anyone imagined and that visual input, whether conveyed through the use of mirrors or dummy hands, can be used to modulate somatic pain.

## Mirror therapy in stroke rehabilitation

The paralysis that follows stroke is thought to result mainly from 'irreversible' damage to the internal capsule. It is possible, however, that during the first few days or weeks there is swelling and edema of white matter that results in a temporary interruption of corticofugal signals, leaving behind a form of learned paralysis even after the swelling and edema subsides. This might be analogous to the 'learned paralysis' that is seen in phantom limbs. Based on this reasoning, we suggested that MVF might accelerate recovery from hemiparesis following stroke (Ramachandran, 1994).

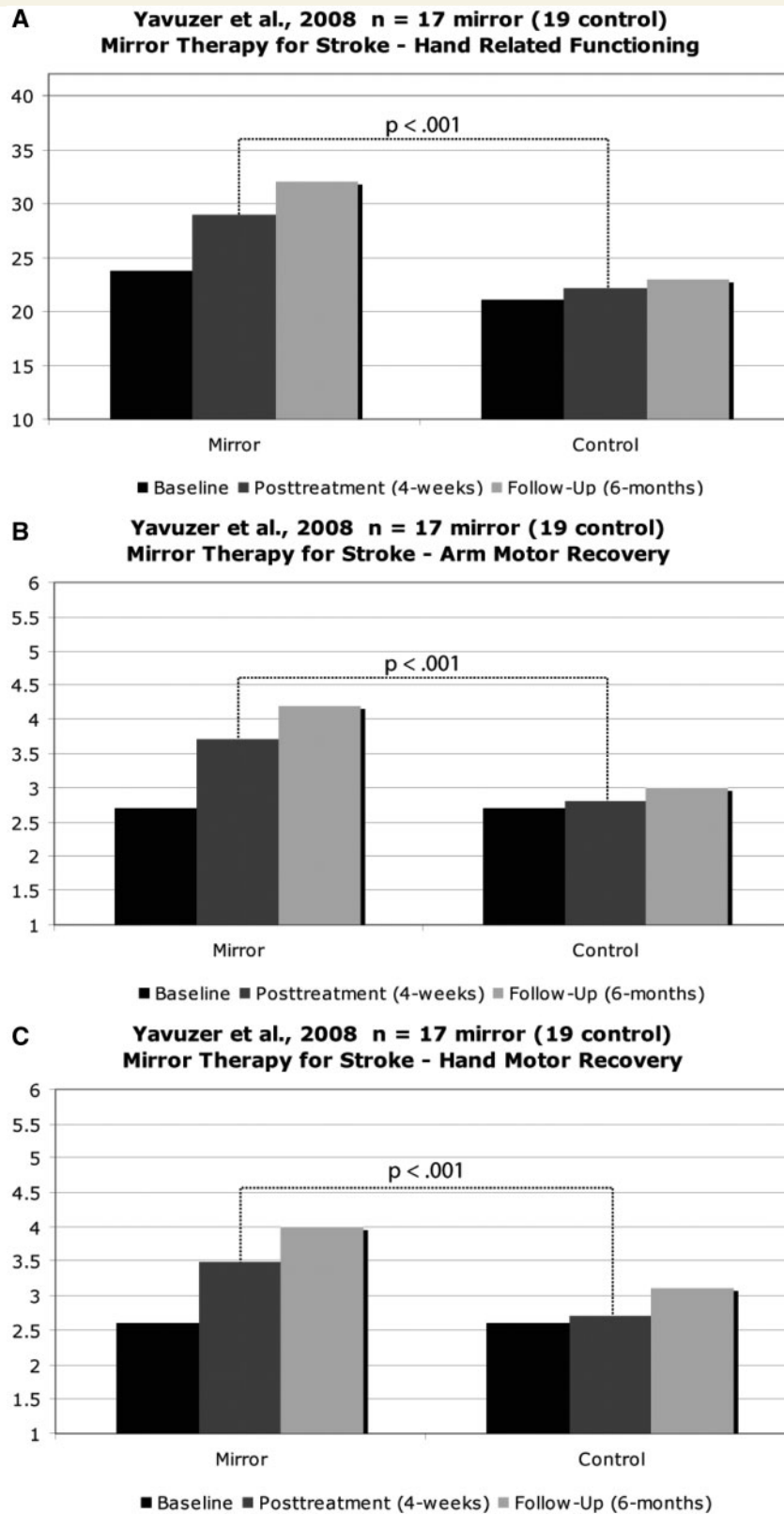
We conducted a placebo-controlled pilot study (Altschuler *et al.*, 1999) along these lines in nine patients. Moderate recovery of function was seen in three patients, mild in three, and almost none in three. Based on these preliminary findings, we suggested that MVF may provide a useful adjunct therapy for paralysis from stroke.

Subsequently, a number of case reports and series (Sathian *et al.*, 2000; Stevens and Stoykov, 2003, 2004) found benefit of mirror therapy in hemiparesis following stroke. Recently, two randomized-controlled trials of mirror therapy have found significant improvement from hemiparesis: A study of 40 patients with lower extremity hemiparesis (Sütbeyaz *et al.*, 2007) were enrolled up to 12 months post-stroke. They were randomly assigned to mirror therapy or a control therapy in which they moved both legs with the legs separated by an opaque partition. All subjects also received conventional physical therapy. Subjects in the mirror therapy group showed statistically significant improvement in Brunnstrom stages and FIM motor scores compared with subjects in the control group. No significant difference was found in the modified Ashworth scale or the functional ambulation categories. However, this was a study that trained subjects only on movements at single joints, not ambulation. In a subsequent study 40 patients with upper extremity hemiparesis (Yavuzer *et al.*, 2008) up to 12 months post-stroke were randomly assigned to mirror therapy or a sham therapy moving both hands and arms but with an opaque partition between the arms. All subjects also received conventional physical therapy. The subjects in the mirror therapy group showed statistically significant improvement in Brunnstrom stage and FIM self-care score over subjects in the control group (Fig. 5).

Another recent randomized, controlled, cross-over study (Matsuo *et al.*, 2008) of 15 sub-acute patients with hemiparesis following stroke found mirror therapy superior to control treatment, the outcome measure being the Fugel–Meyer assessment scale of the paretic arm.

These results indicate that many patients show substantial recovery of function using MVF. But the variability suggests that the procedure may help some patients more than others. This variability may depend in part on the exact location of the lesion and duration of paralysis following stroke. Once these variables have been understood, it might be possible to administer MVF to those patients who are likely to benefit most. (Although, given the simplicity of the procedure, there is no reason why it should not be implemented routinely as adjuvant therapy.)





**Figure 5** (A) Functional independence measure (FIM) self-care score (adapted from Yavuzer et al., 2008). (B) Brunnstrom stage (upper extremity). (C) Brunnstrom stage (hand).

In addition to these blind placebo-controlled studies there have been a number of clinical case studies reporting striking recovery from stroke (Sathian *et al.*, 2000) from phantom pain (MacLachlan *et al.*, 2004) and from reflex sympathetic dystrophy (RSD) (Karmarkar and Lieberman, 2006; Vladimir Tichelaar *et al.*, 2007; Selles *et al.*, 2008). The results of these studies strongly support the idea that visual feedback can modulate pain and even reverse more objective signs such as inflammation and paralysis. These studies complement the results of more controlled trials. They are, in some ways, just as significant because each such patient serves as his own control, having gone through intense regimens of conventional rehab, 'alternative medicine,' drugs such as morphine and even drastic surgical procedures to no avail. (So there is a sense in which the placebo 'controls' for these patients was all the other neurorehabilitation they have been through.) It is also noteworthy that some of the studies also included measurements of physical changes such as skin temperature that would be impossible to confabulate. Especially important, in this regard, is the McCabe *et al.* study conducted in collaboration with Patrick Wall (McCabe *et al.*, 2003b; see below) showing change in the skin temperature of the dystrophic arm produced by MVF over the course of the 6 week study period.

## Neural mechanism of MVF

We have already discussed the manner in which restoring congruence between vision and motor output can lead to an unlearning of learned paralysis in stroke patients.

Another explanation can also be invoked that takes advantage of the discovery of mirror neurons by Rizzolatti and his colleagues in the early 1990s (di Pellegrino *et al.*, 1992).

Such neurons are found in the frontal lobes as well as the parietal lobes. These areas are rich in motor command neurons each of which fires to orchestrate a sequence of muscle twitches to produce simple skilled movement such as (if you are a monkey) reaching for a peanut or pushing a stone or putting an apple in your mouth. Remarkably, a subset of these neurons—'mirror neurons'—also fire when the monkey (or person) merely WATCHES another individual perform the same movement. They allow you to 'put yourself' in the other's shoes—viewing the world from the other's perspective—not just physical but mental perspective—in order to infer his IMPENDING action.

Mirror neurons necessarily involve interactions between multiple modalities—vision, motor commands, proprioception—which suggest that they might be involved in the efficacy of MVF in stroke.

Stroke paralysis results partly from actual 'permanent' damage to the internal capsule but also—as we have seen—from a form of 'learned' paralysis that can be potentially unlearned using a mirror. An additional possibility is that lesion is not always complete; there may be a residue of mirror neurons that have survived but are 'dormant' or whose activity is inhibited and does not reach threshold. (And, indeed, motor areas may have become temporarily inactive as a result of the same mechanism as learned paralysis—a failure of visual feedback to close the loop.) If so one could postulate that MVF might owe part of its efficacy to stimulating these neurons, thus providing the visual input to revive 'motor' neurons.

This hypothesis also receives confirmation from Buccino and colleagues (Ertelt *et al.*, 2007) who followed up our work on stroke recovery using MVF, except they had patients watch videos of movements performed by healthy individuals presented via a screen in frontal view, and then have the subjects try to use their paretic arm to make similar movements. This method of therapy was found in a small trial to be superior to a control group of subjects who received conventional physical therapy and watched videos of geometric symbols. Many groups have also employed virtual reality technology to create the visual feedback—instead of using mirrors (see, e.g. Eng *et al.*, 2007). However, there have not been large clinical studies of virtual reality. Such procedures have the potential advantage that they can be used for BILATERAL stroke patients or amputees for whom the mirror would be useless (though a patient with a bilateral amputation or with bilateral hemiparesis following stroke(s) could move one arm while watching the reflection of the arm of a therapist or family member in the mirror). Also, studies using virtual reality observation of playback of the mirror reflection of the good arm or leg recorded offline could help in parsing out contribution of movement of the contralateral limb. But virtual reality systems have the disadvantage of currently being very expensive and therefore not amenable to self-administration at home. In addition, it is still not clear, and worthy of future study, the extent to which the realistic image provided by a mirror needs to be replicated by virtual reality technology, and also the ability of a virtual reality system to mimic the relative speeds of movement of the normal and the affected limb implicitly generated by a subject using a mirror.

## Recruitment of ipsilateral pathways using mirrors

In addition to the corticospinal tracts that project contralaterally from motor cortex there are some ipsilateral projections. For instance, the right motor cortex sends its efferents not only to the left side of the spinal cord as most medical students are taught but also to the IPSILATERAL spinal cord. Five questions arise: Are these pathways excitatory or inhibitory? Are they functional or vestigial remnants of an ancient uncrossed pathway? When commands are sent to the contralateral body side why do not any commands go simultaneously to the ipsilateral muscles so you get irrepressible ipsilateral movements 'mirroring' those in the left? And last, if the right hemisphere output to the left side of the spinal cord and body is damaged by stroke then why cannot the IPSILATERAL projection from the left hemisphere to the left spinal cord 'take over' and move the 'paralysed' limb?

None of these questions has been answered to satisfaction but clearly a more thorough investigation may allow us to take advantage of these connections in a clinical setting. Perhaps visual feedback acts, in part, by reviving these dormant ipsilateral connections. Indeed, Davare *et al.* (2007), and Schwerin *et al.* (2008) have shown using transcranial magnetic stimulation (TMS) that ipsilateral projections have a non-trivial role even in normal subjects. It might be interesting to see if the degree to which

ipsilateral activation (through TMS) occurs varies with the degree of recovery using MVF.

## Mirror neurons and phantom limbs

Just as mirror neurons exist for motor commands there are 'pain' mirror neurons in the anterior cingulate that fire when you are hurt with a needle or when you merely watch someone else being hurt. One wonders whether such neurons are involved in such phenomena as 'empathy'.

Touch receptors from your skin send signals which—after relay in the thalamus (a fist-sized structure in the center of the brain)—project to somatosensory cortex (S1) and eventually to the superior parietal lobule where different signals are combined. This generates your sense of a coherent body image that endures through time and space. Intriguingly, many of these—the 'touch mirror neurons'—fire not only when you are being touched but also when you watch someone being touched (Keysers C *et al.*, 2004). But if so, how do they know the difference? Why do you not literally feel touch sensations when merely watching someone being touched, given that your mirror neurons are firing away?

One answer might be that when you watch someone touched, even though your 'touch mirror neurons' are activated the receptors in your skin are NOT stimulated and this LACK of activity (the 'null signal') informs your regular garden variety touch neurons (i.e. non-mirror touch neurons) that your hand is NOT being touched. They in turn partially veto the output of mirror touch neurons at some later stage so you do not actually experience touch sensations; you merely empathize. We emphasize that the output from intact (non-touched) skin would only inhibit ONE of the outputs of the mirror neuron system—the one which leads to conscious appreciation of touch quale. If it inhibited the mirror neurons themselves it would defeat the purpose of having mirror neurons in the first place.

To test these ideas, we (Ramachandran and Rogers-Ramachandran, 2008) asked a patient with a phantom arm to simply watch a student being touched on her arm. As we briefly noted earlier, the patient volunteered that he could actually FEEL the touch signals on corresponding locations in his phantom and he seemed amazed by this. The amputation had removed null signal from the skin causing his mirror neuron output to be experienced directly as conscious touch sensations. Indeed massaging the student's arm produced pain relief in his phantom.

These effects—feeling touch stimuli delivered to another person—were replicated in three patients. The effect is unlikely to be confabulatory—for four reasons: first, no sensations were ever felt in the non-amputated intact arm. Second, the patients expressed considerable surprise. Third, there was a latency of several seconds before the effect emerges and one would not expect a long latency for confabulation. (The latency was consistently seen across all three subjects.) Fourth, when the patient watched the student being stroked with a piece of ice, the touch alone was referred for the first half a minute or so followed by referral of cold. (The cold referral was noted only by one of the three patients.) This uncoupling of modalities would also not be expected if confabulation or response bias were involved. We would suggest that the longer latency

(or indeed, failure) of temperature referral is because the Hebbian links for associating ice with cold is not as strong as between vision and touch—the latter association having been seen much more often. (Or one could say there are fewer 'mirror neurons' for temperature than for touch.)

The reduction of pain through watching the student being massaged, however, was demonstrated only in one subject—so this needs confirmation in a formal placebo-controlled study.

In one experiment we had the patient watch a student suddenly prick his own intact palm with a sharp needle and pretend to wince in pain. The patient shouted in pain, and reflexively 'pulled' his phantom away claiming he had felt a nasty twinge of pain. He was quite astonished by this as were several residents who were watching the procedure.

The important lesson is that feeling 'touch' or 'pain' involves far more than sensing the activation of touch or pain receptors from your hand; it results from complex neural networks from different sense modalities interacting with each other and—indeed—with other brains! The properties of these intricate, yet decipherable, networks can be studied by experimenting on neurological patients and can be exploited clinically for reducing pain.

## Functional imaging and TMS with mirrors

Functional imaging studies of patients who have had mirror therapy are still on-going (see, e.g. [www.clinicaltrials.gov](http://www.clinicaltrials.gov) NCT00662415).

We have already mentioned Flor's imaging studies demonstrating the striking effects of MVF and correlating the degree of reorganization with the degree of pain reduction. Space limitations do not allow us to review all experiments in the fields but two others deserve special mention.

In an interesting study in normal subjects Garry *et al.* (2005) used TMS to look at excitability of the motor cortex ipsilateral to a moving hand. They studied four conditions: (i) subjects watching the hand they were moving; (ii) subjects watching their inactive hand; (iii) subjects watching a marked position between the moving and inactive hand; and (iv) subjects watching the reflection of the moving hand in a plane reflecting mirror. They found a significant increase in motor cortex excitability in the mirror viewing condition compared with the other conditions consistent with the mirror reflection exciting the motor cortex corresponding to the reflection of the moving hand.

A somewhat different experiment to explore the effects of MVF was conducted on normal subjects by Frackowiak and colleagues (Fink *et al.*, 1999) using PET imaging. They had subjects looking into the mirror box while performing symmetric motions of the two arms (condition 1; the concordant condition) or DISSIMILAR movements so that the visual reflections contradicted both proprioception and motor commands (condition 2; discordant condition). The prefrontal and motor cortex lit up in both hemispheres in the concordant condition but the main effect of the discordant condition was greater activity in the right dorsolateral prefrontal cortex. This observation points to hemisphere asymmetries during MVF and may have implications for treatment.



## Complex regional pain syndrome—previously known as reflex sympathetic dystrophy

Another enigmatic pain syndrome that has long been considered intractable is complex regional pain syndrome (CRPS). The syndrome was first described by the Philadelphia physician Mitchell who described phantom limbs (Mitchell, 1864, 1872), who, incidentally, was also the first to describe pseudocyesis or phantom pregnancy. Also, most interestingly, Mitchell's father, the physician John Kearsley Mitchell (1798–1858) was the first to describe (1831) the denervation-induced destruction of joints in patients who had spinal cord damage secondary to tuberculosis. (This condition is known today as a 'Charcot joint.' Charcot (1868) described a similar conditions in patients with tertiary syphilis.) The role of the nervous system in musculoskeletal pathology may have been a frequent topic of dinner conversation at the Mitchell household.

The hallmark of the disorder (CRPS) is the persistence—indeed progressive increase—in pain, swelling and inflammation in a limb long after the inciting injury has gone, despite the trivial nature of the original injury and despite the absence of any current infection or tissue damage.

For example, the patient may initially have had a hairline fracture of a metacarpal or even a sprain with accompanying swelling, pain and temperature changes. Ordinarily these changes would subside and disappear altogether as soon as the metacarpal fracture has healed, say in a few weeks (or longer if extensive orthopaedic or neurosurgical operations were necessary). But in a minority of patients the pain and inflammation persist with a vengeance for years—long after the original inciting injury has gone. This usually results in an immobilization or paralysis of the limb partly because any attempt to move it causes excruciating pain. Even light touch applied to the limb is felt as unbearable pain (dysesthesia) and, most remarkably, there is actual atrophy of bone possibly from disuse and 'top down' trophic effects (Sudek's atrophy). CRPS therefore provides a valuable probe for exploring mind–body interactions.

An evolutionary approach to CRPS may help us better understand the disorder and lead to novel treatments. The word 'pain' encompasses at least two very different categories—acute and chronic—which, in our view, may have fundamentally different evolutionary origins and functional consequences. The first—as happens when you touch a hot plate—results in movement or MOBILIZATION of the limb away from the source of pain to avoid injury. The latter results in IMMOBILIZATION of the limb to protect it from further injury (e.g. as in a fracture). Of course this immobilization usually gets reversed when the chronic inflammation/infection subsides but if the mechanism goes awry you get stuck with the painful immobilization. In particular, during the original inflammation, any ATTEMPT to move the arm would cause severe pain so that in time the corollary discharge from

these very attempts get linked in a Hebbian manner to the pain. Subsequently, every signal that gets sent even 'accidentally' to the limb evokes and amplifies the associated memories even though the inflammation itself is no longer there—a phenomenon we have dubbed 'learned pain'. Based on this reasoning we suggested the use of MVF to convey the visual illusion to the patient that his 'painful' arm was moving (painlessly) in response to motor commands thereby resulting in an 'unlearning' of the learned pain and learned immobilization.

## Studies of mirror therapy in CRPS

A number of small studies and case reports have found mirror therapy of benefit in patients with complex regional pain syndrome/reflex sympathetic dystrophy (McCabe *et al.*, 2003b; Karmarkar and Lieberman, 2006; Vladimir Tichelaar *et al.*, 2007; Selles *et al.*, 2008).

The most convincing of these is a placebo-covered mirror-controlled study by McCabe *et al.* (2003b). Significantly, patients with recent (8 weeks or less) onset of CRPS showed significant benefit from mirror therapy—but not from control therapies—while subjects with chronic CRPS (one year or greater) did not show benefit from mirror therapy.

As noted earlier, a surprising aspect of the McCabe study was that they demonstrated that the perceived pain reduction from the visual feedback actually caused changes in objectively measured skin temperature in the affected limb. Such temperature changes cannot be 'faked' and is, as far as we know, the first evidence that objectively measurable physiological changes in a limb can be caused by visual feedback.

If the experiments of McCabe *et al.* and the cases described in Gawande hold up, they would have tremendous impact on the way we think about central pain and mind–body interactions; elevating such phenomena from the obfuscations of 'alternative medicine' to the realm of empirical science.

## MVF-aided visual imagery and phantom pain

Thanks in part to the AI movement in vision it used to be thought all sensory processing happens in a hierarchic manner with early sensory modules computing more primitive stimulus features such as (in the case of vision) colour, motion, orientation of edges, motion direction, etc. and (in the case of somatic sensations, touch, pain, temperature pressure, etc.) and delivering the results of these computations through successive stages to higher levels of processing. This has been caricatured by us as the 'serial hierarchical bucket-brigade—model of perception' (Churchland *et al.*, 1994). It has long been known, however, that there are as many feedback projections going from level to level DOWN the hierarchy as up. It is possible that these reverse pathways are somehow involved in phenomena such as the visual imagery we can all engage in even without an external stimulus. The memories of (say) a previously seen image of a rose are sent back to

reactivate early sensory levels. This ensures that what you have is not merely an abstract conception of a rose stored as neural equations but 'real' visual rose full of tactile, olfactory and visual qualia; a 'sensory' representation of the rose that you can use as an explicit token for language and other forthcoming behavioural rehearsals. Indeed, consistent with non-hierarchical sensory processing, a recent study (Valentini *et al.*, 2008) in stroke patients with hemihypaesthesia found that in group measures sensation detection, localization and intensity detection was superior with touch by a patient's unaffected hand compared with an examiner's hand.

Indeed there is a wealth of experimental evidence that when you imagine something, partial activation of the very same neural pathways occurs as would be evoked by a real external stimulus; as if your brain is doing a virtual reality simulation (Kosslyn *et al.*, 1983). So when you visualize your arm moving (whether it is a normal intact arm, a paralysed one or even just a phantom) then some of the same neural circuits would be activated as are activated by a mirror.

If this line of reasoning is correct then one should be able to use intense—and highly rehearsed—visual imagery to pretend that the painful phantom—or paralysed arm (in CRPS/RSD or stroke) is moving and that, in turn, should help relieve pain and/or paralysis (the only limit being how powerful the patients imagery is and to what extent it stimulates populations of neurons that are ordinarily activated by a direct visual stimulus). Stimulated by our work with mirrors three other groups have tried visual imagery in combination with MVF. Oakley *et al.* (2002) found hypnotically induced imagery of MVF beneficial for phantom limb pain. Moseley (2006) found that beginning subjects with limb laterality training, next imagined movements, then MVF was beneficial in terms of decreasing pain in patients with phantom pain or pain from CRPS. Another study also demonstrated that 'motor imagery/visualization training' and MVF are both more effective than conventional rehab in patients with phantom pain (MacIver *et al.*, 2008). These studies suggests that 'virtual' visual feedback conveyed through imagery may partially mimic the effects of real visual feedback conveyed through mirrors or virtual reality (presumably by recruiting and exploiting the same neural mechanisms).

As previously noted, Tsao and colleagues (Chan *et al.*, 2007) directly compared eight phantom limb patients using imagery (which they used as a placebo) with eight receiving MVF and found that while all patients in the latter group showed a striking reduction in phantom pain within 2 weeks, the imagery group did not (see Phantom limbs section); indeed there was a slight increase in pain. Even more convincingly, when the visual imagery group was crossed over to the mirror they showed the same pain decrement from about 8 (on a scale of 10) to about 2 or 3.

Taken collectively, these studies confirm the important role of visual feedback in neuro-rehabilitation—whether conveyed through mirrors, lenses, visualization training assisted by MVF or by virtual reality technology. What combination of these treatments works best for different patients remains to be explored.

## Use of mirrors in rehabilitation from hand surgery

Rosén and Lundborg (2005) recently described three patients who benefited from mirror therapy. The first patient had poor active flexion of the hand after irrigation and debridement of an infected cat bite. The second had rheumatoid arthritis and had had multiple tendon transfers. Both failed initial traditional hand therapy. After initiating mirror therapy—flexing fingers on both hands, the affected hand as much as possible, while watching the reflection of the good (non-injured) hand—both patients improved considerably in both active range of motion and strength. The patient touched stationary and moving objects with both hands while watching the reflection of the good hand in a parasagittal mirror. Vision of the reflection of the good hand allowed the patient to actually begin touching objects with the affected hand. Training was also apparently able to override the aberrant sensory input from the injured hand to the point where the paraesthesias subsided and were no longer either disabling or troubling.

We have recently observed similar effects of mirror therapy on one patient (Altschuler and Hu, 2008) who had sustained a fracture in February of 2006, in her left distal radius with no tendon or neurovascular involvement. She was treated with closed reduction and casting, but after 2 months needed open reduction with internal fixation and bone graft for non-union of the fracture. Once the final cast was removed in May, 2006 she presented with severe stiffness and pain in the wrist; her active and passive wrist extension and supination were zero degrees. This could have been a form of 'learned paralysis.' Despite being right-handed, she said that inability to use her left arm had greatly hindered her ability to take care of her house and children. After about a week of 'conventional' treatment, passive extension had increased to 20°, but she was unable to actively extend the wrist at all. To facilitate active wrist extension, neuromuscular electrical stimulation was begun on her wrist extensors. After about 1 week, the patient was able to extend the wrist actively during electrical stimulation, but not afterwards. We started her on MVF in early June, 2006. She had 15 min of mirror therapy with electrical stimulation simultaneously applied to the wrist extensors two to three times each week as an outpatient. She also began a home program of mirror therapy—15 min twice daily (of course without stimulation). Her active wrist extension increased to 25° by early July, 2006. She continued mirror therapy until mid-July (a total of 5 weeks), by which time her wrist extension was 30° actively. She was discharged from treatment in mid-August with active wrist extension of 35° and supination of 80°. She was pleased with this physiologic outcome and reported an essentially normal ability to do all activities of home and childcare.

Four other clinical cases observed by us informally deserve mention:

(i) The first patient had a trigger finger. She felt that opening and closing both fists, while watching the reflection of the hand without the trigger finger produced improved movements in

the trigger finger. This anecdotal observation might be worth following up;

(ii) The second patient (K.S.) had focal dystonia (writers cramp) in his right hand, which had started four years prior to our seeing him. He was keen on trying to use the mirror, having seen reports of it in the media. We tried coaching on this and had him come to our facility three 1-h sessions a week for 2 months. The MVF had no effect whatsoever. But this should not discourage other researchers from trying the treatment since the outcome may depend on the duration for which the focal dystonia had been present prior to treatment;

(iii) The third patient had—judging from her history—a form of Jacksonian seizures that started in her hand, progressing proximally to the upper arm and eventually involving the trunk (although it did not culminate in grand mal). Since no formal clinical evaluations were done we have to bear in mind the possibility that her condition was purely ‘psychogenic’ in origin. Whatever the pathogenesis, she was able to use MVF. When the tremors/seizures began in her left arm she looked at the reflection of her normal hand to convey the illusion that the affected arm was still. This seemed to instantly abolish the seizure. The observation reminded us of the ‘trick’ invented in the early days of neurology using powerful smells to ‘mask’ the hallucinatory smell auras that precede TLE seizures, thereby aborting the seizure; and

(iv) Even more surprisingly, we recently encountered a patient who could treat the intense left hemi-facial pain of trigeminal neuralgia using MVF (<http://anadmiracle.blogspot.com/>). He had been suffering from the disorder for nearly 12 years and had gone through several conventional treatments which proved to be completely ineffective (as is often the case). He opted not to have invasive neurosurgery and, following a suggestion from one of us (VSR), looked at his face in a double reflecting mirror. Unlike a normal mirror a double-reflecting mirror (two mirrors taped at right angles) does NOT optically reverse your face. So, if you look in the mirror and someone touches the actual RIGHT side of your face it creates the illusion that the LEFT side of your face is being touched (because the normal ‘expected’ reversal does not occur). The patient made ingenious use of the technique. Obviously he could not massage the left side of the face; the very attempt to get close to it or actually touching it lightly provoked excruciating pain. Presumably years of Hebbian association had established a link between the REAL pain and light touch (as well as vision). He looked in the mirror and watched his wife’s hand massaging his right face so he SAW his left (painful) side being ‘massaged’ without provoking pain; progressively so that the ‘learned pain’ could be unlearned. Astonishingly the pain dropped from about 6 down to 0 after 10 min and with repeated 10 min treatments stayed at zero for months. Massage applied to the right face WITHOUT looking in a mirror was completely ineffective. It would be premature to regard this as some kind of ‘miracle cure’ (the phrase used by the patient) for trigeminal neuralgia, but it is worth noting that the procedure had essentially changed his life. This was tremendously satisfying, especially coming in the wake of 12 years of ineffective conventional treatments. The pain of tic douloureux is usually considered intractable.

It is noteworthy that in this case the reduction of pain was seen after the very first trial—within 10 min (although periodic ‘topping up’ was needed to keep the pain down at zero). The implication is that in addition to its long-term beneficial effects, acting through reversing cortical reorganization, visual feedback can act immediately to modulate pain (as we already noted in the case of phantom pain and CRPS/RSD).

A note of caution is in order: Even though the complete cure of patient’s pain was inspired by our earlier studies using MVF, and the patient’s name for his blog notwithstanding, it is far from proven that the procedure worked in him as a RESULT of MVF. Given the well known trans-callosal connections between the two sides of the face, it would be interesting to see if—in other patients—repeated massage on the contralateral face region might on its own (without visual feedback) be partially effective in reducing pain. This seems unlikely since the patient we described above had tried massage (without MVF) but a more systematic study would be worthwhile since simple massage would be even easier to administer than MVF!

Needless to say all five examples discussed above are single case studies and any conclusions from them must be regarded as highly tentative and unproven. But they do suggest that additional placebo-controlled studies on such syndromes might be fruitful. It is worth noting though that most conventional procedures have proved to be notoriously ineffective in treating these disorders and, in a sense, the patient ‘is his own control’ having gone through several conventional treatments with an intense desire and expectation they would work. Yet they were ineffective whereas visual feedback was. It seems highly improbable that a patient with trigeminal neuralgia should have tried 10 years of other treatments without benefit (even though he had fully hoped/expected them to work) whereas MVF should result in a rapid pain reduction merely as a result of wishful thinking. Yet, improbable does not mean impossible which is why additional clinical trials are needed.

Our observations on MVF as well as those of others also suggest a novel, potentially effective treatment of Parkinson’s disease. Since the disorder usually begins unilaterally, one wonders if MVF administered early on might delay the further progression of the disease indefinitely. We are currently exploring this approach.

## Potential use of the MVF principle for other neuropsychiatry syndromes

We have so far discussed the manner in which ‘false’ visual feedback (with mirrors) can promote recovery from stroke, phantom pain and the pain of RSD. Could the same ‘false feedback’ strategy be applied to other syndromes such as ‘emotional pain’?

A good test case would be panic attacks.

The cause of panic attacks is unknown. One possibility is that it occurs because of a ‘mini’ seizure episode in the temporal lobes that falsely triggers a fight or flight response accompanied by sympathetic outflow. Ordinarily this outflow—along with the



corresponding affective and behavioural propensities ('anger,' 'fear,' etc.)—is caused by a clearly visible external threat. The ensuing consummation of the act appropriate to the threat leads to catharsis of emotion (fighting=relief from anger) and reduction of threat. But if the autonomic outflow and sense of danger—which would include the sensing of feedback from your own heartbeat—occurs WITHOUT any visible external threat, then you would not know what target to attribute the emotion to. You may then turn the danger 'inward' and experience a vague, yet terrifying, sense of impending doom; a panic attack. In the absence of a tangible external threat you would not know how to best to express your response and consequently there is no feedback reduction of the perceived threat.

In short the brain has no way of dealing with a NON-ATTRIBUTABLE yet intense emotion and autonomic storm and the net result is a disabling panic attack

If so could a panic attack be aborted by false feedback analogous that provided by MVF? Most patients experience a vague premonition of an impending attack up to a minute before it actually kicks in. One could conceivably have the patient carry around an iPhone with terrifying horror scenes. He/she could then look at the video as soon as he could sense the attack coming on. Given that his brain can now attribute the fight/flight response to a tangible external threat, perhaps the attack will be aborted. The fact that he 'knows' at an intellectual level that it is only a movie may not matter; just as knowing that MVF is not 'real' does not affect its efficacy. (Nor does knowing that a horror movie is not real diminish the horror.)

We mention this example only to illustrate that the basic principle of providing a 'false' or substitute feedback, may have implications for neuropsychiatric rehab that extend far beyond its use in stroke, phantom pain and RSD.

## Reversibility of neurological disorders

The findings reviewed in this article should not be overstated to imply that there are no hardwired specialized modules in the brain, an absurd claim that would contradict over a century of neurology. Nonetheless they suggest a degree of flexibility that would not have previously been suspected.

By hindsight this is not as radical a doctrine as it might seem at first. Every medical student is taught that the cognitive deficits seen after brain injury are—to a large extent—permanent. Yet we have also long known that there are some syndromes—even profoundly disabling ones—from which the majority of patients recover completely in a matter of weeks or even days. Good examples would be hemineglect and anosognosia (denial of paralysis) following a right parietal stroke. Does not the striking recovery seen in patients with neglect provide an 'existence proof' that recovery is possible even from profound dysfunction?

Or take a syndrome as well known as Wernicke's aphasia. The patient who, purportedly, has dysfunction confined entirely to the Wernicke's area in the left hemisphere, has almost no comprehension of even simple words presented visually or verbally.

The standard explanation for this is that the equivalent region in the right hemisphere has no semantics; it cannot understand word meanings.

But contrast this with what happens after commissurotomy. When words are presented selectively to the right hemisphere they are fully understood even if the word cannot be read out loud. Even simple sentences are understood so long as there is no elaborate hierarchical 'nesting' of clause within clause. This implies that in the normal brain the right hemisphere is indeed capable of semantic comprehension. The reason it cannot function in a Wernicke's patient may be because the lesion in the Wernicke's area produces—via the corpus callosum—some 'sympathetic' malfunction in the mirror symmetric location in the right hemisphere, a possibility that can be tested using functional brain imaging. It is as though the malfunctioning Wernicke's area in the left hemisphere inserts a 'software bug' in the equivalent area in the right hemisphere.

Such effects may also occur in Broca's aphasia, as has been shown in an ingenious experiment performed by Pasqua-Leone and colleagues (Naeser *et al.* 2005). In a small open study they silenced the right hemisphere using TMS and found substantial improvement of in picture naming suggesting that the right hemisphere was inhibiting the malfunctioning Broca's area (the evolutionary rationale being, better a silent module than a dysfunctional one).

More directly relevant is a recent study conducted by Ramachandran *et al.* (2007) on intense chronic pain caused by a small stroke in the thalamus (Dejerine-Roussy syndrome). They found that simply irrigating the right ear with ice cold water (vestibular caloric nystagmus—which activates the left hemisphere) produced an immediate and striking modulation—in some cases a temporary reduction—in pain for the first time in years. That the modulation occurs (beyond a placebo) is clear but it remains to be seen whether it is always in the positive direction—which would be clinically useful—or whether the modulation fluctuates. In either case it is of theoretical interest because it is yet another example of a simple procedure affecting a chronic neurological condition of central origin.

The final, most dramatic example is provided by the recent work of Schiff and his co-workers (Schiff *et al.*, 2007). A patient had been in a 'minimally conscious state' for some years. When deep brain stimulation was applied to his thalamus he woke up for the first time in 12 years and was able to communicate in a simple manner. Schiff's group also did DT imaging and found an actual increase in white matter during the next few weeks of recovery (Voss *et al.*, 2006). Here again is a remarkable example of plasticity of connections in the adult brain.

## Conclusions

The papers reviewed in this article have major implications—both for clinical practice and for our theoretical understanding of the brain.

From the clinical standpoint they suggest that MVF can accelerate recovery of function from a wide range of neurological disorders such as phantom pain, hemiparesis from stroke or other brain injury or lesion, complex regional pain syndrome

(CRPS or RSD) and, possibly, even peripheral nerve or musculoskeletal injury. It remains to be seen whether patients with other syndromes such as focal dystonias, Dejerine-Roussy syndrome (thalamic pain), trigeminal neuralgia and Parkinson's disease might benefit similarly from MVF. This is improbable but deserves to be explored.

At a theoretical level, the findings also have a broader relevance to our understanding of normal and abnormal brain function. The old view of brain function—the 'standard model'—on which the last century of neurology has been based, is the notion that the brain consists of a large number of highly specialized autonomous modules that interact very little—if at all—with each other and are hardwired at birth. Neurological disorders, in this view, result from relatively permanent irreversible injury to one—or a small subset—of modules, which would explain not just the specificity of the localizing signs and deficits but also why there is ordinarily such little recovery of function after injury to the brain. Knock out a module and you knock out a function forever.

This is a caricature of course and, in truth, the standard textbook model is still largely correct and here with us to stay. Yet it has been overstated in the past to the extent of being an impediment to research on rehabilitation.

Indeed our results and those of our colleagues demonstrate unequivocally that using very simple procedures one can dissolve barriers between modules (e.g. between vision and proprioception using MVF), between mind and body (as in McCabe's demonstration of temperature changes in RSD) and, most remarkably, between one brain and another—a patient literally experiencing another's pain in his phantom.

Such findings suggest that we need to revise the 'serial hierarchical modular view' of the brain and replace it with a new more dynamic view of brain. Instead of thinking of brain modules as hardwired and autonomous, we should think of them as being in a state of dynamic equilibrium with each other and with the environment (including the body), with connections being constantly formed and re-formed in response to changing environmental needs. Neurological dysfunction, at least in some instances may be caused not so much by irreversible destruction of a module but by a functional shift in equilibrium. If so, perhaps the equilibrium point can be shifted back to its 'normal' state by hitting a 'reset button' using relatively simple non-invasive procedures.

## References

- Aglioti S, Bonazzi A, Cortese F. Phantom lower limb as a perceptual marker of neural plasticity in the mature human brain. *Proc Biol Sci* 1994; 255: 273–8.
- Aglioti S, Smania N, Atzei A, Berlucchi G. Spatio-temporal properties of the pattern of evoked phantom sensations in a left index amputee patient. *Behav Neurosci* 1997; 111: 867–72.
- Altschuler EL, Hu J. Mirror therapy in a patient with a fractured wrist and no active wrist extension. *Scand J Plast Reconstr Surg Hand Surg* 2008; 42: 110–1.
- Altschuler EL, Ramachandran VS. A simple method to stand outside oneself. *Perception* 2007; 36: 632–4.
- Altschuler EL, Wisdom SB, Stone L, Foster C, Galasko D, Llewellyn DME, et al. Rehabilitation of hemiparesis after stroke with a mirror. *Lancet* 1999; 353: 2035–6.
- Armel KC, Ramachandran VS. Projecting sensations to external objects: evidence from skin conductance response. *Proc Biol Sci* 2003; 270: 1499–506.
- Bach-y-Rita P, Collins CC, Saunders FA, White B, Scadden L. Vision substitution by tactile image projection. *Nature* 1969; 221: 963–4.
- Botvinick M, Cohen J. Rubber hands 'feel' touch that eyes see. *Nature* 1998; 391: 756.
- Cacace AT, Lovely TJ, Winrer DF, Parnes SM, McFarland DJ. Auditory perceptual and visual-spatial characteristics of gaze-evoked tinnitus. *Audiology* 1994; 33: 291–303.
- Chan BL, Witt R, Charrow AP, Magee A, Howard R, Pasquina PF, et al. Mirror therapy for phantom limb pain. *N Engl J Med* 2007; 357: 2206–7.
- Charcot J-M. Sur quelques arthropathies qui paraissent dépendre d'une lésion du cerveau ou de la moëlle épinière. *Arch Physiol Norm Pathol* 1868; 1: 161–78.
- Churchland P, Ramachandran VS, Sejnowski T. A critique of pure vision. In: Koch C, Davis J, editors. *Large-scale neuronal theories of the brain*. *Davis: MIT Press*; 1994. p. 23–47.
- Clarke S, Regli L, Janzer RC, Assal G, de Tribolet N. Phantom face: conscious correlate of neural reorganization after removal of primary sensory neurones. *Neuroreport* 1996; 7: 2853–7.
- Darnall BD. Self-delivered home-based mirror therapy for lower limb phantom pain. *Am J Phys Med Rehabil* 2009; 88: 78–81.
- Davare M, Duque J, Vandermeeren Y, Thonnard JL, Olivier E. Role of the ipsilateral primary motor cortex in controlling the timing of hand muscle recruitment. *Cereb Cortex* 2007; 17: 353–62.
- di Pellegrino G, Fadiga L, Fogassi L, Gallese V, Rizzolatti G. Understanding motor events: a neurophysiological study. *Exp Brain Res* 1992; 91: 176–80.
- Ehrsson HH. The experimental induction of out-of-body experiences. *Science* 2007; 317: 1048.
- Eng K, Siekierka E, Pyk P, Chevrier E, Hauser Y, Cameirao M, et al. Interactive visuo-motor therapy system for stroke rehabilitation. *Med Biol Eng Comput* 2007; 45: 901–7.
- Ertelt D, Small S, Solodkin A, Dettmers C, McNamara A, Binkofski F, et al. Action observation has a positive impact on rehabilitation of motor deficits after stroke. *Neuroimage* 2007; 36 (Suppl 2): T164–73.
- Fink GR, Marshall JC, Halligan PW, Frith CD, Driver J, Frackowiak RS, et al. The neural consequences of conflict between intention and the senses. *Brain* 1999; 122: 497–512.
- Flor H, Diers M, Christmann C, Koeppel C. Mirror illusions of phantom hand movements brain activity mapped by fMRI. *NeuroImage* 2006; 31: S159.
- Flor H, Elbert T, Knecht S, Wienbruch C, Pantev C, Birbaumer N, et al. Phantom-limb pain as a perceptual correlate of cortical reorganization following arm amputation. *Nature* 1995; 375: 482–4.
- Garry MI, Loftus A, Summers JJ. Mirror, mirror on the wall: viewing a mirror reflection of unilateral hand movements facilitates ipsilateral M1 excitability. *Exp Brain Res* 2005; 163: 118–22.
- Gawande A. *Annals of medicine: the itch*. *New Yorker*, 30 June 2008. p. 58–64.
- Gibson JJ. Observations on active touch. *Psych Rev* 1962; 69: 477–91.
- Halligan PW, Marshall JC, Wade DT. Sensory disorganization and perceptual plasticity after limb amputation: a follow-up study. *Neuroreport* 1994; 5: 1341–5.
- Harris AJ. Cortical origin of pathological pain. *Lancet* 2000; 355: 318–9.
- Holmes NP, Crozier G, Spence C. When mirrors lie: 'visual capture' of arm position impairs reaching performance. *Cogn Aff Behav Neurosci* 2004; 4: 193–200.
- Holmes NP, Snijders HJ, Spence C. Reaching with alien limbs: Visual exposure to prosthetic hands in a mirror biases proprioception without accompanying illusions of ownership. *Percept Psychophys* 2006; 68: 685–701.

- Holmes NP, Spence C. Visual bias of unseen hand position with a mirror: spatial and temporal factors. *Exp Brain Res* 2005; 166: 489–97.
- Jensen TS, Nikolajsen L. Phantom pain and other phenomena after amputation. In: Wall PD, Melzack RA, editors. *Textbook of pain*. 4th edn., Edinburgh: Churchill Livingstone; 1999. p. 799–814.
- Karmarkar A, Lieberman I. Mirror box therapy for complex regional pain syndrome. *Anaesthesia* 2006; 61: 412–3.
- Kauffman T, Theoret H, Pascual-Leone A. Braille character discrimination in blindfolded human subjects. *Neuroreport* 2002; 13: 571–4.
- Kew JJ, Halligan PW, Marshall JC, Passingham RE, Rothwell JC, Ridding MC, et al. Abnormal access of axial vibrotactile input to deafferented somatosensory cortex in human upper limb amputees. *J Neurophysiol* 1997; 77: 2753–64.
- Keyserers C, Wicker B, Gazzola V, Anton JL, Fogassi L, Gallese V. A touching sight: SII/PV activation during the observation and experience of touch. *Neuron* 2004; 42: 335–46.
- Knecht S, Henningsen H, Elbert T, Flor H, Hohling C, Pantev C, et al. Reorganizational and perceptual changes after amputation. *Brain* 1996; 119: 1213–9.
- Kosslyn SM, Reiser BJ, Farah MJ, Fliegel SL. Generating visual images: units and relations. *J Exp Psychol Gen* 1983; 112: 278–303.
- Lenggenhager B, Tadi T, Metzinger T, Blanke O. Video ergo sum: manipulating bodily self-consciousness. *Science* 2007; 317: 1096–9.
- MacLachlan M, McDonald D, Waloch J. Mirror treatment of lower limb phantom pain: a case study. *Disabil Rehabil* 2004; 26: 901–4.
- MacIver K, Lloyd DM, Kelly S, Roberts N, Nurmikko T. Phantom limb pain, cortical reorganization and the therapeutic effect of mental imagery. *Brain* 2008; 131: 2181–91.
- Matsuo A, Tezuka Y, Morioka S, Hiyamiza M, Seki M. Mirror therapy accelerates recovery of upper limb movement after stroke: a randomized cross-over trial. *Sixth World Stroke Conference, Vienna, Austria (Abstract)*, 2008.
- McCabe CS, Haigh RC, Halligan PW, Blake DR. Referred sensations in patients with complex regional pain syndrome type 1. *Rheumatology (Oxford)* 2003a; 42: 1067–73.
- McCabe CS, Haigh RC, Halligan PW, Blake DR. Simulating sensory-motor incongruence in healthy volunteers: implications for a cortical model of pain. *Rheumatology (Oxford)* 2005; 44: 509–16.
- McCabe CS, Haigh RC, Ring EF, Halligan PW, Wall PD, Blake DR. A controlled pilot study of the utility of mirror visual feedback in the treatment of complex regional pain syndrome (type 1). *Rheumatology (Oxford)* 2003b; 42: 97–101.
- Melzack R. Phantom limbs. *Sci Am* 1992; 266: 120–6.
- Merzenich MM, Kaas JH, Wall J, Nelson RJ, Sur M, Felleman D. Topographic reorganization of somatosensory cortical areas 3b and 1 in adult monkeys following restricted deafferentation. *Neuroscience* 1983; 8: 33–55.
- Mitchell JK. On a new practice in acute and chronic rheumatism. *Am J Med Sci* 1831; 8: 55–64.
- Mitchell SW. *Injuries of nerves and their consequences*. Philadelphia: J.B. Lippincott; 1872.
- Mitchell SW, Morehouse GR, Keen WW. *Gunshot wounds and other injuries of nerves*. Philadelphia: J.B. Lippincott; 1864.
- Moseley GL. Graded motor imagery for pathologic pain: a randomized controlled trial. *Neurology* 2006; 67: 2129–34.
- Moseley GL, Olthof N, Venema A, Don S, Wijers M, Gallace A, et al. Psychologically induced cooling of a specific body part caused by the illusory ownership of an artificial counterpart. *Proc Natl Acad Sci USA* 2008a; 105: 13169–73.
- Moseley GL, Parsons TJ, Spence C. Visual distortion of a limb modulates the pain and swelling evoked by movement. *Curr Biol* 2008b; 18: R1047–8.
- Naeser MA, Martin PI, Nicholas M, Baker EH, Seekins H, Kobayashi M, et al. Improved picture naming in chronic aphasia after TMS to part of right Broca's area: an open-protocol study. *Brain Lang* 2005; 93: 95–105.
- Oakley DA, Whitman LG, Halligan PW. Hypnotic imagery as a treatment for phantom limb pain: two case reports and a review. *Clin Rehabil* 2002; 16: 368–77.
- Penfield W, Boldrey E. Somatic motor and sensory representation in the cerebral cortex of man as studied by electrical stimulation. *Brain* 1937; 60: 389–443.
- Ramachandran VS. Behavioral and magnetoencephalographic correlates of plasticity in the adult human brain. *Proc Natl Acad Sci USA* 1993; 90: 10413–20.
- Ramachandran VS. Phantom limbs, neglect syndromes, repressed memories, and Freudian psychology. *Int Rev Neurobiol* 1994; 37: 291–333.
- Ramachandran VS. Plasticity and functional recovery in neurology. *Clin Med* 2005; 5: 368–73.
- Ramachandran VS, Hirstein W. The perception of phantom limbs. The D. O. Hebb lecture. *Brain* 1998; 121: 1603–30.
- Ramachandran VS, McGeoch PD, Williams L, Arcilla G. Rapid relief of thalamic pain syndrome induced by vestibular caloric stimulation. *Neurocase* 2007; 13: 185–8.
- Ramachandran VS, Rogers-Ramachandran D, Cobb S. Touching the phantom limb. *Nature* 1995; 377: 489–90.
- Ramachandran VS, Rogers-Ramachandran D. Phantom limbs and neural plasticity. *Arch Neurol* 2000; 57: 317–20.
- Ramachandran VS, Rogers-Ramachandran D. It's all done with mirrors. *Sci Am Mind* 2007; 18: 16–9.
- Ramachandran VS, Rogers-Ramachandran D. Sensations referred to a patient's phantom arm from another subject's intact arm: perceptual correlates of mirror neurons. *Med Hypotheses* 2008; 70: 1233–4.
- Ramachandran VS, Rogers-Ramachandran D, Stewart M. Perceptual correlates of massive cortical reorganization. *Science* 1992; 258: 1159–60.
- Rock I, Victor J. Vision and touch: an experimentally created conflict between the two senses. *Science* 1964; 143: 594–6.
- Rosén B, Lundborg G. Training with a mirror in rehabilitation of the hand. *Scand J Plast Reconstr Surg Hand Surg* 2005; 39: 104–8.
- Sathian K, Greenspan AI, Wolf SL. Doing it with mirrors: a case study of a novel approach to neurorehabilitation. *Neurorehabil Neural Repair* 2000; 14: 73–6.
- Schiff ND, Giacino JT, Kalmar K, Victor JD, Baker K, Gerber M, et al. Behavioural improvements with thalamic stimulation after severe traumatic brain injury. *Nature* 2007; 448: 600–3.
- Schwerin S, Dewald JP, Haztl M, Jovanovich S, Nickeas M, MacKinnon C. Ipsilateral versus contralateral cortical motor projections to a shoulder adductor in chronic hemiparetic stroke: implications for the expression of arm synergies. *Exp Brain Res* 2008; 185: 509–19.
- Selles RW, Schreuders TA, Stam HJ. Mirror therapy in patients with causalgia (complex regional pain syndrome type II) following peripheral nerve injury: two cases. *J Rehabil Med* 2008; 40: 312–4.
- Stevens JA, Stoykov ME. Using motor imagery in the rehabilitation of hemiparesis. *Arch Phys Med Rehabil* 2003; 84: 1090–2.
- Stevens JA, Stoykov ME. Simulation of bilateral movement training through mirror reflection: a case report demonstrating an occupational therapy technique for hemiparesis. *Top Stroke Rehabil* 2004; 11: 59–66.
- Suhonen JO, Peterson DA, Ray J, Gage FH. Differentiation of adult hippocampus-derived progenitors into olfactory neurons in vivo. *Nature* 1996; 383: 624–7.
- Sumitani M, Miyauchi S, McCabe CS, Shibata M, Maeda L, Saitoh Y, et al. Mirror visual feedback alleviates deafferentation pain, depending on qualitative aspects of the pain: a preliminary report. *Rheumatology (Oxford)* 2008; 47: 1038–43.
- Sütbeyaz S, Yavuzer G, Sezer N, Koseoglu BF. Mirror therapy enhances lower-extremity motor recovery and motor functioning after stroke: a randomized controlled trial. *Arch Phys Med Rehabil* 2007; 88: 555–9.



- Taub E. Somatosensory deafferentation research with monkeys: implications for rehabilitation medicine. In: Ince L, editor. Behavioral psychology in rehabilitation medicine: clinical applications. Baltimore, MD: Williams & Wilkins; 1980. p. 371–401.
- Turton AJ, Butler SR. Referred sensations following stroke. *Neurocase* 2001; 7: 397–405.
- Valentini M, Kischka U, Halligan PW. Residual haptic sensation following stroke using ipsilateral stimulation. *J Neurol Neurosurg Psychiatry* 2008; 79: 266–70.
- Vladimir Tichelaar YI, Geertzen JH, Keizer D, Paul van Wilgen C. Mirror box therapy added to cognitive behavioural therapy in three chronic complex regional pain syndrome type I patients: a pilot study. *Int J Rehabil Res* 2007; 30: 181–8.
- Voss HU, Ulug AM, Watts R, Heier LA, McCandliss B, Kobylarz E, et al. Possible axonal regrowth in late recovery from minimally conscious state. *J Clin Invest* 2006; 116: 2005–11.
- Wolf SL, Winstein CJ, Miller JP, Taub E, Uswatte G, Morris D, et al. EXCITE investigators. Effect of constraint-induced movement therapy on upper extremity function 3 to 9 months after stroke: the EXCITE randomized clinical trial. *JAMA* 2006; 296: 2095–104.
- Yang TT, Gallen C, Schwartz B, Bloom FE, Ramachandran VS, Cobb S. Sensory maps in the human brain. *Nature* 1994; 368: 592–3.
- Yavuzer G, Selles R, Sezer N, Sütbeyaz S, Bussmann JB, Köseoğlu F, et al. Mirror therapy improves hand function in subacute stroke: a randomized controlled trial. *Arch Phys Med Rehabil* 2008; 89: 393–8.