

Therapeutic efficacy of *Pimpinella tirupatiensis* (Apiaceae) on acetaminophen induced nephrotoxicity and oxidative stress in male albino rats

S. Palani^{1*}, S. Raja², R.Praveen Kumar¹, Soumya Jayakumar¹, B. Senthil Kumar³

¹Dept of Biotechnology, Anna BioResearch Foundation, Arunai Engineering College, Tiruvannamalai, Tamil Nadu, India.

²Bharat Institute of Technology, Ibrahimpatnam, Hyderabad, India

³ PG Research, Dept of Zoology, CA Abdul Hakeem College, Melvisharam, Tamil Nadu, India.

*Email- spalanitvm@gmail.com Ph-04175 237419, Fax- 04175

237780., Mobile- +919790607796

ABSTRACT: *Pimpinella tirupatiensis* (Apiaceae) is a herbaceous medicinal plant used to treat cough, stomach, liver problems, asthma, ulcer and tooth ache in India and other Asian countries. Acetaminophen (APAP) is a commonly used analgesic and antipyretic agent which, at high doses, causes liver and kidney necrosis in man and animals. The aim of the present study is to investigate the nephroprotective and antioxidant activities of the ethanol extract of *P.tirupatiensis* in two dose levels of 500mg/kg & 750 mg/kg B/W respectively on APAP induced toxicity in rats. Biochemical studies show that there is an increase in the levels of serum urea and creatinine along with an increase in the body weight and reduction in the levels of uric acid in APAP induced groups. These values are retrieved significantly by treatment with *P.tirupatiensis* extracts at two different doses. The antioxidant studies reveal that the levels of renal SOD, CAT, GSH and GPx in the APAP treated animals are increased significantly along with a reduced MDA content in ethanol extract of *P.tirupatiensis* treated groups. Apart from these, histopathological changes also reveal the protective nature of the *P.tirupatiensis* extract against acetaminophen induced necrotic damage of renal tissues. In conclusion, these data suggest that the ethanol extract of *P.tirupatiensis* can prevent renal damage from APAP induced nephrotoxicity in rats and it is likely to be mediated through its antioxidant activities.

Key Words: Acetaminophen, antioxidant, nephroprotective *Pimpinella tirupatiensis*,

1. INTRODUCTION

Acetaminophen (APAP) is a widely used analgesic and antipyretic drug that is safely employed for a wide range of treatments [1], Overdose of APAP in human is fairly common and is often associated with hepatic [2-4] and renal damage [5-7]. Although nephrotoxicity is less common than hepatotoxicity in APAP overdose, renal tubular damage and acute renal failure can occur even in the absence of liver injury [8-10] and can even lead to death in humans and experimental animals [11-12]. Studies are going on throughout the world for the search of protective molecules that would provide maximum protection to the liver, kidney as well as other organs and practically very little or no side effects would be exerted

during their function in the body [13-14]. A number of herbs are traditionally used in different countries during drug or toxin induced hepatic and renal disorders [15]. *Pimpinella tirupatiensis* (Apiaceae) is herbaceous medicinal plant locally known as 'adavikothimeera' (forest coriander) that has been distributed on Tirumala Hills of Chittoor district, Andhra Pradesh, India[16]. Dried roots of *P. tirupatiensis* are administered along with few other ingredients to cure colic and rheumatic ailments in cattle [17]. The local Yanadhi tribal community uses the tuberous roots of *P. tirupatiensis* to cure severe ulcers of stomach, throat and genital organs and also as aphrodisiac [18] and abortifacient agents [19]. Fruits are used to cure asthma and are considered as an effective remedy for

'flatulent colic' [18]. The whole plant of *P. tirupatiensis* is used to treat cough, stomach, liver problems, asthma, ulcer and tooth ache [20-21]. This plant root extract is also used to treat skin disease [22] and is used as an antimicrobial agent [23] it is even given in the treatment of venereal disease and peptic ulcers [24].

The aim of this particular study was to investigate nephro protective and antioxidant properties of *Pimpinella tirupatiensis*. The effect of the plant extract in APAP induced toxicity was evaluated by determining the levels of creatinine, blood urea nitrogen (BUN) and uric acid from the serum in all the experimental groups. The activity of endogenous antioxidant enzymes such as superoxide dismutase (SOD), catalase (CAT) and glutathione-peroxidase (GPx) were measured from kidney homogenates. Further, the level of non-protein thiol, glutathione (GSH) and lipid peroxidation were also estimated from renal samples. To assess the ultra structural changes of the kidney, histopathological studies were conducted from kidney sections of normal rat, rat treated with APAP, and rat treated with plant extract prior and later with APAP.

2. MATERIALS AND METHODS

2.1 Plant material

The whole plant of *P. tirupatiensis* was collected from Tirumala Hills of Chittoor district, Andhra Pradesh, India and the plant material was taxonomically identified and authenticated by the Dr. Madhava chetty (Research Officer) botany, Andhra Pradesh. Voucher specimen (AECBT-05/2007-2008) of this plant has been retained in the Anna Bioresearch foundation, Arunai Engineering College, Tiruvannamalai, Tamilnadu, India.

2.2 Extraction

The whole plant was dried under shade and then powdered with a mechanical grinder to obtain a coarse powder. Equal quantity of powder was passed through 40 mesh sieve and extracted with ethanol (90% v/v) in soxhlet apparatus at 60°C [25]. The solvent was completely removed by rotary vacuum evaporator. The extract was freeze dried and stored in a vacuum desiccator.

2.3 Animals

Studies were carried out using Wistar albino male rats (150-200g), obtained from Indian Veterinary Preventive medicine (IVPM), Ranipet, Tamilnadu, India. The animals were grouped and housed in polyacrylic cages (38 x 23 x 10 cm) with not more than six animals per cage and maintained under standard laboratory conditions (temperature 25 ± 20°C) with dark and light cycle (12/12 h). The animals were fed with standard pellet diet supplied by Poultry Research Station, Nandhanam, India and fresh water *ad libitum*. All the animals were acclimatized to laboratory condition for a week before commencement of experiment. All procedures described were reviewed and approved by the University Animals Ethical Committee.

2.4 Paracetamol induced nephrotoxicity in rats

Animals were randomized and divided into four groups

(I - IV) of six animals in each group. Group I served as untreated control and is fed orally with normal saline 5 ml/kg body weight daily for 14 days. Group II rats were similarly treated as group I. Groups III and IV animals were treated with 500 mg/kg and 750 mg/kg body weight of the ethanol extract of *P. tirupatiensis* for 14 days, respectively. On the 14th day, acetaminophen suspension was given by oral route, in a dose of 750 mg/kg body weight to all rats except the rats in group I.

2.5 Hematological study

After 48 h, animals were sacrificed by chloroform anaesthesia. Blood samples were collected by cardiac puncher under diethyl ether anesthesia, using 21 gauge (21 G) needles mounted on a 5ml syringe (Hindustan syringes and medical devices Ltd, Faridabad, India.) into ethylene diamine terra-acetic acid (EDTA) - coated sample bottles for analyzed Hematological parameters like full blood count (FBC), hemoglobin, (Hb), packed cell volume (PCV), mean corpuscular volume (MCV), mean corpuscular hemoglobin (MCH), mean corpuscular hemoglobin concentration (MCHC), platelet concentration (PLC) and Total leucocyte count (TLC). These parameters were analyzed using automatic hematological system (Sysmex Hematology -Coagulation system, Model MO-1000 I, Trans Asia, Japan).

2.6 Sampling and biochemical analysis

Following termination of the experiment on the day 14, the rats were fasted overnight for 14 hours. Blood samples were collected by cardiac puncture with 21G needle mounted on 5 ml syringe (under diethyl ether anesthesia) and centrifuged for 10min at 5000 rpm. The obtained clear sera were stored at -20 °C for subsequent measurement of blood urea, creatinine and uric acid levels using colorimetric assay kits, Bayer (Seamon) according to the manufacturer's instructions.

2.7 Preparation of renal homogenate

The kidneys were removed and dissected free from the surrounding fat and connective tissue. Each kidney was longitudinally sectioned, and renal cortex was separated and kept at -8°C. Subsequently, renal cortex was homogenized in cold potassium phosphate buffer (0.05 M, pH 7.4). The renal cortical homogenates were centrifuged at 5000rpm for 10 min at 4°C. The resulting supernatant was used for the determination of -malondialdehyde (MDA) content, reduced glutathione (GSH) levels and antioxidant enzyme levels such as superoxide dismutase (SOD), catalase (CAT), glutathione reductase (GRD) and glutathione peroxidase (GPX) activity using colorimetric assay.

2.8 Biochemical estimation of markers of oxidative stress

MDA content was measured according to the earlier method reported [26]. SOD activity was determined according to the previous report [27]. CAT activity was determined from the rate of decomposition of H₂O₂ by the reported method [28]. GPx activity was determined by measuring the decrease in GSH content after

incubating the sample in the presence of H₂O₂ and NaN₃ [29]. Glutathione reductase activity was assayed according to the previous reports [30-31]. Protein content in the tissue was determined by the method reported earlier [32] using bovine serum albumin (BSA) as the standard.

2.9 Histopathological examination Pieces of kidney from each group were fixed immediately in 10% neutral formalin for a period of at least 24 h, dehydrated in graded (50-100%) alcohol, embedded in paraffin, cut into 4-5 μ m thick sections and stained with hematoxylin-eosin. The sections were evaluated for the pathological symptoms of nephrotoxicity such as necrosis, fatty infiltration, fibrosis, lymphocyte infiltration, etc.

3. RESULTS

3.1 Effect of *P. tirupatiensis* extract on serum urea, uric acid and creatinine concentrations

Serum urea and creatinine concentrations were significantly increased ($p < 0.01$) in the APAP treated group of animals compared to the normal animals indicating the induction of severe nephrotoxicity (Fig.2&4). Treatment with the ethanol extract of *P.tirupatiensis* showed significant ($p < 0.05$ & $p < 0.01$) (Group III & IV) decrease in concentrations of serum urea and creatinine compared to the APAP treated group. However the levels of uric acid (UA) significantly decreased ($p < 0.01$) in the APAP treated groups (Group II, Fig.3), when compared to the control group. Treatment with ethanol extract of *P.tirupatiensis* significantly ($p < 0.05$ & $p < 0.01$) (Group III & IV respectively) increased the uric acid levels, compared to the APAP treated group.

3.2 Effect of the *P.tirupatiensis* extract on kidney antioxidant status

The activity of CAT in the APAP treated group was significantly ($p < 0.01$) decreased when compared to the normal animals (Group I). Treatment with the ethanol extract of *P.tirupatiensis* significantly ($p < 0.05$ & $p < 0.01$) (Group III & IV) prevented decrease in the level of catalase activity (Fig.1) compared to the APAP induced rat (Group II). Like wise, the decreased GPx activity as a result of the treatment with APAP was also restored by the *P.tirupatiensis* extract ($p < 0.05$ & $p < 0.01$) (Fig.2) for Group III & IV as compared to the normal group. Renal SOD activity was decreased significantly ($p < 0.01$) in the APAP treated (group II) animals compared to normal group. Treatment with the extract (500 & 750 mg/kg body wt) (Group III & IV) significantly ($p < 0.05$ & $p < 0.01$ respectively) elevated the SOD levels as compared to the APAP induced (Group II) animals (Fig.5). The GSH and MDA levels of APAP and extract treated animals are presented in (Fig.2&3). The GSH level reduced significantly ($p < 0.01$) along with increased in MDA concentration in the APAP treated group as compared to the Group I. However on treatment with *P.tirupatiensis* ethanol extract, the GSH level was found to be enhanced significantly ($p < 0.05$ & $p < 0.01$) and the MDA contents were reduced in Group III & IV as compared to the

induced group (Group II) (Fig.2).

3.3 Effect of ethanol extract of *P. tirupatiensis* on hematological parameters

APAP caused a significant ($P < 0.01$) increase in the levels of Hb, PCV, DLC and MCV (Fig 2&4) (Group II) when compared to the normal control group (Group I), resulting in acetaminophen associated nephropathy. Administration of ethanolic extract of *P. tirupatiensis* significantly (Group III & Group IV ; $p < 0.05$, $p < 0.01$ respectively) decreased the Hb, PCV, DLC and MCV levels as compared to the APAP induced group (Group II) (Fig 2&4). Further, in APAP treated group (Group II), the levels of PLC, MCHC, MCH & lymphocyte are decreased significantly ($p < 0.01$) when compared with normal (Group I) (Fig 1,2&3). Administration of *P. tirupatiensis* ethanol extract ensures that these levels are retrieved normally, significantly ($P < 0.05$, $P < 0.01$) when compared with Group 2.

3.4 Histopathological Studies

The biochemical results were also confirmed by the histological pattern of normal kidney showing normal tubular brushborders and intact glomeruli and Bowman's capsule (Fig. 6 (A)), Treatment with acetaminophen. Severe tubular necrosis and degeneration is shown in the renal tissue (Fig. 6 (B)). The rats treated with ethanolic extract of *P.tirupatiensis* (500mg/kg body weight) showed normal tubular pattern with a mild degree of swelling, necrosis and degranulation (Fig.6(C)). Treatment with the extract (750 mg/kg body weight) ameliorated the toxic manifestations in the kidney. (Fig. 6 (D)).

4. DISCUSSION

Acetaminophen over dose is often linked to many metabolic disorders including serum electrolyte, urea and creatinine dearrangements. Increased concentration of serum urea and creatinine are considered for investigating drug induced nephrotoxicity in animals and man. [33]. The reason behind acetaminophen toxicology is the CYP-mediated conversion of acetaminophen to a highly reactive quinone imine, A⁻acetyl-pbenzoquinone imine. The fundamental role of NAPQI in the toxicity of acetaminophen has been supported by many subsequent studies [34-38].

The vital function that blood cells perform, together with the susceptibility of this highly proliferative tissue to intoxication by xenobiotics, makes the hematopoietic system unique as a target organ [39]. The various blood cells (erythrocytes, leucocytes, and platelets) are produced at a turnover rate of about 1 to 3 million per second in a healthy human adult and this value could be altered in certain physiological or pathological states including hemolytic anemia or suppressive inflammation[40]. Certain drugs including alkylating cytotoxic agents could also affect blood formation rate and the normal range of hematological parameters [39].

Treatment with APAP oral dose significantly increased the Hb, PCV, DLC & MCV levels. After administration

of *Pimpinella tirupatiensis* extract these levels are significantly decreased compare to the APAP induced group. Whereas the levels of granulocyte, MCH, MCHC and PLC were decreased significantly in the APAP treated group, compared to the normal control group. However after administration of *Pimpinella tirupatiensis* extract these levels are significantly increased compared to the APAP treated group. However this study shows that the *Pimpinella tirupatiensis* extract could contain candidate molecules reversing the hematotoxic effect of acetaminophen, with ensuing improvement of hematopoiesis.

However the blood hematological parameters such as Hb, PCV, DLC and MCV values significantly increased the APAP induced groups, the other hematological parameters like MCHC, Neutrophils, PLC, MCH were decreased significantly. The pretreatment with *Pimpinella tirupatiensis* extract significantly decreased the Hb, PCV, DLC and MCV values along with a significant increase in MCHC, Neutrophils, PLC, MCH contents when compared to APAP induced group.

Blood urea nitrogen is found in the liver protein that is derived from diet or tissue sources and is normally excreted in the urine. In renal disease, the serum urea accumulates because the rate of serum urea production exceeds the rate of clearance [41]. Elevation of urea and creatinine levels in the serum was taken as the index of nephrotoxicity [42-44]. Creatinine, on the other hand, is mostly derived from endogenous sources by tissue creatinine breakdown [41]. Thus serum urea concentration is often considered a more reliable renal function predictor than serum creatinine.

In the present study, administration of hepatotoxic and nephrotoxic doses of APAP to rats resulted in development of oxidative stress damage in hepatic and renal tissues. In this study, APAP induced nephrotoxicity showed a significant ($P < 0.01$) increase in the serum urea and creatinine concentrations in the Group II (APAP induced) rat when compared to the normal group (Group I). Moreover, oral administration of ethanolic extract of *P.tirupatiensis* significantly ($P < 0.01$) decreased in group III & IV when compared to the Group II. However the level of uric acid is significantly decreased ($P < 0.01$) in the Group II rats when compared to Group I. Oral administration of plant extract significantly ($P < 0.01$) increases the uric acid level in Group I when compared to the APAP induced rats (Group II).

Thus, oxidative stress and lipid peroxidation are early events related to radicals generated during the hepatic metabolism of APAP. Also the generation of reactive oxygen species has been proposed as a mechanism by which many chemicals can induce nephrotoxicity [45]. Previous studies have clearly demonstrated that acute APAP overdose increases the lipid peroxidation and suppresses the antioxidant defense mechanisms in renal

tissue [46-47]. However in the APAP treated animals the MDA levels are increased significantly, when compared to normal control rats. On Administration of ethanolic extract of *P. tirupatiensis*, the levels of MDA decreased significantly when compared to APAP induced rats. During kidney injury, superoxide radicals are generated at the site of damage and modulate SOD and CAT, resulting in the loss of activity and accumulation of superoxide radical, which damages kidney. SOD and CAT are the most important enzymes involved in ameliorating the effects of oxygen metabolism [48-49]. The present study also demonstrated that acute APAP overdose resulted in a decrease in the SOD, CAT and GST activities, when compared with normal control rats. It is due to enhanced lipid peroxidation or inactivation of the antioxidative enzymes. When rat was treated with the *P.tirupatiensis* extract the reduction of SOD, CAT and GST activity was increased significantly when compared with induced group ($P < 0.01$)(Group II).

Current evidence suggests that intracellular GSH plays an essential role in detoxification of APAP and prevention of APAP-induced toxicity in the liver and kidney [50-52]. However, APAP was found to increase the microsomal superoxide and hydrogen peroxide production in mice. The generation of the reactive oxygen species appears as an early event which precedes intracellular GSH depletion and cell damage in APAP hepatotoxicity [53]. APAP administration also caused a significant decrease in GSH content. Administration of *P. tirupatiensis* extract helped to uplift the GSH depletion induced by APAP. APAP-induced nephrotoxicity was evidenced by biochemical measurements and histopathological changes that coincide with the observations of other investigators [54-57]. The biochemical results were also confirmed by the histological findings which showed preservation of the glomeruli and the surrounding Bowman's capsule and mildly swollen tubules. Other nephroprotective medicinal plants have been reported of inhibiting xenobiotic-induced nephrotoxicity in experimental animal models due to their potent anti-oxidant or free radicals scavenging effects [58-59]. In addition, alkaloids have also been reported to strongly inhibit lipid peroxidation induced in isolated tissues via its antioxidant activity. [60] The protection offered by the extract could have been due to the presence of flavonoids and alkaloids [61-62].

The activity elicited by the extract might be due to its ability to activate antioxidant enzymes. The findings suggest the potential use of the ethanolic extract of *Pimpinella tirupatiensis* as a novel therapeutically useful nephroprotective agent. Therefore, further studies to elucidate their mechanisms of action should be conducted to aid the discovery of new therapeutic agents for the treatment of renal diseases.

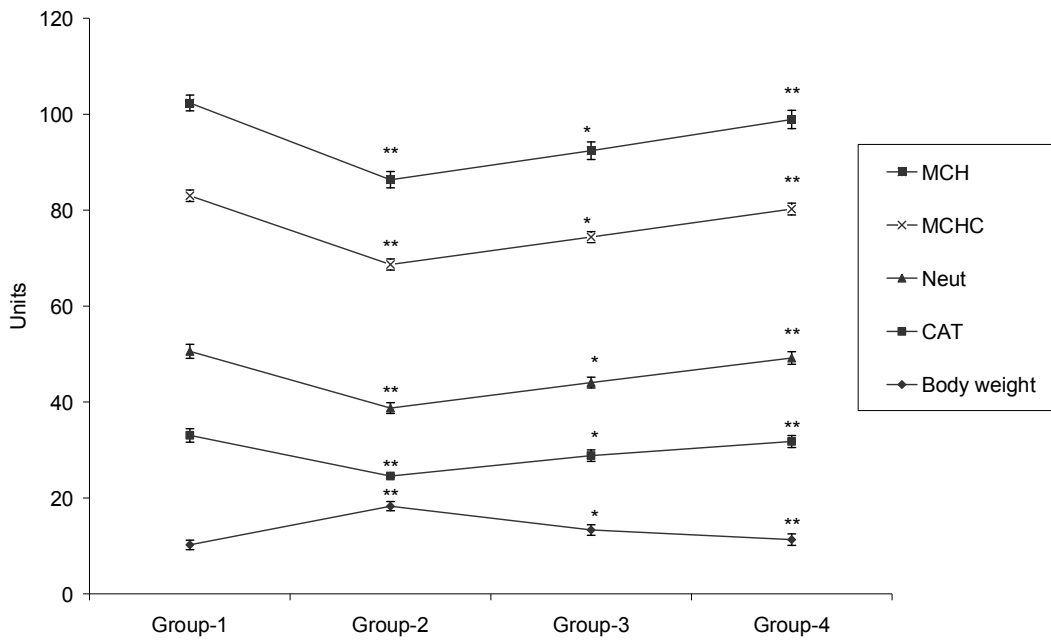


Fig. 1. Effect of treatment with ethanol extract *Pimpinella tirupatiensis* on the renal intracellular CAT activity & blood haematological parameters (Neutrophil, MCHC & MCH), in rats with acetaminophen (APAP)-induced nephrotoxicity. All values are mean \pm S.D., (n = 6). **p < 0.01, *p < 0.05 with respect to control. (One way ANOVA followed by Dunnett's t-test.)

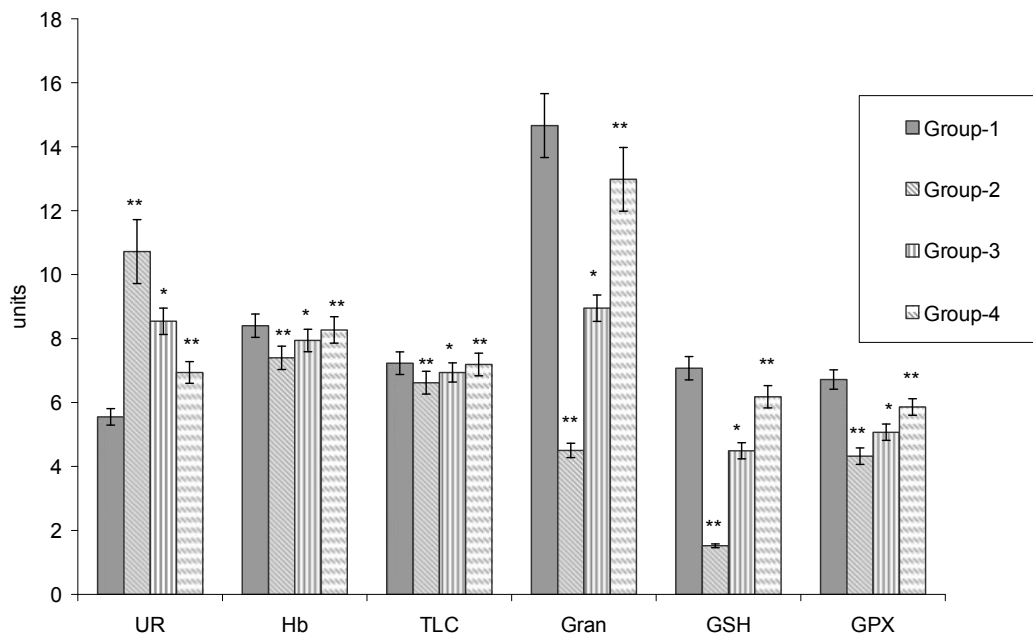


Fig. 2. Effect of treatment with ethanol extract of *Pimpinella tirupatiensis* on the renal intracellular GPX, GSH activity, blood Hematological parameters (Gran, TLC & Hb) and serum urea (UR) levels, in rats with acetaminophen (APAP)-induced nephrotoxicity. All values are mean \pm S.D., (n = 6). **p < 0.01, *p < 0.05 with respect to control. (One way ANOVA followed by Dunnett's t-test.)

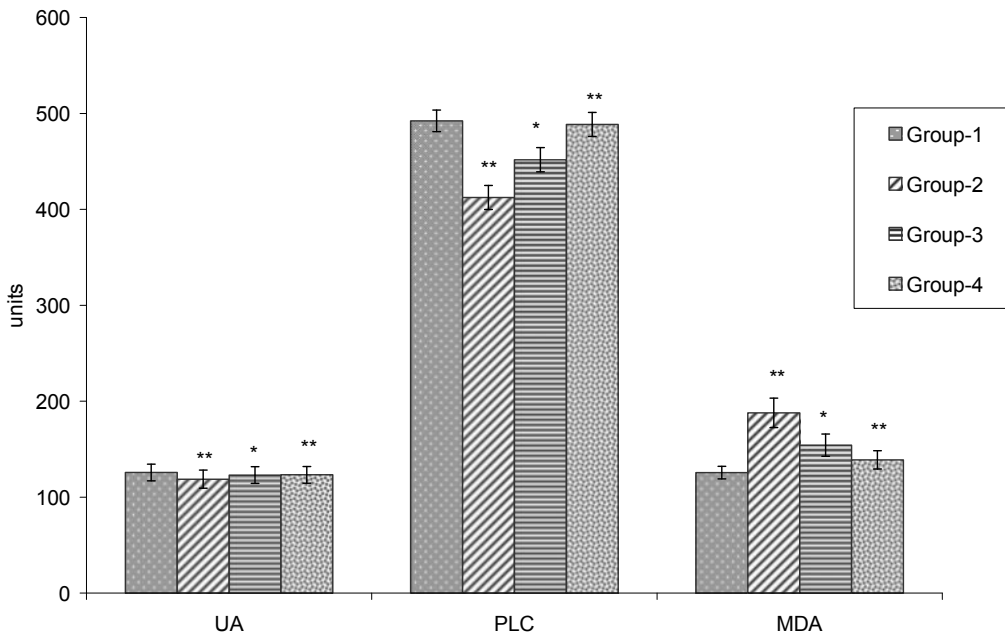


Fig. 3. Effect of treatment with ethanol extract of *Pimpinella tirupatiensis* on the renal MDA level, blood hematological parameter(PLC) and serum uric acid levels, in rats with acetaminophen (APAP)-induced nephrotoxicity. All values are mean \pm S.D., (n = 6). **p < 0.01, *p < 0.05 with respect to control (One way ANOVA followed by Dunnett's t-test.)

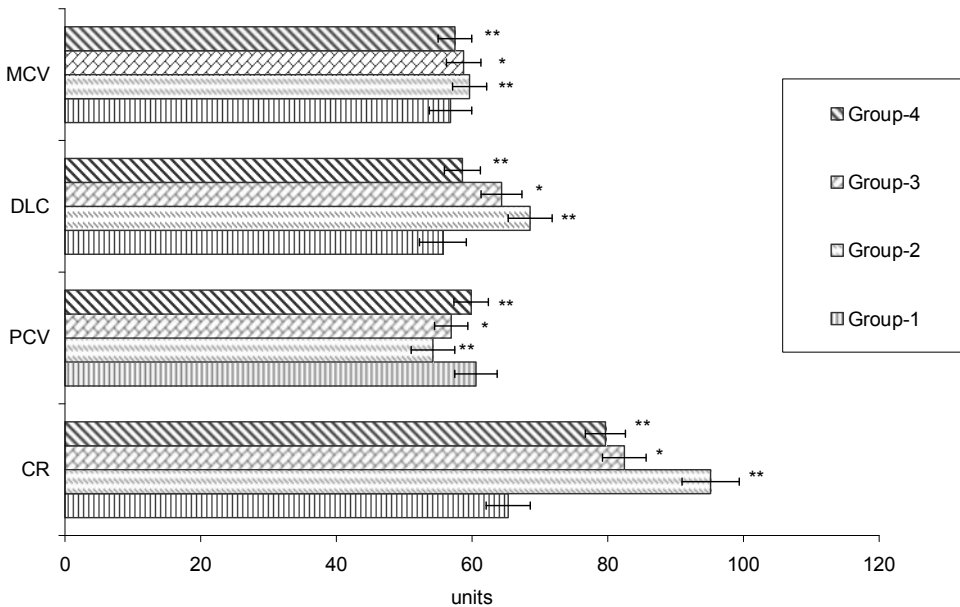


Fig. 4. Effect of treatment with ethanol extract of *Pimpinella tirupatiensis* on the blood hematological parameter (MCV, DLC, PCV) and serum creatinine levels, in rats with acetaminophen (APAP)-induced nephrotoxicity. All values are mean \pm S.D., (n = 6). **p < 0.01, *p < 0.05 with respect to control. (One way ANOVA followed by Dunnett's t-test.)

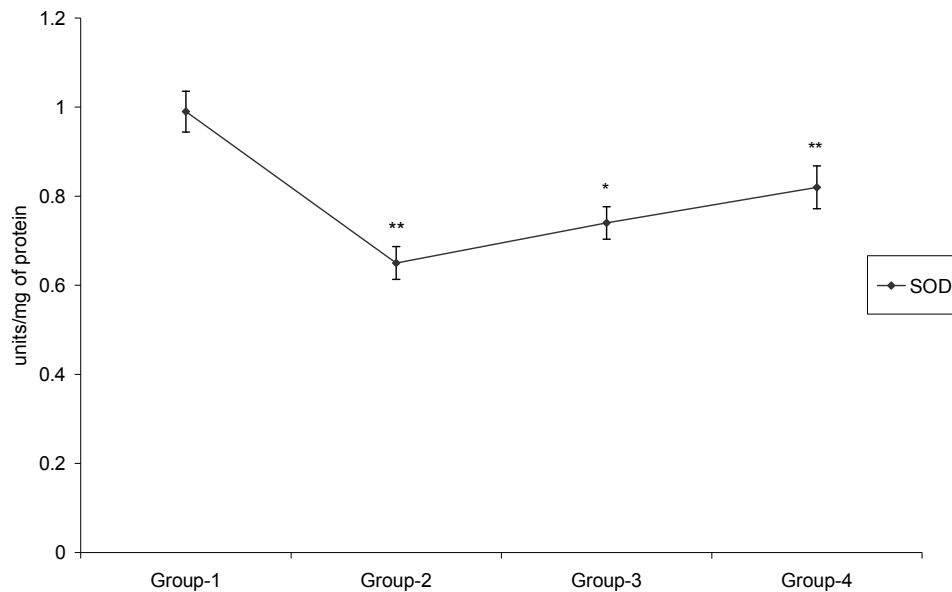


Fig. 5. Effect of treatment with ethanol extract of *Pimpinella tirupatiensis* on renal SOD activity in rats with acetaminophen (APAP)-induced nephrotoxicity. All values are mean \pm S.D., (n = 6). **p < 0.01, *p < 0.05 with respect to control. (One way ANOVA followed by Dunnett's t-test.)

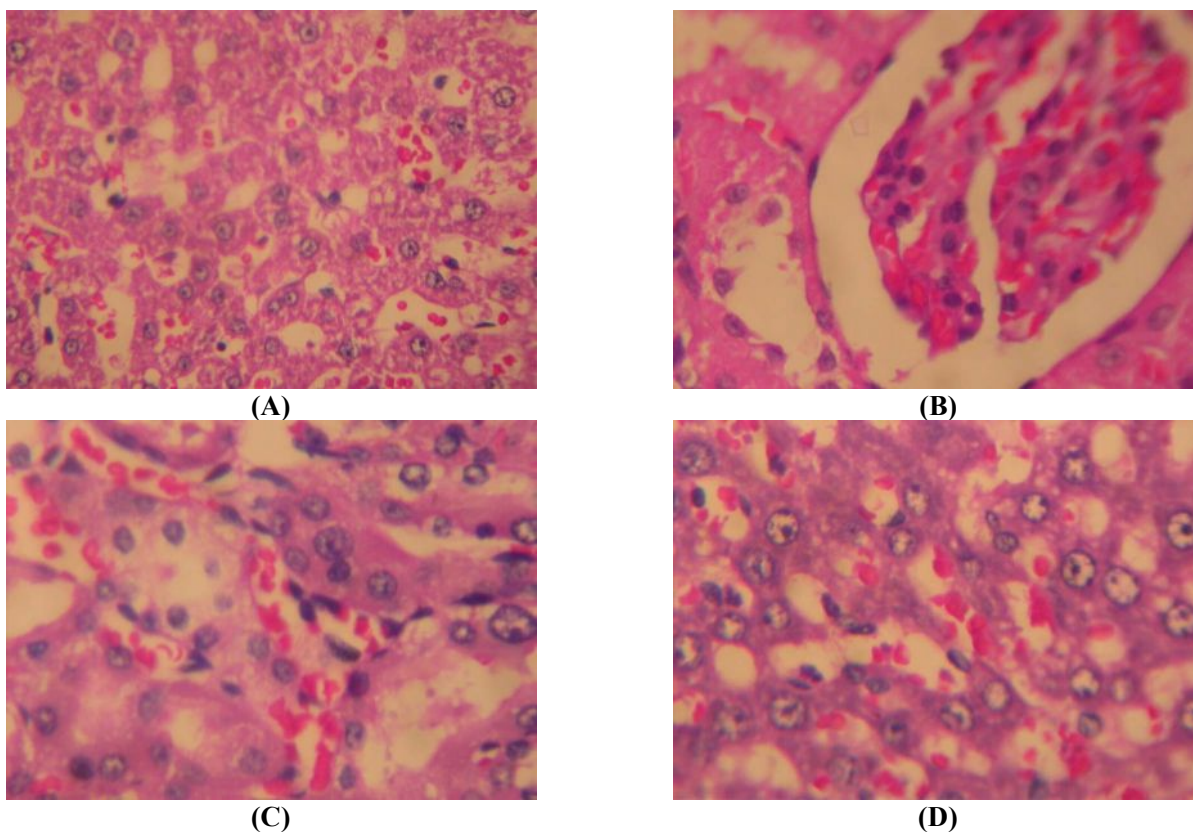


Fig. 6. Nephroprotective effect of *Pimpinella tirupatiensis* extract. Histopathological observations (kidney sections stained with Hematoxylin-Eosin, magnification-100x) (A) Normal, (B) Acetaminophen(APAP), (C) Extract 500mg/kg + APAP, (D) Extract 750 mg/kg + APAP.

REFERENCES

- [1] Yapar K, Kart A, Karapehliyan M, Atakisi O, Tunca R, Erginsoy S, Citil M. Hepatoprotective effect of l-carnitine against acute acetaminophen toxicity in mice. (2007) *Exp and toxicolo pathology*, **59**,121-128.
- [2] Nelson SD. Mechanisms of the formation and disposition of reactive metabolites that can cause acute liver injury. (1995) *Drug Metab. Rev.*, **27**,147-177.
- [3] Boelsterli UA. Specific targets of covalent drug-protein interactions in hepatocytes and their toxicological significance in drug-induced liver injury. (1993), *Drug Met. Res.* **25**, 395-451.
- [4] Holtzman JL. The role of covalent binding to microsomal proteins in the hepatotoxicity of acetaminophen. (1995), *Drug Metab. Rev.* **27**, 277-97.
- [5] Placke ME, Wyand DS, Cohen SD. Extrahepatic lesions induced by acetaminophen in the mouse. (1987) *Toxicol. Pathol.*, **15**, 381-387.
- [6] Trumper L, Monasterolo LA, and Elias MM. Probenecid protects against in vitro acetaminophen-induced nephrotoxicity in male Wistar rats. (1998), *J. Pharmacol. Exp. Therapeut.*, **283**, 606-10.
- [7] Ghosh A, Sil PC. Anti-oxidative effect of a protein from *Cajanus indicus* L. against acetaminophen-induced hepato-nephro toxicity. (2007), *Biochem Mol Biol*, **40**,1039-49.
- [8] Carpenter, H.M., Mudge, G.H. Acetaminophen nephrotoxicity: studies on renal acetylation and deacetylation. (1981), *J. Pharmacol. Exp. Ther.* **218**, 161-167.
- [9] Jones AF, Vale JA. Paracetamol poisoning and the kidney. (1993), *J. Clin. Pharm. Ther.*, **18**, 5-8.
- [10] Eguia L, Materson BJ. Acetaminophen related acute renal failure without fulminant liver failure. (1977), *Pharmacotherapy*; **17**,363-70.
- [11] Ray SD, Mumaw VR, Raje RR, Fariss MW. Protection of AAP-induced hepatocellular apoptosis and necrosis by cholesteryl hemisuccinate pretreatment. (1996), *J. Pharmacol. Experiment. Therapeutics*, **279**, 1470-1483.
- [12] Webster PA, Roberts DW, Benson RW, Kearns GL. Acetaminophen toxicity in children diagnostic confirmation using specific antigen biomarker. 1996, *J. Clin. Pharmacol.* **36**, 397-402.
- [13] Montilla P, Barcos M, Munoz MC, Bujalance I, Munoz-Castaneda JR., and Tunez, I. Red wine prevents brain oxidative stress and nephropathy in streptozotocin-induced diabetic rats. (2005), *J. Biochem. Mol. Biol.* **38**, 539-544.
- [14] Mansour HH, Hafez HF, Fahmy NM. (2006), Silymarin modulates Cisplatin-induced oxidative stress and hepatotoxicity in rats. *J. Biochem. Mol. Biol.* **39**, 656-661.
- [15] El-Beshbishy HA. Hepatoprotective effect of green tea [*Camellia sinensis*] extract against tamoxifen-induced liver injury in rats. (2005), *J. Biochem. Mol. Biol.* **38**, 300-306
- [16] Balakrishnan NP, Subramanyam K, Bull. (1960), *Bot. Surv. India*, 427-428.
- [17] Sudarsanam G, Reddy KB, Nagaraju, N, (1995), Somatic embryogenesis in *Pimpinella tirupatiensis* Bal. and Subr, an endangered medicinal plant of Tirumala Hills. *Int. J. Pharmacog.*, **33**, 52-66.
- [18] Thammanna, Narayana Rao K. (1990), Medicinal Plants of Tirumala, TTD Press, Tirupati, pp. 36-40.
- [19] Vedavathi S, Mrudula V, Sudhakar A. (1997), Tribal Medicine of Chittoor District, AP, Herbal Folklore Research Centre, Tirupati, pp. 110-111.
- [20] Madhava Chetty K, Siraji K, Tulasi Rao K. (2008), Flowering plants of Chittoor district, Andhra Pradesh, India, Student press. Pp.360-368.
- [21] Rajendra Kumar Reddy P, Jayarama Reddy S. (1997), Elemental Concentrations in Medicinally Important Leafy Materials Chemosphere, **34**, 2193-2212.
- [22] Jeevan Ram A, Md. Bhakshu L, Venkata Raju RR. (2004), In Vitro Antimicrobial Activity of Certain Medicinal Plants From Eastern Ghats, India, used for skin diseases. *J of Ethnopharmacol.* **90**, 353-357.
- [23] Bakshu LMD, Venkata Raju RR. Essential oil composition and antimicrobial activity of tuberous roots of *Pimpinella tirupatiensis* Bal. & Subr., (2002), an endemic taxon from eastern ghats, India. *Flavour and Fragrance Journal*, **17**, 413-415.
- [24] Nagaraju N, Rao KN. (1989) *Ancient Science of Life*, **9**, 31-35.
- [25] Chattopadhyay RR. (2003), Possible mechanism of hepatoprotective activity of *Azadirachta indica* leaf extract: Part II. *J Ethnopharmacol.* **89**, 217-19.
- [26] Zhang XZ. Crop Physiology Research Methods. (1992), China Agricultural Press Beijing; pp. 131-207.
- [27] Rai S, Wahile A, Mukherjee K, Saha BP, Mukherjee PK. (2006;), Antioxidant activity of *Nelumbo nucifera* [sacred lotus] seeds. *J Ethnopharmacol.* **104**, 322-27.

- [28] Bergmeyer HU, Gowehn K, Grassel H. In: (1974),Bergmeyer HU, editor. Methods of enzymatic analysis. Weinheim Verlag Chemie pp. 438-39.
- [29] Hafemann DG, Sunde RA, Houestra WG.(1974), Effect of dietary selenium on erythrocyte and liver glutathione peroxidase in the rat. *J Nutr*; **104**, 580-84.
- [30] Carlberg I, Mannervik B.(1975), Glutathione reductase levels in rat brain. *J Biol Chem*; **250**, 5475-79.
- [31] Mohandas J, Marshall JJ, Duggin GG, Horvath JS, Tiller D.(1984), Differential distribution of glutathione and glutathione related enzymes in rabbit kidney: possible interactions in analgesic neuropathy. *Cancer Res* , **44**, 5086-91.
- [32] Lowry OH, Rosebrough NJ, Farr AL, Randal RJ.(1951), Protein measurement with the folin phenol reagent. *J Biol Chem*, **193**, 265-75.
- [33] Bennit WM, Parker RA, Elliot WC, Gilbert D, Houghton D. (1982),Sex related differences in the susceptibility of rat to gentamicin nephrotoxicity. *J of Infec diseases* **145**, 370-74.
- [34] Corcoran GB, Mitchell JR, Vaishnav YN, Horning EC.(1980), Evidence that acetaminophen and N-hydroxyacetaminophen form a common arylating intermediate, N-acetyl-p-benzoquinoneimine. *Mol Pharmacol* **18**,:536-542.
- [35] Dahlin DC, Nelson SD. (1982),Synthesis, decomposition kinetics, and preliminary toxicological studies of pure N-acetyl-p-benzoquinone imine, a proposed toxic metabolite of acetaminophen. *J Med Chem*,**25** ,:885-86.
- [36] Holme JA, Dahlin DC, Nelson SD, Dybing E. (1984), Cytotoxic effects of N-acetyl-pbenzoquinone imine, a common arylating intermediate of paracetamol and N-hydroxyacetamol. *Biochem Pharmacol*,**33** ,:401-06.
- [37] Dahlin DC, Miwa GT, Lu AY, Nelson SD.(1984), N-Acetyl-p-benzoquinone imine: a cytochrome P-450-mediated oxidation product of acetaminophen. *Proc Natl Acad Sci USA*, **81**, 1327-331.
- [38] Streeter AJ, Dahlin DC, Nelson SD,(1984), Baillie TA. The covalent binding of acetaminophen to protein. Evidence for cysteine residues as major sites of arylation in vitro. *Chem Biol Interact*, **48**, 349-66.
- [39] Adeneye AA, Olagunju JA, Benebo AS, Elias SO, Adisa AO, Idowu BO,Oyededeji MO, Isioye EO, Braimoh OB, Oladejo OO, Alana EO. (2008),Nephroprotective effects of the aqueous root extract of *Harungana madagascariensis* [L.] In acute and repeated dose acetaminophen renal injured rats. *Inl Journal of Appl Rese in NatProd*,**1**, 6-14.
- [40] Guyton AC. (1991), Red Blood Cells, Anemia, and Polycythemia. In: Textbook of Medical Physiology. 8th ed. Philadelphia: W.B. Saunders Co,pp. 356 - 64.
- [41] Mayne PD.(1994), The kidneys and renal calculi. In: Clinical chemistry in diagnosis and treatment. 6th ed. London:Edward Arnold Publications, pp.2-24.
- [42] Anwar S, Khan NA, Amin KMY, Ahmad G.(1999), Effects of Banadiq-al Buzoor in some renal disorders. *Hamdard Medicus*, vol. XLII. Hamdard Foundation, Karachi, Pakistan, **4**, 31-36.
- [43] Bennit WM, Parker RA, Elliot WC, Gilbert D, Houghton D.(1982), Sex related differences in the susceptibility of rat to gentamicin nephrotoxicity. *J of Infec diseases*; **145**, 370-74.
- [44] Ali BH, Ben Ismail, TH, Basheer AA. (2001), Sex related differences in the susceptibility of rat to gentamicin nephrotoxicity: influence of gonadectomy and hormonal replacement therapy. *Ind J of Pharmacol*,**33**, 369-73.
- [45] Somani SM, Husain K, Whitworth C, Trammell GL, Malafa, M, Rybak, LP,(2000), Dose-dependent protection by lipoic acid against cisplatin-induced nephrotoxicity in rats: antioxidant defense system. *Pharmacol. Toxicol*,**86**, 234-241.
- [46] Abdel-Zaher OA, Abdel-Rahman M.M, Hafez MM, Omran FM. (2007), Role of nitric oxide and reduced glutathione in the protective effects of aminoguanidine, gadolinium chloride and oleanolic acid against acetaminophen-induced hepatic and renal damage. *Toxicology*; **243**, 124-34.
- [47] Ghosh A, Sil PC. (2007),Anti-oxidative effect of a protein from *Cajanus indicus* L. against acetaminophen-induced hepato-nephro toxicity. *Biochem Mol Biol*, **40**, 1039-49.
- [48] Pande M, Flora SJ.(2002), Lead induced oxidative damage and its response to combined administration of alpha-lipoic acid and succimers in rats. *Toxicology*; **177**,187-96.
- [49] Linares MV, Bellés M, Albina ML, Sirvent JJ, Sánchez, DJ et al.(2006), Assesment of the pro-oxidant activity of uranium in kidney and testis of rats.*Toxicol Lett*,**167**, 152-61.
- [50] Newton J, Hoefle D, Gemborys M, Mugege G, Hook J.(1996), Metabolism and excretion of a glutathione conjugate of acetaminophen in the

- isolated rat kidney. *J. Pharmacol. Exp. Ther.*, **237**, 519-524.
- [51] Richie Jr JP, Long CA, Chen TS.(1992), Acetaminophen-induced depletion of glutathione and cysteine in aging mouse kidney. *Biochem. Pharmacol.*, **44**, 129-135.
- [52] Nelson SD.(1990), Molecular mechanisms of hepatotoxicity caused by acetaminophen. *Semin. Liver Dis*,**10**,267-278.
- [53] Manov I, Hirsh M, Ianccu TC.(2003), Acetaminophen hepatotoxicity and mechanisms of its protection by N-acetylcysteine: a study of Hep3B cells. *Exp. Toxicol. Pathol*,**53**, 489-500.
- [54] Corcoran G, Rac W, Smith G, Mitchell J. (1985), Effect of Nacetylcysteine on acetaminophen covalent binding and hepatic necrosis in mice. *J Pharmacol Exp Ther*; **232**, 864–72.
- [55] Gardner CR, Laskin JD, Dambach DM, Sacco M, Durham SK et al.,(2002), Reduced hepatotoxicity of acetaminophen in mice lacking inducible nitric oxide synthase: potential role of tumor necrosis factor-alpha and interleukin-10. *Toxicol Appl Pharmacol*, **184**, 27–36.
- [56] Newton JF, Bailie MB Hook JB. (1983), Acetaminophen nephrotoxicity in the rat. Renal metabolic activation in vitro. *Toxicol Appl Pharmacol*,**170**, 433-44.
- [57] Trumper L, Monasterolo LA and Elias MM.(1998), Probenecid protects against in vitro acetaminophen induced nephrotoxicity in male Wistar rats. *J Pharmacol Exp Ther*; **283**, 606-10.
- [58] Devipriya S, Shyamaladevim CS. (1999), Protective effect of quercetin in cisplatin induced cell injury in the rat kidney. *Ind J of Pharmacol* , **31**,: 422 –26.
- [59] Annie S, Rajagopal PL, Malini S. (2005), Effect of Cassia auriculata Linn. root extract on cisplatin and gentamicin-induced renal injury. *Phytomedicine* **12**, 555 - 560.
- [60] Kumaran A, Karunnakaran RJ. (2007), In vitro antioxidant activities of methanol extracts of Phyllanthus amarus species from India. *LWT-Swiss Society of Food Science and Technology*; **40**, 344-52.
- [61] Donsky, Howard MD, Clarke, Don MD. (2007), Reliéva.a Mahonia Aquifolium extract for the treatment of adult patients with atopic dermatitis. *Am J Ther* , 14, 442-46.
- [62] Lucia R, Marek O, Daniela K, Viktor K, Lydia B.(2007), Free radical scavenging activity and lipoyxygenase inhibition of Mahonia aquifolium extract and isoquinoline alkaloids. *J Inflamm*, **32**,4:15.
