

on each occasion by the location and size of the cyst<sup>4</sup>. In most cases, the enucleation can be carried out intraorally, as clearly evident in a review of international bibliography, which found that in 120 cysts surgically treated, 70 (58%) were done intraorally, 37 (31%) extraorally, and 13 (11%) via a combination of intra and extraoral approaches<sup>5</sup>. Effective treatment of dermoid and teratoid cyst of the floor of the mouth requires identification and surgical excision of any tracts leading to the midline of the mandible or hyoid bone. Failure to eliminate these epithelium-lined structures is stated to increase risk of recurrence<sup>14,15</sup>. The cyst described here was completely excised by intraoral approach, which was determined by the location of the cysts on higher planes. A broad surgical field was obtained, allowing a blunt dissection and full removal of the cyst, without break of the capsule, reducing the chances of recurrence. On histopathological examination, the presence of gastrointestinal epithelium, along with hair follicles and sebaceous glands in the capsule confirmed the final diagnosis of a teratoid cyst.

## REFERENCES

1. Agaimy A, Raab B, Bonkowsky V, Wünsch PH (2007) Intestinal-type adenocarcinoma arising in a congenital sublingual teratoid cyst. *Virchows Arch* 450:479-481.
2. Azañero WD, Mazzonetto R, León JE, Vargas PA, Lopes MA, de Almeida OP (2009) Lingual cyst with respiratory epithelium: a histopathological and immunohistochemical analysis of two cases. *Int J Oral Maxillofac Surg* 38:388-392.
3. Bonet-Coloma C, Mínguez-Martínez I, Palma-Carrió C, Ortega-Sánchez B, Peñarocha-Diogo M, Mínguez-Sanz JM (2011) Orofacial dermoid cysts in pediatric patients: a review of 8 cases. *Med Oral Patol Oral Cir Bucal* 16:200-203.
4. Celik M, Akkaya H, Arda IS, Hiçsönmez A (2006) Congenital teratoma of the tongue: a case report and review of the literature. *J Pediatr Surg* 41:25-28.
5. Dimtsas S, Theologie-Lygidakis N, Iatrou I (2010) Intralingual dermoid cyst in an infant presenting swallowing and sleeping difficulties. *J Clin Pediatr Dent* 34:335-337.
6. Dutta M, Saha J, Biswas G, Chattopadhyay S, Sen I, Sinha R (2013) Epidermoid cysts in head and neck: our experiences, with review of literature. *Indian J Otolaryngol Head Neck Surg* 65:14-21.
7. Gan K, Fung E, Idikio H, El-Hakim H (2008) A floor of mouth teratoid cyst with tract in a newborn - Case report and English literature review unraveling erroneous quotes and citations. *Int J Pediatr Otorhinolaryngol* 72:1275-1279.
8. Gordon PE, Faquin WC, Lahey E, Kaban LB (2013) Floor-of-mouth dermoid cysts: report of 3 variants and a suggested change in terminology. *J Oral Maxillofac Surg* 71:1034-41.
9. Kinzer S, Mattern D, Ridder GJ (2006) Diagnostic and therapeutic management of a big cyst at the floor of the mouth: the 6 Case Reports in Medicine mouth-a case report. *Laryngo-Rhino-Otologie* 85:827-831.
10. Liang Y, Yang YSh, Zhang Y (2012) Retrospective analysis of ten cases of congenital sublingual teratoid cyst. *Eur J Paediatr Dent* 13:333-6.
11. Lin HW, Silver AL, Cunnane ME, Sadow PM, Kieff DA (2011) Lateral dermoid cyst of the floor of mouth: unusual radiologic and pathologic findings. *Auris Nasus Larynx* 38:650-653.
12. MacNeil SD, Moxham JP (2010) Review of floor of mouth dysontogenic cysts. *Ann Otol Rhinol Laryngol* 119:165-173.
13. Meyer I. Oral pathology: dermoid cysts (dermoids) of the floor of the mouth (1955) *Oral Surg Oral Med Oral Pathol* 8:1149-1164.
14. Pentenero M, Marino R, Familiari U, Gandolfo S (2013) Choristoma involving the floor of the mouth and the anterior tongue: a case of teratoid cyst with gastric and respiratory epithelia. *J Oral Maxillofac Surg* 71:1706-11.
15. Pirgousis P, Fernandes R (2011) Giant submental dermoid cysts with near total obstruction of the oral cavity: report of 2 cases. *J Oral Maxillofac Surg* 69:532-535.

ABCDV/1190

ABCD Arq Bras Cir Dig

2016;29(2):128-129

DOI: /10.1590/0102-6720201600020016

Letter to the Editor

# THIRTY KILOGRAMS GIANT RETROPERITONEAL TERATOMA: CASE REPORT

*Teratoma retroperitoneal gigante de 30 kg: relato de caso*

James **SKINOVSKY**, Fernanda Keiko **TSUMANUMA**,  
Marcos Fabiano **SIGWALT**, Flávio **PANEGALLI-FILHO**,  
Adriana Mitie **KAWAKUBO**, Bruna Gimenes **ROLIM**,  
Luciana Andrade de **GODOY**

From the Hospital da Cruz Vermelha and Universidade Positivo (Red Cross University Hospital and Positivo University), Curitiba, PR, Brazil.

**HEADINGS** - Tumor, teratoma. Retroperitoneal neoplasms.

**Correspondence:**

James Skinovsky

E-mail: skinovsky@gmail.com

Financial source: none

Conflicts of interest: none

Received for publication: 12/02/2015

Accepted for publication: 18/02/2016

 This is an open access article distributed under the terms of the Creative Commons Attribution License.

## INTRODUCTION

**T**eratomas are composed of somatic cells from two or more germ layers (ectoderm, mesoderm or endoderm)<sup>8</sup>. Although the child's age being the most affected, in adults it occurs at different locations, such as mediastinum, sacrococix, retroperitoneum and more often in the gonads<sup>7,13</sup>. Retroperitoneal teratomas in adults are rare, representing only 1-11% of all primary tumors in that anatomic region<sup>9</sup>, generally are benign and asymptomatic in the first stages. However when symptoms occur, they are typically due to their size, presenting with abdominal distension and a palpable mass<sup>12</sup>. Diagnosis can be made by ultrasound, that can identify solid or cystic components, computerized tomography and magnetic resonance imaging, which are both superior than ultrasound to evaluate tumoral extension and relation to adjacent organs<sup>2,4,5,12,13</sup>. Angiography can be used to detect and evaluate the blood supply. In this article, it is presented a case of a giant retroperitoneal treated with surgical resection.

## CASE REPORT

A 42-year-old male was suffering from an insidious abdominal distention for the last 13 years, that was more remarkable in the initial three years. There was no fever, abdominal pain, or bowel complaints. He denied smoking or drinking abuse. There was not any kind of disease in patient's past or family medical history. He had been treated with spironolactone years before, with no previous investigation, and it was suspended by the occurrence of gynecomastia. On admission, he was clinically in good condition, and presenting an important abdominal distention without tenderness, and bowel sounds preserved. The rest of the examination was unremarkable. Admission laboratory tests showed no abnormalities. An abdominal computerized tomography revealed a mass occupying all regions in the abdominal cavity, showing no apparent origin. The patient underwent exploratory laparotomy that showed a mass weighing approximately 30 kilograms (Figure 1), whose origin was in the retroperitoneum completely displacing the

left kidney to the right iliac fossa. The patient did well post-operatively and is currently asymptomatic and has been followed as an outpatient. Histopathological analysis demonstrated heterogeneous contents, with predominant cystic formations and other unctuous and soft components, and the diagnosis of mature teratoma was confirmed by microscopy (Figure 2).

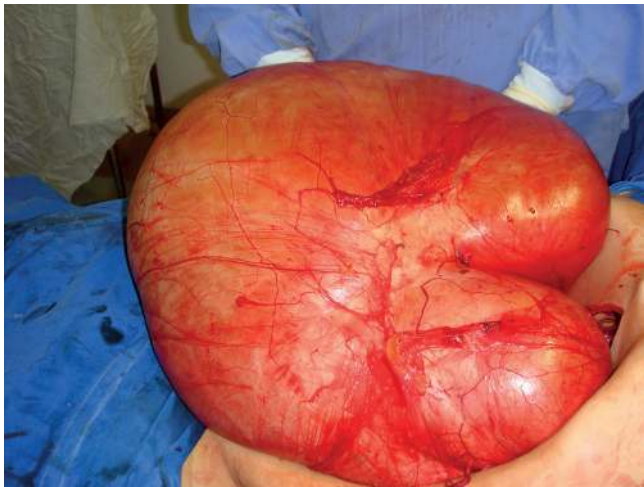


FIGURE 1 – Surgically resected giant retroperitoneal tumor weighing approximately 30 kilograms

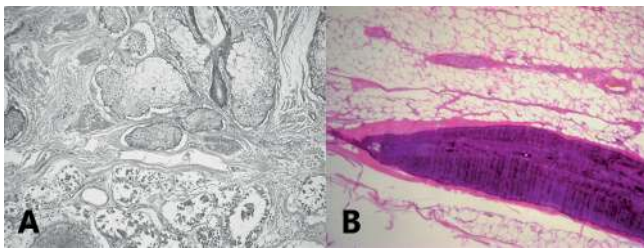


FIGURE 2 – A) Elements from the cyst wall: cutaneous epidermis, dermis with sebaceous glands and apocrine sweat glands, adipose tissue; B) fragment of mineralized bone tissue (Courtesy: Doctor Lisiane Cristine, Citolab, Curitiba, PR, Brazil)

## DISCUSSION

Histologically, teratomas are classified as mature or immature, and the mature type, which was described in this case, has the most common occurrence<sup>3,7,8</sup>. Mature teratomas are usually cystic, benign and have well-differentiated elements, resembling adult tissues, as can be observed in the case as well.

Migratory property of the germ cells may explain the occurrence of teratomas in extragonadal sites. The retroperitoneum account for approximately 5% of teratomas and are responsible for less than 10% of the retroperitoneal neoplasms. In the retroperitoneal space, teratomas have a predilection for the upper pole of the kidney and are frequently located on the left side<sup>12,13</sup>. In this case, the tumor was located in retroperitoneum, completely displacing the left kidney to the right iliac fossa due to its large volume.

This type of tumor can affect both children and adults, exhibiting different behavior between the two groups. With higher incidence in the retroperitoneal region in children, less than 20% of patients develop these tumors by the age of thirty, though the patient in this case was in the fourth decade of life at diagnosis. Considering gender, teratomas at a retroperitoneal location affect approximately twice as many women than men<sup>1,8,13</sup>.

Most of the patients are asymptomatic and when the tumor compresses adjacent structures, due to its growth, it can

bring pain, bloating, nausea and vomiting. Malignant teratomas tend to progress more quickly and occur more frequently in adults than in children, with incidences of 26% and 10%, respectively<sup>8,13</sup>. In this case, the only complaint the patient had was an insidious abdominal distention, no other complaints, as would be expected due to the size of the tumor found and the compression of adjacent structures. Computerized tomography was the imaging method used for the diagnosis and to plan the surgical procedure, which is, according to the literature<sup>2,4,5,12,13</sup>, one of the best methods, like magnetic resonance imaging, compared to ultrasound. The final diagnosis was made with the histopathological analysis after surgery.

Pinson et al<sup>11</sup>, on a long-term study, showed that complete resection is associated with improved survival rates for primary retroperitoneal tumors in general. A disease-free survival is related to complete resection because of the risk of malignant teratoma or carcinoma to sarcoma. The patient underwent complete excision of the tumor and is currently asymptomatic and being followed as an outpatient. Testicular ultrasound is necessary to rule out a coexisting testicular germ cell tumor in male patients, because 50% of men presenting a retroperitoneal tumor also have testicular carcinoma in situ, a precursor for testicular germ cell tumors<sup>6</sup>.

## REFERENCES

1. Bahrami A, Ro JY, Ayala AG. An overview of testicular germ cell tumors. *Archives of pathology & laboratory medicine* [Internet]. 2007 Aug;131(8):1267–80. Available from: <http://www.ncbi.nlm.nih.gov/pubmed/17683189>
2. Bellin MF, Duron JJ, Curet P, Dion-Voirin E, Grellet J. Primary retroperitoneal teratoma in the adult: correlation of MRI features with CT and pathology. *Magn Reson Imaging*. 1991;9:263-6.
3. Chong HMD, Lee FYJ, Lo A, Li CMJ. A giant gas-filled abdominal mass in an elderly female: a case report. *World journal of gastroenterology : WJG* [Internet]. 2011 Aug 21 [cited 2012 Sep 30];17(31):3659–62. Available from: <http://www.pubmedcentral.nih.gov/articlerender.fcgi?artid=3180025&tool=pmcentrez&rendertype=abstract>
4. Davidson AJ, Hartman DS, Goldman SM. Mature teratoma of the retroperitoneum: radiologic, pathologic, and clinical correlation. *Radiology*. 1999;172:421-5.
5. GarkKP, JaswalV, JainKB. Retroperitoneal Benign Mature Teratoma. 2011 July. Available from: <http://www.inaactamedica.org/archives/2011/21979287.pdf>
6. Gatcombe H, Assikis D, Kooby D, Johnstone P. Primary retroperitoneal teratomas: a review of the literature. *Journal of Surgical Oncology*. 2004; 86(2):107-113.
7. Liu H, Li W, Yang W, Qi Y. Giant retroperitoneal teratoma in an adult. *American journal of surgery* [Internet]. 2007 Jun [cited 2012 Sep 30];193(6):736–7. Available from: <http://www.ncbi.nlm.nih.gov/pubmed/17512286>
8. Mathur P, Lopez-Viego M a, Howell M. Giant primary retroperitoneal teratoma in an adult: a case report. *Case reports in medicine* [Internet]. 2010 Jan [cited 2012 Sep 30];2010:3–5. Available from: <http://www.pubmedcentral.nih.gov/articlerender.fcgi?artid=2938464&tool=pmcentrez&rendertype=abstract>
9. Mathur P, Lopez-Viego M, Howell M. Giant primary retroperitoneal in an adult: a case report. Hindawi Publishing Corporation. *Case Reports in Medicine*. 2010. Available from: <http://www.hindawi.com/crim/medicine/2010/650424/>
10. Pandya JS, Pai MV, Muchhala S. Retroperitoneal teratoma presenting as acute abdomen in an elderly person. *Indian J Gastroenterol*. 2000;19:89-90.
11. Pinson C, ReMine SG, Fletcher WS, Braasch JW. Long-term Results With Primary Retroperitoneal Tumors. *Arch Surg*. 1989;124(10):1168-1173. doi:10.1001/archsurg.1989.01410100070012
12. Sarin YK. Peritonitis caused by rupture of infected retroperitoneal teratoma. *APSP journal of case reports* [Internet]. 2012 Jan;3(1):2. Available from: <http://www.pubmedcentral.nih.gov/articlerender.fcgi?artid=3418036&tool=pmcentrez&rendertype=abstract>
13. Taori K, Rathod J, Deshmukh a, Sheorain VS, Jawale R, Sanyal R, et al. Primary extragonadal retroperitoneal teratoma in an adult. *The British journal of radiology* [Internet]. 2006 Oct [cited 2012 Sep 30];79(946):e120–2. Available from: <http://www.ncbi.nlm.nih.gov/pubmed/16980665>