

Three-dimensional CT of Eagle's syndrome

Ahmet Savranlar, Lokman Uzun, Mehmet Birol Uğur, Tülay Özer

ABSTRACT

This case report presents three-dimensional computed tomography (3D-CT) findings in the diagnosis of Eagle's syndrome that is characterized with an elongated styloid process or a calcified stylohyoid ligament causing craniofacial or cervical pain. We have performed 3D-CT in three patients suspected to have this condition. Coronal images were taken in two patients and axial images in one patient with a spiral CT scanner. 3D-CT images were then produced. The length of the styloid process in the case suspected of right elongated styloid process was 45.6 mm (left styloid process, 37 mm). In the second case suspected of left elongated styloid process, the length of the left styloid process was 41.1 mm (right styloid process, 40.2 mm). In the last case suspected of right elongated styloid process, the length of the right styloid process was 40.6 mm (left styloid process, 38.9 mm). 3D-CT is a valuable diagnostic tool in the diagnosis of Eagle's syndrome because of its ability to facilitate accurate measurement of the length of the styloid process.

Key words: • facial pain • tomography, spiral computed
• imaging, three dimensional

Eagle's syndrome is characterized by craniofacial or cervical pain due to an elongated styloid process or calcified stylohyoid ligament. Patients with Eagle's syndrome may present with a sore throat, ear pain, or even with foreign body symptoms in the pharynx secondary to pharyngeal and cervical nerve interactions. Eagle first described clinical findings of this syndrome in 1937 (1). As the diagnosis is not very easy, it is reported that the number of cases are underestimated in the population (2). Since the symptoms are variable and non-specific, patients seek treatment in several different clinics such as otolaryngology, family practice, neurology, neurosurgery, psychiatry, and dentistry.

Although conventional radiographs provide a rough idea of the anatomy, it is difficult to get to the actual diagnosis due to superimposed anatomical structures. In imaging the head and neck region in particular, three-dimensional computed tomography (3D-CT) has several advantages over conventional coronal and axial CT images. 3D-CT is an extremely valuable imaging tool in head and neck pathologies because of its ability to accurately image the anatomy and help tailor the surgical plan (3). In this study, 3 different cases with Eagle's syndrome are presented in which the syndrome was clinically suspected and then diagnosed, primarily with the help of 3D-CT.

Case reports

Three cases with symptoms of Eagle's syndrome presented to the otolaryngology clinic and underwent 3D-CT imaging. Using a spiral CT scanner (Secura, Philips Medical Systems, Best, the Netherlands), the images were obtained in the coronal plane in prone position in two cases (Cases 1 and 2) and in the axial plane in supine position in one case (Case 3). The CT parameters chosen were 120 kV and 200 mAs. Post-processing of the raw data was performed at a workstation terminal (Easy Vision, Version 5.1.1.2, Philips Medical Systems, Best, the Netherlands) using 'shaded surface' and 'volume rendering' software. The lengths of the styloid processes were then measured accurately on 3D reconstructions. Surgical treatment was recommended in all three cases with Eagle's syndrome.

Case 1

A 36-year-old man with a prior history of tonsillectomy dating back 3 years presented with a sore throat prominent on the right side of the pharynx, ear pain, and difficulty in swallowing solid foods. Physical examination and the medical history were highly suggestive of Eagle's syndrome; therefore, 3D-CT was ordered. Two-millimeter slice thickness and 3 mm slice gap were chosen in coronal plane, which was then reconstructed in 1 mm slices. In 3D-CT reconstructed images, the right

From the Departments of Radiology (A.S. ✉ savranlar@yahoo.com, T.Ö.), and Otorhinolaryngology (L.U., M.B.U.) Zonguldak Karaelmas University School of Medicine, Zonguldak, Turkey.

Received 4 May 2005; revision requested 30 June 2005; revision received 2 July 2005; accepted 5 July 2005.

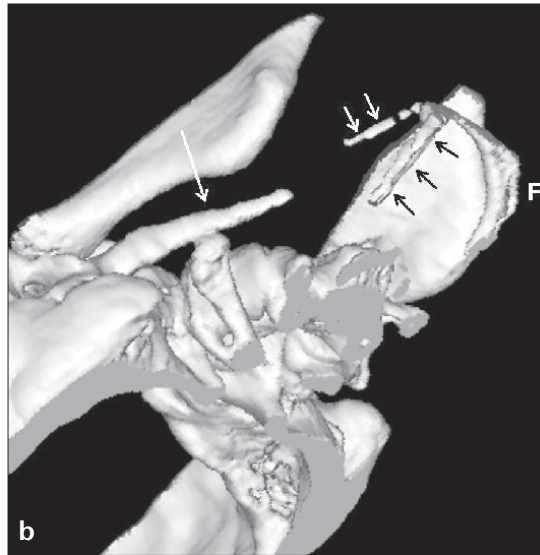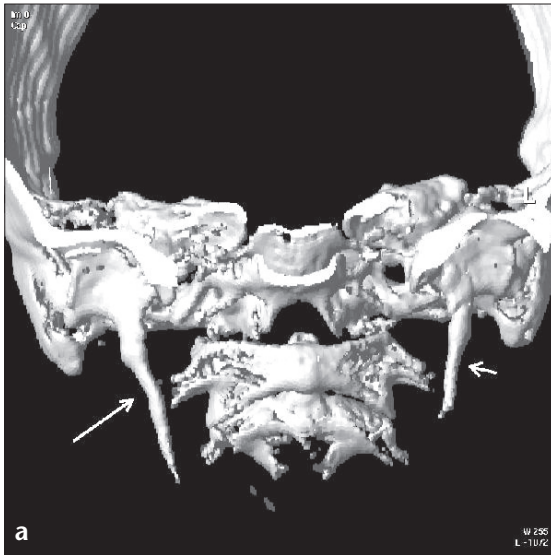


Figure 1. a, b. 3D-CT images of a 36-year-old male. **a.** Demonstration of bilateral styloid processes from the anterior aspect of the skull (the mandible was excluded). The right styloid process (45.6 mm) (*long arrow*) is significantly longer than the left (37 mm) (*short arrow*). **b.** Inferior-oblique view of the same case shows the right styloid process (*long white arrow*), the hyoid bone (*black arrows*), and the stylohyoid ligament calcification (*short white arrows*).

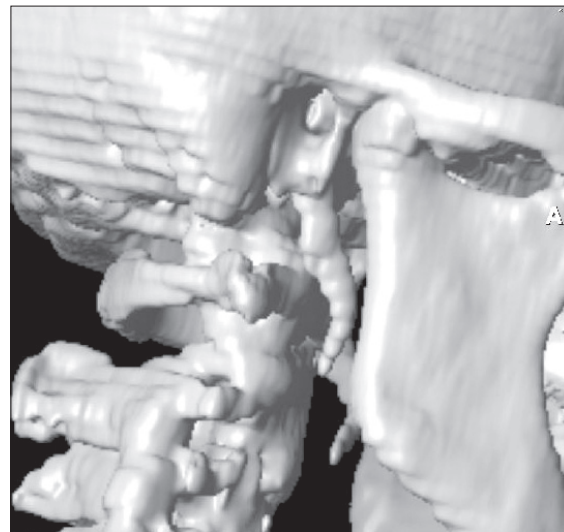
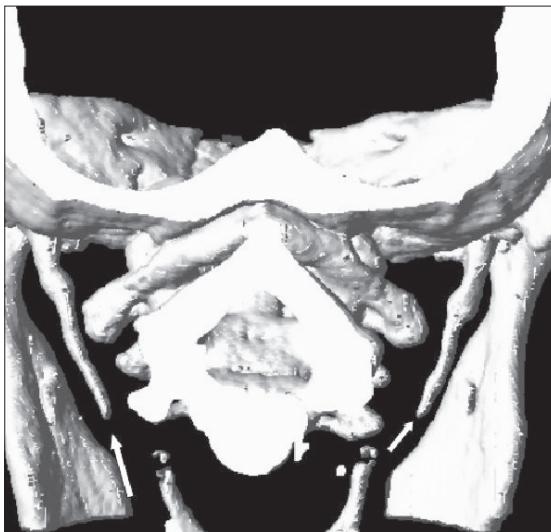

Figure 2. 3D-CT image. The left styloid process (41.1 mm) (*long arrow*) is slightly longer than the right (40.2 mm) (*short arrow*) in a 35-year-old woman.

Figure 3. Right lateral 3D-CT image of a 53-year-old female that shows the styloid processes. Stepping artifact due to slice thickness does not interfere with the diagnostic quality of the image.

styloid process was measured as 45.6 mm and the left styloid process was 37 mm. The mandible was excluded in the post-processing step, and by this, styloid processes were well visualized in the reformatted images (Figure 1a). Calcification of the stylohyoid ligament was also noted at its insertion point to the hyoid bone (Figure 1b).

Case 2

A 35-year-old woman who had been complaining of discomfort at the left submandibular area was found to have a local tenderness at palpation. Ultra-

sonographic evaluation of the area was unremarkable. Eagle's syndrome was suspected from the clinical picture. CT was taken at 2 mm slice thickness and 3 mm slice gap in coronal plane, which was then reconstructed in 1 mm slices. Final 3D-CT images showed that the left styloid process was slightly longer than the right, 41.1 mm and 40.2 mm, respectively (Figure 2).

Case 3

A 53-year-old woman with a history of sore throat with referred pain to both ears, and painful swallowing

for almost ten years was suspected to have Eagle's syndrome. With 3 mm slice thickness, 3 mm slice gap, and 3 mm reconstructions, CT was taken in the axial plane. The 3D-CT images reformatted from the raw axial images showed bilateral elongated styloid processes measuring 40.6 mm and 38.9 mm on the right and the left, respectively (Figure 3).

Discussion

The styloid process, stylohyoid ligament, and the small horn of the hyoid bone form the stylohyoid apparatus,

which originally derives from the Reichert cartilage of the second brachial arch during embryogenesis. The styloid process, the thin and long osseous part of the temporal bone, lies caudally, medially, and anteriorly towards the maxillo-vertebro-pharyngeal recess, which involves the carotid arteries, internal jugular vein, facial nerve, glossopharyngeal nerve, and the vagal and hypoglossal nerves (4).

The length of the styloid process is variable. Kaufman et al. reported that 30 mm is the upper limit for normal styloid processes (2). Moffat et al. performed a cadaver study on the styloid process and reported that the normal length is between 1.52 cm and 4.77 cm (5). Monsour and Young concluded that the diagnosis of an elongated styloid process could be made whenever the styloid process was longer than 40 mm (6). In radiological studies, the length of the styloid process is reported to be no longer than 25 mm (7). In our cases, 4 out of 6 styloid processes were longer than 40 mm, whereas the remaining 2 styloid processes were close to 40 mm in length. Thus, all our styloid processes were accepted as elongated styloid processes. Calcification of the stylohyoid ligament can also be seen (4). In one of our cases (Case 1), this condition was demonstrated in 3D-CT (Figure 1b).

Because of an elongated styloid process or a calcified stylohyoid ligament, a patient with Eagle's syndrome may develop non-specific pain, which may change with head movements at the ear or neck. Additionally, a patient with an elongated styloid process may have referred pain to the jaw joint or upper extremities, or dysphagia or foreign body-like irritation throughout the pharynx (8).

Prevalence of Eagle's syndrome in the population is reported to be 4% and is more frequent among women (1, 9). Most patients with Eagle's syndrome are more than 50 years old (7). Two of our cases were middle aged (35 and 36 years old) and the other one was 53 years old.

There are several different theories, which try to explain the etiopathology of Eagle's syndrome such as congenital elongation of the styloid process and calcification and ossification of the stylohyoid ligament (1, 8). Fini et al. reported that past tonsillectomy is somehow related to Eagle's syndrome

(4). One of our cases (Case 1) had a tonsillectomy in his past medical history as well. Although it is common to have elongated styloid processes bilaterally, symptoms tend to be unilateral (10). All three of our cases had bilateral elongated styloid processes. However, only one patient (Case 3) had bilateral symptoms. The remaining two cases had symptoms only at the site of the longer styloid process.

In differential diagnosis, laryngopharyngeal dysesthesia has to be considered as well as dental malocclusion, neuralgia of sphenopalatine ganglia, temporomandibular arthritis, glossopharyngeal and trigeminal neuralgia, chronic tonsillo-pharyngitis, hyoid bursitis, Sluder's syndrome, histamine cephalgia, cluster type headache, esophageal diverticula, temporal arteritis, cervical vertebral arthritis, benign or malign neoplasms, and migraine type headache (10).

Several imaging modalities have been used for the diagnosis of Eagle's syndrome thus far, including lateral head and neck radiograph, Towne radiograph, panoramic radiograph, lateral-oblique mandible plain film, anteroposterior head radiograph, and CT. Also, barium swallow studies can show the indentation of the elongated styloid process as a filling defect (11). Despite the valuable information about the anatomy, there are some difficulties in reading the plain radiographs secondary to superimposed anatomical structures. Superimposition of the mandible and the teeth can cause difficulty in viewing the styloid process, especially if it is not very long. Again, calcification of the stylohyoid ligament is difficult to evaluate for actual diagnosis in plain films. Superimposition of several osseous structures, and distortion and magnifications secondary to angulations are the potential disadvantages of conventional radiographs and, in particular, panoramic films (12). In CT imaging, those drawbacks are eliminated. 3D-CT images reformatted from the raw data obtained with a spiral scanner provide all the information about the styloid process, including its length, direction, and anatomical relations. 3D-CT is an objective diagnostic tool used to outline the anatomy, tailor the surgical plan, and offer a detailed explanation to the patients as well (3). Another advantage of the 3D-CT images is, of course, three dimensional

length measurements, which are impossible in 2D images such as in coronal or axial planes. In cross-sectional imaging, even in coronal plane, most of the time the images will not be parallel to the SP, which leads to underestimation of the actual length of the styloid process. There was no single CT slice completely parallel to the styloid process in our two cases in whom CT images were obtained in the coronal plane. We were able to visualize the entire styloid process only in 3D-CT and then accurately measure their lengths.

The image quality in all our three cases was good enough to make the diagnosis. We encountered some stepping artifact in Case 3, in which CT was performed in the axial plane with relatively large slice thickness compared to the other two cases (Figure 3). However, this did not interfere with the diagnostic quality of the images.

In conclusion, 3D-CT is a valuable diagnostic imaging tool in patients with Eagle's syndrome that allows clinicians to evaluate the styloid process in spatial geometry, make accurate length measurements, and explain the problem in detail to patients, all of which make this technique superior to conventional imaging modalities.

References

1. Eagle WW. Elongated styloid process: report of two cases. *Arch Otolaryngol* 1937; 25:584-586.
2. Kaufman SM, Elzay RP, Irish EF. Styloid process variation: radiologic and clinical study. *Arch Otolaryngol* 1970; 91:460-463.
3. Nakamaru Y, Fukuda S, Miyashita S, Ohashi M. Diagnosis of the elongated styloid process by three-dimensional computed tomography. *Auris Nasus Larynx* 2002; 29:55-57.
4. Fini G, Gasparini G, Filippini F, Becelli R, Marcotullio D. The long styloid process syndrome or Eagle's syndrome. *J Craniomaxillofac Surg* 2000; 28:123-127.
5. Moffat DA, Ramsden RT, Shaw HJ. The styloid process syndrome: aetiological factors and surgical management. *J Laryngol Otol* 1977; 91:279-294.
6. Mansour P, Young WJ. Variability of the styloid process and stylohyoid ligament in panoramic radiographs. *Arch Otolaryngol* 1986; 61:522-526.
7. Montalbetti L, Ferrandi D, Pergami P, Savoldi F. Elongated styloid process and Eagle's syndrome. *Cephalalgia* 1995; 15:80-93.
8. Balbuena L, Hayes D, Ramirez SG, Johnson R. Eagle's syndrome (elongated styloid process). *South Med J* 1997; 90:331-334.
9. Prasad KC, Kamath MP, Reddy KJ, Raju K, Agarwal S. Elongated styloid process (Eagle's syndrome): a clinical study. *J Oral Maxillofac Surg* 2002; 60:171-175.

10. Harma R. Stylalgia: clinical experiences of 52 cases. *Acta Otolaryngol* 1966; 224:149.
11. Dayal V, Morrison MD, Dickson TJM. Elongated styloid process. *Arch Otolaryngol* 1971; 94:174-175.
12. Ferrario VF, Sigurta D, Daddona A, et al. Calcification of the stylohyoid ligament: incidence and morphoquantitative evaluations. *Oral Surg Oral Med Oral Pathol* 1990; 6:524-529.