

# Three- /Four-dimensional Ultrasound for the Assessment of Ovarian Tumors

Juan L Alcázar

## ABSTRACT

**Background:** Adnexal masses are a common clinical problem in gynecology. Most adnexal masses are benign, but few of them are malignant. An accurate diagnosis is essential for adequate management. There is a possibility to make a distinction between benign and malignant adnexal masses using two-dimensional grayscale ultrasound (2D-US) and color Doppler ultrasound, which are the best imaging techniques for that purpose.

**Objective:** To review current state-of-art of 3D/4D ultrasound in assessing ovarian masses.

**Materials and methods:** Narrative review of literature published from 1995 to 2017 using 3D/4D ultrasound for assessing adnexal masses masses.

**Results:** Three-dimensional ultrasound (3D-US) has become a routine practice in many gynecologic ultrasound laboratories because it overcomes the limitations of two-dimensional ultrasound (2D-US). This technique allows a surface rendering of the internal aspect of the cyst's wall. It can also present the masses in new different ways, such as "inversion mode" or "silhouette mode" or it can represent the vascular tree of the tumor using a 3D reconstruction, or even allowing a unique way for estimating the amount of vessels within the tumor or a part of the tumor. The reproducibility of 3D-US performed by different sonographers has been assessed in several studies. All of them have found that this technique is reproducible among different observers. The main limitations of all the studies are a few cases compared to the high prevalence of malignancies.

**Conclusion:** 3D-US probably have better diagnostic performance than 2D-US assessing malignancies in adnexal masses. However, better-designed studies are needed to draw definitive conclusions.

**Keywords:** Four-dimensional ultrasonography, Ovarian neoplasms, Three-dimensional ultrasonography.

*Donald School Journal of Ultrasound in Obstetrics and Gynecology* (2019): 10.5005/jp-journals-10009-1608

## INTRODUCTION

Adnexal masses are a common clinical problem in gynecology. Most adnexal masses are benign, but few of them are malignant. An accurate diagnosis is essential for adequate management. There is a possibility to make a distinction between benign and malignant adnexal masses using two-dimensional ultrasound (2D-US) and color Doppler ultrasound, which are the best imaging techniques for that purpose.<sup>1</sup> However, there is still a group of masses difficult to classify.<sup>2</sup>

Three-dimensional ultrasound has become a routine practice in many gynecologic ultrasound laboratories because it overcomes the limitations of 2D-US.<sup>3</sup> This technique allows a surface rendering of the internal aspect of the cyst's wall. It can also present the masses in new different ways, such as "inversion mode" or "silhouette mode" or it can represent the vascular tree of the tumor using a 3D reconstruction, or even allowing a unique way for estimating the amount of vessels within the tumor or a part of the tumor.<sup>4</sup>

In this article, we review the role of three-dimensional ultrasound (3D-US) in the evaluation of adnexal masses.

## THREE-DIMENSIONAL GRAYSCALE ULTRASOUND

Grayscale 3D-US aims to depict the macroscopic features of a given adnexal mass by using different ways of renderization.

Using surface rendering, Bonilla-Musoles et al. reported that 3D-US enabled the visualization of papillary projections in the inner surface of the mass missed in 7% of the cases by 2D-US. They found that the sensitivity of 3D-US was higher compared to 2D-US (100% and 80%, respectively) and specificity was similar for both techniques (100% and 99%, respectively).<sup>5</sup> However,

---

Department of Obstetrics and Gynecology, Clinica Universidad de Navarra, School of Medicine, Pamplona, Spain

**Corresponding Author:** Juan L Alcázar, Department of Obstetrics and Gynecology, Clinica Universidad de Navarra, School of Medicine, Pamplona, Spain, Phone: +34 948245400, e-mail: jlacazar@unav.es

**How to cite this article:** Alcázar JL. Three- /Four-dimensional Ultrasound for the Assessment of Ovarian Tumors. *Donald School J Ultrasound Obstet Gynecol* 2019;13(4):229–235.

**Source of support:** Nil

**Conflict of interest:** None

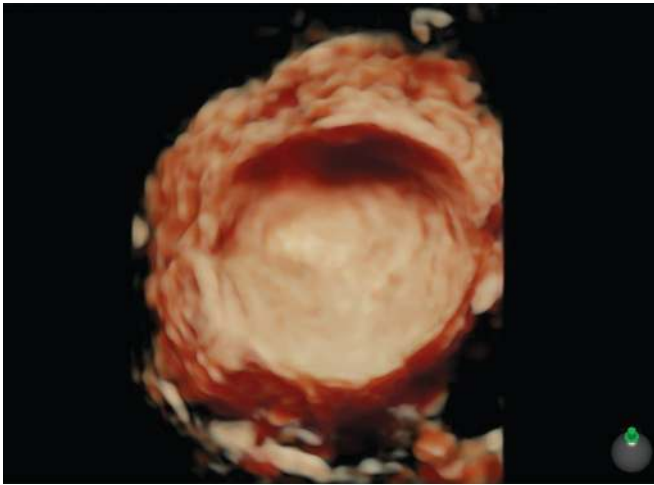
---

Hata et al., using a similar approach, found that 3D-US showed higher specificity than 2D-US (92.3% and 38.4%, respectively) with identical sensitivity (100%).<sup>6</sup>

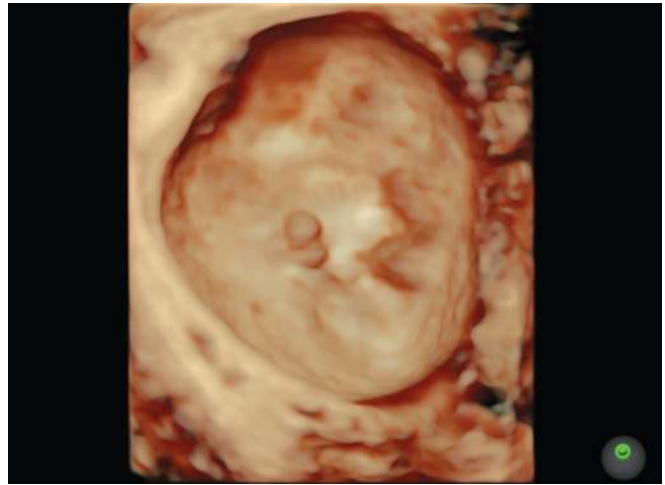
Forty-one women with complex adnexal masses detected by Alcázar et al. on 2D-US underwent 3D-US for further assessment.<sup>7</sup> They found that 3D-US showed better sensitivity (100% vs 90%) and specificity (78% vs 61%) than 2D-US for predicting ovarian malignancy, although the differences did not show statistical significance. However, 3D-US reinforced examiner's diagnostic impression (Figs 1 to 4). Laban et al. also observed that 3D-US was more sensitive (90% vs 81%) and specific (84% vs 79%) than 2D-US.<sup>8</sup>

The main limitations of these studies are a few cases in comparison with the high prevalence of malignancy.

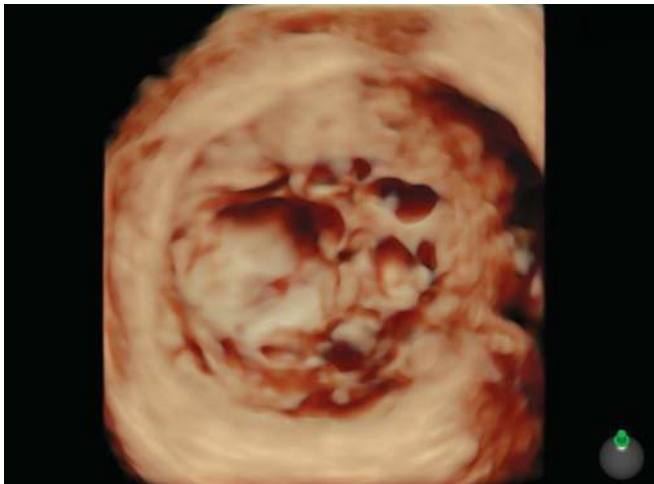
Several studies have assessed the reproducibility of 3D-US performed by different sonographers in several studies. All of them have found that this technique is reproducible among different observers.<sup>9–11</sup>



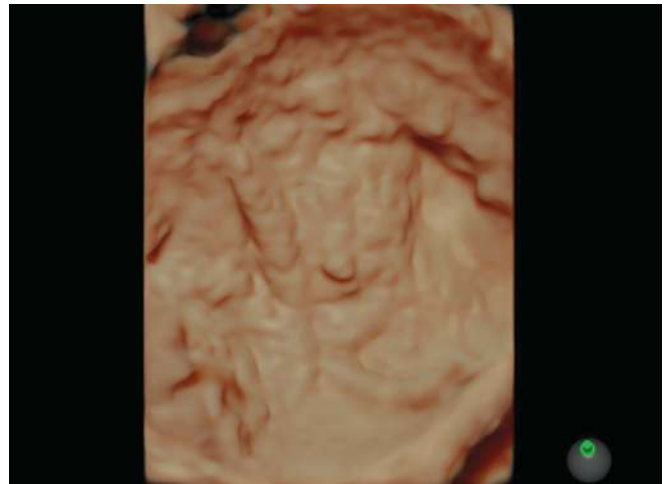
**Fig. 1:** Three-dimensional surface rendering of an ovarian simple cyst. A smooth internal wall is clearly observed. Histology revealed a serous cystadenoma



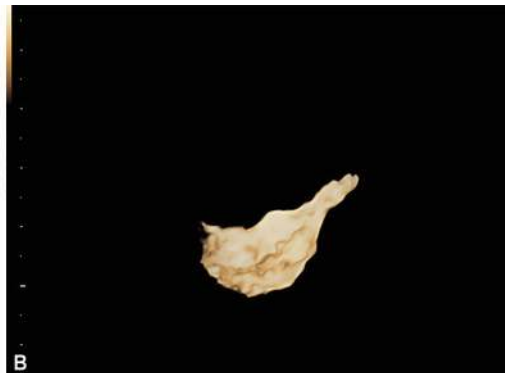
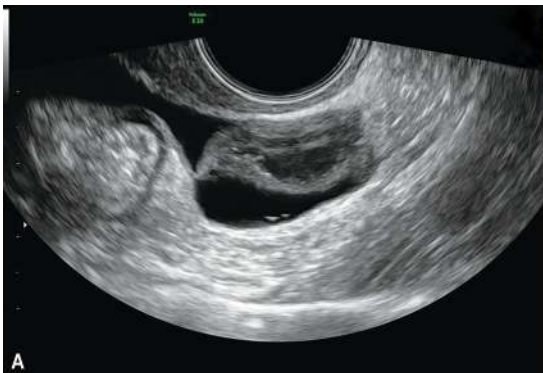**Fig. 2:** Three-dimensional surface rendering of an ovarian cyst. In this case, a papillary projection arising from the internal wall is observed. Histology revealed a serous cystadenofibroma



**Fig. 3:** Three-dimensional surface rendering of a multilocular ovarian cyst. Different locules are seen. Histology revealed a mucinous cystadenoma



**Fig. 4:** Three-dimensional surface rendering of a unilocular ovarian cyst showing an irregular internal surface. Histology revealed a serous borderline cystadenoma



**Figs 5A and B:** (A) Transvaginal ultrasound of a hydrosalpinx; (B) The same lesion as observed using the "inversion mode" on three-dimensional ultrasound

In conclusion, after reviewing these studies, 3D-US probably have better diagnostic performance than the 2D-US for prediction of malignancies in adnexal masses, hence better-designed studies are needed to draw definitive conclusions.

There are some reports have assessed the role of other rendering modes. Hydrosalpinx could be diagnosed by the use of inverted mode as shown by Timor-Tirtsch et al.<sup>12</sup> (Fig. 5). Ovarian endometrioma can be easily diagnosed by 2D-US if the so called



mean gray value is calculated while objectively analyzing the content of the cyst, as shown by Alcázar et al.<sup>13</sup>

### THREE-DIMENSIONAL POWER DOPPLER ULTRASOUND

Kurjak et al. in their pioneering work<sup>14</sup> used three-dimensional power Doppler ultrasound (3D-PDU) for the differential diagnosis

of ovarian tumors, and since then there are many reports using this technique for the same purpose.

Three-dimensional power Doppler angiography (3D-PDA) is a powerful tool for a depiction of the vessel tree of ovarian tumors. The examiner can analyze the reconstructed vascular tree<sup>14</sup> (Figs 6 and 7). Dedicated software three-dimensional power Doppler can be used to calculate from the tissue or organ indices using the manual mode (Fig. 8) or the spherical mode (Fig. 9).

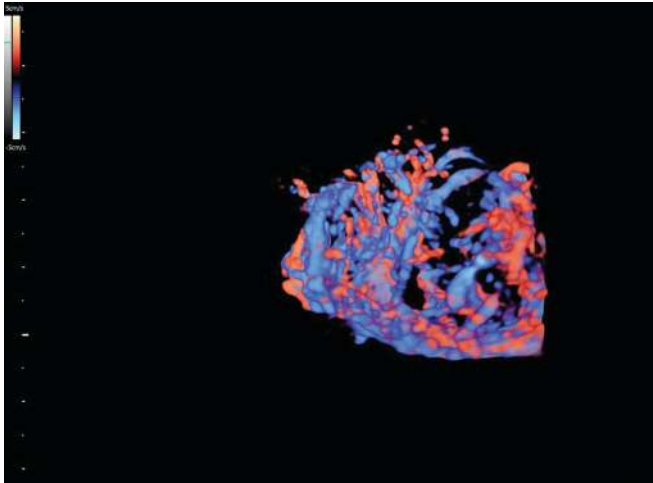


Fig. 6: Three-dimensional reconstruction of the vessel tree from an ovarian cancer. The chaotic distribution of vessels is shown

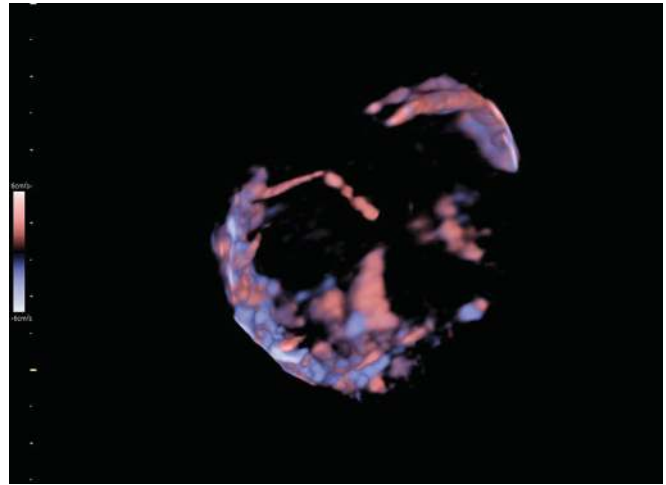
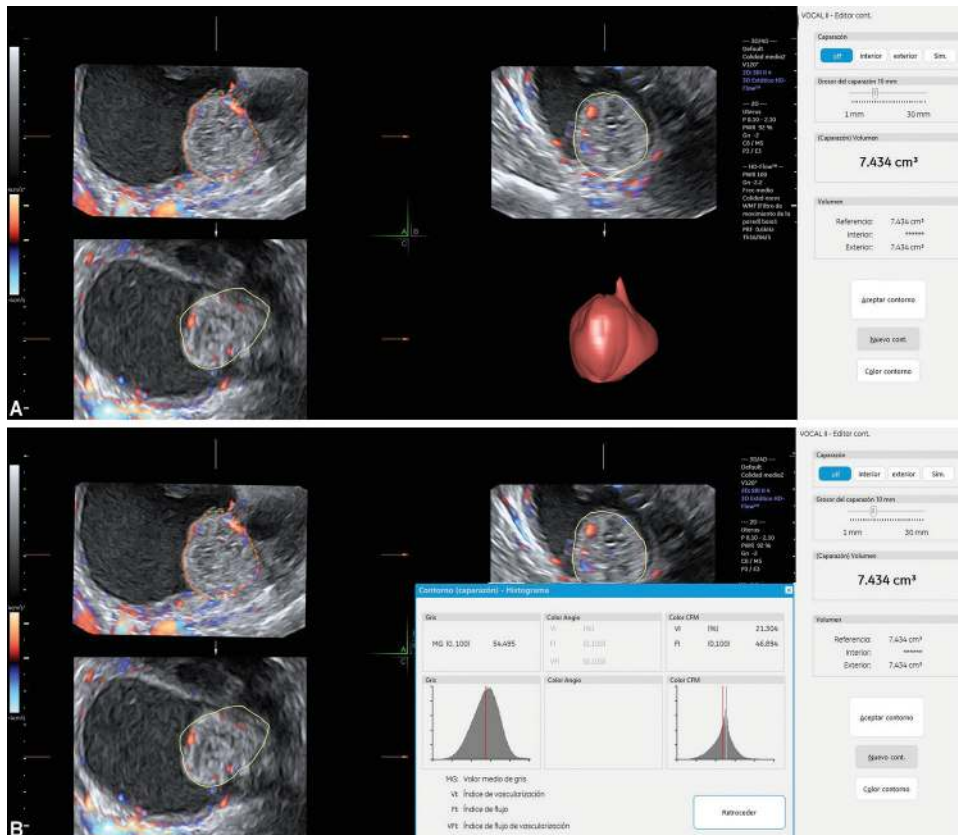
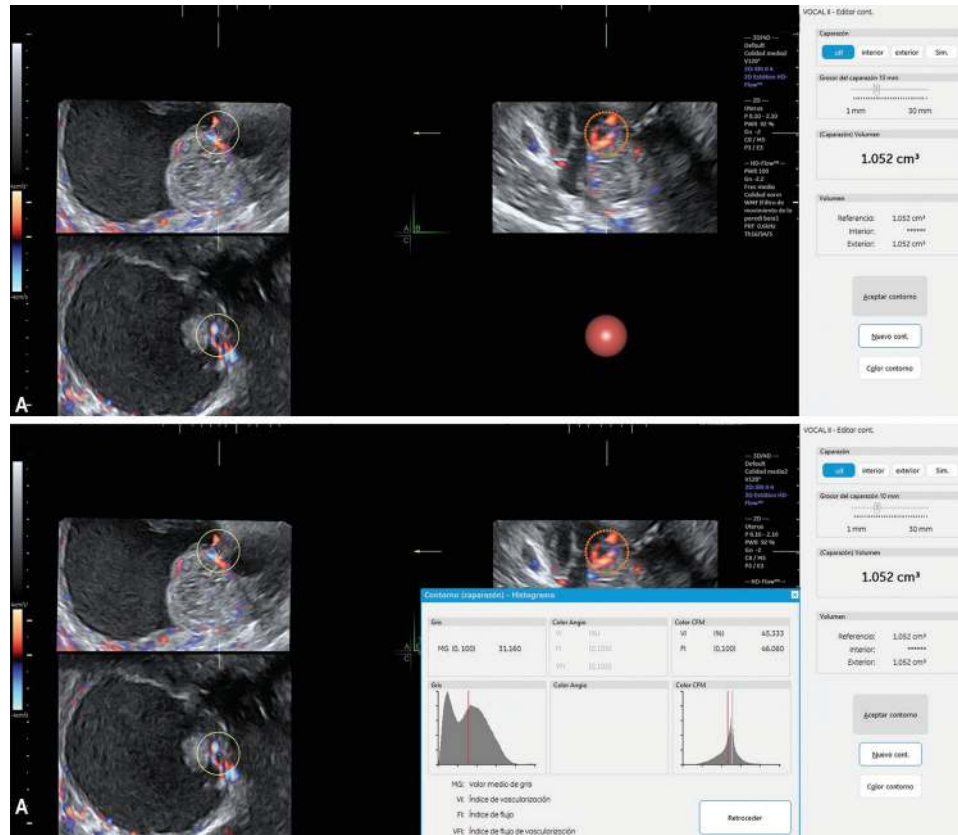


Fig. 7: Three-dimensional reconstruction of the vessel tree from an ovarian benign tumor. In this case, there is no chaotic distribution in the vessels network



Figs 8A and B: Three-dimensional vascular sampling from an ovarian tumor using the manual mode. (A) The solid is outlined and its volume calculated; (B) Three-dimensional vascular indices within this volume are calculated



**Figs 9A and B:** (A) Three-dimensional vascular sampling from the same ovarian tumor as shown in Figure 8, but using the spherical mode (volume: 1.052-cc) from the most vascularized area; (B) Three-dimensional vascular indices within this sphere are calculated; note that values are higher than the valves as shown in Figure 8

Cohen et al. evaluated 71 complex adnexal masses using this technique. Addition of 3D-PDU improved the specificity of 2D-US (75% vs 54%), with an identical sensitivity (100%) for both techniques.<sup>15</sup> The limitation of their study was that they missed to use 2D conventional color Doppler or 2D power Doppler.

Alcázar et al. compared the 2D power Doppler and 3D power Doppler, and did not compare the differences between the two techniques in terms of diagnostic performance.<sup>16</sup>

Kurjak et al. were the first who used 3D-PDA to discriminate between benign and malignant ovarian tumors by depicting tumoral vascular tree architecture.<sup>14</sup> By including 3D-US tumor vascular tree architecture and 2D-US morphological features, they developed a scoring system to discriminate between benign and malignant tumors. The presence of chaotic vessel arrangement and complex branching pattern by 3D-PDA were criteria of malignant tumors. In two different investigations, they found that 3D-PDU/2D-US-based scoring system was better than 2D-US alone.<sup>14,17</sup>

Chase et al. analyzed vascular architecture was assessed by 3D-PDU in a series of 66 women diagnosed with an adnexal mass by Chase et al. with the presence of chaotic vessel pattern as a criterion for malignancy suspicion. They concluded that by using 3D-US for the assessment of the vascular tree, it enabled to make a distinction of benign from malignant ovarian masses.<sup>18</sup> Mansour et al. evaluated the vascularity pater of adnexal masses in 400 patients by 3D-PDU. The pattern of vascularity of the masses was interpreted as avascular, parallel, or chaotic. A chaotic pattern was suggestive of malignancy, while avascular and parallel patterns were found in benign masses. The diagnostic performance of the risk of malignancy index (RMI) can be improved by adding 3D-PDU information to the RMI.<sup>19</sup>

Kalmantis et al. found that the sensitivity and specificity of 2D-US increased when added 3D-PDA.<sup>20</sup> However, Laban et al. used the criteria proposed by Kurjak in a series of 50 selected women with complex adnexal masses, reporting that 3D-PDU was not superior to 2D-PD.<sup>8</sup> After this report, other studies from Sladkevicius et al.,<sup>21</sup> Alcázar et al.,<sup>22</sup> and Dai et al.<sup>23</sup> reported similar findings.

More recently, there are some case reports showing that the 3D-PDU silhouette mode might be useful.<sup>24</sup> However, data are still too scanty to draw any conclusion.

It can be concluded, that albeit potentially interesting, the assessment of the tumoral vascular network by 3D-PDA has yielded conflicting results and its use is controversial.

Alcázar et al. were the first to suggest that the assessment of objective quantification of tumor vascularization by using 3D-PDU vascular indices (namely VI, FI, and VFI) within the most suspicious vascularized area from the tumor. In a selected series of 69 solid and cystic-solid masses with vascularization within the solid component, using manual sampling, they reported that all 3D-PDU vascular indices were significantly higher in ovarian cancer compared with benign tumors.<sup>25</sup> Geomini et al. evaluated 181 women with adnexal masses diagnosed by transvaginal ultrasound, including vascular assessment of the whole tumor. They found that FI, but neither VI nor VFI, was significantly higher in ovarian cancer.<sup>26</sup>

The use of a virtual 5-cc spherical sampling from the most vascularized area from the tumor was proposed as a different approach by Jokubkiene et al.<sup>27</sup> They found that 3D-PDU vascular indices from the spherical sample were higher in ovarian cancers compared with benign tumors. However, they concluded that this information added no value to that obtained using grayscale



assessment by an expert sonologist. Later on, Kudla et al. suggested the use of 1-cc spherical sampling instead of 5-cc.<sup>28</sup> They also reported that the 3D-PDU indices were significantly higher in ovarian cancer.

Abbas et al. compared the assessment of tumoral vascular network and 3D-PDA derived indices that were higher in ovarian cancer, but nevertheless, they concluded that the vascular network assessment was better compared with 3D-PDU derived indices.<sup>29</sup>

Notwithstanding, three studies did not show differences in 3D-PD indices between benign and malignant ovarian tumors.<sup>30-32</sup>

Alcázar et al. showed that both manual and spherical sampling assessments were reproducible between observers.<sup>33-35</sup>

Some studies have shown that the use of 3D-PDU vascular indices could improve the specificity of morphological grayscale and 2D-PDU in selected ovarian tumors, which are difficult to classify using the latter technique. Manual sampling method was used by Alcázar and Rodriguez in 143 adnexal masses with vascularized solid components. Using a cutoff VI >1.556% for classifying tumors as malignant, these authors reported that specificity improved a 33% retaining similar sensitivity.<sup>36</sup>

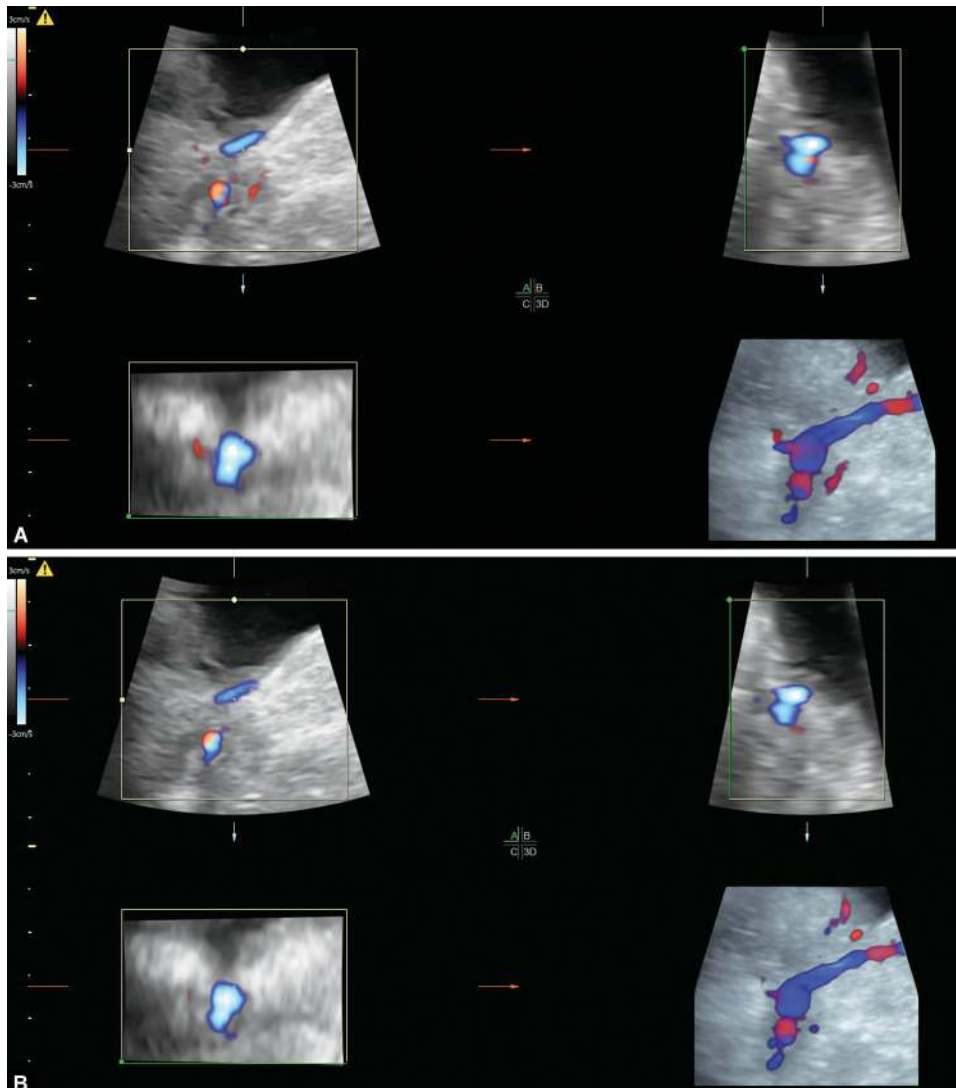
In a series of 138 women classified as malignant using 2D-US and 2D-PD by Kudla and Alcázar. They used 1-cc spherical sampling

instead of manual sampling. Using a cutoff of VI >24.015%, 20 out of 26 benign tumors in this series were correctly classified as benign (specificity: 77%) while 91% of malignant tumors were correctly classified as malignant.<sup>37</sup>

Vrachnis et al. also found in a small series that the use of 3D-PDA could add valuable information to conventional 2D-US.<sup>38</sup>

However, a prospective study reported by Utrilla-Layna et al. using the same method and cutoff for VI as proposed by Kudla and Alcázar, found that the 3D-PDU used as a third-step in the differential diagnosis of ovarian tumors did not improve the diagnostic accuracy of conventional 2D-PD ultrasound. However, a suspicious VI (>24.015%) significantly increases the probability of malignancy.<sup>39</sup> Silvestre et al. also reported that three-dimensional power Doppler indices have low accuracy for discriminating between benign and malignant tumors classified as inconclusive when using International Ovarian Tumor Analysis group (IOTA) simple rules.<sup>40</sup>

Some studies have used contrast-enhanced 3D-PDU. Huchon et al. reported that using contrast agent improved the visualization of vascular network and 3D-PDA derived indices were higher in malignant compared with benign tumors. They concluded that 3D-PDU could be useful in those cases 2D-US diagnosis was



**Figs 10A and B:** Four-dimensional spatiotemporal image correlation technique from the same area of an ovarian tumor. Vascular mapping changes from (A) systole to (B) diastole

uncertain.<sup>41</sup> Zhang et al. also reported that contrast-enhanced 3D-PDA could add valuable information in uncertain masses than 2D-US.<sup>42</sup> Hu et al. reached similar conclusions in their study focused on small ovarian masses, reaching 100% accuracy.<sup>43</sup>

However, it should be borne in mind that the actual significance of these indices is not fully understood, there are some important technical limitations of this technique and standardization is lacking, and its potential use in clinical practice is debated.<sup>44–47</sup>

## FOUR-DIMENSIONAL POWER DOPPLER ULTRASOUND

Because of the problems mentioned above in using 3D-PDU, some authors have proposed the use of the spatiotemporal image correlation technique, the so-called 4D angiography.<sup>48</sup> This technique allows a detailed estimation of blood flow changes in the tissue under investigation within one cardiac cycle (Fig. 10). Using this technology, a new volumetric vascular index has been developed, the volumetric pulsatility index (vPI).<sup>49,50</sup>

This index should be low when the blood flow increases in a given organ. In fact, Kudla and Alcázar demonstrated this in the ovaries of women with polycystic ovarian syndrome.<sup>51</sup>

Alcázar et al. have reported a prospective study using a similar design than Utrilla-Layna et al. They found that vPI was significantly lower in malignant tumors compared to benign ones. However, the addition of 4D angiography did not improve the overall diagnostic performance.<sup>52</sup> This could be explained by the fact that the number of cases in which 4D angiography was used was small.

In conclusion, the use of 3D-PDU and 4D angiography should be restricted to the research field and it should not be used in the clinical setting.

## REFERENCES

- American College of Obstetricians and Gynecologists' Committee on Practice Bulletins—Gynecology. Practice bulletin no. 174: evaluation and management of adnexal masses. *Obstet Gynecol* 2016;128(5):e210–e226. DOI: 10.1097/AOG.0000000000001768.
- Valentin L, Ameye L, Jurkovic D, et al. Which extrauterine pelvic masses are difficult to correctly classify as benign or malignant on the basis of ultrasound findings and is there a way of making a correct diagnosis? *Ultrasound Obstet Gynecol* 2006;27(4):438–444. DOI: 10.1002/uog.2707.
- Alcázar JL. Three-dimensional ultrasound in gynecology: current status and future perspectives. *Curr Women's Health Rev* 2005;1(1): 1–14. DOI: 10.2174/1573404052950221.
- Alcázar JL. Three-dimensional ultrasound in gynecological practice. *Report Med Imag* 2012;5:1–13. DOI: 10.2147/RMI.S21963.
- Bonilla-Musoles F, Raga F, Osborne NG. Three-dimensional ultrasound evaluation of ovarian masses. *Gynecol Oncol* 1995;59(1):129–135. DOI: 10.1006/gyno.1995.1279.
- Hata T, Yanagihara T, Hayashi K, et al. Three-dimensional ultrasonographic evaluation of ovarian tumours: a preliminary study. *Hum Reprod* 1999;14(3):858–861. DOI: 10.1093/humrep/14.3.858.
- Alcázar JL, Galán MJ, García-Manero M, et al. Three-dimensional ultrasound morphologic assessment in complex adnexal masses: a preliminary experience. *J Ultrasound Med* 2003;22(3):249–254. DOI: 10.7863/jum.2003.22.3.249.
- Laban M, Metawee H, Elyan A, et al. Three-dimensional ultrasound and three-dimensional power Doppler in the assessment of ovarian tumors. *Int J Gynaecol Obstet* 2007;99(3):201–205. DOI: 10.1016/j.ijgo.2007.03.027.
- Alcázar JL, García-Manero M, Galván R. Three-dimensional sonographic morphologic assessment of adnexal masses: a reproducibility study. *J Ultrasound Med* 2007;26(8):1007–1011. DOI: 10.7863/jum.2007.26.8.1007.
- Pascual MA, Graupera B, Hereter L, et al. Intra- and interobserver variability of 2D and 3D transvaginal sonography in the diagnosis of benign versus malignant adnexal masses. *J Clin Ultrasound* 2011;39(6):316–321. DOI: 10.1002/jcu.20808.
- Sladkevicius P, Valentin L. Re: Intra- and inter-observer agreement when describing adnexal masses using the International Ovarian Tumour Analysis terms and definitions: a study on three-dimensional ultrasound volumes. P. Sladkevicius and L. Valentin. *Ultrasound Obstet Gynecol* 2013;41:318–327. *Ultrasound Obstet Gynecol* 2013;41(3):318–327. DOI: 10.1002/uog.12289.
- Timor-Tritsch IE, Monteagudo A, Symbal T. Three dimensional ultrasound inversion rendering technique facilitates the diagnosis of hydrosalpinx. *J Clin Ultrasound* 2010;38(7):372–376. DOI: 10.1002/jcu.20707.
- Alcázar JL, León M, Galván R, et al. Assessment of cyst content using mean gray value for discriminating endometrioma from other unilocular cysts in premenopausal women. *Ultrasound Obstet Gynecol* 2010;35(2):228–232. DOI: 10.1002/uog.7535.
- Kurjak A, Kupesic S, Anic T, et al. Three-dimensional ultrasound and power Doppler improve the diagnosis of ovarian lesions. *Gynecol Oncol* 2000;76(1):28–32. DOI: 10.1006/gyno.1999.5647.
- Cohen LS, Escobar PF, Scharm C, et al. Three dimensional ultrasound power Doppler improves the diagnostic accuracy for ovarian cancer prediction. *Gynecol Oncol* 2001;82(1):40–48. DOI: 10.1006/gyno.2001.6253.
- Alcázar JL, Castillo G. Comparison of 2-dimensional and 3-dimensional power-Doppler imaging in complex adnexal masses for the prediction of ovarian cancer. *Am J Obstet Gynecol* 2005;192(3): 807–812. DOI: 10.1016/j.ajog.2004.10.630.
- Kurjak A, Kupesic S, Sparac V, et al. Preoperative evaluation of pelvic tumors by Doppler and three-dimensional sonography. *J Ultrasound Med* 2001;20(8):829–840. DOI: 10.7863/jum.2001.20.8.829.
- Chase DM, Crade M, Basu T, et al. Preoperative diagnosis of ovarian malignancy: preliminary results of the use of 3-dimensional vascular ultrasound. *Int J Gynecol Cancer* 2009;19(3):354–360. DOI: 10.1111/IGC.0b013e3181a1d73e.
- Mansour GM, El-Lamie IK, El-Sayed HM, et al. Adnexal mass vascularity assessed by 3-dimensional power Doppler: does it add to the risk of malignancy index in prediction of ovarian malignancy?: four hundred-case study. *Int J Gynecol Cancer* 2009;19(5):867–872. DOI: 10.1111/IGC.0b013e3181a8335e.
- Kalmantis K, Rodolakis A, Daskalakis G, et al. Characterization of ovarian tumors and staging ovarian cancer with 3-dimensional power Doppler angiography: correlation with pathologic findings. *Int J Gynecol Cancer* 2013;23(3):469–474. DOI: 10.1097/IGC.0b013e3182866679.
- Sladkevicius P, Jokubkiene L, Valentin L. Contribution of morphological assessment of the vessel tree by three-dimensional ultrasound to a correct diagnosis of malignancy in ovarian masses. *Ultrasound Obstet Gynecol* 2007;30(6):874–882. DOI: 10.1002/uog.5150.
- Alcázar JL, Cabrera C, Galván R, et al. Three-dimensional power Doppler vascular network assessment of adnexal masses: intraobserver and interobserver agreement analysis. *J Ultrasound Med* 2008;27(7):997–1001. DOI: 10.7863/jum.2008.27.7.997.
- Dai SY, Hata K, Inubashiri E, et al. Does three-dimensional power Doppler ultrasound improve the diagnostic accuracy for the prediction of adnexal malignancy? *J Obstet Gynaecol Res* 2008;34(3):364–370. DOI: 10.1111/j.1447-0756.2007.00702.x.
- Sajapala S, AboEllail MA, Tanaka T, et al. Three-dimensional power Doppler with silhouette mode for diagnosis of malignant ovarian tumors. *Ultrasound Obstet Gynecol* 2016;48(6):806–808. DOI: 10.1002/uog.15730.
- Alcázar JL, Merce LT, Garcia Manero M. Three-dimensional power Doppler vascular sampling: a new method for predicting ovarian



- cancer in vascularized complex adnexal masses. *J Ultrasound Med* 2005;24(5):689–696. DOI: 10.7863/jum.2005.24.5.689.
26. Geomini PM, Kluivers KB, Moret E, et al. Evaluation of adnexal masses with three-dimensional ultrasonography. *Obstet Gynecol* 2006;108(5):1167–1175. DOI: 10.1097/01.AOG.0000240138.24546.37.
  27. Jokubkiene L, Sladkevicius P, Valentin L. Does three-dimensional power Doppler ultrasound help in discrimination between benign and malignant ovarian masses? *Ultrasound Obstet Gynecol* 2007;29(2):215–225. DOI: 10.1002/uog.3922.
  28. Kudla MJ, Timor-Tritsch IE, Hope JM, et al. Spherical tissue sampling in 3-dimensional power Doppler angiography: a new approach for evaluation of ovarian tumors. *J Ultrasound Med* 2008;27(3):425–433. DOI: 10.7863/jum.2008.27.3.425.
  29. Abbas AM, Zahran KM, Nasr A, et al. Three-dimensional power Doppler evaluation of adnexal masses. Which parameter performs best? *Thai J Obstet Gynecol* 2014;22:102–107.
  30. Ohel I, Sheiner E, Aricha-Tamir B, et al. Three-dimensional power Doppler ultrasound in ovarian cancer and its correlation with histology. *Arch Gynecol Obstet* 2010;281(5):919–925. DOI: 10.1007/s00404-009-1269-8.
  31. Perez-Medina T, Orensanz I, Pereira A, et al. Three-dimensional angioultrasonography for the prediction of malignancy in ovarian masses. *Gynecol Obstet Invest* 2013;75(2):120–125. DOI: 10.1159/000345576.
  32. Niemi RJ, Saarelainen SK, Luukkaala TH, et al. Reliability of preoperative evaluation of postmenopausal ovarian tumors. *J Ovarian Res* 2017;10(1):15. DOI: 10.1186/s13048-017-0309-4.
  33. Alcázar JL, Rodríguez D, Royo P, et al. Intraobserver and interobserver reproducibility of 3-dimensional power Doppler vascular indices in assessment of solid and cystic-solid adnexal masses. *J Ultrasound Med* 2008;27(1):1–6. DOI: 10.7863/jum.2008.27.1.1.
  34. Alcázar JL, Prka M. Evaluation of two different methods for vascular sampling by three-dimensional power Doppler angiography in solid and cystic-solid adnexal masses. *Ultrasound Obstet Gynecol* 2009;33(3):349–354. DOI: 10.1002/uog.6312.
  35. Kudla M, Alcázar JL. Does the size of three-dimensional power Doppler spherical sampling affect the interobserver reproducibility of measurements of vascular indices in adnexal masses? *Ultrasound Obstet Gynecol* 2009;34(6):732–734. DOI: 10.1002/uog.7462.
  36. Alcázar JL, Rodríguez D. Three-dimensional power Doppler vascular sonographic sampling for predicting ovarian cancer in cystic-solid and solid vascularized masses. *J Ultrasound Med* 2009;28(3):275–281. DOI: 10.7863/jum.2009.28.3.275.
  37. Kudla MJ, Alcázar JL. Does sphere volume affect the performance of three-dimensional power Doppler virtual vascular sampling for predicting malignancy in vascularized solid or cystic-solid adnexal masses? *Ultrasound Obstet Gynecol* 2010;35(5):602–608. DOI: 10.1002/uog.7601.
  38. Vrachnis N, Sifakis S, Samoli E, et al. Three-dimensional ultrasound and three-dimensional power Doppler improve the preoperative evaluation of complex benign ovarian lesions. *Clin Exp Obstet Gynecol* 2012;39(4):474–478.
  39. Utrilla-Layna J, Alcázar JL, Aubá M, et al. Performance of three-dimensional power Doppler angiography as third-step assessment in differential diagnosis of adnexal masses. *Ultrasound Obstet Gynecol* 2015;45(5):613–617. DOI: 10.1002/uog.14674.
  40. Silvestre L, Martins WP, Candido-Dos-Reis FJ. Limitations of three-dimensional power Doppler angiography in preoperative evaluation of ovarian tumors. *J Ovarian Res* 2015;8:47. DOI: 10.1186/s13048-015-0174-y.
  41. Huchon C, Metzger U, Bats AS, et al. Value of three-dimensional contrast-enhanced power Doppler ultrasound for characterizing adnexal masses. *J Obstet Gynaecol Res* 2012;38(5):832–840. DOI: 10.1111/j.1447-0756.2011.01785.x.
  42. Zhang X, Mao Y, Zheng R, et al. The contribution of qualitative CEUS to the determination of malignancy in adnexal masses, indeterminate on conventional US - a multicenter study. *PLoS One* 2014;9(4):e93843. DOI: 10.1371/journal.pone.0093843.
  43. Hu R, Xiang H, Mu Y, et al. Combination of 2- and 3-dimensional contrast-enhanced transvaginal sonography for diagnosis of small adnexal masses. *J Ultrasound Med* 2014;33(11):1889–1899. DOI: 10.7863/ultra.33.11.1889.
  44. Alcázar JL. Three-dimensional power Doppler derived vascular indices: what are we measuring and how are we doing it? *Ultrasound Obstet Gynecol* 2008;32(4):485–487. DOI: 10.1002/uog.6144.
  45. Raine-Fenning NJ, Nordin NM, Ramnarine KV, et al. Evaluation of the effect of machine settings on quantitative three-dimensional power Doppler angiography: an in-vitro flow phantom experiment. *Ultrasound Obstet Gynecol* 2008;32(4):551–559. DOI: 10.1002/uog.6138.
  46. Raine-Fenning NJ, Nordin NM, Ramnarine KV, et al. Determining the relationship between three-dimensional power Doppler data and true blood flow characteristics: an in-vitro flow phantom experiment. *Ultrasound Obstet Gynecol* 2008;32(4):540–550. DOI: 10.1002/uog.6110.
  47. Martins WP. Three-dimensional power Doppler: validity and reliability. *Ultrasound Obstet Gynecol* 2010;36(5):530–533. DOI: 10.1002/uog.8836.
  48. Kudla MJ, Alcázar JL. Spatiotemporal image correlation using high-definition flow: a new method for assessing ovarian vascularization. *J Ultrasound Med* 2010;29(10):1469–1474. DOI: 10.7863/jum.2010.29.10.1469.
  49. Martins WP, Welsh AW, Lima JC, et al. The “volumetric” pulsatility index as evaluated by spatiotemporal imaging correlation (STIC): a preliminary description of a novel technique, its application to the endometrium and an evaluation of its reproducibility. *Ultrasound Med Biol* 2011;37(12):2160–2168. DOI: 10.1016/j.ultrasmedbio.2011.08.014.
  50. Kudla MJ, Alcázar JL. Spatiotemporal image correlation with spherical sampling and high-definition flow: new 4-dimensional method for assessment of tissue vascularization changes during the cardiac cycle: reproducibility analysis. *J Ultrasound Med* 2012;31(1):73–80. DOI: 10.7863/jum.2012.31.1.73.
  51. Alcázar JL, Kudla MJ. Ovarian stromal vessels assessed by spatiotemporal image correlation-high definition flow in women with polycystic ovary syndrome: a case-control study. *Ultrasound Obstet Gynecol* 2012;40(4):470–475. DOI: 10.1002/uog.11187.
  52. Alcázar JL, Auba M, Ruiz-Zambrana A, et al. Evaluation of the 4D “Spatiotemporal Image Correlation” technology with high-definition color Doppler as third step for preoperative differential diagnosis of ovarian tumors. A prospective study. *Donald School J Ultrasound Obstet Gynecol* 2018;12:1–8. DOI: 10.5005/jp-journals-10009-1545.