



THE UNIVERSITY *of* EDINBURGH

## Edinburgh Research Explorer

### Tokyo Guidelines 2018 surgical management of acute cholecystitis

**Citation for published version:**

Wakabayashi, G, Iwashita, Y, Hibi, T, Takada, T, Strasberg, SM, Asbun, HJ, Endo, I, Umezawa, A, Asai, K, Suzuki, K, Mori, Y, Okamoto, K, Pitt, HA, Han, H-S, Hwang, T-L, Yoon, Y-S, Yoon, D-S, Choi, I-S, Huang, WS-W, Giménez, ME, Garden, OJ, Gouma, DJ, Belli, G, Dervenis, C, Jagannath, P, Chan, ACW, Lau, WY, Liu, K-H, Su, C-H, Misawa, T, Nakamura, M, Horiguchi, A, Tagaya, N, Fujioka, S, Higuchi, R, Shikata, S, Noguchi, Y, Ukai, T, Yokoe, M, Cherqui, D, Honda, G, Sugioka, A, de Santibañes, E, Supe, AN, Tokumura, H, Kimura, T, Yoshida, M, Mayumi, T, Kitano, S, Inomata, M, Hirata, K, Sumiyama, Y, Inui, K & Yamamoto, M 2018, 'Tokyo Guidelines 2018 surgical management of acute cholecystitis: safe steps in laparoscopic cholecystectomy for acute cholecystitis (with videos)', *Journal of Hepato-Biliary-Pancreatic Sciences*, vol. 25, no. 1. <https://doi.org/10.1002/jhbp.517>

**Digital Object Identifier (DOI):**

[10.1002/jhbp.517](https://doi.org/10.1002/jhbp.517)

**Link:**

[Link to publication record in Edinburgh Research Explorer](#)

**Document Version:**

Peer reviewed version

**Published In:**

Journal of Hepato-Biliary-Pancreatic Sciences

**General rights**

Copyright for the publications made accessible via the Edinburgh Research Explorer is retained by the author(s) and / or other copyright owners and it is a condition of accessing these publications that users recognise and abide by the legal requirements associated with these rights.

**Take down policy**

The University of Edinburgh has made every reasonable effort to ensure that Edinburgh Research Explorer content complies with UK legislation. If you believe that the public display of this file breaches copyright please contact [openaccess@ed.ac.uk](mailto:openaccess@ed.ac.uk) providing details, and we will remove access to the work immediately and investigate your claim.



**Tokyo Guidelines 2018 surgical management of acute cholecystitis: safe steps in laparoscopic cholecystectomy for acute cholecystitis (with videos)**

Go Wakabayashi, Yukio Iwashita, Taizo Hibi, Tadahiro Takada, Steven M. Strasberg, Horacio J. Asbun, Itaru Endo, Akiko Umezawa, Koji Asai, Kenji Suzuki, Yasuhisa Mori, Kohji Okamoto, Henry A. Pitt, Ho-Seong Han, Tsann-Long Hwang, Yoo-Seok Yoon, Dong-Sup Yoon, In-Seok Choi, Wayne Shih-Wei Huang, Mariano Eduardo Giménez, O. James Garden, Dirk J. Gouma, Giulio Belli, Christos Dervenis, Palepu Jagannath, Angus C.W. Chan, Wan Yee Lau, Keng-Hao Liu, Cheng-Hsi Su, Takeyuki Misawa, Masafumi Nakamura, Akihiko Horiguchi, Nobumi Tagaya, Shuichi Fujioka, Ryota Higuchi, Satoru Shikata, Yoshinori Noguchi, Tomohiko Ukai, Masamichi Yokoe, Daniel Cherqui, Goro Honda, Atsushi Sugioka, Eduardo de Santibañes, Avinash Nivritti Supe, Hiromi Tokumura, Taizo Kimura, Masahiro Yoshida, Toshihiko Mayumi, Seigo Kitano, Masafumi Inomata, Koichi Hirata, Yoshinobu Sumiyama, Kazuo Inui, Masakazu Yamamoto

The author's affiliations are listed in the Appendix.

**Corresponding author:**

Tadahiro Takada, M.D., Ph.D.

Department of Surgery, Teikyo University School of Medicine, 2-11-1 Kaga, Itabashi-ku, Tokyo 173-8605, Japan  
E-mail: t-takada@jshbps.jp

**Keywords:** Laparoscopic cholecystectomy, acute cholecystitis, safety, difficult, critical view of safety

**Abstract**

In some cases, laparoscopic cholecystectomy (LC) may be difficult to perform in patients with acute cholecystitis (AC) with severe inflammation and fibrosis. The Tokyo Guidelines 2018 (TG18) expand the indications for LC under difficult conditions for each level of severity of AC. As a result of expanding the indications for LC to treat AC, it is absolutely

This article has been accepted for publication and undergone full peer review but has not been through the copyediting, typesetting, pagination and proofreading process, which may lead to differences between this version and the Version of Record. Please cite this article as doi: 10.1002/jhbp.517

This article is protected by copyright. All rights reserved.

necessary to avoid any increase in bile duct injury (BDI), particularly vasculo-biliary injury (VBI), which is known to occur at a certain rate in LC. Since the Tokyo Guidelines 2013 (TG13), an attempt has been made to assess intraoperative findings as objective indicators of surgical difficulty; based on expert consensus on these difficulty indicators, bail-out procedures (including conversion to open cholecystectomy) have been indicated for cases in which LC for AC is difficult to perform. A bail-out procedure should be chosen if, when the Calot's triangle is appropriately retracted and used as a landmark, a critical view of safety (CVS) cannot be achieved because of the presence of nondissectable scarring or severe fibrosis. We propose standardized safe steps for LC to treat AC. To achieve a CVS, it is vital to dissect at a location above (on the ventral side of) the imaginary line connecting the base of the left medial section (Segment 4) and the roof of Rouvière's sulcus and to fulfill the three criteria of CVS before dividing any structures. Achieving a CVS prevents the misidentification of the cystic duct and the common bile duct, which are most commonly confused.

## **Introduction**

Laparoscopic cholecystectomy (LC) was first performed by Mühe (under direct scope vision) in 1985. Subsequently, the same procedure using a video-laparoscope, which is used today, was carried out by Mouret in 1987, and was spread worldwide from Europe and the United States by Dubois and Perissat [1]. In 1992 an NIH consensus concluded that it is a safe, effective treatment procedure for almost all patients with symptomatic cholelithiasis [2]. However, because surgery is performed remotely from outside the abdominal cavity via images, and haptic feedback from tissue is weak compared with that in open abdominal surgery, LC is difficult to perform in some patients with acute cholecystitis (AC) with severe inflammation and fibrosis. In guidelines published by the Society of American Gastrointestinal and Endoscopic Surgeons (SAGES) in 1993, AC was described as a relative contraindication for LC [3]. Subsequent advances in optical and surgical devices and improvements in surgical techniques, however, have led to the expansion of the surgical indications for LC and a gradual increase in use of LC to treat AC. Severity assessment criteria for AC were first set out in 2007, indicating treatment guidelines for AC of different levels of severity [4]; these guidelines were not changed when they were revised in 2013 [5]. In the Tokyo Guidelines 2007 (TG07) and the Tokyo Guidelines 2013 (TG13), LC was indicated for Grade I (mild) and Grade II (moderate) AC. For Grade II, however, this was conditional on the availability of advanced laparoscopic techniques; and for Grade III, LC was to be performed only after gallbladder (GB) drainage. In this updated Tokyo Guidelines

2018 (TG18), which are based on various reports published since TG13 including a large-scale Japanese/Taiwanese joint study [6], this has been revised to “If both the patient and the facilities where the surgery is to be performed meet strict conditions, LC may also be performed as a straight forward procedure in under certain conditions of Grade III cases.” [7].

As LC has become more widely performed, bile duct injury (BDI) is known to occur in a certain proportion of cases, and the prognoses of patients who suffer vasculo-biliary injury (VBI) in particular has been poor [8]. The surgical difficulty of AC varies greatly depending on the severity of inflammation and fibrosis. The risk of BDI has been shown to increase in accordance with the severity of AC [9]. Since TG13, an attempt has been made to assess intraoperative findings as objective indicators of surgical difficulty; expert consensus on intraoperative findings as indicators of surgical difficulty was reached by over 400 doctors from Japan, Korea, and Taiwan [10]. In a Delphi survey, 614 surgeons in Japan, Korea, Taiwan, the United States, and elsewhere were presented with 29 situations that might involve the risk of BDI along with preventative measures and asked which of these findings they regarded as most important [11]. Suggestions for safe LC procedures based on consensus indicators of surgical difficulty are considered to serve as important guidelines for reducing BDI for surgeons with various levels of experience who perform LC. It is essential to avoid any increase in BDI and VBI as a result of the recommendation in TG18 to perform LC in the surgical management of AC irrespective of its grade. Therefore, we present safe steps and bail-out procedures that are important when performing LC to treat AC. We also investigated treatment strategies in the event that choledocholithiasis is also present and whether the recently-developed reduced port surgery is indicated for AC.

#### **Q1. What are the indicators of surgical difficulty in laparoscopic cholecystectomy for acute cholecystitis?**

**Besides preoperative factors and severity of AC, intraoperative findings are considered to be appropriate indicators of surgical difficulty in LC for AC.  
(level D)**

Severe inflammation of the GB and its surroundings increases both the difficulty of LC and the frequency of postoperative complications. The estimated incidence of serious complications such as BDI and VBI is 2 to 5 times higher for LC than for open cholecystectomy [12, 13]. As AC is a common disease, even if the frequency of

complications is low, the absolute number of cases is high. To reduce these serious complications, it is essential to assess the surgical difficulty appropriately and to standardize treatment strategies. Many previous studies have used factors such as the open conversion rate, operating time, and the incidence of complications as indicators of surgical difficulty.

An investigation of preoperative data and diagnostic imaging using operating time or the open conversion rate as indicators of surgical difficulty in cases of symptomatic cholelithiasis (including AC) identified body-mass index (BMI), non-visualized GB on preoperative cholangiography, cystic duct length, temperature, and abnormal findings on CT as five factors that significantly affected the time required for cholecystectomy [14]. Another study found that the three factors of GB wall thickening, incarcerated stones in the GB neck, and duration of elevated CRP contributed to prolonged operating time [15], and many other studies have found that factors including male sex, elevated white blood cell count (WBC), low albumin, high bilirubin, fluid retention around the GB, and diabetes are predictive of open conversion [16-19]. A meta-analysis of the collected results of these observational studies identified GB wall thickening (>4 to 5 mm) on ultrasound, male sex, advanced age, and obesity as risk factors for open conversion [20]. A recent study has found that the rates of open conversion and complications were significantly higher in TG13 Grade II and III cases compared with Grade I cases [21] (Table 1 ).

From these results, the level of surgical difficulty might be predictable on the basis of factors including preoperative imaging and blood tests, and TG13 grade. Some studies investigating surgical timing and surgical difficulty also found that if surgery was performed within 72 h of the onset of AC, there were fewer complications, operating time was shorter, and surgical difficulty was lower [22, 23]. One issue is that almost all these studies were observational studies derived from single-center data, and no studies have provided a high level of evidence.

Questionnaire surveys of Japanese, Korean, and Taiwanese experts have found that operating time, which is frequently used as an indicator of surgical difficulty, is greatly dependent on the skill and experience of the operator and that the criteria for conversion to open cholecystectomy vary among surgeons [10, 24]. Operating time and conversion rate are useful indicators of surgical difficulty but must be interpreted in light of surgical training, skill and experience. Some studies have suggested that it may be possible to identify objective indicators of surgical difficulty on the basis of intraoperative findings, some of

This article is protected by copyright. All rights reserved.

which are not based merely on expert opinion [25] but are also based on a Delphi consensus among a large number of surgeons of different nationalities [26]. The use and evaluation in future studies of intraoperative findings (Table 2) as objective, direct indicators capable of measuring of surgical difficulty is therefore desirable.

**Q2. Which surgical procedures are alternatives to difficult laparoscopic cholecystectomy for acute cholecystitis?**

**Surgeons should choose bail-out procedures to prevent BDI according to the intraoperative findings (recommendation 1, level C).**

In TG13, conversion to open cholecystectomy was the only recommendation in cases of AC for which LC was difficult. In the current revisions, the specific bail-out procedures listed below are suggested, and it is strongly recommended that surgeons make appropriate judgments and choose a bail-out procedure based on intraoperative findings in order to avoid secondary damage (level C).

*Subtotal cholecystectomy*

The procedure involves making an incision in the GB, aspirating the contents, and then removing as much of the GB wall as possible and treating the stump instead of removing the entire GB has been in use since the days of open cholecystectomy [27]. Previous studies have not drawn a clear distinction between partial and subtotal removal, and the situation is confused. Strasberg *et al.* designated all procedures in which as much of the GB wall as possible is removed as subtotal (rather than partial) resection (Figure 1a) and proposed that resection of the fundus alone should be referred to as “fundectomy” [28]. Subtotal cholecystectomy is deemed “reconstituting” when a closed gallbladder remnant is left and “fenestrating” when the remnant is left open or the internal opening of the cystic duct is closed (Figure 1) [28].

According to a systematic review and a meta-analysis, although postoperative bile leakage was more common following laparoscopic subtotal cholecystectomy compared with open conversion, rates of BDI, postoperative complications, reoperation, and mortality were all lower [29, 30]. More patients whose surgery concluded with drainage because the stump of the neck of the GB was not closed underwent postoperative endoscopic retrograde cholangiography compared with those in whom closure was successfully performed, but there was no change in the rate of complications. In long-term follow-up after subtotal

resection, gallstones recurred in around 5% of patients and these patients have usually had subtotal reconstituting operations [30]. Although risk of concomitant GB cancer has also been reported, frequency of occurrence is low [29]. Laparoscopic subtotal cholecystectomy is an important procedure that should be considered in order to avoid serious damage to the bile duct or blood vessels. Video 1 shows a typical case of laparoscopic subtotal cholecystectomy.

#### *Open conversion*

No randomized controlled trial (RCT) has investigated the merits and demerits of open conversion, but a meta-analysis found that open conversion had no effect on the rate of local postoperative complications [31]. However, some studies have pointed out that as LC comes to account for the great majority of procedures and surgeons have less experience performing open cholecystectomy, open conversion may not necessarily be safe [32]. In a questionnaire survey of experts in Japan, South Korea, and Taiwan, only 17.5% of the total responded that open conversion made surgery easier [24]. Although decision-making on open conversion may vary greatly between hospitals, appropriate judgment should be made in light of the surgeon's skill level. Subtotal cholecystectomy may also be done after conversion when it is found that complete cholecystectomy is dangerous.

#### *Fundus first technique*

The procedure in which the separation of the GB from the liver starts at the fundus, without initially visualizing a cystic artery and cystic duct in the Calot's triangle (Figure 1d), has not yet been adequately studied. Even the terminology has yet to be made consistent, with terms including "dome down," "fundus first," and "fundus down" all being used. A search of PubMed reveals that "fundus first" is the most commonly used. If a difficult case with severe inflammation of the Calot's triangle is encountered, fundus first LC with subtotal cholecystectomy may offer an option that enables the completion of LC while avoiding BDI as an alternative to immediate conversion to open cholecystectomy. The merits and demerits of the fundus first technique have been reported in previous studies [33, 34], and several case series have described successful use of the fundus first technique [35-37]. Other studies described a subtotal cholecystectomy combined with a fundus first technique starting with retrograde dissection of the GB [38, 39]. However, because of the low event rate of bile duct injury (approximately 1/333), large numbers of patients are required to demonstrate safety of a technique in respect to this complication. Therefore, these studies cannot be used to draw a conclusion that the techniques are safe or better than other techniques in regard to bile duct injury. Some studies indeed have warned that VBI may occur due to misidentification of the



layer to be dissected when dissecting from the fundus of the GB toward its neck [40, 41]. Importantly, this technique has been shown to be associated with an “extreme” VBI when performed in patients with marked chronic inflammation with biliary inflammatory fusion and contraction [40]. Therefore, the plane of dissection should always be kept close to the GB [42, 43].

#### *Delphi consensus on bail-out procedures in difficult situations*

Indications to perform a bail-out procedure have been identified by a recent Delphi consensus [11]. A bail-out procedure should be chosen if a CVS cannot be achieved because of scarring or severe fibrosis, as long as the Calot’s triangle is appropriately retracted and is recognized as a landmark.

### **Q3. What are the important points to avoid biliary injury in laparoscopic cholecystectomy for acute cholecystitis?**

- **Early LC before fibrosis:** AC for LC should be performed at an early stage before florid inflammation and fibrosis develop in order to avoid BDI.
- **Creation of the CVS:** To perform LC safely, it is recommended that the three criteria of CVS be achieved and noted in a “time-out” before clipping or cutting structures.
- **Dissection along the GB surface with the following landmarks:** If the GB surface is difficult to identify in the Calot's triangle, an attempt should first be made to identify the GB surface from the dorsal side of the neck of the GB. If the GB surface is still difficult to identify, bail-out procedures (see Q2) should be considered. The base of Segment 4 and the roof of Rouvière's sulcus should be used as anatomical landmarks, and any surgical procedures during cholecystectomy should be performed above the imaginary line connecting these two landmarks.
- **Bail-out procedures:** Subtotal laparoscopic or open cholecystectomy have been reported to reduce BDI (see Q2).
- **Perioperative imaging:** Although there is no evidence for the value of intraoperative cholangiography, preoperative magnetic resonance cholangiopancreatography (MRCP), intraoperative fluorescence cholangiography, and intraoperative ultrasound may reduce BDI (level D).

In AC, surgery becomes more difficult as fibrosis progresses in the inflammatory process, so performing LC early is recommended [5, 44]. Early LC has been found to cause fewer total complications and to reduce operating time and total cost [44-48]. Because BDI occurs

This article is protected by copyright. All rights reserved.



infrequently, some studies have found that early LC has no impact on BDI [44], whereas others have found that early LC reduces BDI [45-48]. A recent meta-analysis [47] and a propensity score matching study [48] found that early LC resulted in significantly fewer cases of BDI and a 50% reduction in cases of BDI [47].

The CVS concept proposed by Strasberg *et al.* [49] has been popularized worldwide, and in a questionnaire survey of members of the UK Association of Upper Gastrointestinal Surgeons (AUGIS), exposing a CVS was the most commonly recommended option for preventing intraoperative BDI [50]. Although the CVS is valuable for preventing BDI, greater awareness of this concept among surgeons is still required; the CVS score is increased [51] and actual operating time is decreased by resident training [52].

Fibrosis and adhesions surrounding the GB and in the Calot's triangle may be severe in AC, causing difficulty to identify local anatomy and achieve a CVS [41]. If the GB surface and/or the anatomy of the Calot's triangle is unclear, then bail-out procedures should be considered (see Q2 and the following paragraph). A safe procedure is to identify Rouvière's sulcus and the base of Segment 4 and perform all surgical procedures above the imaginary line connecting these two landmarks. To maintain the plane of dissection on the GB surface throughout cholecystectomy is paramount to avoid injury to hilar structures and liver parenchyma [41, 53, 54].

If severe fibrosis in the Calot's triangle prevents safe completion of LC with/without using the fundus first technique, BDI can be avoided by subtotal LC or open conversion [55]. In a retrospective study of patients who underwent subtotal LC or open conversion, BDI occurred in 3.3% who underwent open conversion but in none of the patients who underwent subtotal LC [56]. Subtotal LC should be considered as an option when straightforward LC cannot be completed safely. At the moment, the decision to switch procedures depends on the subjective judgment of the operator. Intraoperative findings may serve as objective indicators of surgical difficulty; accordingly, there is a need to establish criteria for switching procedures based on intraoperative findings [10].

Whether intraoperative cholangiography reduces BDI has been reported with mixed results [13, 57-60], and its performance is optional [50, 61]. However, it is important to note that there is evidence that intraoperative cholangiography might reduce the extent of the injury. Perioperative cholangiography, including preoperative MRCP, decreases complications and

This article is protected by copyright. All rights reserved.

open conversion [55], and laparoscopic ultrasound [62, 63] and fluorescence cholangiography may prevent BDI. Although these procedures may become standard during LC, further studies are required [64].

#### **Q4: What are the safe steps in laparoscopic cholecystectomy for acute cholecystitis?**

**Standardized safe steps are recommended in difficult LC according to the intraoperative findings (level D).**

Based on the recent Delphi consensus [11], we propose the following safe steps in LC for AC.

**Step 1:** If a distended GB interferes with the field of view, it should be decompressed by needle aspiration (Figure 2a).

**Step 2:** Effective retraction of the GB to develop a plane in the Calot's triangle area and identify its boundaries (countertraction). (Fig.2b)

**Step 3:** Starting dissection from the posterior leaf of the peritoneum covering the neck of the GB and exposing the GB surface above Rouvière's sulcus. (Fig.2c)

**Step 4:** Maintaining the plane of dissection on the GB surface throughout LC. (Fig.2d)

**Step 5:** Dissecting the lower part of the GB bed (at least one-third) to obtain the critical view of safety (CVS) (Fig.2e).

**Step 6:** Creating the critical view of safety (Fig.2f).

\*: For persistent hemorrhage, achieving hemostasis primarily by compression and avoiding excessive use of electrocautery or clipping.

Video 2 shows a typical procedure following these safe steps.

If there is a risk of BDI, intraoperative cholangiography, intraoperative ultrasound, intraoperative indocyanine green fluorescence imaging, or another imaging modality to confirm the courses of the bile duct and blood vessels may be useful, but there is no unified consensus on this.

If there is severe fibrosis and scarring in the Calot's triangle due to inflammation and impacted gallstones in the confluence with the cystic duct or if a CVS showing anatomically important landmarks cannot be achieved, a bail-out procedure should be considered (see Q2). Even if inflammation is absent or mild, BDI may occur due to misidentification. Particular

care is required not to misidentify the common bile duct as the cystic duct.

Table 3 shows a summary of the content of the recent Delphi consensus [11].

**Q5. Is one-stage management for acute cholecystitis associated with common bile duct stone more effective than two-stage management?**

**Either approach is acceptable. (level B)**

**Commentary:**

For concomitant common bile duct stone and gallstone, multiple randomized control trials [65-67] and meta-analyses [68, 69] have shown that one- (laparoscopic common bile duct exploration plus laparoscopic cholecystectomy or intraoperative laparoendoscopic rendezvous technique) and two-stage (endoscopic retrograde cholangiopancreatography followed by sequential laparoscopic cholecystectomy) approaches are equally safe and feasible. One randomized study [70] and one meta-analysis [71] concluded that a single-stage management has less morbidity and higher success rate. However, aforementioned studies have combined patients having acute biliary colic with those accompanying acute cholecystitis, which are two different entities. The incidence and severity of acute cholecystitis are not reported in any of these series; therefore, it is difficult to recommend one way or the other at the moment for patients with AC. The frequency of common bile duct stone complicating AC range between 7.7% and 14.3% [72-74] and whether patients with AC are at higher risk of common bile duct stone remains debatable. There is no significant predictor for the diagnosis of common bile duct stone to date and preoperative magnetic resonance cholangiography, endoscopic ultrasound, and intraoperative cholangiography are equally reliable [75].

Based on the randomized control trials since 2010 [65-67, 70], we conducted a meta-analysis and found no significant difference in the success rate of common bile duct stone removal (Fig. 3), complication rate (Fig. 4), and in-hospital mortality (Fig. 5). From a patient's point of view, it is clear that one-stage management is preferable because only a single procedure is required, which in turn results in a shorter hospital stay and lesser cost [65-69]. At this time, the feasibility of one-stage management is determined at the sole discretion of each institution depending on the skill and preference of endoscopists and surgeons (i.e., whether an endoscopist is willing to perform endoscopic retrograde cholangiography concurrently with the operation and whether a surgeon is capable of performing laparoscopic common bile

This article is protected by copyright. All rights reserved.

duct exploration). Moreover, the adoption rate of one-stage strategy in each region and country remains unclear. There is also a wide variety of healthcare delivery systems and health economics/policies around the globe. Well-designed, large-scale multicenter randomized control trial in patients exclusively with confirmed diagnosis of acute cholecystitis (in accordance with Tokyo Guidelines) associated with common bile duct stone are warranted.

**Q6. What is the role of reduced port surgery for acute cholecystitis?**

Because the superiority of reduced port surgery for AC is unclear, it is weakly recommended for use only in a limited number of appropriately selected patients (level D).

Reduced port surgery was not mentioned in TG13. In the current revisions, LC is designated as the first-choice treatment by surgical removal. LC seeks to be as minimally invasive as possible provided that safety is assured. Reduced port surgery is even less invasive than LC with better cosmetic results. The role of reduced port surgery as a laparoscopic procedure for AC is therefore mentioned in TG18.

Here, the term “reduced port surgery” is used as a general term for surgical procedures in which the size or number of trochars or the number of skin incisions is reduced compared to standard laparoscopic surgery for the purpose of reducing invasiveness or for cosmetic reasons.

In terms of reducing the number of trochars and skin incisions, the ultimate laparoscopic surgery is one-wound laparoscopic cholecystectomy, described by Navarra *et al.* in 1997 [76]. Although this technique is currently known by various names [77], here we use the term “single incision laparoscopic cholecystectomy” (SILC).

The RCTs comparing SILC with conventional laparoscopic cholecystectomy (CLC) have either excluded AC or included fewer than 40% of patients with AC [78, 79]. We can thus say that the role of SILC for AC has yet to be investigated. According to a meta-analysis, pain assessed on a visual analog scale (VAS) was lower in SILC [80]. However, the alleviation of pain was only significant at a very early stage after surgery, with no difference being evident after Day 1 [80]. Although many studies have not found significantly higher

Accepted Article

rates of complications associated with SILC [81, 82], the pooled risk ratio for serious complications (including BDI, reoperation, abdominal fluid retention, bile leakage, and abdominal infection) and the rate of moderate complications (wound infection and bile leakage or abdominal fluid retention that improved without treatment) have been found to be higher for SILC [80]. Furthermore, operating time was longer [81-86] and the number of trochars added intraoperatively were higher for SILC than for CLC [80, 82].

Although analyses have found that SILC provides better cosmetic results [81, 83, 85, 86], its superiority has not been demonstrated in terms of postoperative quality of life (QOL) score [80]. On the other hand, SILC requires a longer operating time and increases the risk of complications. The multi-channel ports used in SILC are expensive, and the procedure also requires special instruments. SILC is still at the stage of instrument development and improving the techniques involved in the procedure.

Reduced port surgery with trochar diameters <3 mm is known as “needlescopic surgery” [87]. Few RCTs have compared needlescopic cholecystectomy (NLC) and CLC for AC, but one study has found that although NLC requires a longer operating time, the rate of complications is within tolerable limits [88]. Figure 7 shows the results of a meta-analysis comparing NLC and CLC. This meta-analysis found that there was no difference in operating time and that pain tended to be less after NLC. Albeit for RCTs that either excluded AC or included very few patients with the condition, the ability to deal with inflammatory changes was found to be limited by technical difficulties related to the characteristics of the instruments [89], and high rates of conversion from NLC to CLC have been reported [90, 91]. Although NLC provides better cosmetic results, there is no difference with CLC in terms of patient satisfaction [92, 93].

These studies indicate that reduced port surgery for AC has no advantages other than cosmetic results and reduced pain. The extent to which these factors contribute to patient satisfaction should be investigated. Although it is hoped that the indications for reduced port surgery are extended in the future by instrument development and improved techniques, at this point, it should only be performed in a limited number of selected patients.

## **Acknowledgements**

We express our deep gratitude to the Japanese Society of Hepato-Biliary-Pancreatic Surgery, the Japanese Society of Abdominal Emergency Medicine, the Japanese Society of Surgical Infection, the Japan Biliary Association, for their substantial support and guidance in the preparation of the article. We also would like to express our deep gratitude to the Japanese Society of Hepato-Biliary-Pancreatic Surgery for the article processing managing office of Tokyo Guidelines 18 to prepare the publication. We appreciate all secretariats of the Japanese Society of Hepato-Biliary-Pancreatic Surgery for their technical support.

## **Conflicts of interest**

Goro Honda has received honoraria from Johnson and Johnson and Medtronics.

## **Appendix**

Go Wakabayashi, Department of Surgery, Ageo Central General Hospital, Saitama, Japan; Yukio Iwashita, Department of Gastroenterological and Pediatric Surgery, Oita University Faculty of Medicine, Oita, Japan; Taizo Hibi, Department of Surgery, Keio University School of Medicine, Tokyo, Japan; Tadahiro Takada, Department of Surgery, Teikyo University School of Medicine, Tokyo, Japan; Steven M. Strasberg, Section of Hepato-Pancreato-Biliary Surgery, Washington University School of Medicine in St. Louis, MO, USA; Horacio J. Asbun, Department of Surgery, Mayo Clinic College of Medicine, Florida, USA; Itaru Endo, Department of Gastroenterological Surgery, Yokohama City University Graduate School of Medicine, Kanagawa, Japan; Koji Asai, Department of Surgery, Toho University Ohashi Medical Center, Tokyo, Japan; Akiko Umezawa, Minimally Invasive Surgery Center, Yotsuya Medical Cube, Tokyo, Japan; Kenji Suzuki and Taizo Kimura, Department of Surgery, Fujinomiya City General Hospital, Shizuoka, Japan; Yasuhisa Mori and Masafumi Nakamura, Department of Surgery and Oncology, Graduate School of Medical Sciences, Kyushu University, Fukuoka, Japan; Kohji Okamoto, Department of Surgery, Center for Gastroenterology and Liver Disease, Kitakyushu City Yahata Hospital, Fukuoka, Japan; Henry A. Pitt, Lewis Katz School of Medicine at Temple University, Philadelphia, PA, USA; Ho-Seong Han and Yoo-Seok Yoon, Department of Surgery, Seoul National University Bundang Hospital, Seoul National University College of Medicine, Seoul, Korea; Tsann-Long Hwang and Keng-Hao Liu, Division of General Surgery, Linkou Chang Gung Memorial Hospital, Taoyuan, Taiwan; Dong-Sup Yoon, Department of Surgery, Yonsei University Gangnam Severance Hospital, Seoul, Korea; In-Seok Choi, Department of Surgery, Konyang University Hospital, Daejeon, Korea; Wayne Shih-Wei Huang, Department

This article is protected by copyright. All rights reserved.

of Surgery, Show Chwan Memorial Hospital, Changhua, Taiwan; Mariano Eduardo Giménez, Chair of General Surgery and Minimal Invasive Surgery “Taquini” University of Buenos Aires. Argentina DAICIM Foundation, Argentina; O James Garden, Clinical Surgery, University of Edinburgh, Edinburgh, UK; Dirk Joan Gouma, Department of Surgery, Academic Medical Center, Amsterdam, The Netherlands; Giulio Belli, Department of General and HPB Surgery, Loreto Nuovo Hospital, Naples Italy; Christos Dervenis, First Department of Surgery, Agia Olga Hospital, Athens, Greece; Palepu Jagannath, Department of Surgical Oncology, Lilavati Hospital and Research Centre, Mumbai, India; Angus C.W. Chan, Surgery Centre, Department of Surgery, Hong Kong Sanatorium and Hospital, Hong Kong, Hong Kong; Wan Yee Lau, Faculty of Medicine, The Chinese University of Hong Kong, Shatin, Hong Kong; Cheng-Hsi Su, Department of Surgery, Cheng Hsin General Hospital, Taipei, Taiwan; Takeyuki Misawa, Department of Surgery, The Jikei University Kashiwa Hospital, Chiba, Japan; Akihiko Horiguchi, Department of Gastroenterological Surgery, Fujita Health University School of Medicine, Aichi, Japan; Nobumi Tagaya, Department Of Surgery, Dokkyo Medical University Koshigaya Hospital, Saitma, Japan; Shuichi Fujioka, Department of Surgery, The Jikei University Kashiwa Hospital, Chiba, Japan; Ryota Higuchi and Masakazu Yamamoto, Department of Surgery, Institute of Gastroenterology, Tokyo Women’s Medical University, Tokyo, Japan; Satoru Shikata, Director, Mie Prefectural Ichishi Hospital, Mie, Japan; Yoshinori Noguchi and Masamichi Yokoe, Department of General Internal Medicine, Japanese Red Cross Nagoya Daini Hospital, Aichi, Japan; Tomohiko Ukai, Department of Family Medicine, Mie Prefectural Ichishi Hospital, Mie, Japan; Daniel Cherqui, Hepatobiliary Center, Paul Brousse Hospital, Villejuif, France; Goro Honda, Department of Surgery, Tokyo Metropolitan Komagome Hospital, Tokyo, Japan; Atsushi Sugioka, Department of Surgery, Fujita Health University School of Medicine, Aichi, Japan; Eduardo de Santibañes, Department of Surgery, Hospital Italiano, University of Buenos Aires, Buenos Aires, Argentina; Avinash Nivritti Supe, Department of Surgical gastroenterology, Seth G S Medical College and K E M Hospital, Mumbai, India; Hiromi Tokumura, Department of Surgery, Tohoku Rosai Hospital, Miyagi, Japan; Masahiro Yoshida, Department of Hemodialysis and Surgery, Ichikawa Hospital, International University of Health and Welfare, Chiba, Department of EBM and Guidelines, Japan Council for Quality Health Care, Tokyo, Japan; Toshihiko Mayumi, Department of Emergency Medicine, School of Medicine University of Occupational and Environmental Health, Fukuoka, Japan; Seigo Kitano, President, Oita University, Oita, Japan; Masafumi Inomata, Department of Gastroenterological and Pediatric Surgery, Oita University Faculty of Medicine, Oita, Japan; Koichi Hirata, Department of Surgery, JR Sapporo Hospital, Hokkaido, Japan;

This article is protected by copyright. All rights reserved.



Yoshinobu Sumiyama, Director, Toho University, Tokyo, Japan; Kazuo Inui, Department of Gastroenterology, Second Teaching Hospital, Fujita Health University, Aichi, Japan

### Figure legends

Figure 1. Detailed bail-out procedures for difficult laparoscopic cholecystectomy: a, Subtotal cholecystectomy; b, Fenestrating (The GB is opened and the cystic duct is closed from inside); c, Reconstituting (closure of the remnant GB wall); d, Fundus first.

Figure 2. Standardized safe steps in laparoscopic cholecystectomy. a: Decompression of a distended GB with needle aspiration (arrow). b: Effective retraction of the GB to develop a plane in the Calot's triangle area and identify its boundaries (countertraction). c: Starting dissection from the posterior leaf of the peritoneum covering the neck of the GB and exposing the GB surface above Rouvière's sulcus (arrow). d: Maintaining the plane of dissection on the GB surface throughout laparoscopic cholecystectomy. e: Dissecting the lower part of the GB bed (at least one-third) to obtain the critical view of safety (broken line). f: Always obtaining the critical view of safety.

Figure 3. Forest plot of the success rate of common bile duct stone removal.

Figure 4. Forest plot of the complication rate of common bile duct stone removal.

Figure 5. Forest plot of the in-hospital mortality rate of common bile duct stone removal.

Figure 6. Forest plot of the operative time and postoperative pain between Needlescopic and conventional laparoscopic cholecystectomy.

## REFERENCES

1. Miyasaka Y, Nakamura M, Wakabayashi G, Pioneers in laparoscopic hepato-biliary-pancreatic surgery. *J Hepatobiliary Pancreat Surg.* doi:10.1002/jhbp.506
2. NIH consensus conference. gallstones and laparoscopic cholecystectomy. *JAMA.* 1993; 269:1018-1024.
3. The role of laparoscopic cholecystectomy (L.C.). guidelines for clinical application. society of american gastrointestinal endoscopic surgeons (SAGES). *Surg Endosc.* 1993; 7:369-370.
4. Yamashita Y, Takada T, Kawarada Y, Nimura Y, Hirota M, Miura F, Mayumi T, Yoshida M, Strasberg S, Pitt HA, de Santibanes E, Belghiti J, Buchler MW et al. Surgical treatment of patients with acute cholecystitis: Tokyo guidelines. *J Hepatobiliary Pancreat Surg.* 2007; 14:91-97.
5. Yamashita Y, Takada T, Strasberg SM, Pitt HA, Gouma DJ, Garden OJ, Buchler MW, Gomi H, Dervenis C, Windsor JA, Kim SW, de Santibanes E, Padbury R et al. TG13 surgical management of acute cholecystitis. *J Hepatobiliary Pancreat Sci.* 2013; 20:89-96.
6. Endo I, Takada T, Hwang TL, Akazawa K, Mori R, Miura F, Yokoe M, Itoi T, Gomi H, Chen MF, Jan YY, Ker CG, Wang HP et al. Optimal treatment strategy for acute cholecystitis based on predictive factors: Japan-taiwan multicenter cohort study. *J Hepatobiliary Pancreat Sci.* 2017; 24:346-361.
7. Okamoto, et al. TG18 Flowchart. in press. JHBPS
8. Tornqvist B, Zheng Z, Ye W, Waage A, Nilsson M. Long-term effects of iatrogenic bile duct injury during cholecystectomy. *Clin Gastroenterol Hepatol.* 2009; 7:1013-8; quiz 915.
9. Tornqvist B, Waage A, Zheng Z, Ye W, Nilsson M. Severity of acute cholecystitis and risk of iatrogenic bile duct injury during cholecystectomy, a population-based case-control study. *World J Surg.* 2016; 40:1060-1067.
10. Iwashita Y, Ohyama T, Honda G, Hibi T, Yoshida M, Miura F, Takada T, Han HS, Hwang TL, Shinya S, Suzuki K, Umezawa A, Yoon YS et al. What are the appropriate

Accepted Article

indicators of surgical difficulty during laparoscopic cholecystectomy? results from a japan-korea-taiwan multinational survey. *J Hepatobiliary Pancreat Sci.* 2016; 23:533-547.

11. Iwashita Y, Hibi T, Ohyama T, Umezawa A, Takada T, Strasberg SM, Asbun HJ, Pitt HA, Han HS, Hwang TL, Suzuki K, Yoon YS, Choi IS et al. Delphi consensus on bile duct injuries during laparoscopic cholecystectomy: An evolutionary cul-de-sac or the birth pangs of a new technical framework? *J Hepatobiliary Pancreat Sci.* 2017. DOI: 10.1002/jhbp.503

12. Morgenstern L, Wong L, Berci G. Twelve hundred open cholecystectomies before the laparoscopic era. A standard for comparison. *Arch Surg.* 1992; 127:400-403.

13. Flum DR, Dellinger EP, Cheadle A, Chan L, Koepsell T. Intraoperative cholangiography and risk of common bile duct injury during cholecystectomy. *JAMA.* 2003; 289:1639-1644.

14. Sakuramoto S, Sato S, Okuri T, Sato K, Hiki Y, Kakita A. Preoperative evaluation to predict technical difficulties of laparoscopic cholecystectomy on the basis of histological inflammation findings on resected gallbladder. *Am J Surg.* 2000; 179:114-121.

15. Hiromatsu T, Hasegawa H, Salamoto E, Komatsu S, Kawai K, Tabata T, et al. Preoperative evaluation of difficulty of laparoscopic cholecystectomy (in Japanese). *Jpn J Gastroenterol Surg.* 2007; 40:1449-1455.

16. Cho KS, Baek SY, Kang BC, Choi HY, Han HS. Evaluation of preoperative sonography in acute cholecystitis to predict technical difficulties during laparoscopic cholecystectomy. *J Clin Ultrasound.* 2004; 32:115-122.

17. Shamiyeh A, Danis J, Wayand W, Zehetner J. A 14-year analysis of laparoscopic cholecystectomy: Conversion--when and why? *Surg Laparosc Endosc Percutan Tech.* 2007; 17:271-276.

18. Cho JY, Han HS, Yoon YS, Ahn KS, Lee SH, Hwang JH. Hepatobiliary scan for assessing disease severity in patients with cholelithiasis. *Arch Surg.* 2011; 146:169-174.

19. Cwik G, Skoczylas T, Wyroslak-Najs J, Wallner G. The value of percutaneous ultrasound in predicting conversion from laparoscopic to open cholecystectomy due to acute cholecystitis. *Surg Endosc.* 2013; 27:2561-2568.

20. Philip Rothman J, Burcharth J, Pommergaard HC, Viereck S, Rosenberg J. Preoperative risk factors for conversion of laparoscopic cholecystectomy to open surgery - A systematic review and meta-analysis of observational studies. *Dig Surg.* 2016; 33:414-423.
21. Ambe PC, Christ H, Wassenberg D. Does the tokyo guidelines predict the extent of gallbladder inflammation in patients with acute cholecystitis? A single center retrospective analysis. *BMC Gastroenterol.* 2015; 15:142-015-0365-4.
22. Low JK, Barrow P, Ower A, Ammori BJ. Timing of laparoscopic cholecystectomy for acute cholecystitis: Evidence to support a proposal for an early interval surgery. *Am Surg.* 2007; 73:1188-1192.
23. Zhu B, Zhang Z, Wang Y, Gong K, Lu Y, Zhang N. Comparison of laparoscopic cholecystectomy for acute cholecystitis within and beyond 72 h of symptom onset during emergency admissions. *World J Surg.* 2012; 36:2654-2658.
24. Hibi T, Iwashita Y, Ohyama T, Honda G, Yoshida M, Takada T, Han HS, Hwang TL, Shinya S, Suzuki K, Umezawa A, Yoon YS, Choi IS et al. The "right" way is not always popular: Comparison of surgeons' perceptions during laparoscopic cholecystectomy for acute cholecystitis among experts from japan, korea and taiwan. *J Hepatobiliary Pancreat Sci.* 2017; 24:24-32.
25. Sugrue M, Sahebally SM, Ansaloni L, Zielinski MD. Grading operative findings at laparoscopic cholecystectomy- a new scoring system. *World J Emerg Surg.* 2015; 10:14-015-0005-x. eCollection 2015.
26. Iwashita Y, Hibi T, Ohyama T, Honda G, Yoshida M, Miura F, Takada T, Han HS, Hwang TL, Shinya S, Suzuki K, Umezawa A, Yoon YS et al. An opportunity in difficulty: Japan-korea-taiwan expert delphi consensus on surgical difficulty during laparoscopic cholecystectomy. *J Hepatobiliary Pancreat Sci.* 2017; 24:191-198.
27. Madding GF. Subtotal cholecystectomy in acute cholecystitis. *Am J Surg.* 1955; 89:604-607.
28. Strasberg SM, Pucci MJ, Brunt LM, Deziel DJ. Subtotal cholecystectomy-"fenestrating" vs "reconstituting" subtypes and the prevention of bile duct injury: Definition of the optimal procedure in difficult operative conditions. *J Am Coll Surg.* 2016; 222:89-96.

29. Elshaer M, Gravante G, Thomas K, Sorge R, Al-Hamali S, Ebdewi H. Subtotal cholecystectomy for "difficult gallbladders": Systematic review and meta-analysis. *JAMA Surg.* 2015; 150:159-168.
30. Henneman D, da Costa DW, Vrouenraets BC, van Wagenveld BA, Lagarde SM. Laparoscopic partial cholecystectomy for the difficult gallbladder: A systematic review. *Surg Endosc.* 2013; 27:351-358.
31. Borzellino G, Sauerland S, Minicozzi AM, Verlato G, Di Pietrantonj C, de Manzoni G, Cordiano C. Laparoscopic cholecystectomy for severe acute cholecystitis. A meta-analysis of results. *Surg Endosc.* 2008; 22:8-15.
32. Lengyel BI, Azagury D, Varban O, Panizales MT, Steinberg J, Brooks DC, Ashley SW, Tavakkolizadeh A. Laparoscopic cholecystectomy after a quarter century: Why do we still convert? *Surg Endosc.* 2012; 26:508-513.
33. Kato K, Matsuda M, Onodera K, Kobayashi T, Kasai S, Mito M. Laparoscopic cholecystectomy from fundus downward. *Surg Laparosc Endosc.* 1994; 4:373-374.
34. Uyama I, Iida S, Ogiwara H, Takahara T, Kato Y, Furuta T, Kikuchi K. Laparoscopic retrograde cholecystectomy (from fundus downward) facilitated by lifting the liver bed up to the diaphragm for inflammatory gallbladder. *Surg Laparosc Endosc.* 1995; 5:431-436.
35. Kelly MD. Laparoscopic retrograde (fundus first) cholecystectomy. *BMC Surg.* 2009; 9:19-2482-9-19.
36. Fullum TM, Kim S, Dan D, Turner PL. Laparoscopic "dome-down" cholecystectomy with the LCS-5 harmonic scalpel. *JSLs.* 2005; 9:51-57.
37. Huang SM, Hsiao KM, Pan H, Yao CC, Lai TJ, Chen LY, Wu CW, Lui WY. Overcoming the difficulties in laparoscopic management of contracted gallbladders with gallstones: Possible role of fundus-down approach. *Surg Endosc.* 2011; 25:284-291.
38. Harilingam MR, Shrestha AK, Basu S. Laparoscopic modified subtotal cholecystectomy for difficult gall bladders: A single-centre experience. *J Minim Access Surg.* 2016; 12:325-329.

39. Nasr MM. An innovative emergency laparoscopic cholecystectomy technique; early results towards complication free surgery. *J Gastrointest Surg.* 2017; 21:302-311.
40. Strasberg SM, Gouma DJ. 'Extreme' vasculobiliary injuries: Association with fundus-down cholecystectomy in severely inflamed gallbladders. *HPB (Oxford).* 2012; 14:1-8.
41. Honda G, Hasegawa H, Umezawa A. Universal safe procedure of laparoscopic cholecystectomy standardized by exposing the inner layer of the subserosal layer (with video). *J Hepatobiliary Pancreat Sci.* 2016; 23:E14-9.
42. Callery MP. Avoiding biliary injury during laparoscopic cholecystectomy: Technical considerations. *Surg Endosc.* 2006; 20:1654-1658.
43. Asbun HJ, Rossi RL, Lowell JA, Munson JL. Bile duct injury during laparoscopic cholecystectomy: Mechanism of injury, prevention, and management. *World J Surg.* 1993; 17:547-51; 551-2.
44. Halpin V, Gupta A. Acute cholecystitis. *BMJ Clin Evid.* 2011; 2011:0411.
45. Gurusamy KS, Davidson C, Gluud C, Davidson BR. Early versus delayed laparoscopic cholecystectomy for people with acute cholecystitis. *Cochrane Database Syst Rev.* 2013; (6):CD005440. doi:CD005440.
46. Cao AM, Eslick GD, Cox MR. Early cholecystectomy is superior to delayed cholecystectomy for acute cholecystitis: A meta-analysis. *J Gastrointest Surg.* 2015; 19:848-857.
47. Cao AM, Eslick GD, Cox MR. Early laparoscopic cholecystectomy is superior to delayed acute cholecystitis: A meta-analysis of case-control studies. *Surg Endosc.* 2016; 30:1172-1182.
48. de Mestral C, Rotstein OD, Laupacis A, Hoch JS, Zagorski B, Alali AS, Nathens AB. Comparative operative outcomes of early and delayed cholecystectomy for acute cholecystitis: A population-based propensity score analysis. *Ann Surg.* 2014; 259:10-15.
49. Strasberg SM, Hertl M, Soper NJ. An analysis of the problem of biliary injury during laparoscopic cholecystectomy. *J Am Coll Surg.* 1995; 180:101-125.

50. Sanjay P, Kulli C, Polignano FM, Tait IS. Optimal surgical technique, use of intra-operative cholangiography (IOC), and management of acute gallbladder disease: The results of a nation-wide survey in the UK and Ireland. *Ann R Coll Surg Engl.* 2010; 92:302-306.
51. Chen CB, Palazzo F, Doane SM, Winter JM, Lavu H, Chojnacki KA, Rosato EL, Yeo CJ, Pucci MJ. Increasing resident utilization and recognition of the critical view of safety during laparoscopic cholecystectomy: A pilot study from an academic medical center. *Surg Endosc.* 2017; 31:1627-1635.
52. Vettoretto N, Saronni C, Harbi A, Balestra L, Taglietti L, Giovanetti M. Critical view of safety during laparoscopic cholecystectomy. *JSLs.* 2011; 15:322-325.
53. Hugh TB, Kelly MD, Mekisic A. Rouviere's sulcus: A useful landmark in laparoscopic cholecystectomy. *Br J Surg.* 1997; 84:1253-1254.
54. Singh K, Ohri A. Anatomic landmarks: Their usefulness in safe laparoscopic cholecystectomy. *Surg Endosc.* 2006; 20:1754-1758.
55. Hussain A. Difficult laparoscopic cholecystectomy: Current evidence and strategies of management. *Surg Laparosc Endosc Percutan Tech.* 2011; 21:211-217.
56. Kaplan D, Inaba K, Chouliaras K, Low GM, Benjamin E, Lam L, Grabo D, Demetriades D. Subtotal cholecystectomy and open total cholecystectomy: Alternatives in complicated cholecystitis. *Am Surg.* 2014; 80:953-955.
57. Ford JA, Soop M, Du J, Loveday BP, Rodgers M. Systematic review of intraoperative cholangiography in cholecystectomy. *Br J Surg.* 2012; 99:160-167.
58. Ludwig K, Bernhardt J, Steffen H, Lorenz D. Contribution of intraoperative cholangiography to incidence and outcome of common bile duct injuries during laparoscopic cholecystectomy. *Surg Endosc.* 2002; 16:1098-1104.
59. Slim K, Martin G. Does routine intra-operative cholangiography reduce the risk of biliary injury during laparoscopic cholecystectomy? an evidence-based approach. *J Visc Surg.* 2013; 150:321-324.



60. Tornqvist B, Stromberg C, Persson G, Nilsson M. Effect of intended intraoperative cholangiography and early detection of bile duct injury on survival after cholecystectomy: Population based cohort study. *BMJ*. 2012; 345:e6457.
61. Tornqvist B, Stromberg C, Akre O, Enochsson L, Nilsson M. Selective intraoperative cholangiography and risk of bile duct injury during cholecystectomy. *Br J Surg*. 2015; 102:952-958.
62. Machi J, Johnson JO, Deziel DJ, Soper NJ, Berber E, Siperstein A, Hata M, Patel A, Singh K, Arregui ME. The routine use of laparoscopic ultrasound decreases bile duct injury: A multicenter study. *Surg Endosc*. 2009; 23:384-388.
63. Gwinn EC, Daly S, Deziel DJ. The use of laparoscopic ultrasound in difficult cholecystectomy cases significantly decreases morbidity. *Surgery*. 2013; 154:909-15; discussion 915-7.
64. Pesce A, Piccolo G, La Greca G, Puleo S. Utility of fluorescent cholangiography during laparoscopic cholecystectomy: A systematic review. *World J Gastroenterol*. 2015; 21:7877-7883.
65. Rogers SJ, Cello JP, Horn JK, Siperstein AE, Schecter WP, Campbell AR, Mackersie RC, Rodas A, Kreuwel HT, Harris HW. Prospective randomized trial of LC+LCBDE vs ERCP/S+LC for common bile duct stone disease. *Arch Surg*. 2010; 145:28-33.
66. ElGeidie AA, ElEbidi GK, Naeem YM. Preoperative versus intraoperative endoscopic sphincterotomy for management of common bile duct stones. *Surg Endosc*. 2011; 25:1230-1237.
67. Tzovaras G, Baloyiannis I, Zachari E, Symeonidis D, Zacharoulis D, Kapsoritakis A, Paroutoglou G, Potamianos S. Laparoendoscopic rendezvous versus preoperative ERCP and laparoscopic cholecystectomy for the management of cholecysto-choledocholithiasis: Interim analysis of a controlled randomized trial. *Ann Surg*. 2012; 255:435-439.
68. Alexakis N, Connor S. Meta-analysis of one- vs. two-stage laparoscopic/endoscopic management of common bile duct stones. *HPB (Oxford)*. 2012; 14:254-259.

69. Nagaraja V, Eslick GD, Cox MR. Systematic review and meta-analysis of minimally invasive techniques for the management of cholecysto-choledocholithiasis. *J Hepatobiliary Pancreat Sci.* 2014; 21:896-901.
70. Koc B, Karahan S, Adas G, Tural F, Guven H, Ozsoy A. Comparison of laparoscopic common bile duct exploration and endoscopic retrograde cholangiopancreatography plus laparoscopic cholecystectomy for choledocholithiasis: A prospective randomized study. *Am J Surg.* 2013; 206:457-463.
71. Zhu HY, Xu M, Shen HJ, Yang C, Li F, Li KW, Shi WJ, Ji F. A meta-analysis of single-stage versus two-stage management for concomitant gallstones and common bile duct stones. *Clin Res Hepatol Gastroenterol.* 2015; 39:584-593.
72. Peng WK, Sheikh Z, Nixon SJ, Paterson-Brown S. Role of laparoscopic cholecystectomy in the early management of acute gallbladder disease. *Br J Surg.* 2005; 92:586-591.
73. Nebiker CA, Baierlein SA, Beck S, von Flue M, Ackermann C, Peterli R. Is routine MR cholangiopancreatography (MRCP) justified prior to cholecystectomy? *Langenbecks Arch Surg.* 2009; 394:1005-1010.
74. Wong HP, Chiu YL, Shiu BH, Ho LC. Preoperative MRCP to detect choledocholithiasis in acute calculous cholecystitis. *J Hepatobiliary Pancreat Sci.* 2012; 19:458-464.
75. Costi R, Gnocchi A, Di Mario F, Sarli L. Diagnosis and management of choledocholithiasis in the golden age of imaging, endoscopy and laparoscopy. *World J Gastroenterol.* 2014; 20:13382-13401.
76. Navarra G, Pozza E, Occhionorelli S, Carcoforo P, Donini I. One-wound laparoscopic cholecystectomy. *Br J Surg.* 1997; 84:695.
77. Naito T. Terminology. In: Mori T, Depri G, eds. *Reduced Port Surgery.* Springer Japan; 2014: 23-26. doi: 10.1007/978-4-431-54601-6.
78. Lurje G, Raptis DA, Steinemann DC, Amygdalos I, Kambakamba P, Petrowsky H, Lesurtel M, Zehnder A, Wyss R, Clavien PA, Breitenstein S. Cosmesis and body image in patients undergoing single-port versus conventional laparoscopic cholecystectomy: A

multicenter double-blinded randomized controlled trial (SPOCC-trial). *Ann Surg.* 2015; 262:728-34; discussion 734-5.

79. Cao ZG, Cai W, Qin MF, Zhao HZ, Yue P, Li Y. Randomized clinical trial of single-incision versus conventional laparoscopic cholecystectomy: Short-term operative outcomes. *Surg Laparosc Endosc Percutan Tech.* 2011; 21:311-313.

80. Evers L, Bouvy N, Branje D, Peeters A. Single-incision laparoscopic cholecystectomy versus conventional four-port laparoscopic cholecystectomy: A systematic review and meta-analysis. *Surg Endosc.* 2016.

81. Wu XS, Shi LB, Gu J, Dong P, Lu JH, Li ML, Mu JS, Wu WG, Yang JH, Ding QC, Zhang L, Liu YB. Single-incision laparoscopic cholecystectomy versus multi-incision laparoscopic cholecystectomy: A meta-analysis of randomized clinical trials. *J Laparoendosc Adv Surg Tech A.* 2013; 23:183-191.

82. Sajid MS, Ladwa N, Kalra L, Hutson KK, Singh KK, Sayegh M. Single-incision laparoscopic cholecystectomy versus conventional laparoscopic cholecystectomy: Meta-analysis and systematic review of randomized controlled trials. *World J Surg.* 2012; 36:2644-2653.

83. Arezzo A, Scozzari G, Famiglietti F, Passera R, Morino M. Is single-incision laparoscopic cholecystectomy safe? results of a systematic review and meta-analysis. *Surg Endosc.* 2013; 27:2293-2304.

84. Markar SR, Karthikesalingam A, Thrumurthy S, Muirhead L, Kinross J, Paraskeva P. Single-incision laparoscopic surgery (SILS) vs. conventional multiport cholecystectomy: Systematic review and meta-analysis. *Surg Endosc.* 2012; 26:1205-1213.

85. Trastulli S, Cirocchi R, Desiderio J, Guarino S, Santoro A, Parisi A, Noya G, Boselli C. Systematic review and meta-analysis of randomized clinical trials comparing single-incision versus conventional laparoscopic cholecystectomy. *Br J Surg.* 2013; 100:191-208.

86. Garg P, Thakur JD, Garg M, Menon GR. Single-incision laparoscopic cholecystectomy vs. conventional laparoscopic cholecystectomy: A meta-analysis of randomized controlled trials. *J Gastrointest Surg.* 2012; 16:1618-1628.

87. Gagner M, Garcia-Ruiz A. Technical aspects of minimally invasive abdominal surgery performed with needlescopic instruments. *Surg Laparosc Endosc*. 1998; 8:171-179.
88. Hsieh CH. Early minilaparoscopic cholecystectomy in patients with acute cholecystitis. *Am J Surg*. 2003; 185:344-348.
89. Novitsky YW, Kercher KW, Czerniach DR, Kaban GK, Khera S, Gallagher-Dorval KA, Callery MP, Litwin DE, Kelly JJ. Advantages of mini-laparoscopic vs conventional laparoscopic cholecystectomy: Results of a prospective randomized trial. *Arch Surg*. 2005; 140:1178-1183.
90. Bisgaard T, Klarskov B, Trap R, Kehlet H, Rosenberg J. Pain after microlaparoscopic cholecystectomy. A randomized double-blind controlled study. *Surg Endosc*. 2000; 14:340-344.
91. Look M, Chew SP, Tan YC, Liew SE, Cheong DM, Tan JC, Wee SB, Teh CH, Low CH. Post-operative pain in needlescopic versus conventional laparoscopic cholecystectomy: A prospective randomised trial. *J R Coll Surg Edinb*. 2001; 46:138-142.
92. Ainslie WG, Catton JA, Davides D, Dexter S, Gibson J, Larvin M, McMahon MJ, Moore M, Smith S, Vezakis A. Micropuncture cholecystectomy vs conventional laparoscopic cholecystectomy: A randomized controlled trial. *Surg Endosc*. 2003; 17:766-772.
93. Cabral PH, Silva IT, Melo JV, Gimenez FS, Cabral CR, Lima AP. Needlescopic versus laparoscopic cholecystectomy. A prospective study of 60 patients. *Acta Cir Bras*. 2008; 23:543-550.

Table 1. Risk factors associated with prolonged operative time and open conversion	
Prolonged operative time [8, 9]	Conversion [15, 16]
Gallbladder wall thickening	Gallbladder wall>4-5 mm on preoperative ultrasound
Incarcerated stones in the gallbladder neck	Age > 60 or 65
Duration of elevated CRP	Male gender
Non-visualized gallbladder on preoperative cholangiography	Acute cholecystitis (TG13 grade II/III)
Body temperature	Contracted gallbladder on ultrasound
Abscess formation	Previous abdominal surgery
BMI	BMI
	ASA score

Table 2. Difficulty score for each intraoperative finding	
Intraoperative findings	score
A. Factors related to inflammation of the gallbladder	
(a) Appearance around the gallbladder	
1. Fibrotic adhesions around the gallbladder due to inflammation	2
2. Partial scarring adhesions around the gallbladder	2
3. Diffuse scarring adhesions around the gallbladder	4
(b) Appearance of the Calot's triangle area	
4. Sparse fibrotic change in the Calot's triangle area	2
5. Dense fibrotic change but no scarring in the Calot's triangle area	3
6. Partial scarring in the Calot's triangle area	4
7. Diffuse scarring in the Calot's triangle area	5
(c) Appearance of the gallbladder bed	
8. Sparse fibrotic change in the gallbladder bed	1
9. Dense fibrotic change but no scarring in the gallbladder bed	2
10. Partial scarring in the gallbladder bed	3
11. Diffuse scarring in the gallbladder bed (includes atrophic gallbladder with no lumen due to severe contraction)	4
(d) Additional findings of the gallbladder and its surroundings	
12. Edematous change around the gallbladder/in the Calot's triangle area/in the gallbladder bed	1
13. Easy bleeding at dissection around the gallbladder/in the Calot's triangle area/in the gallbladder bed	3
14. Necrotic changes around the gallbladder/in the Calot's triangle area/in the gallbladder bed	4
15. Non-iatrogenic, perforated gallbladder wall and/or abscess formation towards the abdominal cavity noted during adhesiolysis around the gallbladder	3
16. Abscess formation towards the liver parenchyma	4
17. Cholecysto-enteric fistula	5
18. Cholecysto-choledochal fistula (included in the expanded classification of Mirizzi syndrome)	6
19. Impacted gallstone in the confluence of the cystic, common hepatic, and common bile duct (included in the expanded classification of Mirizzi syndrome)	5

#### B. Intra-abdominal factors unrelated to inflammation

20. Excessive visceral fat	2
21. Inversion of the gallbladder in the gallbladder bed due to liver cirrhosis	4
22. Collateral vein formation due to liver cirrhosis	4
23. Non-inflammatory (physiological) adhesion around the gallbladder	1
24. Anomalous bile duct	4
25. Gallbladder neck mounting on the common bile duct	3

Expert surgeons participated in a Delphi process and graded the 25 intraoperative findings using the seven-stage scale ranging from 0 to 6 [0: easiest, 6: most difficult]. The median point for each item was set as the difficulty score. [5].

Table 3

#### Proposal for avoiding vasculo-biliary injury based on the Delphi Consensus (2017)

##### How to prevent?

- Effective retraction of the gallbladder to develop a plane in the Calot's triangle area and identify its boundaries (countertraction)
- Creating the critical view of safety
- For persistent hemorrhage, achieving hemostasis primarily by compression and avoiding excessive use of electrocautery or clipping

##### When to stop?

- Severe fibrosis and scarring in Calot's triangle due to inflammation
- Impacted gallstone in the confluence of the cystic, common hepatic, and common bile duct (included in the expanded classification of Mirizzi syndrome)

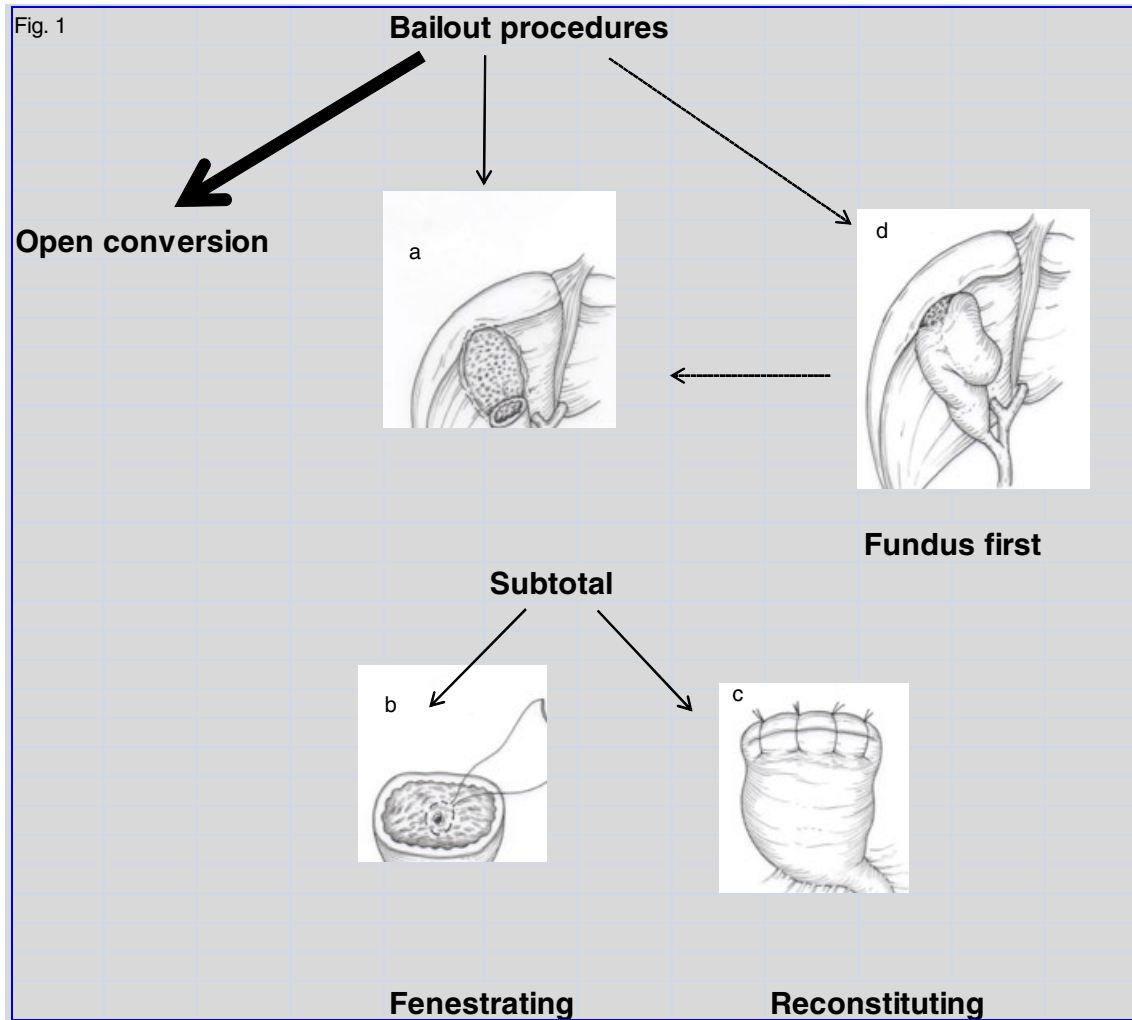
##### Where to stop?

- Critical view of safety
- Calot's triangle area

##### What are the alternative (bailout procedure)?

- Open conversion
- Subtotal (partial) cholecystectomy
- Fundus first (dome down)
- Cholecystostomy (drainage only)





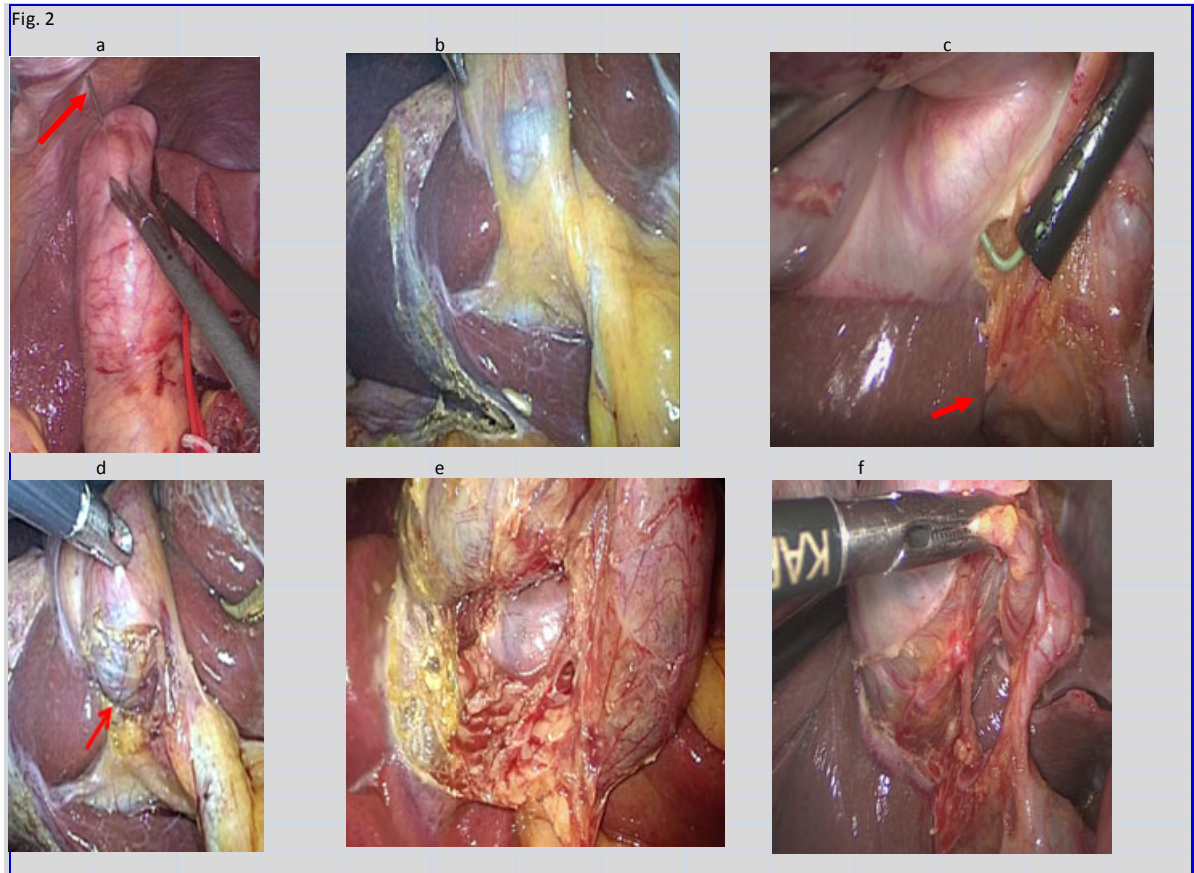


Fig. 3

Success rate of complete extraction of common bile duct stone.

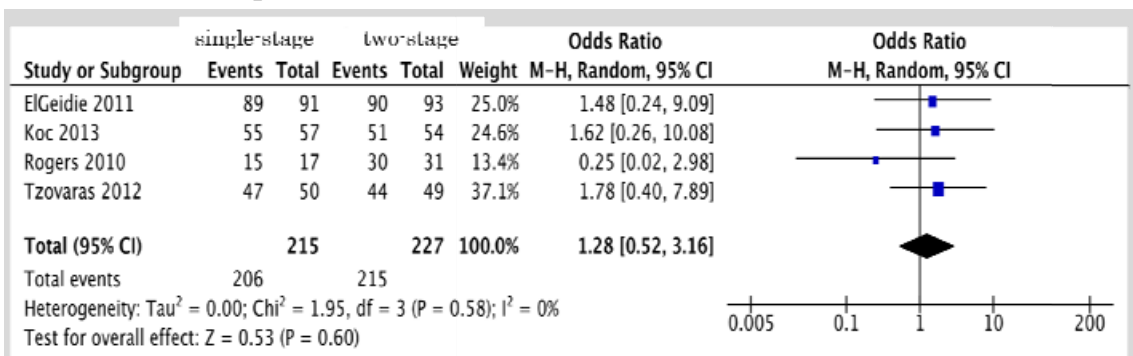


Fig. 4

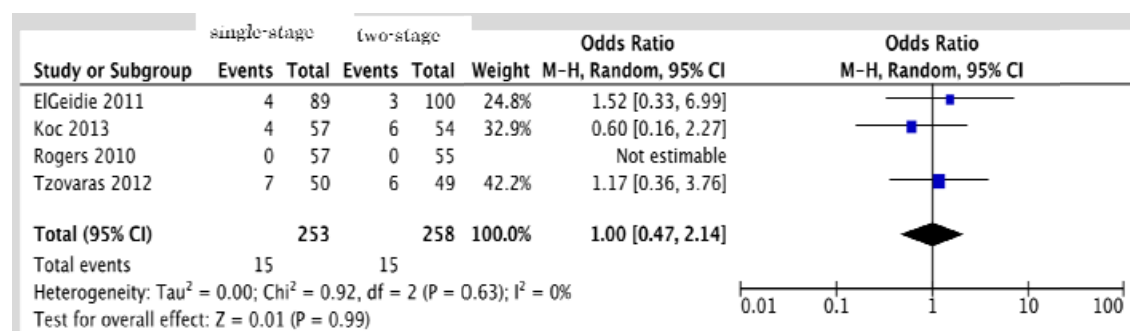
**Complication rate of complete extraction of common bile duct stone.**

Fig.5

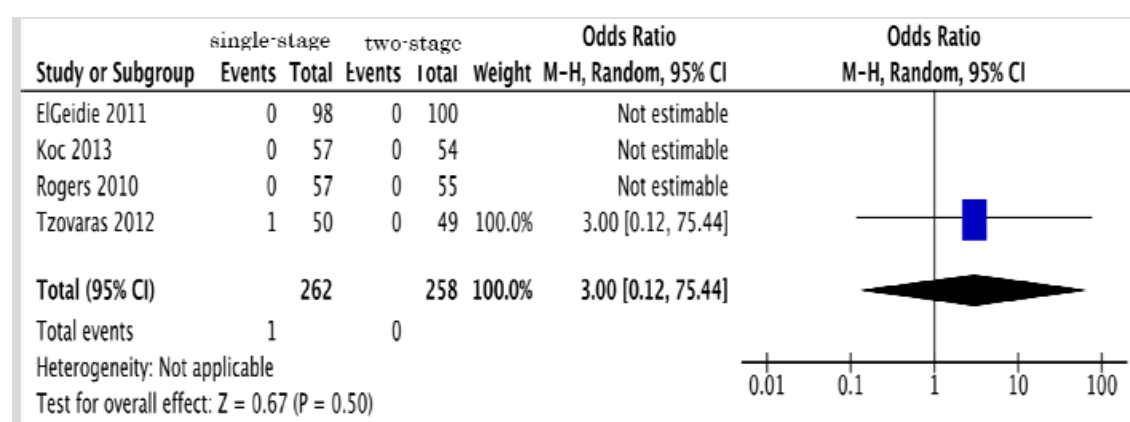
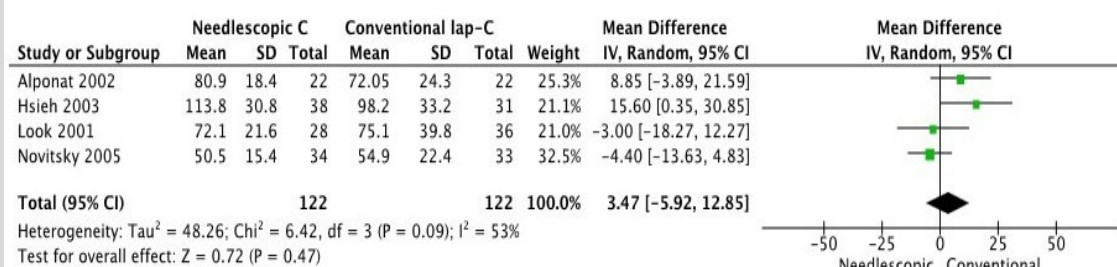
**In-hospital mortality of complete extraction of common bile duct stone.**

Fig.6

# Operative time and postoperative pain between needlescopic and conventional laparoscopic cholecystectomy.

## operative time



## postoperative pain

