

# Toxicological Effects of Ethanolic Stem Bark Extract of *Xylopi* *aethi* *opica* on Testicular Oxidative Stress Markers and Histology of Male Rats

Elias Adikwu<sup>1,\*</sup>, Ben Enoluomen Ehigiator<sup>2</sup>

<sup>1</sup>Department of Pharmacology and Toxicology, Faculty of Pharmacy, Niger Delta University, Nigeria

<sup>2</sup>Department of Pharmacology and Toxicology, Faculty of Pharmacy, Madonna University, Nigeria

Corresponding author\*  
adikwuelias@gmail.com

Manuscript received: 22 April, 2020. Revision accepted: 10 May, 2020. Published: 11 May, 2020.

## Abstract

Impairment in testicular function can occur through perturbations in testicular oxidative stress markers and histology. *Xylopi*  
*aethi*  
*opica* (XE) is used to enhance fertility in males, but with information gap on its effect on testicular oxidative stress markers and histology. The present study assessed the effects of ethanolic stem bark extract of *Xylopi*  
*aethi*  
*opica* (EEXA) on testicular oxidative stress markers and histology of male albino rats. Sixty adult male albino rats (200g-250g) were randomly grouped into 4 (A-D) of 15 rats per group. The rats in the control group A (A1-A3) were administered per oral (p.o) with water (0.2 mL/day) for 15, 30 and 60 days respectively. The rats in groups B (B1-B3), C(C1-C3) and D (D1-D3) were administered p.o with EEXA (200, 400 and 800 mg/kg/day) for 15, 30 and 60 days respectively. The rats were anesthetized at the termination of EEXA administration and were dissected and testes removed. The testes were weighed and evaluated for oxidative stress markers and histology. Testicular weights were decreased in a dose and-time dependent fashion in EEXA-treated rats. Significant decreases in testicular superoxide dismutase, glutathione, catalase, and glutathione peroxidase levels with significant increases in malondialdehyde levels in a dose and time-dependent fashion were observed in rats administered with EEXA. Testicular histology showed cellular necrosis, degeneration and loss of interstitial tissues in rats administered with EEXA. This study observed that EEXA perturbed testicular oxidative markers and histology. Its use may impair testicular function.

**Keywords:** *Xylopi*  
*aethi*  
*opica*; testis; oxidative stress; histology; rat.

## INTRODUCTION

Infertility is defined as the inability to conceive after 1 year of regular unprotected sexual intercourse (Rowe *et al.*, 1993). Infertility can be caused by a number of factors including drugs and exposure to chemical substances (Slade *et al.*, 2007). One of the proposed mechanisms by which drugs and chemical substances cause infertility is through the induction of oxidative stress via uncontrollable activity of reactive oxygen species (ROS) (Geng *et al.*, 2015; Alahmar, 2019). Studies have shown that 40%–88% of infertile patients have high levels of seminal ROS (Lewis *et al.*, 1995). Increased ROS can lead to testicular redox imbalance, reduced sperm quality and increased sperm DNA damage. Spermatozoa are highly vulnerable to the deleterious activities of excess ROS because of the presence of unsaturated fatty acids found in their cell membranes. The unsaturated fatty acids undergo oxidation which is detrimental to sperm cell, germ cell membrane, eventually inducing cell death (Proudfoot, 2007). Excess ROS can also damage biomolecules (DNA, lipids and proteins) thus, altering the morphology

and functions of the testes (Uzunhisarcikli *et al.*, 2007; Afolabi *et al.*, 2018).

In traditional medicine, the use of herbal remedies to treat ailments including infertility is one of the most important therapeutic approaches used by man (Kashani *et al.*, 2017). Evidence based herbal remedies can serve as effective treatments for infertility among males and females. Herbal remedies produced from special plant parts are believed to improve reproductive organ functions, hormonal system, and sex drive (Kashani *et al.*, 2017). However, the indiscriminate use of herbal remedies to enhance fertility is becoming worrisome due to possible adverse effects on reproduction function (Leke, 2018). Studies using animals have shown spermatogenesis arrest, impaired gonadal hormone function, distorted testicular morphology and altered testicular redox status caused by some herbal products (Kusemiju *et al.*, 2012).

*Xylopi*  
*aethi*  
*opica* (Annonaceae) (XE) is an aromatic tree that grows up to 15-30 m high. It is native to lowland rainforest and moist fringe forest in savannah zones of Africa (Orwa *et al.*, 2009). XE is commonly used in traditional medicine for the treatment of diseases

(Ogbonnia *et al.*, 2008). Its bark and leaves are used to treat boils, sores, wounds and cuts. The stem bark is used in combination with other medicinal plants as topical remedy for post-partum breast infections. The decoction of its fruit is used as treatment for bronchitis, rheumatism, asthma, and dysenteric conditions. Its fruit and bark extracts are also used as tonic to facilitate or stimulate fertility (Burkill, 1985) which has not been proven scientifically. However, we have shown that the ethanolic stem bark extract of XE decreased sperm quality and impaired reproductive hormones in male albino rats (Ehigiator and Adikwu, 2020). This study further examined the toxicological effects of the ethanolic stem bark extract of *Xylopiya aethiopica* (EEXA) on testicular oxidative stress markers and morphology of male albino rats. This study is imperative due to the fact that experimentally, anti-fertility effects of xenobiotics have been associated with perturbations in testicular oxidative stress markers and histology (Agarwal *et al.*, 2005)

## MATERIALS AND METHODS

### Plant material

XE stem bark was sourced from Imo State, Nigeria and was identified at the Federal Ministry of Environment and Forestry Research Institute of Nigeria, Benin City, Edo State. XE stem bark was air dried and powdered using mortar, pestle and manual grinder. Thereafter, 900g of the powder was macerated in 200mL of ethanol for 72 hours with intermittent shaking. The resultant extract was filtered at the end of maceration. The filtrate was concentrated using a rotary evaporator and the yield of the extract was used for this study.

### Animals

In bred adult male albino rats (200g-250g) were sourced from the Department of Pharmacology and Toxicology, Madonna University, Nigeria. The rats were housed in clean gauze cages with free access to diet and water and maintained under standard laboratory conditions. The rats were acclimatized for 2 weeks prior to the experiment. The study was approved by the Research Ethics Committee of the Department of Pharmacology and Toxicology, Madonna University, Nigeria. The rats were handled according to the recommendations of the research ethics committee.

### Animal grouping and treatment

- Sixty adult male albino rats were randomized into 4 groups (A-D) of 15 rats each. Each group was further divided into 3 subgroups of 5 rats each.
- Group A which served as control was administered per oral (p.o) with water (0.2mL/day) for 15, 30 and 60 days.
- Group B (B1-B3) was administered p.o with EEXA (200mg/kg/day) for 15, 30 and 60 days.

- Group C (C1-C3) was administered p.o with EEXA (400mg/kg/day) for 15, 30 and 60 days.
- Group D (D1-D3) was administered p.o with EEXA (800mg/kg/day) for 15, 30 and 60 days.

### Animal sacrifice, collection of samples and oxidative stress assay

The rats were anesthetised at end of extract administration after overnight fast. Testes were excised and washed in cold physiological saline. The testes were homogenized in 0.1 M Tris-HCl solution buffered (pH 7.4) and centrifuged at 3000 g for 20 min. The supernatants were collected and assessed for oxidative stress markers. Testicular total protein was measured according to Gonall *et al.* (1949) whereas malondialdehyde (MDA) was assayed as reported by Buege and Aust, (1978). Reduced glutathione (GSH) was analysed according to Sedlak and Lindsay, (1968) whereas superoxide dismutase (SOD) was assayed as reported by Sun and Zigma, (1978). The method of Aebi, (1984) was used to determine catalase (CAT) whereas glutathione peroxidase (GPx) was assessed according to Rotruck *et al.* (1973).

### Histological examination of the testes

Testicular tissues were routinely processed and dehydrated in graded alcohol and embedded in paraffin wax. Sections 3-5µm thick were prepared using a rotary microtome and stained with hematoxylin and eosin (H and E) and viewed with the aid of a light microscope for histological changes.

### Statistical analysis

Graph pad Prism 5.03 (GraphPad Software Inc., CA, USA) statistical package was used for the analysis of data. Results are expressed as mean  $\pm$  standard error of mean (SEM). Results were subjected to two-way analysis of variance (ANOVA) followed by *Tukey's multiple comparison test*. Values at  $P < 0.05$ ; 0.01 and 0.001 were considered significant.

## RESULTS

Testicular weights were decreased in a dose and time-dependent fashion in rats administered with EEXA (200, 400 and 800 mg/kg) when compared to control (**Table 1**). The decrease in testicular weight was significant at  $p < 0.05$  in rats administered with EEXA (200 mg/kg) for 60 days whereas decreases were significant at  $p < 0.01$  in rats administered with EEXA (400 and 800 mg/kg) for 30 and 60 days when compared to control (**Table 1**). The administration of EEXA produced dose and time-dependent increases in testicular MDA levels when compared to control (**Table 2**). The increases were significant at  $p < 0.05$  and  $p < 0.001$  in rats administered with EEXA (800 and 400 mg/kg) for 15 and 30 days

respectively when compared to control. However, at  $p<0.001$  increase was significant in rats administered with EEEXA (800mg/kg) for 60 days when compared to control (**Table 2**). Furthermore, the administration of EEEXA decreased testicular SOD, CAT, GSH and GPx levels in a dose and time- dependent fashion when compared to control (**Tables 3-6**). Testicular SOD, CAT, GSH and GPx levels were significantly decreased at  $p<0.05$  in rats administered with EEEXA (200 and 400 mg/kg) for 15 and 30 days. On the other hand, significant decreases at  $p<0.01$  and  $p<0.001$  were observed in rats administered with EEEXA (200, 400 and 800mg/kg) for 60 days when compared to control (**Tables 3-6**). H and E stained section of the testis of control rat showed normal histology (**Figure A**). In contrast, the testis of rat administered with EEEXA (800mg/kg) for 15 days showed necrosis, loss of interstitial tissues and cellular degeneration (**Figure B**). The testis of rat administered with EEEXA (800mg/kg) for 30 days showed enlarged interstitial space, loss of interstitial tissues, and cellular degeneration (**Figure C**). The testis of rat administered with EEEXA (800mg/kg) for 60 days showed loss of interstitial tissues, cellular degeneration and necrosis (**Figure D**).

**Table 1.** Effect of ethanolic stem bark extract of *Xylopi* *aethiopi*ca on relative testicular weight of albino rats.

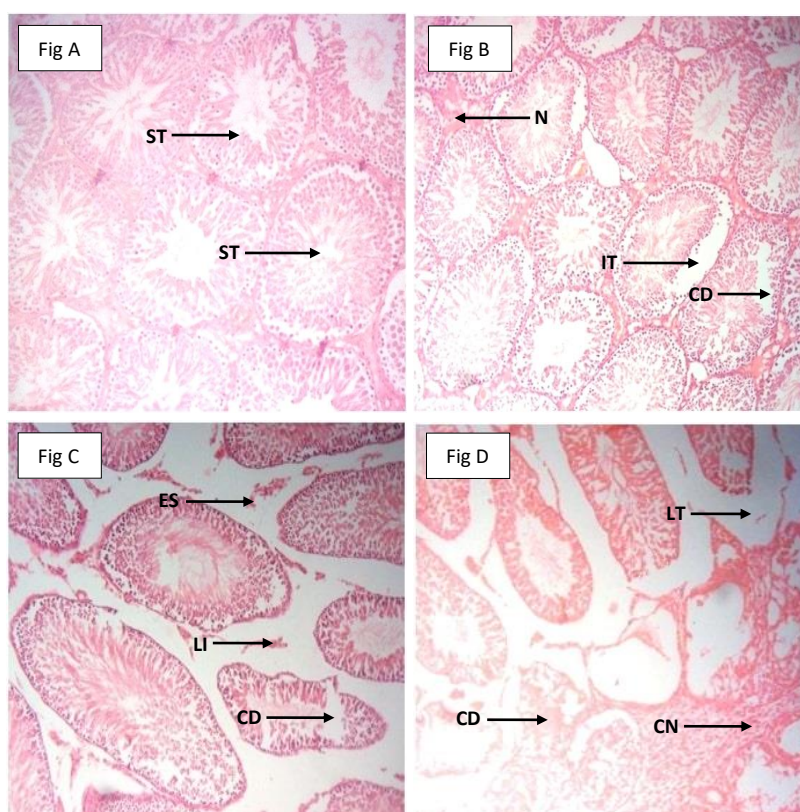
| Dose (mg/kg)   | 15 Days     | 30 Days      | 60 Days      |
|----------------|-------------|--------------|--------------|
| <b>Control</b> | 0.71± 0.03  | 0.72± 0.05   | 0.70± 0.01   |
| 200            | 0.67± 0.02  | 0.62± 0.07   | 0.41± 0.06*  |
| 400            | 0.50± 0.06* | 0.40± 0.11** | 0.30± 0.03** |
| 800            | 0.43± 0.04* | 0.31± 0.36** | 0.25± 0.44** |

Data are expressed as mean ±SEM, n=5, \*  $p<0.05$  when compared to control \*\*  $p<0.01$  when compared to control

**Table 2.** Effect of ethanolic stem bark extract of *Xylopi* *aethiopi*ca on testicular malondialdehyde of albino rats.

| Dose (mg/kg)   | 15 Days      | 30 Days      | 60 Days        |
|----------------|--------------|--------------|----------------|
| <b>Control</b> | 0.46 ± 0.09  | 0.42 ± 0.01  | 0.45 ± 0.04    |
| 200            | 0.47 ± 0.05  | 0.48 ± 0.03  | 0.78 ± 0.05*   |
| 400            | 0.65± 0.03*  | 0.72± 0.07*  | 1.00 ± 0.03**  |
| 800            | 0.76 ± 0.08* | 0.89± 0.04** | 1.45 ± 0.07*** |

Data are expressed as mean ±SEM, n=5 \* $p<0.05$  when compared to control \*\* $p<0.01$  when compared to control, \*\*\*at  $p<0.001$  when compared to control



**Figure 1.** Fig A. The testis of control rat showing normal seminiferous tubules (ST). Fig B: Testis of rat treated with EEEXA(800mg/kg) for 15 days showing necrosis (N) loss of interstitial tissue (IT) and cellular degeneration (CD). Fig C: Testis of rat treated with EEEXA (800 mg/kg) for 30 days showing enlarged interstitial space (ES), loss of interstitial tissues (LI), and cellular degeneration (CD). Fig D: Testis of rat treated with EEEXA (800mg/kg) for 60 days showing loss of interstitial tissues (LT) cellular degeneration (CD) and necrosis (CN) (H&E)x 200 .

**Table 3.** Effect of ethanolic stem bark extract of *Xylopi aethiopic a* on testicular superoxide dismutase of albino rats.

| Dose (mg/kg)   | 15 Days       | 30 Days       | 60 Days        |
|----------------|---------------|---------------|----------------|
| <b>Control</b> | 17.5 ± 2.63   | 16.9 ± 1.69   | 17.9 ± 2.00    |
| 200            | 13.4 ± 0.19*  | 10.7 ± 1.11*  | 7.62 ± 0.47**  |
| 400            | 9.14 ± 0.55*  | 6.32 ± 0.35*  | 4.57 ± 0.02**  |
| 800            | 6.26 ± 0.32** | 3.68 ± 0.19** | 1.17 ± 0.04*** |

Data are expressed as mean ±SEM, n=5 \*p<0.05 when compared to control \*\*p<0.01 when compared to control, \*\*\*at p<0.001 when compared to control

**Table 4.** Effect of ethanolic stem bark extract of *Xylopi aethiopic a* on testicular catalase of albino rats.

| Dose (mg/kg)   | 15 Days       | 30 Days       | 60 Days        |
|----------------|---------------|---------------|----------------|
| <b>Control</b> | 25.3 ± 3.00   | 26.5 ± 2.57   | 26.9 ± 3.90    |
| 200            | 20.1 ± 2.25*  | 15.8 ± 1.00*  | 9.37 ± 0.77**  |
| 400            | 15.6 ± 1.53*  | 9.96 ± 0.21*  | 6.44 ± 0.62**  |
| 800            | 9.90 ± 0.61** | 6.32 ± 0.51** | 2.51 ± 0.54*** |

Data are expressed as mean ±SEM, n=5 \*p<0.05 when compared to control \*\*p<0.01 when compared to control, \*\*\*at p<0.001 when compared to control

**Table 5.** Effect of ethanolic stem bark extract of *Xylopi aethiopic a* on testicular glutathione of albino rats.

| Dose (mg/kg)   | 15 Days       | 30 Days       | 60 Days        |
|----------------|---------------|---------------|----------------|
| <b>Control</b> | 15.0 ± 0.11   | 16.7 ± 1.04   | 15.9 ± 0.33    |
| 200            | 10.9 ± 0.62*  | 7.08 ± 0.39*  | 5.43 ± 0.57**  |
| 400            | 7.32 ± 0.65*  | 5.61 ± 0.91** | 3.24 ± 0.73*** |
| 800            | 5.14 ± 0.58** | 3.65 ± 0.63** | 1.22 ± 0.09*** |

Data are expressed as mean ±SEM, n=5 \*p<0.05 when compared to control \*\*p<0.01 when compared to control, \*\*\*at p<0.001 when compared to control

**Table 6.** Effect of ethanolic stem bark extract of *Xylopi aethiopic a* on testicular glutathione peroxidase of albino rats.

| Dose (mg/kg)   | 15 Days       | 30 Days       | 60 Days        |
|----------------|---------------|---------------|----------------|
| <b>Control</b> | 20.2 ± 2.55   | 20.9 ± 2.43   | 21.9 ± 2.78    |
| 200            | 15.7 ± 1.25*  | 11.7 ± 1.00*  | 8.99 ± 0.52**  |
| 400            | 11.6 ± 0.11*  | 9.05 ± 0.61*  | 5.76 ± 0.28**  |
| 800            | 8.48 ± 0.32** | 6.71 ± 0.22** | 2.32 ± 0.32*** |

Data are expressed as mean ±SEM, n=5 \*p<0.05 when compared to control \*\*p<0.01 when compared to control, \*\*\*at p<0.001 when compared to control

## DISCUSSION

One of the primary objectives of the preclinical toxicological assessment of xenobiotics is the identification of target organs which can help clinicians to monitor the adverse profile of xenobiotics during clinical development. Experimentally, perturbation in testicular weight is an index for the adverse effect of xenobiotics on testicular function (Stevens and Gallo, 1989). The current study observed decreases in testicular weights in a dose and time-dependent fashion

in EEXA- administered rats. Testis contains antioxidants including SOD, CAT, GSH, and GPx which prevent free radical-induced damage (Quinn and Payne, 1984). Free radicals especially ROS are very important for cell signalling and essential physiological functions in the testis. However, excessive production of free radicals can alter cellular redox balance through oxidative stress thereby disrupting normal biological functions. The male reproductive system especially the testes are susceptible to ROS-induced oxidative stress (Sabeti *et al.*, 2016; Asadi *et al.*, 2017). Most health related issues that impaired testicular function have been associated with ROS-induced oxidative stress and decreased testicular antioxidant defence (Halliwell, 2006). The present study observed dose and time-dependent decreases in testicular SOD, CAT, GSH and GPx levels in rats administered with EEXA. This observation is a sign of testicular oxidative stress caused by ROS. The overwhelming activity of ROS in the testis might have surpassed the regulatory capacity of antioxidants leading to their depletion.

ROS production is regulated by antioxidants to prevent oxidative damage, including lipid peroxidation (LPO). LPO is a ROS-induced oxidation of polyunsaturated fatty acids. LPO has been related to various health conditions including infertility because of the oxidative products produced that can be detrimental to testicular function (Nam, 2011). The present study assayed testicular MDA level to ascertain the extent and magnitude of testicular LPO caused by EEXA. Testicular MDA levels were elevated in a dose and time-dependent fashion in EEXA administered rats. This observation can be attributed to excess ROS production which oxidized testicular polyunsaturated fatty acids.

Furthermore, the present study correlates perturbation in testicular redox status with testicular morphology of EEXA-administered rats. The testes of EEXA administered rats showed varying degrees of damage including necrosis, loss of interstitial tissues, and cellular degeneration. The present observation can be attributed to EEXA-induced testicular oxidative stress causing LPO. Extensive LPO in biological membranes can cause loss of fluidity, decrease membrane potential, increased permeability and eventual rupture leading to release of cell and organelle contents. Damage to lipids can alter and modify cellular membranes, cellular function and structure (Esterbauer *et al.*, 1991).

## CONCLUSION

The findings in this study showed that EEXA perturbed testicular oxidative stress markers and morphology in a dose and time-dependent fashion. Its use may impair testicular function.

**Acknowledgment:** The authors appreciate animal handling by Mr Eze Ihukumere of the Department of

Pharmacology and Toxicology, Faculty of Pharmacy, Madonna University, Nigeria.

**Source of fund:** None

**Conflict of interest:** Authors declare no conflict of interest

## REFERENCES

- Aebi H. 1984. Catalase in vitro. *Methods Enzymol*, 105:121- 6.
- Afolabi, OK, Wusu AD, Ugbaja R, and Fatoki JO 2018. Aluminium phosphide-induced testicular toxicity through oxidative stress in Wistar rats: Ameliorative role of hesperidin. *ToxRes and Appl* 2: 1–11
- Agarwal A, Prabakaran, SA. 2005. Oxidative stress and antioxidants in male infertility: a difficult balance. *Iran J Reprod Med* 3; 1-8
- Alahmar AT. 2019. Role of Oxidative Stress in Male Infertility: An Updated Review *J Hum Reprod Sci*. 12(1): 4–18
- Asadi N, Bahmani M, Kheradmand A, Rafieian-Kopaei M 2017. The Impact of Oxidative Stress on Testicular Function and the Role of Antioxidants in Improving it: A Review. *J Clin Diagn Res*. 11(5):1-5
- Buege JA, Aust SD. 1997. Microsomal lipid peroxidation. *Methods Enzymol*. 52:302-10.
- Burkill, H. M 1985. Entry for *Xylopia aethiopica* Dunal A. Rich.: family Annonaceae". The useful plants of west tropical Africa, Vol 1 (JSTOR). Retrieved 1 January 2013.
- Ehigiator BE, Adikwu E. 2020. Toxicity study of ethanolic stem bark extract of *Xylopia aethiopica* on fertility indexes in male rats: An experimental study. *Int J ReprodBioMed*2020; 18: 1–10
- Esterbauer H, Schaur R, J, Zoilner J. 1991. Chemistry and biochemistry of 4-hydroxynonenal malondialdehyde and related aldehydes (Review). *Free Radic Biol Med*. 11:82-128.
- Geng X, Shao H, Zhang Z, Ng JC, Peng C 2015. Malathion-induced testicular toxicity is associated with spermatogenic apoptosis and alterations in testicular enzymes and hormone levels in male Wistar rats. *Environ Toxicol Pharmacol* 39(2):659–667
- Gornall AG, Bardawill CJ, David MM. 1949. Determination of serum proteins by means oof the biureto reaction. *J Biol Chem*. 177:751-66.
- Halliwell B. 2006. Oxidative stress and neurodegeneration: where are we now? *J Neurochem*. 58:1634–36.
- Kashani L, Akhondzadeh S 2017. Female Infertility and Herb. *Med* 16, 61: 1-7
- Kusemiju TO, Yama OE, Okanlawon AO. 2012. Effect of Carica papaya bark extract on oxidative stress parameters in testes of male albino rats; *Int. J. Appl. Res. Nat. Prod*. 4(4):1-6
- Leke, R. Reproductive health in Cameroun. Geneva, WHO. Collaborating centre for Research in Human Reproduction. 2008
- Lewis SE, Boyle PM, Mckinney KA, Young IS, Thompson W. 1995. Total antioxidant capacity (TAC) of seminal plasma is different in fertile and infertile men. *Fertil Steril*. 64:868–70
- Nam T. 2011. Lipid Peroxidation and Its Toxicological Implications *Toxicol Res*. 27(1): 1–6.
- Ogbonnia, S, Adekunle, A.A, Bosa, M.K, and Enwuru, V.N. 2008. Evaluation of acute and sub-acute toxicity of *Alstonia congensis* Engler bark and *Xylopia aethiopca* (Dunal) A. Rich (Annonaceae) fruits mixtures used in treatments of diabetes. *African J Biotechnol*. 7: 701-705
- Orwa, C., Mutua, A., Kindt, R., Jamnadass, R. and Simons, A. Agroforestry Database:a tree reference and selection guide 2009. version 4.0 (<http://www.worldagroforestry.org/af/treedb/>)
- Proudfoot AT. 2009. Aluminium and zinc phosphide poisoning. *Clin Toxicol*. 47: 89–100.
- Quinn PG, Payne AH. 1984. Oxygen mediated damage of microsomal cytochrome P-450 enzymes in cultured leydig cells: Role in steroid genic desensitization. *J Biol Chem*. 259:4130–15
- Rotruck JT, Pope AL, Ganther HE, Swanson AB, Hafeman DG, Hoekstra WG. 1997. Selenium: biochemical role as a component of glutathione peroxidase. *Scie*. 179:588-90.
- Rowe P, Comhaire FH, Hargreave T. WHO Manual for the Standardized Investigation of the Infertile Couple. Cambridge: Cambridge University Press; 1993.
- Sabeti P, Pourmasumi S, Rahiminia T, Akyash F and Reza A. Talebi. 2016. Etiologies of sperm oxidative stress *Int J Reprod BioMed*. 14; 231-240
- Sedlak J, Lindsay RH. 1986. Estimation of total, protein-bound, and nonprotein sulfhydryl groups in tissue with Ellman's reagent. *Anal Biochem*. 25:192-205.
- Slade P, O'Neill C, Simpson AJ, Lashen H. 2007. The relationship between perceived stigma, disclosure patterns, support and distress in new attendees at an infertility clinic. *Hum Reprod*. 22:2309–17
- Stevens K R, Gallo M A: Practical considerations in the conduct of chronic toxicity studies. In: Principles and Methods of Toxicology. Raven Press, New York, Edition 4, 1989: 237-250.
- Sun M, Zigma S. 1978. An Improved spectrophotometer assay of superoxide dismutase based on epinephrine antioxidation. *Anal Biochem*. 90:81-9.
- Uzunhisarcikli M, Kalender Y, Dirican K, Kalender S, Ogutcu A, Buyukkomurcu F 2007. Acute, subacute and subchronic administration of methyl parathioninduced testicular damage in male rats and protective role of vitamins C and E. *Pestic Biochem Physiol* 87(2):115–122

**THIS PAGE INTENTIONALLY LEFT BLANK**