

Tracheobronchial Manifestations of *Aspergillus* Infections

Rafal Krenke and Elzbieta M. Grabczak

*Department of Internal Medicine, Pneumology and Allergology, Medical University of Warsaw,
02-097 Warsaw, Poland*

Received 20 April 2011; Accepted 4 October 2011

Academic Editor: K. Kayser

Human lungs are constantly exposed to a large number of *Aspergillus* spores which are present in ambient air. These spores are usually harmless to immunocompetent subjects but can produce a symptomatic disease in patients with impaired antifungal defense. In a small percentage of patients, the trachea and bronchi may be the main or even the sole site of *Aspergillus* infection. The clinical entities that may develop in tracheobronchial location include saprophytic, allergic and invasive diseases. Although this review is focused on invasive *Aspergillus* tracheobronchial infections, some aspects of allergic and saprophytic tracheobronchial diseases are also discussed in order to present the whole spectrum of tracheobronchial aspergillosis. To be consistent with clinical practice, an approach basing on specific conditions predisposing to invasive *Aspergillus* tracheobronchial infections is used to present the differences in the clinical course and prognosis of these infections. Thus, invasive or potentially invasive *Aspergillus* airway diseases are discussed separately in three groups of patients: (1) lung transplant recipients, (2) highly immunocompromised patients with hematologic malignancies and/or patients undergoing hematopoietic stem cell transplantation, and (3) the remaining, less severely immunocompromised patients or even immunocompetent subjects.

KEYWORDS: *Aspergillus*, *Aspergillus* tracheobronchitis, tracheobronchial aspergillosis, pseudomembranous tracheobronchitis, ulcerative tracheobronchitis, obstructing bronchial aspergillosis, invasive *Aspergillus* pulmonary diseases, fungal tracheobronchitis, allergic bronchopulmonary aspergillosis (ABPA), mucoid impaction

1. INTRODUCTION

Aspergillus forms a genus of ubiquitous, dimorphic molds present in soil, various types of organic debris, water, indoor environment, and many other sites [1, 2]. Airborne *Aspergillus* spores are present virtually everywhere in the atmosphere and are small enough (2–3 μm) to be regularly inhaled into the lower airways [1, 2]. However, due to efficient natural antifungal defense mechanisms (i.e., mucosal barriers, macrophage and neutrophil function) symptomatic pulmonary infections in otherwise healthy subjects are extremely rare. Conversely, the impairment of these mechanisms (local or systemic) significantly increases the risk of airway colonization and progression to various *Aspergillus*-related pulmonary disorders [3–5].

Although more than 250 *Aspergillus* species have been identified, only a minority of them are associated with human diseases [1, 6–8]. *Aspergillus fumigatus* is by far the most common pathogen involved in 50–60% of all *Aspergillus* infections. Three other species which are a relatively common cause of human diseases are: *A. flavus*, *A. niger*, and *A. terreus*. Each of these species may be responsible for 10–15% of invasive human diseases [9–11]. Other species, for example, *A. nidulans* and *A. ustus* are only occasionally identified and constitute less than 2% of isolates in patients with invasive *Aspergillus* infections [9–11]. The predominance of *A. fumigatus* infections in patients with tracheobronchial involvement is even more significant. Karnak et al. reviewed 121 cases reported in the literature, and found that in 76 (63%) patients with diverse *Aspergillus* tracheobronchial infections *A. fumigatus* was identified as the cause of the disease. *A. flavus*, *A. niger*, and *A. nidulans* were cultured in 5 (4.1%), 4 (3.3%), and 2 (1.7%) cases, respectively, while, in 34 (28%), data regarding the species were not available [12].

1.1. Host-Fungus Relationships and Classifications of *Aspergillus*-Related Respiratory Diseases

The wide clinical spectrum of pulmonary aspergillosis reflects the complex relationship between the number and virulence of organisms and the status of the patient's antifungal defense. As different host-dependent anatomical and immunological factors are the key prerequisite for the development of various clinical entities, the general classification of *Aspergillus*-related lung diseases is based on the type of the host-fungus relationship. This includes saprophytic infections, allergic pulmonary diseases, invasive disease, and toxic reactions [13] (Figure 1). Although this reasonable classification presents a spectrum of *Aspergillus*-related pulmonary diseases in humans, it does not address some aspects of these conditions. For example, it does not reflect the anatomical location of the disease. Thus, the diagram shown in Figure 1 might be further completed by adding subsequent rows in which anatomical location and/or disease subtype would be presented.

Since the anatomical site of the disease plays a crucial role in development of specific signs and symptoms as well as determines the diagnostic and therapeutic strategy, a simple, anatomical classification of *Aspergillus*-related respiratory disease is also used in clinical practice (Table 1).

In all anatomical locations, a spectrum of *Aspergillus*-related disorders involving various host-fungus relationships (saprophytic, allergic, and invasive) may develop. It is important to realize that, on rare occasions, one distinct *Aspergillus*-related entity may change to another; for example, an aspergilloma may progress to semiacute invasive or invasive pulmonary aspergillosis (IPA) [13].

Some of the *Aspergillus*-related respiratory diseases are well defined and common; others are unusual but recognized; still, others are rare and controversial [6]. *Aspergillus*-related upper airway and pulmonary diseases belong to the first group. In a small percentage of patients, the trachea and bronchi may be the main or even the sole site of *Aspergillus* infection. This condition is referred to as lower airway aspergillosis, tracheobronchial aspergillosis, or *Aspergillus* tracheobronchitis.

2. TRACHOBRONCHIAL ASPERGILLOSIS

In 1991, Kramer and coworkers proposed a classification of tracheobronchial aspergillosis. Similarly to upper airway and pulmonary aspergillosis, the authors distinguished saprophytic, allergic, and invasive

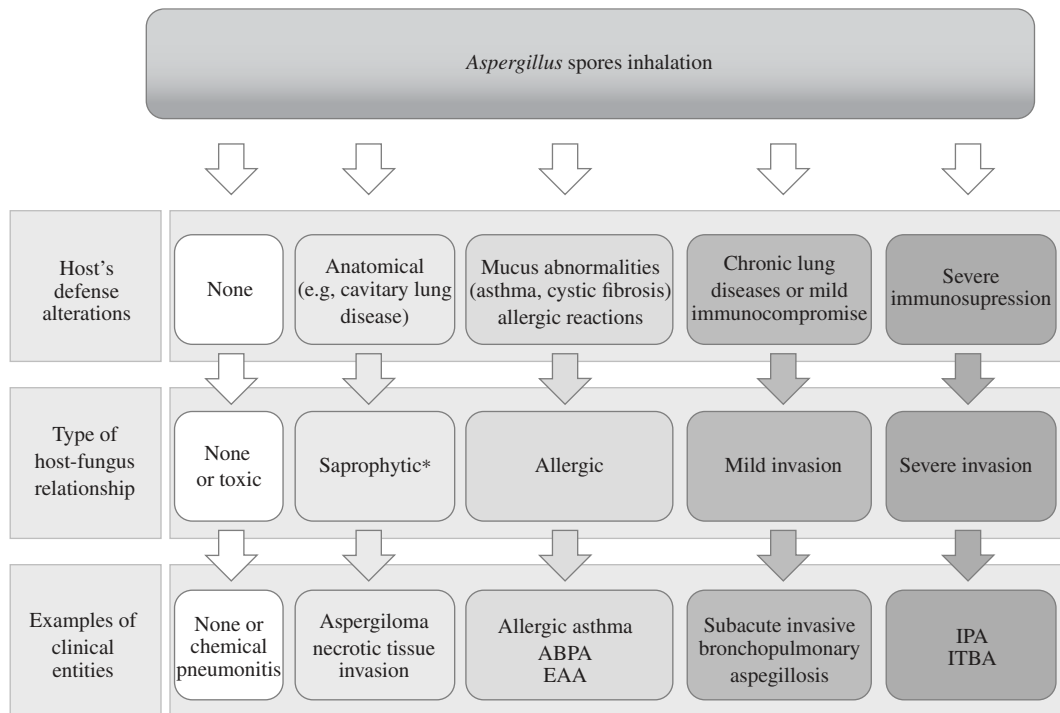


FIGURE 1: Classification of the *Aspergillus*-related respiratory diseases based on their pathogenesis, including the status of antifungal defense and the type of host-fungus relationship (upper and middle row, respectively) (based on [13], modified). * In many patients, a true saprophytic nature of the infection is difficult to prove and might be questionable. Note, that in fact, not only vertical (showed with arrows), but also horizontal relationships might exist in the middle and bottom rows (e.g., saprophytic forms can evolve into invasive forms; relationships not shown); EEA: extrinsic allergic alveolitis, ABPA: allergic bronchopulmonary aspergillosis, IPA: invasive pulmonary aspergillosis, ITBA: invasive tracheobronchial aspergillosis.

TABLE 1: Anatomical classification of *Aspergillus*-related respiratory disease.

<i>Aspergillus</i> -related respiratory diseases
<i>Aspergillus</i> -related upper airway diseases
Tracheobronchial <i>Aspergillus</i> diseases
<i>Aspergillus</i> -related diseases of lung parenchyma

forms of *Aspergillus* tracheobronchial involvement. Based on clinical, bronchoscopic, and pathological presentations, they were further subdivided into different clinical entities (Table 2) [14–16].

Recently, Patel et al. reported three patients with different forms of tracheobronchial aspergillosis and presented their own, simplified, classification of *Aspergillus*-related tracheobronchial diseases [17]. Although this classification includes most of the known tracheobronchial manifestations of aspergillosis, it also raises some doubts; for example, pulmonary aspergilloma was classified as tracheobronchial disease, while endobronchial localization of *Aspergillus* fungal ball has not been mentioned [17, 18].

We realize that in view of the variety of different forms of *Aspergillus* tracheobronchial involvement it is difficult to propose a uniform and unequivocal classification involving all entities. A review of 121 cases of *Aspergillus*-related endobronchial diseases reported in the literature, listing 13 different

TABLE 2: Classification of *Aspergillus*-related tracheobronchial diseases (based on [14–16]).

Host-fungus relationship (type of tracheobronchial involvement)	Clinical characteristics of tracheobronchial involvement
Saprophytic	Mucoid impaction
	Obstructing bronchial aspergillosis
Allergic	Allergic bronchopulmonary aspergillosis (ABPA)
	Bronchocentric granulomatosis
Invasive tracheobronchial aspergillosis (ITBA)	<i>Aspergillus</i> tracheobronchitis
	Ulcerative <i>Aspergillus</i> tracheobronchitis
	Pseudomembranous <i>Aspergillus</i> tracheobronchitis

bronchoscopic/pathologic descriptions and 17 different diagnoses, clearly demonstrates these difficulties [12]. Nevertheless, we believe that the classification presented by Kramer et al. is still valuable and convincing. Therefore, it will be further used in this paper. However, since, from the original publication in 1991, a large body of papers has been published on different forms of tracheobronchial aspergillosis, new data exceeding the original classification will also be presented.

2.1. Allergic Forms of Tracheobronchial Aspergillosis

2.1.1. Asthma with Hypersensitivity to *Aspergillus* Antigen and Allergic Bronchopulmonary Aspergillosis (ABPA)

Asthma with hypersensitivity to *Aspergillus* antigens as well as allergic bronchopulmonary aspergillosis (ABPA) is well-defined entities which can be considered as tracheobronchial manifestations of *Aspergillus* infections. As both diseases have been extensively discussed in several articles published in the recent years [1, 6, 19, 20], they will only be mentioned in this paper.

Clinical symptoms of asthma developing in patients with type I hypersensitivity to *Aspergillus* antigens are not different from those found in patients allergic to other molds including *Alternaria* and *Penicillium* [6]. Treatment is similar to that recommended for other patients with allergic asthma and includes inhaled steroids and bronchodilators [1, 6].

ABPA usually develops in atopic individuals with extrinsic asthma or patients with cystic fibrosis and affects both, the bronchial compartment and adjacent lung tissue. Its pathogenesis involves Th2-dependent, eosinophilic response to *Aspergillus* antigens [19]. Chronic inflammation of the airway walls typically results in development of bronchiectasis and recurrent mucous plugging. Five stages of the disease have been recognized with pulmonary fibrosis being its final consequence [1, 20]. Suppression of the immunological response to *Aspergillus* antigens with systemic corticosteroids is a mainstay of ABPA therapy. It aims at relieving acute symptoms and preventing progressive pulmonary fibrosis [1, 19, 20]. Treatment with new azoles may have some beneficial effect enabling the reduction of corticosteroid doses [1, 19, 21]. Not all authors, however, confirmed the efficacy of antifungal agents [20].

2.1.2. Bronchocentric Granulomatosis

Bronchocentric granulomatosis is an effect of abnormal cell-mediated response to *Aspergillus* spp. This inflammatory reaction involves the bronchi and bronchioles and is characterized by the formation of necrotizing granulomas containing numerous inflammatory cells (mainly eosinophils) [1, 6, 13, 22]. This is often associated with impaction of the airway lumen by a granular basophilic mucin and cellular debris [22]. The *Aspergillus* hyphae were identified within the granulomas in 40–50% of cases, but typically there

is no tissue or vascular invasion [13]. Two subtypes of bronchocentric granulomatosis are distinguished by some authors [6, 14]. The first is closely related to atopy and asthma. The second subtype may be related to a variety of other diseases, such as rheumatoid arthritis, bronchogenic carcinoma, postradiation pulmonary fibrosis, and Wegener's granulomatosis [17]. In some cases, bronchocentric granulomatosis may overlap invasive forms of *Aspergillus*-related pulmonary diseases, namely, semiacute invasive pulmonary aspergillosis (also termed chronic necrotizing aspergillosis) [1]. Corticosteroids are the mainstay of treatment, but they are effective mainly in patients with atopy and asthma.

2.2. Saprophytic Forms of Tracheobronchial Aspergillosis

2.2.1. Muroid Impaction

Muroid impaction is defined as intrabronchial retention of the inspissated muroid secretions. Although it has been found to be a nonspecific finding, inflammatory and allergic reactions to *Aspergillus* antigens are probably the most common causes of this condition [23, 24]. Intrabronchial obstruction is often associated with an inflammatory reaction in the airway wall. If the affected airway is large or dilated, the secretion may be depicted on a chest radiograph or CT scan as tubular or branching opacities known as the *finger-in-glove* sign [24].

Although muroid impaction associated with hypersensitivity to *Aspergillus* antigens is usually reported in patients with ABPA, it probably can also affect patients with asthma and hypersensitisation to *Aspergillus* but without ABPA. [25, 26]. Other causes of muroid impaction have been widely discussed elsewhere [24]. Treatment of muroid impaction associated with inflammatory response to *Aspergillus* is not different from that used in patients with ABPA.

2.2.2. Obstructing Bronchial Aspergillosis

Obstructing bronchial aspergillosis was first described by Denning et al. in three patients with AIDS [27]. This was defined as the presence of thick mucous plugs containing *Aspergillus* hyphae, with little or no airway inflammation and no evidence of invasion or allergic reaction [15, 27]. The disease is characterized by a subacute onset of symptoms, which include cough, hemoptysis, dyspnea, chest pain, and expectoration of fungal casts [14, 27, 28]. Obstructing bronchial aspergillosis was also reported in a heart transplant recipient whose chest radiograph performed on the third postoperative day revealed middle lobe atelectasis. [29]. Multiple, endobronchial casts, containing *Aspergillus* hyphae were removed during bronchoscopy. Although obstructing bronchial aspergillosis is regarded as a saprophytic form of tracheobronchial aspergillosis, in immunocompromised patients, it can probably progress to invasive tracheobronchitis [27–29].

It should be stressed that saprophytic, obstructing bronchial aspergillosis is an entity distinct from invasive pseudomembranous *Aspergillus* tracheobronchitis which can also be associated with bronchial obstruction by necrotic pseudomembranes (pseudomembranous, obstructive *Aspergillus* tracheobronchitis).

2.2.3. Other Saprophytic Forms of *Aspergillus* Tracheobronchial Involvement

Another saprophytic *Aspergillus* tracheobronchial infection which had not been included in classification presented by Kramer et al. is saprophytic *Aspergillus* infection involving bronchial anastomoses. This entity has been described in lung transplant recipients. Devascularization of the bronchial anastomosis in the early posttransplantation period may result in sloughing of epithelial tissue into the airway lumen [30]. This necrotic debris may serve as nourishment for fungal hyphae germinating from airborne spores. The intensive immunosuppression in the early posttransplantation period is an important factor promoting fungal growth. Nunley et al. defined saprophytic fungal infection as positive culture of bronchial washing and presence of fungal organisms in biopsy samples from bronchial anastomosis [30]. In their series, the

incidence of saprophytic fungal infection of bronchial anastomosis was as high as 24.6%, with *Aspergillus* spp. being responsible for two thirds of the cases. The median time from transplantation to diagnosis of saprophytic fungal infection was 35 (range 13–159) days [30]. All patients with anastomotic fungal infection were intensively treated with intravenous and nebulized amphotericin B and oral itraconazole. This intensive treatment and, particularly, the complications which developed in some patients including bronchomalacia, bronchial stenosis and hemorrhage raise some doubt about the truly saprophytic nature of these infections. We suppose, that in some patients fungal infection of bronchial anastomosis which is initially limited to necrotic tissue and defined as saprophytic may easily progress to locally invasive fungal infection. If so, the borderline between saprophytic fungal infection of bronchial anastomosis and local, invasive *Aspergillus* tracheobronchitis in lung or heart and lung transplant recipients might be quite elusive (see further: *Aspergillus tracheobronchitis in patients after lung transplantation*).

Aspergillus growth on silk sutures closing a bronchial stump is another example of saprophytic fungal-host relationship. This infection usually develops 6–12 months after lung resection and can spread to mucous plug or debris as well as granulation tissue located in the stump. The removal of the thread solves the problem, and usually no antifungal therapy is necessary [31]. A much longer latency period between lung resection and development of bronchial stump aspergillosis, ranging between 4 and 7 years, was also reported [32, 33]. Noppen et al. found that, albeit bronchoscopic removal of the silk thread seems to be the first choice therapy, treatment with oral itraconazole can also result in resolution of infection [32]. Le Rochais et al. demonstrated that bronchial stump aspergillosis is not specific for silk thread but can also affect patients in whom nylon threads were used [34].

Since invasion of bronchial mucosa was reported in patients with bronchial stump aspergillosis [32], this is yet another example that the line between saprophytic and invasive *Aspergillus* infection may not be well defined, and borderline cases can be expected in clinical practice.

Aspergillus can overgrow necrotic debris and mucous plug on the surface of endobronchial tumors. We observed a thick layer of *Aspergillus* hyphae covering an endobronchial carcinoid tumor (data not published). Initially, this caused a diagnostic challenge. A similar situation was reported by others [35].

2.3. Invasive Tracheobronchial Aspergillosis (ITBA)

While invasive pulmonary aspergillosis centered on the airways accounts for 14–34% of invasive pulmonary aspergillosis (IPA), invasive tracheobronchial aspergillosis (ITBA) is a relatively rare manifestation of *Aspergillus*-related lung disease [36]. ITBA has been described as an isolated or dominating local manifestation only in a small number of patients (6.9% of patients with intrathoracic aspergillosis in three case series analyzed by Kemper et al.) [37]. In the majority of cases, ITBA is probably associated with IPA, which is the most common form of *Aspergillus* invasion. [38, 39]. Both, IPA and ITBA, predominantly affect severely immunocompromised patients [39]. ITBA has also been reported in patients with various chronic diseases without severe immune suppression (e.g., diabetes) and even in immunocompetent subjects [40–42].

Since the most reliable criterion of invasive fungal airway disease is demonstration of tissue invasion and damage caused by hyphae [15, 43, 44], bronchoscopy with biopsy, microscopy, and culture is the only way to confirm invasive *Aspergillus* tracheobronchial infection in the clinical setting [16].

Basing on the bronchoscopic or pathologic appearance, three different invasive forms of tracheobronchial aspergillosis were described: *Aspergillus* tracheobronchitis, ulcerative *Aspergillus* tracheobronchitis, and pseudomembranous *Aspergillus* tracheobronchitis [14]. Denning and coworkers proposed to apply the term “*Aspergillus* tracheobronchitis” to tracheobronchial disease caused by *Aspergillus* spp. which is characterized by the evidence of bronchial and/or tracheal inflammation and excessive mucus production without invasion of the bronchial mucosa on biopsy [15]. The features of the ulcerative forms include the presence of variable, ulcerative, or plaque-like lesions in the bronchial walls. This form has been most commonly recognized in patients with AIDS and heart-lung or lung transplant recipients [15]. Pseudomembranous form of ITBA is characterized by extensive involvement of the lower airways, with

sloughing of necrotic epithelium which, together with endobronchial mucus, form the pseudomembranes overlying the mucosal surface. This form has usually been found in severely immunocompromised hosts with hematologic malignancies [14, 15, 37, 45]. It is important, however, to be aware that the morphological appearance of airway aspergillosis may easily change and that different forms of *Aspergillus*-related invasive airway involvement may coexist. Kramer et al. hypothesized that these three forms represent a progressive evolution of the disease ranging from mild bronchitis to widespread pseudomembranous diffuse disease [14]. Many publications seem to confirm this point of view. Thus, it should be stressed that although this classification will be further used to present different aspects of ITBA, it has rather an educational than true clinical value.

A novel classification of isolated ITBA has recently been proposed by Wu et al. According to bronchoscopic findings, the authors recognized four types of invasive airway aspergillosis: type I: superficial infiltration, type II: full-layer involvement, type III: occlusive, and type IV: mixed [46]. Although at first glance this classification significantly differs from that presented by Kramer et al., both classifications have much in common. They both classify several disease stages from relatively mild to severe and more complex forms. As reliability of visual bronchoscopic assessment of the depth of bronchial wall involvement may be questionable, descriptive terms used by Kramer et al. seem more justified [14, 46].

Keeping in mind three different forms of invasive or potentially invasive *Aspergillus* airway disease, an approach basing on specific conditions predisposing to tracheobronchial infections rather than on the macroscopic and/or pathologic appearance might be of more use for a clinician. This is justified not only by the fact that specific groups of high-risk patients are usually treated by different specialists, but also by the fact that the same form of *Aspergillus* airway involvement may have a different clinical course and prognosis, highly dependent on a variety of host factors. Therefore, invasive or potentially invasive *Aspergillus* airway diseases will be further presented in three main groups of patients: (1) lung transplant recipients, (2) highly immunocompromised patients with hematologic malignancies and/or patients undergoing hematopoietic stem cell transplantation, and (3) the remaining, less severely immunocompromised patients, or even immunocompetent subjects.

2.3.1. *Aspergillus* Tracheobronchitis in Patients after Lung Transplantation

Lung transplant recipients are a unique subset of patients which are particularly susceptible to *Aspergillus* bronchial invasion. This is a consequence of continuous exposure of the transplanted organ to environmental pathogens and, simultaneously, the use of aggressive immunosuppressive therapy [47, 48]. In a group of 121 patients with endobronchial aspergillosis identified by the literature review, 80 (66%) were lung transplant recipients [12].

In 2000, Nathan et al. reported a relatively high incidence of *Aspergillus*-related endobronchial abnormalities in lung transplant recipients. These authors found endobronchial involvement in 7 out of 38 patients (18.4%), and, at least in 4 of these patients, bronchial wall invasion was demonstrated [49]. One year later, Mehrad et al. presented the retrospective analysis of the large series of 133 patients and reviewed the literature on *Aspergillus* infections in lung transplant recipients. The incidence of isolated *Aspergillus* tracheobronchitis was 5% in the authors' series and 4% in pooled published data [47]. The incidence of *Aspergillus* tracheobronchitis was only slightly lower than the incidence of IPA (5% versus 8% and 4% versus 5% in Mehrad et al. and pooled published data, resp.). Virtually the same results were presented in a Spanish study (6% and 8% of *Aspergillus* tracheobronchitis and IPA, resp.) [48]. Interestingly, the review of 40 papers, which reported 159 lung transplant recipients who developed *Aspergillus* infections, showed that tracheobronchitis was the most common form of *Aspergillus* infection responsible for 37% of cases. IPA, *Aspergillus* infections of bronchial anastomosis and disseminated aspergillosis, accounted for 32%, 20%, and 10% of cases, respectively [50].

It seems that, in certain patients, the risk of postoperative ITBA development depends on preoperative airway colonization by *Aspergillus*. This was shown by Helmi et al. in patients with cystic fibrosis (CF). ITBA developed only in patients with persistent preoperative airway colonization with *A. fumigatus*

while none of the patients who had not been colonized prior to surgery developed any form of invasive aspergillosis [51]. The authors noted that antifungal prophylaxis did not prevent the development of ITBA, and amphotericin B therapy (with or without endobronchial debridement of necrotic tissue) was required to clear the infection in all patients [51]. A recent study revealed that despite voriconazole prophylaxis, the risk of posttransplant fungal infection in recipients with features of the mold infection in the explanted lung was significantly higher than in patients without mold infection, 43 and 14%, respectively [52]. Results of other studies do not, however, confirm the relationship between pre-transplant *Aspergillus* airway colonization and the risk of posttransplant colonization and/or *Aspergillus* infection [53, 54].

The incidence of isolated *Aspergillus* tracheobronchitis is highest in the first year after transplantation, with virtually all cases diagnosed within the first three-to-six months after transplantation [47, 48, 51]. According to the review by Singh and Husain, the median time from transplantation to diagnosis of *Aspergillus* tracheobronchitis and/or bronchial anastomotic infection was 2.7 months [50].

All patients with *Aspergillus* tracheobronchitis seen by Mehrad et al. were asymptomatic, while in other series, the clinical presentation, as well as endoscopic appearance of the isolated tracheobronchitis was variable. One of the reviews showed that none of 13 patients who developed *Aspergillus* tracheobronchitis and/or bronchial anastomotic infection had fever [50]. Monitoring of the serum *Aspergillus* galactomannan (GM) level plays no role in the diagnosis of IPA and ITBA in lung transplant recipients. One study showed positive results of the test in only 28.5% of patients with IPA and in none of four patients with ITBA (sensitivity 0%) [55]. Another paper from the same group of authors demonstrated that albeit overall diagnostic sensitivity of GM measurement in BALF was higher (60%), the level of GM in the sole patient with ITBA was below the cut-off value [56], hence, the important role of surveillance bronchoscopy in early diagnosis of isolated *Aspergillus* tracheobronchitis [47].

The vast majority of *Aspergillus*-related tracheobronchial lesions in patients who underwent lung transplantation occurred in the transplanted lung and involved the anastomosis line [47–50]. *Aspergillus fumigatus* was responsible for almost 90% of all tracheobronchial infections [50]. The bronchoscopic appearance of the airway lesions included pseudomembrane formation, bronchial stenosis in the anastomosis line, ulcerations, and black eschar [47–49]. Severe complications may develop including a nontraumatic disruption of the anterolateral, fibrocartilaginous tracheal wall, as reported by Aerni et al. [57]. The probable pathophysiologic basis for this complication was fungal invasion of the blood vessels resulting in a critical compromise of local blood supply [57].

Prognosis for lung transplant patients with *Aspergillus* tracheobronchitis is favorable as compared to IPA and disseminated infections. Mortality rate calculated from 40 studies was 23.7% in patients with *Aspergillus* tracheobronchitis and/or anastomotic infection versus 81.8% and 50% in patients with IPA and disseminated infections, respectively [50]. In the series presented by Sole et al., *Aspergillus* tracheobronchitis resulted in a 14% mortality rate as compared to 78% in IPA [48]. All six patients treated by Mehrad et al. survived, and pooled data from all series analyzed by these authors showed the mortality rate 18% [47].

The most common therapeutic option for lung transplant recipients with *Aspergillus* tracheobronchitis was oral itraconazole or intravenous amphotericin B. Some centers used aerosolized amphotericin B as adjunctive treatment. A substantial number of patients required additional local treatment including bronchoscopic debridement, balloon dilatation, laser treatment, and/or stent placement [47–49]. It should be noted, that none of the patients progressed to invasive pneumonia [47].

Prophylactic administration of the antifungal agents has been shown to decrease the incidence of invasive fungal infection after lung transplantation. However, there is no uniformly accepted strategy, and different drugs are used in lung transplant centers throughout the world [58, 59]. They include nebulized amphotericin B, oral voriconazole, or itraconazole, alone or in combinations [59, 60]. Since the use of aerosolized medications may significantly reduce their toxic systemic effects and potential drug interactions, they are an attractive option [61]. This especially regards liposomal and lipid complex forms of amphotericin B which can be administered three times a week or even once a week, respectively [62, 63].

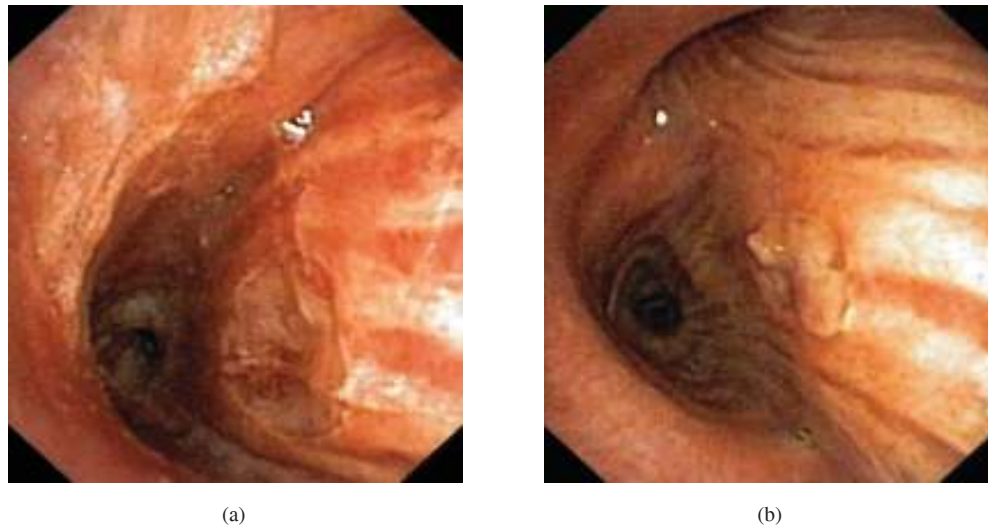


FIGURE 2: A large *Aspergillus* ulcer in the posterior wall of the left main stem bronchus (a). Similar ulceration in the posterior wall of the right main stem bronchus covered by fibrin and tissue debris (b).

2.3.2. *Aspergillus* Tracheobronchitis in Immunocompromised Patients with Hematological Malignancies

Although *Aspergillus* airway infection may complicate the course of different malignant diseases, the highest risk affects severely immunocompromised patients with hematological malignancies. In one of the early reports, 6 out of 9 patients with fungal tracheobronchitis had underlying malignant diseases and in 3 of them different leukemias were diagnosed [64]. In the later review reporting 20 cases of pseudomembranous ITBA, an underlying malignant disease of the hematopoietic system was found in 13 (65%) patients [45]. The proportion of lung versus airway involvement in patients with hematological malignancies is significantly different than that in previously discussed patients undergoing lung transplantation; IPA is responsible for 80–90% of *Aspergillus* infections, while tracheobronchial aspergillosis is much less common. It is estimated that approximately 10% of patients with invasive aspergillosis may present relevant signs of tracheobronchial invasion, either alone or with pulmonary parenchyma involvement [6].

All the three forms of ITBA listed in the classification by Kramer et al. (Table 2) can probably develop in patients with hematological malignancies. However, a significant predominance of the ulcerative and pseudomembranous forms was found in reports published up to date. If the supposition that the three forms of *Aspergillus* tracheobronchitis represent a progressive spectrum of fungal invasion is true, the predominance of more invasive forms in patients with severe immunosuppression can be easily understood. This is also consistent with observations that the course of *Aspergillus* airway infection in these patients is severe, and the prognosis is significantly worse than in patients after lung transplantation.

Some less common forms of invasive airway aspergillosis have also been reported in patients with hematological malignancies. In a severely immunocompromised patient with the graft versus host disease (GvHD) which developed after allogeneic bone marrow transplantation due to low-grade non-Hodgkin lymphoma, Irani et al. found multiple white papular lesions of the tracheal mucosa and plaque-like vascularized changes. Pathological examination of the biopsy specimen confirmed invasion with numerous fungal hyphae consistent with ITBA [39]. Multiple, small, 3 to 5 mm in diameter nodules in both main stem and lobar bronchi were the dominating picture in a patient with ITBA and acute lymphoblastic leukemia (ALL) treated by Sancho et al. [65]. It should also be realized that in many patients with ITBA the endobronchial appearance might not be uniform and include different lesions, even in the context of the same form of *Aspergillus* tracheobronchitis. For example, ulcerative lesions may be less obvious when covered by fibrin, as compared to uncovered ulcers (Figure 2(a) and 2(b)).

Moreover, features of different forms of *Aspergillus* tracheobronchitis can be found in the same patient. We observed large ulcerative lesions, being the most relevant feature of fungal invasion in both main stem bronchi, coexisting with extensive pseudomembranous bronchitis seen in the peripheral bronchi [66]. The coexistence of different forms of *Aspergillus* tracheobronchitis has also been demonstrated by other authors. Arriero et al. found simultaneous obstructive and pseudomembranous necrotizing tracheobronchitis due to *Aspergillus flavus* in a diabetic patient with ALL [67]. Buchheidt et al. reported a patient with Hodgkin lymphoma and pseudomembranous form of tracheobronchial aspergillosis in whom patchy ulcerations were also found in the trachea and bronchi [68]. Van Assen et al. described “yellowish plaques, ulcerations and pseudomembranes” seen during bronchoscopy in a patient who underwent hematopoietic stem cell transplantation (HSCT) due to acute myeloid leukemia (AML) and who subsequently developed *Aspergillus* tracheobronchitis [69]. It is of note that many of the invasive *Aspergillus* tracheobronchial infections affected patients treated with HSCT who subsequently developed GvHD requiring further, intensive immunosuppressive therapy [39, 69–71].

Unlike *Aspergillus* tracheobronchitis in lung transplant recipients, ITBA in patients with hematological malignancies is usually symptomatic. Dyspnea, inspiratory wheezes, fever, and nonproductive cough belong to the most commonly reported symptoms [66, 68–70]. Airway obstruction may result in atelectasis and severe respiratory failure [72]. It should be emphasized that, in patients with isolated tracheobronchitis, the chest radiograph and CT scan may not reveal pulmonary lesions [36, 67, 69, 70]. Different features and extent of pulmonary involvement, from small parenchymal or peribronchial infiltrations to larger areas of consolidation and nodules, can be seen in patients with simultaneous lung involvement [38, 39, 65, 66]. In some patients, CT scanning, positron emission tomography-CT scanning, and endobronchial ultrasonography (EBUS) can demonstrate bronchial wall involvement with bronchial lumen narrowing [38, 71]. Bronchoscopy plays a crucial role in endobronchial disease assessment and specimen collection for microbiological and pathological evaluations. However, due to *Aspergillus* capability to invade blood vessels, bronchial biopsies may carry the additional risk of bleeding, particularly that many patients have a low platelet count [73]. Fatal hemorrhage was reported when attempts have been undertaken to remove obstructing pseudomembranes [74]. Recently, Casal et al. have shown that EBUS-guided transbronchial needle aspiration biopsy (EBUS-TBNA) can help to obtain adequate tissue specimens in patients in whom the results of endobronchial specimen evaluation were inconclusive [71].

The value of other methods in diagnosing ITBA, including the serum level of circulating GM, is uncertain. The serum concentration of GM was elevated in the patient described by Machida et al. [70] but remained low in a series of 6 serum samples in a patient treated by Van Assen et al. [69]. In the small series of patients with pseudomembranous *Aspergillus* tracheobronchitis reported by Tasci et al., one patient had elevated level of serum *Aspergillus* antigen, while borderline and negative results were found in two other patients, respectively [45]. Low serum *Aspergillus* antigen level in a heart transplant recipient with pseudomembranous *Aspergillus* tracheobronchitis has been recently reported by Ramos et al. [75]. To explain these differences, Van Assen et al. presented two hypotheses. The first assumes that in some patients the fungal invasion is limited to the superficial layer of the airway mucosa and, thus, is not sufficient to cause the spread of *Aspergillus* antigens into the circulating blood. The alternative explanation points out a false negative ELISA reactivity as a cause of low serum GM level [69].

There are some data that BALF, or maybe even bronchial washing, might be a more accurate diagnostic material in patients with ITBA as compared to peripheral blood. In one of our patients, we found a negative result of serum *Aspergillus* GM measurement while the bronchoalveolar lavage fluid (BALF) examination gave a positive result. Also De Rosa et al. showed that BALF GM concentrations in a diabetic patient with pseudomembranous *Aspergillus* tracheobronchitis significantly exceeded GM concentrations in serum [76].

In earlier reports, amphotericin B was invariably used to treat patients with invasive *Aspergillus* tracheobronchitis (Table 3). In the recent years, combined treatment including amphotericin B plus caspofungin or amphotericin B plus voriconazole as well as monotherapy with voriconazole has been the predominant therapeutic options. This is consistent with the latest Infectious Diseases Society of America

TABLE 3: Characteristics of 19 patients with ITBA and hematological malignancies reported between 1996 and 2010.

Author, publication's year [ref]	Patient's sex and age (years)	Underlying conditions	WBC ($\times 10^9/L$)	PMN ($\times 10^9/L$)	Classification	Species	Treatment	Outcome	Cause of death
Kuo et al. 1996 [91]	M, 44	Peripheral T-cell lymphoma, CHTH	0.7	0.3	Ulcerative and plaque-like tracheobronchitis	<i>Aspergillus fumigatus</i>	Amphotericin B followed by itraconazole	Survived	
Sancho et al. 1997 [65]	M, 43	Acute lymphoblastic leukemia, CHTH	3.2	1.6	Multiple white nodules, inflammatory bronchial stenosis	<i>Aspergillus</i> sp.	Amphotericin B	Died	Disseminated aspergillosis, massive hemoptysis
Arriero et al. 1998 [67]	F, 64	Acute lymphoblastic leukemia, CHTH, diabetes	7.0	4.7	Pseudomembranous and obstructing tracheobronchitis	<i>Aspergillus flavus</i>	Amphotericin B	Died	Respiratory failure
Machida et al. 1999 [70]	F, 44	Chronic myelogenous leukemia	NA	5.0	Necrotic pseudomembranes	NA	Amphotericin B	Died	Respiratory failure
Ahn et al. 2000 [38]	M, 56	Acute myeloid leukemia, CHTH	0.3	NA	Pseudomembranous tracheobronchitis	<i>Aspergillus</i> sp.	Amphotericin B	Died	Massive hemoptysis
Tasci et al. 2000 [92]	F, 54	Plasma cell myeloma, CHTH, autologous HSCT	NA	0.1	Multiple white plaques, pseudomembranes, mucous plugs	<i>Aspergillus fumigatus</i>	Amphotericin B	Died	Sepsis, respiratory failure
Van Assen et al. 2000 [69]	F, 56	Acute myeloid leukemia, CHTH, allogeneic HSCT, GvHD, immunosuppressive therapy	NA	NA	Plaques, ulcerations, pseudomembranes	<i>Aspergillus fumigatus</i>	Amphotericin B i.v. plus nebulization \rightarrow liposomal amphotericin B plus itraconazole	Died	Respiratory failure
Koh et al. 2000 [93]	M, 20	Leukemia, HSCT, GvHD, immunosuppressive therapy	NA	NA	Pseudomembranous tracheobronchitis	<i>Aspergillus fumigatus</i>	NA	Died	Respiratory failure
Routsi et al. 2001 [94]	M, 60	Erythroleukemia, CHTH	Pancytopenia	NA	Bronchial obstruction by mass containing <i>Aspergillus</i> hyphae	<i>Aspergillus fumigatus</i>	Amphotericin B	Died	Septic shock

TABLE 3: Continued.

Author, publication's year [ref]	Patient's sex and age (years)	Underlying conditions	WBC ($\times 10^9/L$)	PMN ($\times 10^9/L$)	Classification	Species	Treatment	Outcome	Cause of death
Buchheidt et al. 2003 [68]	F, 55	Hodgkin lymphoma, CHTH	3.0	2.6	Ulcerations, plaque-like lesions and pseudomembranes	<i>Aspergillus fumigatus</i>	Amphotericin B, \rightarrow liposomal Amphotericin B	Survived	
Irani et al. 2003 [39]	M, 40	Low-grade non-Hodgkin lymphoma, allogeneic HSCT, severe GvHD, immunosuppressive therapy	NA	NA	Multiple papular and plaque-like, vascularized mucosal lesions	<i>Aspergillus fumigatus</i>	NA	NA	
Routsi et al. 2004 [72]	F, 22	Lymphom, CHTH	0.21	NA	Pseudomembranes, bronchial obstruction	<i>Aspergillus terreus</i>	Liposomal amphotericin B plus voriconazole	Died	Respiratory failure
Tasci et al. 2006 [45]	M, 58	Plasma cell myeloma, CHTH	NA	0.4	Multiple circumscribed lesions, pseudomembranes	<i>Aspergillus fumigatus</i>	Liposomal amphotericin B	Died	Septic shock
	F, 64	Burkitts' lymphoma, CHTH	Pancytopenia		Pseudomembranes	<i>Aspergillus fumigatus</i>	Amphotericin B	Died	Respiratory failure
	M, 34	Burkitts' lymphoma, CHTH	NA	NA	Pseudomembranes	<i>Aspergillus fumigatus</i>	Amphotericin B plus caspofungin	Died	Initial improvement in ITBA but lymphoma progression, fatal intracranial bleeding

TABLE 3: Continued.

Author, publication's year [ref]	Patient's sex and age (years)	Underlying conditions	WBC ($\times 10^9/L$)	PMN ($\times 10^9/L$)	Classification	Species	Treatment	Outcome	Cause of death
Onozawa et al. 2009 [95]	M, 49	Angioimmunoblastic T-cell lymphoma	NA	NA	Pseudomembranous cream-coloured plaques	<i>Aspergillus fumigatus</i>	Inhaled amphotericin B plus oral voriconazole	Survived	
Casal et al. 2009 [71]	M, 65	Chronic lymphocytic leukemia, allogeneic HSCT,	NA	4.0	Bronchial narrowing with necrotic and friable mucosa	NA	Liposomal amphotericin B plus posaconazole	Survived	
Krenke et al. 2009 [66]	M, 63	Acute myeloid leukemia, CHTH	0.5	<0.1	Ulcerative lesions and pseudomembranes	<i>Aspergillus</i> sp.	Voriconazole	Died	Respiratory failure, pulmonary embolism
Patel et al. 2010 [17]	M, 73	Non-Hodgkin lymphoma, CHTH	15.9	NA	Plaques forming pseudomembranes, ulcerations	<i>Aspergillus fumigatus</i>	Voriconazole	Died	Respiratory failure

CHTH: antineoplastic chemotherapy, HSCT: hematopoietic stem cell transplantation, GvHD: graft versus host disease, → change of the treatment regimen.

guidelines which recommend voriconazole for primary treatment of invasive *Aspergillus* tracheobronchitis [77]. Alternative treatments include liposomal or lipid complex form of amphotericin B, caspofungin, micafungin, posaconazole, and itraconazole [77]. Due to poor penetration of antifungal agents into the fungal masses, bronchoscopic removal of pseudomembranes and mycelial masses seems a reasonable component of treatment, but this might be associated with significant risk of severe bleeding [74].

The prognosis in severely immunocompromised patients with hematological malignancies and ITBA is significantly worse than in lung transplant recipients. None of the three patients with hematological malignancies reported by Tasci et al. survived [45]. Searching through the papers published in the last 15 years, we found 17 reports presenting the outcome in 19 patients with ITBA and hematological malignancies. The data from these papers are summarized in Table 3. The mortality rate related to *Aspergillus* infection was as high as 72.2% (only four patients survived). Buchheidt et al., who successfully treated one patient with Hodgkin disease and pseudomembranous *Aspergillus* tracheobronchitis, stress that the key factors which warrant a favorable outcome are an early diagnosis involving bronchoscopy with culture and pathology as well as an adequate antifungal therapy [68]. Although 12 out of 19 patients with isolated *Aspergillus* tracheobronchitis complicating various malignant and nonmalignant diseases reported by Wu et al. survived, the only patient with underlying hematological malignancy (non-Hodgkin lymphoma) died of cerebral dissemination of aspergillosis [46].

Thus, we believe that the prognosis in patients with ITBA depends more on the underlying condition than on the form of *Aspergillus* airway involvement which, to a large extent, is a consequence of the immune status of the infected host. This seems to be confirmed by the comparison of prognosis in lung transplant recipients and patients with hematological malignancies (see above). Assuming that the diagnosis of diverse forms of ITBA is based on the macroscopic appearance of endobronchial lesions, we cannot share the opinion of Tasci et al., that the term “ulcerative *Aspergillus* tracheobronchitis” should be reserved for patients with limited involvement of the tracheobronchial tree and that this entity is invariably associated with favorable prognosis [45]. In patients, reported by Van Assen et al. and by Krenke et al., ulcerative lesions were the important features of airway involvement and both patients died because of invasive fungal infection [66, 69]. Hence, there are probably at least two different subforms of ulcerative tracheobronchitis significantly differing in prognosis: one seen around the suture line in lung transplant recipients (reported to have a relatively favorable outcome) and the second which affects severely immunocompromised patients (e.g., HSCT recipients, patients with hematologic malignancies treated with highly cytotoxic regimens) and frequently coexists with the pseudomembranous form of tracheobronchitis. The prognosis in the second group of patients is poor and similar to that in pseudomembranous *Aspergillus* tracheobronchitis. Severe bleeding and respiratory failure are common complications responsible for a high mortality rate in these forms of airway invasive aspergillosis [38, 65, 69].

2.3.3. *Aspergillus* Tracheobronchitis in AIDS Patients

An overall incidence of *Aspergillus* infections in HIV-infected subjects ranges between 0 and 12% [16, 28, 78]. Invasive aspergillosis usually affects patients with advanced AIDS. Neutropenia, an impaired neutrophil and monocyte-derived macrophage function, and/or corticosteroid therapy are important factors contributing to disease development [16, 79, 80].

The majority of the reports on tracheobronchial aspergillosis in this patients group come from the 80s and the 90s of the XX century [27, 37, 79, 81]. In the review of 342 patients with AIDS and pulmonary aspergillosis, Mylonakis et al. identified 23 (7%) cases in which infection mainly involved large airways [82]. ITBA was diagnosed in 3 out of 93 AIDS patients (3.2%) with definite IPA [82]. Besides obstructing *Aspergillus* tracheobronchitis representing saprophytic *Aspergillus* airways involvement, different invasive forms of tracheobronchial aspergillosis have been reported. They include ulcerative or plaque-like and pseudomembranous (necrotizing) *Aspergillus* tracheobronchitis [37, 79]. Some of the reported cases are difficult to classify due to incomplete bronchoscopic and pathologic data [81].

Patients with AIDS and ITBA are usually symptomatic, with cough, dyspnea, and fever being the most commonly reported symptoms [37, 79, 81]. Physical examination may reveal wheezes. In a series of four patients reported by Kemper et al., chest radiograph was abnormal in two patients showing patchy multinodular or interstitial infiltrates [37]. Similarly, bilateral alveolar infiltrates were revealed in patient treated by Conte et al., while, in a patient reported by Pervez et al., the chest radiograph was normal [79, 81]. Contrary to variable and nonspecific results of radiographic examination, bronchoscopy with pathology and culture of bronchial specimens plays a key role in diagnosis [37, 83]. The endobronchial appearance of invasive aspergillosis may include erythematous or edematous mucosa, ulcers, white or grayish lesions forming plaques, or pseudomembranes or linings covering bronchial mucosa, causing even airway occlusion [37, 79, 81, 83].

Due to limiter number of reports, the assessment of the prognosis and optimal therapeutic strategy is not easy. Three of the four patients seen by Kemper et al. were treated with intravenous amphotericin B followed by oral itraconazole, and one patient received itraconazole followed by intravenous amphotericin B. One patient was lost to follow up and one patient died of disseminated aspergillosis shortly after the diagnosis. In two other patients, initial clinical response was noted but both patients died between 6 and 12 months after disease onset. The true role of the *Aspergillus* infection in the fatal outcome of these two patient is equivocal [37]. An initial response has also been noted in a patient treated with oral itraconazole, flucytosine, and nebulized amphotericin B [81].

2.3.4. *Aspergillus* Tracheobronchitis in Other Groups of Patients

Invasive tracheobronchial aspergillosis has also been reported in other groups of patients. Several cases of *Aspergillus* tracheobronchitis in immunocompetent and previously healthy subjects were reported [42, 46, 84–86]. However, in the majority of other publications, different underlying conditions in patients who developed ITBA were diagnosed. They include various malignant diseases, and for example, thymoma, breast, lung, esophageal and renal carcinomas and chronic diseases, for example, diabetes mellitus, chronic obstructive pulmonary disease, solid organ transplantation other than lung, and posttuberculous tracheal stenosis [40, 41, 46, 75, 76, 87–89].

In this heterogeneous group of patients, the spectrum of ITBA-related symptoms can be very wide and range from chronic dry cough and decreased appetite to high fever, severe respiratory distress, and rapid development of respiratory and multiorgan failure [85, 86, 90].

Bronchoscopic appearance did not significantly differ from that found in other patients groups although the extent of endobronchial changes might be limited [84, 88]. Pseudomembranous form of ITBA was reported in the majority of patients. [40, 41, 75, 84, 85, 87, 88]. Serum GM concentration was measured in a patient who had undergone heart transplantation complicated by pseudomembranous *Aspergillus* tracheobronchitis, but the level was low and, hence, not diagnostically useful [75]. On the other hand, strongly positive results of *Aspergillus* antigen testing in serum were observed in an immunocompetent patient in whom both tracheobronchial and pulmonary invasive *Aspergillus* diseases were diagnosed [90].

Intravenous itraconazole with or without nebulized amphotericin B and bronchoscopic debridement was most commonly applied initial therapy in patients treated by Wu et al. [46]. Alternatively, some patients received liposomal amphotericin B, nebulized amphotericin B, or voriconazole [46]. The mean treatment duration was 25 (range 8 to 47) days. In the several case reports, different treatment modalities were relatively equally distributed and included amphotericin B, voriconazole or itraconazole [40, 75, 85–88].

The prognosis seems to be largely dependent on the underlying disease. In the series presented by Wu et al., all five patients who had no or had nonmalignant underlying diseases survived. Conversely, 6/13 (46%) of patients with a malignant underlying disease died [46]. In four of them, the cause of death was directly related to *Aspergillus* infection. A relatively good prognosis in patients with ITBA and nonmalignant underlying disease was also found in other publications. Only one of the five reported patients died (mortality rate 20%) [40, 41, 75, 87]. Considering patients with *Aspergillus* tracheobronchitis and no underlying diseases, two of the three patients survived, but one, a 44-year-old man treated by Oh et al., died due to refractory septic shock and hypoxemia [84–86].

3. SUMMARY

Although tracheobronchial *Aspergillus* infections are relatively rare, they include a wide spectrum of different entities. Host-fungus relationship plays a key role in the development of these diseases. Thus, conditions affecting host organism and predisposing to tracheobronchial infections are critical in predicting the form, clinical course of the disease, and prognosis. The most serious, invasive tracheobronchial diseases affect patients with profound impairment of the antifungal defense, namely, patients with hematologic malignancies and/or patients undergoing hematopoietic stem cell transplantation. The prognosis in these subjects is generally poor, with mortality rate up to 70%. Key factors which may warrant a favorable outcome are an early diagnosis in adequate antifungal therapy. Bronchoscopy plays the most important role in endobronchial disease assessment and enables specimen collection for microbiological and pathological evaluation.

ACKNOWLEDGMENT

The authors thank Professor David W. Denning for his helpful comments and suggestions concerning the manuscript.

REFERENCES

- [1] A. Al-Alawi, C. F. Ryan, J. D. Flint, and N. L. Müller, "Aspergillus-related lung disease," *Canadian Respiratory Journal*, vol. 12, no. 7, pp. 377–387, 2005.
- [2] O. S. Zmeili and A. O. Soubani, "Pulmonary aspergillosis: a clinical update," *Quarterly Journal of Medicine*, vol. 100, no. 6, pp. 317–334, 2007.
- [3] E. Roilides, H. Katsifa, and T. J. Walsh, "Pulmonary host defences against *Aspergillus fumigatus*," *Research in Immunology*, vol. 149, no. 4-5, pp. 454–460, 1998.
- [4] M. Farouk Allam, A. Serrano del Castillo, C. Díaz-Molina, and R. Fernández-Crehuet Navajas, "Invasive pulmonary aspergillosis: identification of risk factors," *Scandinavian Journal of Infectious Diseases*, vol. 34, no. 11, pp. 819–822, 2002.
- [5] K. J. Hartemink, M. A. Paul, J. J. Spijkstra, A. R. J. Girbes, and K. H. Polderman, "Immunoparalysis as a cause for invasive aspergillosis?" *Intensive Care Medicine*, vol. 29, no. 11, pp. 2068–2071, 2003.
- [6] O. P. Sharma and R. Chwogule, "Many faces of pulmonary aspergillosis," *European Respiratory Journal*, vol. 12, no. 3, pp. 705–715, 1998.
- [7] F. Reichenberger, J. M. Habicht, A. Gratwohl, and M. Tamm, "Diagnosis and treatment of invasive pulmonary aspergillosis in neutropenic patients," *European Respiratory Journal*, vol. 19, no. 4, pp. 743–755, 2002.
- [8] D. M. Geiser, M. A. Klich, J. C. Frisvad, S. W. Peterson, J. Varga, and R. A. Samson, "The current status of species recognition and identification in *Aspergillus*," *Studies in Mycology*, vol. 59, pp. 1–10, 2007.
- [9] T. F. Patterson, W. R. Kirkpatrick, M. White et al., "Invasive aspergillosis. Disease spectrum, treatment practices, and outcomes. I3 *Aspergillus* Study Group," *Medicine*, vol. 79, no. 4, pp. 250–260, 2000.
- [10] K. A. Marr, R. A. Carter, F. Crippa, A. Wald, and L. Corey, "Epidemiology and outcome of mould infections in hematopoietic stem cell transplant recipients," *Clinical Infectious Diseases*, vol. 34, no. 7, pp. 909–917, 2002.
- [11] G. Maschmeyer, A. Haas, and O. A. Cornely, "Invasive aspergillosis: epidemiology, diagnosis and management in immunocompromised patients," *Drugs*, vol. 67, no. 11, pp. 1567–1601, 2007.
- [12] D. Karnak, R. K. Avery, T. R. Gildea, D. Sahoo, and A. C. Mehta, "Endobronchial fungal disease: an under-recognized entity," *Respiration*, vol. 74, no. 1, pp. 88–104, 2006.
- [13] A. O. Soubani and P. H. Chandrasekar, "The clinical spectrum of pulmonary aspergillosis," *Chest*, vol. 121, no. 6, pp. 1988–1999, 2002.
- [14] M. R. Kramer, D. W. Denning, S. E. Marshall et al., "Ulcerative tracheobronchitis after lung transplantation: a new form of invasive aspergillosis," *American Review of Respiratory Disease*, vol. 144, no. 3 I, pp. 552–556, 1991.
- [15] D. W. Denning, "Commentary: unusual manifestations of aspergillosis," *Thorax*, vol. 50, no. 7, pp. 812–813, 1995.

- [16] D. W. Denning, "Invasive aspergillosis," *Clinical Infectious Diseases*, vol. 26, no. 4, pp. 781–803, 1998.
- [17] N. Patel, A. Saleh, S. Raoof, M. Gudi, L. George, and U. B.S. Prakash, "Tracheobronchial manifestations of aspergillosis," *Journal of Bronchology*, vol. 17, no. 1, pp. 45–53, 2010.
- [18] J. S. Kim, Y. Rhee, S. M. Kang et al., "A case of endobronchial aspergilloma," *Yonsei Medical Journal*, vol. 41, no. 3, pp. 422–425, 2000.
- [19] K. Patterson and M. E. Streck, "Allergic bronchopulmonary aspergillosis," *Proceedings of the American Thoracic Society*, vol. 7, no. 3, pp. 237–244, 2010.
- [20] R. Agarwal, "Allergic bronchopulmonary aspergillosis," *Chest*, vol. 135, no. 3, pp. 805–826, 2009.
- [21] P. A. B. Wark, M. J. Hensley, N. Saltos et al., "Anti-inflammatory effect of itraconazole in stable allergic bronchopulmonary aspergillosis: a randomized controlled trial," *Journal of Allergy and Clinical Immunology*, vol. 111, no. 5, pp. 952–957, 2003.
- [22] R. L. Kradin and E. J. Mark, "The pathology of pulmonary disorders due to *Aspergillus* spp," *Archives of Pathology and Laboratory Medicine*, vol. 132, no. 4, pp. 606–614, 2008.
- [23] R. R. SHAW, "Mucoid impaction of the bronchi," *The Journal of Thoracic Surgery*, vol. 22, no. 2, pp. 149–163, 1951.
- [24] S. Martinez, L. E. Heyneman, H. P. McAdams, S. E. Rossi, C. S. Restrepo, and A. Eraso, "Mucoid impactions: finger-in-glove sign and other CT and radiographic features," *Radiographics*, vol. 28, no. 5, pp. 1369–1382, 2008.
- [25] V. Maurya, H. C. Gujnani, P. U. Sarma, T. Madan, and A. Shah, "Sensitization to *Aspergillus* antigens and occurrence of allergic bronchopulmonary aspergillosis in patients with asthma," *Chest*, vol. 127, no. 4, pp. 1252–1259, 2005.
- [26] A. Shah, "Aspergillus-associated hypersensitivity respiratory disorders," *The Indian Journal of Chest Diseases & Allied Sciences*, vol. 50, no. 1, pp. 117–128, 2008.
- [27] D. W. Denning, S. E. Follansbee, M. Scolaro, S. Norris, H. Edelstein, and D. A. Stevens, "Pulmonary aspergillosis in the acquired immunodeficiency syndrome," *The New England Journal of Medicine*, vol. 324, no. 10, pp. 654–662, 1991.
- [28] W. T. Miller Jr., G. J. Sais, I. Frank, W. B. Geftter, J. M. Aronchick, and W. T. Miller, "Pulmonary aspergillosis in patients with AIDS: clinical and radiographic correlations," *Chest*, vol. 105, no. 1, pp. 37–44, 1994.
- [29] M. Hummel, S. Schuler, S. Hempel, W. Rees, and R. Hetzer, "Obstructive bronchial aspergillosis after heart transplantation," *Mycoses*, vol. 36, no. 11-12, pp. 425–428, 1993.
- [30] D. R. Nunley, A. A. Gal, J. D. Vega, C. Perlino, P. Smith, and E. Clinton Lawrence, "Saprophytic fungal infections and complications involving the bronchial anastomosis following human lung transplantation," *Chest*, vol. 122, no. 4, pp. 1185–1191, 2002.
- [31] D. W. Denning and D. A. Stevens, "Antifungal and surgical treatment of invasive aspergillosis: review of 2,121 published cases," *Reviews of Infectious Diseases*, vol. 12, no. 6, pp. 1147–1201, 1990.
- [32] M. Noppen, I. Claes, B. Maillet, M. Meysman, I. Monsieur, and W. Vincken, "Three cases of bronchial stump aspergillosis: unusual clinical presentations and beneficial effect of oral itraconazole," *European Respiratory Journal*, vol. 8, no. 3, pp. 477–480, 1995.
- [33] J. Roig, J. Ruiz, X. Puig, A. Carreres, and J. Morera, "Bronchial stump aspergillosis four years after lobectomy," *Chest*, vol. 104, no. 1, pp. 295–296, 1993.
- [34] J. P. Le Rochais, P. Icard, T. Simon, P. Poirier, and C. Evrard, "Bronchial stump aspergillosis," *Annals of Thoracic Surgery*, vol. 70, no. 1, pp. 302–304, 2000.
- [35] L. Kumar, M. Singh, S. K. Mitra, and C. K. Bannerjee, "Superadded aspergillosis on carcinoid bronchial adenoma leading to delayed diagnosis," *Postgraduate Medical Journal*, vol. 66, no. 781, pp. 938–939, 1990.
- [36] P. M. Logan, S. L. Primack, R. R. Miller, and N. L. Muller, "Invasive aspergillosis of the airways: radiographic, CT, and pathologic findings," *Radiology*, vol. 193, no. 2, pp. 383–388, 1994.
- [37] C. A. Kemper, J. S. Hostetler, S. E. Follansbee et al., "Ulcerative and plaque-like tracheobronchitis due to infection with *Aspergillus* in patients with AIDS," *Clinical Infectious Diseases*, vol. 17, no. 3, pp. 344–352, 1993.
- [38] M. I. Ahn, S. H. Park, J. A. Kim, M. S. Kwon, and Y. H. Park, "Pseudomembranous necrotizing bronchial aspergillosis," *British Journal of Radiology*, vol. 73, no. 865, pp. 73–75, 2000.
- [39] S. Irani, T. Brack, and E. W. Russi, "Tracheobronchial mucosal lesions in a 40-year-old bone marrow recipient," *Respiration*, vol. 70, no. 3, p. 302, 2003.

- [40] S. M. Chang, H. T. Kuo, F. J. Lin, C. Y. Tzen, and C. Y. Sheu, “Pseudomembranous tracheobronchitis caused by *Aspergillus* in immunocompromised patients,” *Scandinavian Journal of Infectious Diseases*, vol. 37, no. 11-12, pp. 937–942, 2005.
- [41] J. Franco, C. Muñoz, B. Vila, and J. Marín, “Pseudomembranous invasive tracheobronchial aspergillosis,” *Thorax*, vol. 59, no. 5, p. 452, 2004.
- [42] A. Mohan, R. Guleria, S. Mukhopadhyaya, C. Das, A. Nayak, and S. K. Sharma, “Invasive tracheobronchial aspergillosis in an immunocompetent person,” *American Journal of the Medical Sciences*, vol. 329, no. 2, pp. 107–109, 2005.
- [43] S. Ascioglu, J. H. Rex, B. De Pauw et al., “Defining opportunistic invasive fungal infections in immunocompromised patients with cancer and hematopoietic stem cell transplants: an international consensus,” *Clinical Infectious Diseases*, vol. 34, no. 1, pp. 7–14, 2002.
- [44] B. De Pauw, T. J. Walsh, J. P. Donnelly et al., “Revised definitions of invasive fungal disease from the European Organization for Research and Treatment of Cancer/Invasive Fungal Infections Cooperative Group and the National Institute of Allergy and Infectious Diseases Mycoses Study Group (EORTC/MSG) Consensus Group,” *Clinical Infectious Diseases*, vol. 46, no. 12, pp. 1813–1821, 2008.
- [45] S. Tasci, A. Glasmacher, S. Lentini et al., “Pseudomembranous and obstructive *Aspergillus* tracheobronchitis—optimal diagnostic strategy and outcome,” *Mycoses*, vol. 49, no. 1, pp. 37–42, 2006.
- [46] N. Wu, Y. Huang, Q. Li, C. Bai, H. D. Huang, and X. P. Yao, “Isolated invasive *Aspergillus* tracheobronchitis: a clinical study of 19 cases,” *Clinical Microbiology and Infection*, vol. 16, no. 6, pp. 689–695, 2010.
- [47] B. Mehrad, G. Paciocco, F. J. Martinez, T. C. Ojo, M. D. Iannettoni, and J. P. Lynch, “Spectrum of *Aspergillus* infection in lung transplant recipients: case series and review of the literature,” *Chest*, vol. 119, no. 1, pp. 169–175, 2001.
- [48] A. Solé, P. Morant, M. Salavert et al., “*Aspergillus* infections in lung transplant recipients: risk factors and outcome,” *Clinical Microbiology and Infection*, vol. 11, no. 5, pp. 359–365, 2005.
- [49] S. D. Nathan, A. F. Shorr, M. E. Schmidt, and N. A. Burton, “*Aspergillus* and endobronchial abnormalities in lung transplant recipients,” *Chest*, vol. 118, no. 2, pp. 403–407, 2000.
- [50] N. Singh and S. Husain, “*Aspergillus* infections after lung transplantation: clinical differences in type of transplant and implications for management,” *Journal of Heart and Lung Transplantation*, vol. 22, no. 3, pp. 258–266, 2003.
- [51] M. Helmi, R. B. Love, D. Welter, R. D. Cornwell, and K. C. Meyer, “*Aspergillus* infection in lung transplant recipients with cystic fibrosis: risk factors and outcomes comparison to other types of transplant recipients,” *Chest*, vol. 123, no. 3, pp. 800–808, 2003.
- [52] A. Vadnerkar, C. J. Clancy, U. Celik et al., “Impact of mold infections in explanted lungs on outcomes of lung transplantation,” *Transplantation*, vol. 89, no. 2, pp. 253–260, 2010.
- [53] P. A. Flume, T. M. Egan, L. J. Paradowski, F. C. Detterbeck, J. T. Thompson, and J. R. Yankaskas, “Infectious complications of lung transplantation: impact of cystic fibrosis,” *American Journal of Respiratory and Critical Care Medicine*, vol. 149, no. 6, pp. 1601–1607, 1994.
- [54] D. R. Nunley, N. P. Otori, W. F. Grgurich et al., “Pulmonary aspergillosis in cystic fibrosis lung transplant recipients,” *Chest*, vol. 114, no. 5, pp. 1321–1329, 1998.
- [55] E. J. Kwak, S. Husain, A. Obman et al., “Efficacy of galactomannan antigen in the Platelia *Aspergillus* enzyme immunoassay for diagnosis of invasive aspergillosis in liver transplant recipients,” *Journal of Clinical Microbiology*, vol. 42, no. 1, pp. 435–438, 2004.
- [56] S. Husain, D. L. Paterson, S. M. Studer et al., “*Aspergillus* galactomannan antigen in the bronchoalveolar lavage fluid for the diagnosis of invasive aspergillosis in lung transplant recipients,” *Transplantation*, vol. 83, no. 10, pp. 1330–1336, 2007.
- [57] M. R. Aerni, J. G. Parambil, M. S. Allen, and J. P. Utz, “Nontraumatic disruption of the fibrocartilaginous trachea: causes and clinical outcomes,” *Chest*, vol. 130, no. 4, pp. 1143–1149, 2006.
- [58] S. Husain, D. Zaldonis, S. Kusne, E. J. Kwak, D. L. Paterson, and K. R. McCurry, “Variation in antifungal prophylaxis strategies in lung transplantation,” *Transplant Infectious Disease*, vol. 8, no. 4, pp. 213–218, 2006.
- [59] A. Solé and M. Salavert, “Fungal infections after lung transplantation,” *Current Opinion in Pulmonary Medicine*, vol. 15, no. 3, pp. 243–253, 2009.

- [60] R. Zaragoza, J. Pemán, M. Salavert et al., “Multidisciplinary approach to the treatment of invasive fungal infections in adult patients. Prophylaxis, empirical, preemptive or targeted therapy, which is the best in the different hosts?” *Therapeutics and Clinical Risk Management*, vol. 4, no. 6, pp. 1261–1280, 2008.
- [61] A. Solé, “Invasive fungal infections in lung transplantation: role of aerosolised amphotericin B,” *International Journal of Antimicrobial Agents*, vol. 32, no. 2, pp. S161–S165, 2008.
- [62] J. M. Borro, A. Solé, M. de la Torre et al., “Efficiency and safety of inhaled amphotericin B lipid complex (Abelcet) in the prophylaxis of invasive fungal infections following lung transplantation,” *Transplantation Proceedings*, vol. 40, no. 9, pp. 3090–3093, 2008.
- [63] V. Monforte, P. Ussetti, J. Gavalda et al., “Feasibility, tolerability, and outcomes of nebulized liposomal amphotericin B for Aspergillus infection prevention in lung transplantation,” *Journal of Heart and Lung Transplantation*, vol. 29, no. 5, pp. 523–530, 2010.
- [64] A. Clarke, J. Skelton, and R. S. Fraser, “Fungal tracheobronchitis. Report of 9 cases and review of the literature,” *Medicine*, vol. 70, no. 1, pp. 1–14, 1991.
- [65] J. M. Sancho, J. M. Ribera, A. Rosell, C. Muñoz, and E. Feliu, “Unusual invasive bronchial aspergillosis in a patient with acute lymphoblastic leukemia,” *Haematologica*, vol. 82, no. 6, pp. 701–702, 1997.
- [66] R. Krenke, A. Kołkowska-Leśniak, G. Pałynyczko, M. Prochorec-Sobieszek, and L. Konopka, “Ulcerative and pseudomembranous Aspergillus tracheobronchitis in a patient with acute myeloid leukemia,” *International Journal of Hematology*, vol. 89, no. 3, pp. 257–258, 2009.
- [67] J. M. Arriero, E. Chiner, J. Marco, M. J. Mayol, and M. Serna, “Simultaneous obstructing and pseudomembranous necrotizing tracheobronchitis due to Aspergillus flavus,” *Clinical Infectious Diseases*, vol. 26, no. 6, pp. 1464–1465, 1998.
- [68] D. Buchheidt, A. Weiss, S. Reiter, G. Hartung, and R. Hehlmann, “Pseudomembranous tracheobronchial aspergillosis: a rare manifestation of invasive aspergillosis in a non-neutropenic patient with Hodgkin’s disease,” *Mycoses*, vol. 46, no. 1-2, pp. 51–55, 2003.
- [69] S. Van Assen, G. P. Bootsma, P. E. Verweij, J. P. Donnelly, and J. M. M. Racemakers, “Aspergillus tracheobronchitis after allogeneic bone marrow transplantation,” *Bone Marrow Transplantation*, vol. 26, no. 10, pp. 1131–1132, 2000.
- [70] U. Machida, M. Kami, Y. Kanda et al., “Aspergillus tracheobronchitis after allogeneic bone marrow transplantation,” *Bone Marrow Transplantation*, vol. 24, no. 10, pp. 1145–1149, 1999.
- [71] R. F. Casal, R. Adachi, C. A. Jimenez, M. Sarkiss, R. C. Morice, and G. A. Eapen, “Diagnosis of invasive aspergillus tracheobronchitis facilitated by endobronchial ultrasound-guided transbronchial needle aspiration: a case report,” *Journal of Medical Case Reports*, vol. 3, article 9290, 2009.
- [72] C. Routsis, P. Kaltsas, E. Bessis, D. Rontogianni, S. Kollias, and C. Roussos, “Airway obstruction and acute respiratory failure due to Aspergillus tracheobronchitis,” *Critical Care Medicine*, vol. 32, no. 2, pp. 580–582, 2004.
- [73] S. A. Garofano, D. E. Stover, G. W. Freeberg, and D. S. Klimstra, “Necrotizing aspergillus tracheobronchitis: a case associated with fatal hemorrhage following endobronchial biopsy,” *Journal Of Bronchology*, vol. 1, pp. 299–303, 1994.
- [74] N. T. Berlinger and T. J. Freeman, “Acute airway obstruction due to necrotizing tracheobronchial aspergillosis in immunocompromised patients: a new clinical entity,” *Annals of Otology, Rhinology and Laryngology*, vol. 98, no. 9, pp. 718–720, 1989.
- [75] A. Ramos, J. Segovia, M. Gómez-Bueno et al., “Pseudomembranous aspergillus tracheobronchitis in a heart transplant recipient: case report,” *Transplant Infectious Disease*, vol. 12, no. 1, pp. 60–63, 2010.
- [76] F. G. De Rosa, P. Terragni, D. Pasero et al., “Combination antifungal treatment of pseudomembranous tracheobronchial invasive aspergillosis: a case report,” *Intensive Care Medicine*, vol. 35, no. 9, pp. 1641–1643, 2009.
- [77] T. J. Walsh, E. J. Anaissie, D. W. Denning et al., “Treatment of aspergillosis: clinical practice guidelines of the infectious diseases society of America,” *Clinical Infectious Diseases*, vol. 46, no. 3, pp. 327–360, 2008.
- [78] A. Moreno, M. Perez-Elías, J. Casado et al., “Role of antiretroviral therapy in long-term survival of patients with AIDS-related pulmonary aspergillosis,” *European Journal of Clinical Microbiology and Infectious Diseases*, vol. 19, no. 9, pp. 688–693, 2000.

- [79] N. K. Pervez, J. Kleinerman, M. Kattan et al., “Pseudomembranous necrotizing bronchial aspergillosis. A variant of invasive aspergillosis in a patient with hemophilia and acquired immune deficiency syndrome,” *American Review of Respiratory Disease*, vol. 131, no. 6, pp. 961–963, 1985.
- [80] E. Roilides, A. Holmes, C. Blake, P. A. Pizzo, and T. J. Walsh, “Defective antifungal activity of monocyte-derived macrophages from human immunodeficiency virus-infected children against *Aspergillus fumigatus*,” *Journal of Infectious Diseases*, vol. 168, no. 6, pp. 1562–1565, 1993.
- [81] I. D. Conte, G. Riva, R. Obert et al., “Tracheobronchial aspergillosis in a patient with AIDS treated with aerosolized amphotericin B combined with itraconazole,” *Mycoses*, vol. 39, no. 9-10, pp. 371–374, 1996.
- [82] E. Mylonakis, T. F. Barlam, T. Flanigan, and J. D. Rich, “Pulmonary aspergillosis and invasive disease in AIDS: review of 342 cases,” *Chest*, vol. 114, no. 1, pp. 251–262, 1998.
- [83] M. A. Judson and S. A. Sahn, “Endobronchial lesions in HIV-infected individuals,” *Chest*, vol. 105, no. 5, pp. 1314–1323, 1994.
- [84] S. E. Lee, J. H. Song, J. W. Shin et al., “A case of pseudomembranous necrotizing bronchial aspergillosis in an old age host,” *Tuberculosis and Respiratory Diseases*, vol. 63, no. 3, pp. 278–282, 2007.
- [85] H. J. Oh, H. R. Kim, K. E. Hwang et al., “Case of pseudomembranous necrotizing tracheobronchial aspergillosis in an immunocompetent host,” *Korean Journal of Internal Medicine*, vol. 21, no. 4, pp. 279–282, 2006.
- [86] S. De and P. Desikan, “Unusual cause of chronic cough in an immunocompetent host,” *Journal of Bronchology*, vol. 16, no. 1, pp. 61–62, 2009.
- [87] P. Pornsuriyasak, S. Murgu, and H. Colt, “Pseudomembranous aspergillus tracheobronchitis superimposed on post-tuberculosis tracheal stenosis,” *Respirology*, vol. 14, no. 1, pp. 144–147, 2009.
- [88] T. Niimi, M. Kajita, and H. Saito, “Necrotizing bronchial aspergillosis in a patient receiving neoadjuvant chemotherapy for non-small cell lung carcinoma,” *Chest*, vol. 100, no. 1, pp. 277–279, 1991.
- [89] A. Al-Alawi and F. Ryan, “Aspergillus pseudomembranous tracheobronchitis complicating treatment of COPD exacerbations,” *Kuwait Medical Journal*, vol. 39, pp. 184–187, 2007.
- [90] M. Ruhnke, E. Eichenauer, J. Searle, and F. Lippek, “Fulminant tracheobronchial and pulmonary aspergillosis complicating imported *Plasmodium falciparum* malaria in an apparently immunocompetent woman,” *Clinical Infectious Diseases*, vol. 30, no. 6, pp. 938–940, 2000.
- [91] P. H. Kuo, L. N. Lee, P. C. Yang, Y. C. Chen, and K. T. Luh, “Aspergillus laryngotracheobronchitis presenting as stridor in a patient with peripheral T cell lymphoma,” *Thorax*, vol. 51, no. 8, pp. 869–870, 1996.
- [92] S. Tasci, H. Schäfer, S. Ewig, B. Lüderitz, and H. Zhou, “Pseudomembranous *Aspergillus fumigatus* tracheobronchitis causing life-threatening tracheobronchial obstruction in a mechanically ventilated patient,” *Intensive Care Medicine*, vol. 26, no. 1, pp. 143–144, 2000.
- [93] L. P. Koh, Y. T. Goh, Y. C. Linn, J. Hwang, and P. Tan, “Pseudomembranous tracheobronchitis caused by *Aspergillus* in a patient after peripheral blood stem cell transplantation,” *Annals of the Academy of Medicine Singapore*, vol. 29, no. 4, pp. 531–533, 2000.
- [94] C. Routsi, E. Platsouka, A. Prekates, D. Rontogianni, O. Paniara, and C. Roussos, “Aspergillus bronchitis causing atelectasis and acute respiratory failure in an immunocompromised patient,” *Infection*, vol. 29, no. 4, pp. 243–244, 2001.
- [95] M. Onozawa, S. Takahashi, H. Kanamori et al., “Pseudomembranous tracheobronchial aspergillosis,” *Internal Medicine Journal*, vol. 39, no. 1, pp. 65–66, 2009.

This article should be cited as follows:

Rafal Krenke and Elzbieta M. Grabczak, “Tracheobronchial Manifestations of *Aspergillus* Infections,” *TheScientificWorldJOURNAL*, vol. 11, pp. 2310–2329, 2011.

