

How to do it

Transabdominal minimally invasive direct coronary artery bypass grafting (MIDCAB)[☆]

Valavanur A. Subramanian^{*}, Nilesh U. Patel

Lenox Hill Hospital, New York, NY, USA

Received 7 September 1999; received in revised form 28 December 1999; accepted 26 January 2000

Abstract

The major limitations of current minimally invasive direct coronary artery bypass (MIDCAB) techniques are multivessel and distal vessel disease frequently seen in patients with extensive stent restenosis ('full metal jacket syndrome') and reoperative surgery. Two separate minimal access incisions (minithoracotomy, lower partial sternotomy) have been used to bypass two separate arteries (left internal mammary artery (LIMA) to left anterior descending (LAD), right gastroepiploic artery (RGEA) to posterior descending artery (PDA)). To bypass multiple coronary arteries using multiple arterial conduits without violation of bony parts, we use a new minimal access incision by 'transabdominal approach'. © 2000 Elsevier Science B.V. All rights reserved.

Keywords: Transabdominal; Minimally invasive; Coronary bypass

1. Introduction

Despite increasing application of minimally invasive direct coronary artery bypass (MIDCAB) through variety of access incisions and encouraging early clinical results reported by Benetti [1], Buffolo [2], Calafiore [3], Subramanian [4] and their associates, the procedure has met with concerns regarding its technical limitations. Of all the MIDCAB procedures, LIMA to LAD MIDCAB has been the most standardized procedure with proven clinical results. However, the major technical difficulties with this approach are distal and multivessel disease and also complications like peri-operative pain and morbidity due to rib fractures.

After the development of subxiphoid approach for inferior wall revascularization, two separate access incisions were being used to bypass multiple vessels [5]. The major disadvantages with this approach were need for two separate incisions, which included violation of some of the bony parts and difficulty with stabilization of inferior wall vessel due to narrow working angle.

Our preliminary observations were based on some simple physiological facts:

1. Ectus abdominis muscle is the strongest downward pull on the lower sternum.
2. When the rib cage is elevated, the lower ribs projected directly forward so that sternum also moves away from the spine increasing anteroposterior diameter of the chest by 20%.

This led us to the development of this new access approach.

2. Surgical technique

Standard anesthesia techniques and monitoring lines are used in all patients. A 2–3" curvilinear epigastric incision (Fig. 1) just under the xiphisternum and lower costal margin is made. Both rectus abdominis muscles with their anterior and posterior sheaths are divided. Neurovascular bundles, which run on the lateral margins of the recti are preserved to reduce post-operative pain. The cut edges of recti are marsupelized by several retractor sutures anchored to the skin. Bilateral costal attachments of diaphragm are released with cautery to further facilitate exposure and to increase the working angle. The lower edge of the sternum and the costal arch are lifted with table mounted internal mammary artery (IMA) retractor hooks. Sterno-pericardial ligament and fibrous adhesions are divided with cautery to drop

[☆] Presented at the 13th Annual Meeting of the European Association for Cardio-thoracic Surgery, Glasgow, Scotland, UK, September 5–8, 1999.

^{*} Corresponding author. Department of Surgery, 130 East 77th Street, 4th Floor, New York, NY 10021, USA. Tel.: +1-212-434-3000; fax: +1-212-434-4559.

E-mail address: vasubramanian@csi.com (V.A. Subramanian)

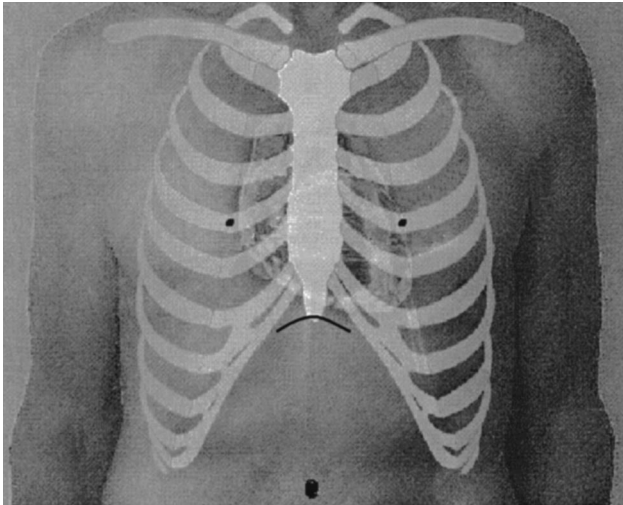


Fig. 1. Trans abdominal incision.

down the mediastinum. Due to the ‘bucket handle’ movement of the lower ribs, the lower sternum is lifted enabling dissection of mammary arteries under direct vision up to 2nd or 3rd space. Thoracoscopic technique has been used in some patients to facilitate mammary harvesting. The right gastroepiploic artery is harvested by opening the peritoneum and clipping its branches. The left anterior descending coronary artery is approached through inverted T pericardiotomy above the diaphragm with dislocation of the anterior surface of the left ventricle to midline by deep left lateral pericardial stay sutures with retraction of these towards right side (Fig. 2). Mid right coronary artery can also be approached from above the diaphragm. Taking deep diaphragmatic stay sutures and pulling them right and downwards helps to dislocate the inferior surface of the heart and provides excellent exposure to mid right coronary artery (Fig. 2). Posterior descending and posterolateral coronary arteries can be approached through a 1.5" incision

in the central tendon of diaphragm. The division of left triangular ligament and retraction of left liver lobe downwards and towards right provides adequate working space. Once target vessels are exposed a CTS (Cardio Thoracic Systems, Inc., Cupertino, CA) multivessel stabilizer (used for MIDCAB of left internal mammary artery to left anterior descending coronary artery) is placed in the lower edge of wound. The stabilizer is mounted on the left lower angle of the retractor for all the target vessels. Silastic loops are used for local coronary occlusion and coronary anastomosis is performed in a standard manner with continuous 7:0 prolene suture. Intacoronary shunt is used if ischaemic changes occur during preconditioning. A small pericardial tube is placed for drainage at the end of the procedure. Anterior rectus sheath is closed with unabsorbable suture and the other wound layers with Vicryl.

3. Discussion

Advantages of transabdominal approach are single incision for multivessel grafting, cosmetically better, use of bilateral mammary even in diabetics as no bony parts are violated and availability of multiple arterial conduits in the event of injury to one of them. However, this approach may present difficulties in obese patients with large A-P diameter of the chest and those with previous abdominal surgery or with hepatomegaly. Current restricting factors in achieving a totally endoscopic approach are difficult instrumentation and mobility due to the rigidity of chest cavity. The diaphragm being a non-rigid ‘door’ for the front, bottom and back surface of the heart, with the use of intra abdominal insufflations, endoscopic IMA harvesting, right heart assist device and robotic assistance, the transabdominal approach creates the highest potential for the route to totally endoscopic coronary artery bypass surgery.

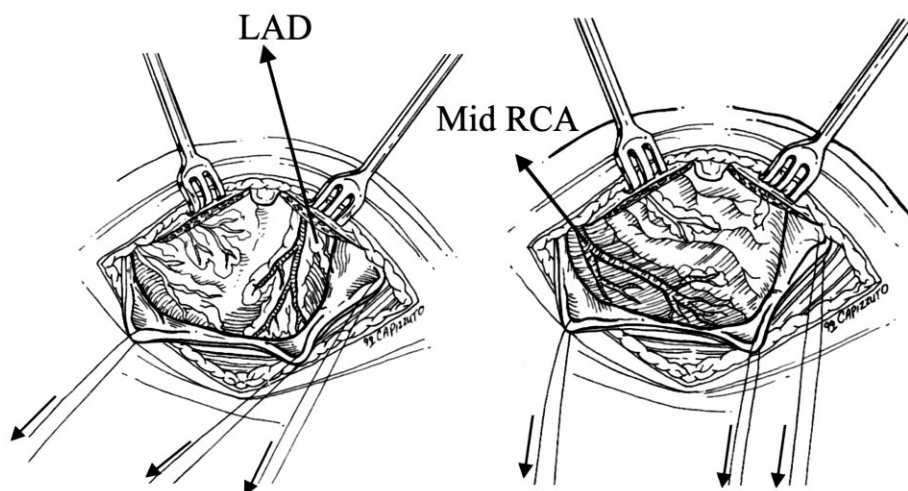


Fig. 2. Exposure of LAD and Mid right coronary artery (RCA) by Trans abdominal approach.

References

- [1] Benneti FJ, Ballester C, Sani G, Boonstra P, Grandjean J. Video assisted coronary artery bypass surgery. *J Card Surg* 1995;10:620–625.
- [2] Buffolo ED, DE Andrade JCS, Branco JNR, Teles CA, Aguiar LF, Gomes WJ. Coronary artery bypass grafting without cardiopulmonary bypass. *Ann Thorac Surg* 1992;54:108–192.
- [3] Calafiore AM, Di Giammarco G, Teodori G, Bosco G, D'Annunzio E, Barsotti A, Maddestra N, Paloscia L, Vitolla G, Sciarra A, Fino C, Contini M. Left anterior descending coronary artery grafting via left anterior small thoracotomy without cardiopulmonary bypass. *Ann Thorac Surg* 1996;61:1658–1665.
- [4] Subramanian VA, Sani G, Benetti FJ, Calafiore AM. Minimally invasive coronary bypass surgery: a multi-center report of preliminary clinical experience. *Circulation* 1995;92(Suppl 8):1645.
- [5] Sari V, Kalervo V, Antero J, Markku K, Pekka K, Petri V, Severi M. Minimally invasive coronary artery bypass grafting using the right gastroepiploic artery. *Ann Thorac Surg* 1998;65:444–448.

Appendix A. Conference discussion

Dr S. Schueler (*Dresden, Germany*): I have a question. There is always a concern if we open the abdomen as to whether there will be some problems after the operation, especially in these older patients you have shown us. Did you see any intestinal problems after surgery?

Dr Subramanian (*New York, NY, USA*): This is a very limited upper abdominal exploration. We have a large experience in the gastroepiploic artery, about 700 patients. We limit dissection to the upper abdomen, and haven't seen any peritoneal or ileus problems in these patients. In fact, the NG tube is taken out as soon as they are extubated, within the first 2 or 3 h.

Dr C. Yankah (*Berlin, Germany*): My question is, did you study the intraoperative flow dynamics of these vessels, because you might have a

functional flow insufficiency, which might occur later on by many factors? Is it planned in your studies to find out, flow dependent factors such as arteriosclerosis, cholesterinemia, which might influence the flow dynamics of this gastroepiploic artery?

Dr Subramanian: All I can tell you is that we are prospectively following these patients with an angiogram as well as a stress thallium for asymptomatic ischaemia, and so far we haven't seen it. As I said, we have a very large experience in the gastroepiploic artery bypass grafting to the inferior wall. The clinical results have been excellent in this group.

Dr J. Melo (*Carnaxide, Portugal*): Can you give us more fine details on the early recovery of these patients regarding pain in the area where most muscles are completely cut and about chest pain in the early postoperative period?

Dr Subramanian: I don't understand your question. People have asked me about the pain in the abdominal incision, because the rectus is divided. The most important part is that we preserve the neurovascular bundle, which comes laterally. You do not have to cut that to divide the rectus. And as far as thoracic cage lifting, the only bony area you may have to cut is a projecting xiphoid, which may come in your way for the LAD anastomosis. The lower part of the chest cage is very flexible, so you can spread it like wings of a bird.

Dr Melo: Your patients stay in the hospital for how long?

Dr Subramanian: The patients stay, for a mean of 2.9 days.

Dr V. Guliemos (*Dresden, Germany*): Just a short technical question. In terms of pulling through of the right GEA using this approach, are you obliged to cut down the diaphragm or are you obliged to make a hole pulling through the right GEA, or you can do either way?

Dr Subramanian: There are three ways to do it. If it is a distal RCA, we can just go through the anterior part of the diaphragm, if it is PDA we would go by a transdiaphragmatic approach, (central tendon of diaphragm) if it's LAD, We just make a very small niche in the diaphragm because the plane of the LAD is pretty much on the plane of the diaphragmatic attachment to the costal margin.