

Transapical transcatheter aortic valve implantation using the JenaValve™ system: acute and 30-day results of the multicentre CE-mark study†

Hendrik Treede^{a,*}, Friedrich-Wilhelm Mohr^{b,†}, Stephan Baldus^c, Ardawan Rastan^b, Stephan Ensminger^d, Martin Arnold^e, Joerg Kempfert^f and Hans-Reiner Figulla^g

^a Department of Cardiovascular Surgery, University Heart Center, Hamburg, Germany

^b Department of Cardiac Surgery, Heart Center Leipzig, Leipzig, Germany

^c Department of General and Interventional Cardiology, University Heart Center, Hamburg, Germany

^d Department of Cardiac Surgery, University Heart Center, Erlangen, Germany

^e Department of Cardiology, University Heart Center, Erlangen, Germany

^f Department of Cardiac Surgery, Kerckhoff Clinic, Bad Nauheim, Germany

^g Department of Cardiology, University Heart Center of Thuringia, Jena, Germany

* Corresponding author. Department of Cardiovascular Surgery, University Heart Center Hamburg, Martinistr. 52, 20246 Hamburg, Germany. Tel: +49-40-741058949; fax: +49-40-741057926; e-mail: treede@uke.de (H. Treede).

Received 29 September 2011; received in revised form 21 January 2012; accepted 27 January 2012

Abstract

OBJECTIVES: Transcatheter aortic valve implantation (TAVI) has shown promising results in patients with severe aortic stenosis (AS) at high risk for conventional heart surgery. The safety and efficacy of transapical aortic valve implantation using the JenaValve™, a second-generation TAVI device, were evaluated. The system consists of a tested porcine root valve mounted on a nitinol stent with feeler-guided positioning and clip fixation on the diseased leaflets.

METHODS: This multicentre, prospective, single-arm study, conducted at seven German sites, enrolled 73 patients (mean age 83.1 ± 3.9), European System for Cardiac Operative Risk Evaluation (EuroSCORE) ($28.4 \pm 6.5\%$) of whom 67 patients underwent elective TAVI. Three sizes were used for annular diameters up to 23 mm ($n = 21$), 25 mm ($n = 31$) and 27 mm ($n = 15$). Clinical and echocardiographic evaluations were performed at baseline, post-procedure, discharge and 30 days, and also at 3, 6 and 12 months. The primary endpoint was all-cause mortality at 30 days. Secondary endpoints were procedural success, major adverse cardiac and cerebrovascular events and echocardiographic performance.

RESULTS: TAVI with the JenaValve™ device was successful in 60 patients (procedural success rate 89.6%). The overall mortality at 30 days was 7.6%. Conversion to surgery was necessary in four patients (6%), two patients underwent valve-in-valve implantations (3%), one patient was withdrawn per protocol after conversion to TAVI using a balloon-expandable valve (1.5%) since the patient did not receive the study device. Perioperative stroke occurred in two cases (3%). Pacemaker implantation for new onset conduction disorders was necessary in six patients (9.1%). No ostial coronary obstructions were seen. Post-procedure TAVI resulted in favourable reduction of mean transvalvular gradients (40.6 ± 15.9 vs. 10.0 ± 7.2 mmHg, $P < 0.0001$) and increase in valve opening area (0.7 ± 0.2 vs. 1.7 ± 0.6 cm², $P < 0.0001$). The majority of successfully treated patients revealed no or minimal paravalvular aortic regurgitation (86.4%); none of the patients had severe post-procedural regurgitation (>2+).

CONCLUSIONS: Transapical JenaValve™ implantation was safe and effective in the treatment of severe AS in elderly patients at high risk for surgery. Active clip fixation on the native leaflets and anatomically correct feeler-guided positioning led to good functionality and prevented ostial coronary impairment. Implantation without the need for rapid pacing prevented haemodynamic compromise during valve implantation.

Keywords: Aortic valve stenosis • Transapical • Transcatheter • Minimally invasive • Self-expanding

INTRODUCTION

Transcatheter aortic valve implantation (TAVI) has become a routine treatment option for severe aortic stenosis (AS) in

patients at high risk for surgical aortic valve replacement (AVR) [1–5]. To date, two TAVI systems have received CE-mark approval and are currently commercially available: the self-expanding Medtronic CoreValve™ (Medtronic Inc., St. Paul, MN, USA) and the balloon-expandable Edwards Sapien XT™ (Edwards Lifesciences Inc., Irvine, CA, USA) system. More than 15 000 TAVI procedures have been performed worldwide to date. The transapical approach has been evaluated in clinical studies since 2004,

† Presented at the 25th Annual Meeting of the European Association for Cardio-Thoracic Surgery Lisbon, Portugal, 1–5 October 2011.

† Both authors contributed equally to this manuscript.

using the Edwards Sapien™ valve to establish a TAVI technique that is independent of peripheral vascular status. Since 2008, the Edwards Sapien™ device has been the only commercially available valve approved for transapical TAVI. Major limitations of this device relate to the need for rapid procedural pacing and the limited capability of repositioning.

As a second-generation device, the JenaValve™ system (JenaValve Technology GmbH, Munich, Germany) features anatomically aligned positioning without the need for rapid pacing during implantation. During the first step of deployment, the valve is fully repositionable. The JenaValve™ consists of a porcine root valve mounted on a low-profile self-expanding nitinol stent. In contrast to devices expanding within the aortic annulus, the JenaValve™ relies on an active clip fixation on the native aortic valve leaflets. Coronary occlusion due to obstruction by leaflets is prevented. The device underwent successful animal testing [6] and a first-in-man implantation series [7]. Here, we report on the 30-day results of the JenaValve™ pivotal study for CE-mark approval conducted in seven German centres.

MATERIALS AND METHODS

Patients

Between October 2010 and July 2011, 73 patients were enrolled in the trial, six patients were excluded; five due to screening failures and one withdrew consent (Fig. 1). Surgical risk was assessed using the logistic EuroSCORE (European System for Cardiac Operative Risk Evaluation) [8]. Society of Thoracic Surgeons Predicted Risk of Mortality score calculation was not part of the study protocol.

Inclusion criteria involved patients with symptomatic AS with an aortic valve area of ≤ 1.0 cm² and/or a mean transvalvular pressure gradient of ≥ 40 mmHg and/or a peak velocity of >4 m/s, an aortic annulus diameter between 21 and 26.9 mm, age ≥ 75 years, New York Heart Association (NYHA) class \geq II and a logistic

EuroSCORE of $\geq 20\%$. Preprocedural transthoracic echocardiography (TTE) and transoesophageal echocardiography (TEE) were used for evaluation. Preprocedural imaging of the aorta and the femoral vessels was performed and analysed for aortic annulus diameters, straight length of the ascending aorta as measured from annulus to begin of curvature (≥ 65 mm) and distance between valve level and coronary ostia (≥ 8 mm).

All participating centres had clinical experience with transapical TAVI. The study was approved by the local ethics committees of the participating sites and the German competent authority (Bundesinstitut für Arzneimittel und Medizinprodukte). All patients provided written informed consent in accordance with the principles of the Declaration of Helsinki.

Study device

The JenaValve™ AVR system is designed as a tri-leaflet porcine root tissue valve. It is attached to a low profile nitinol stent with flexible stent posts supporting the valve leaflets and positioning feelers for accurate placement of the prosthesis with regard to the native valve leaflets (Fig. 2). The valve prosthesis is manufactured in three different sizes (23-, 25- and 27-mm) for implantation in native aortic annuli ranging from 21 to 27 mm in diameter. A sheathless 32Fr delivery catheter is utilized for the three-step deployment procedure.

Valve implantation

Implantation was performed in seven institutions in Germany (University Heart Center, Hamburg, 27 patients; Heart Center, Leipzig, 19 patients; University Hospital, Jena, 11 patients; University Heart Center, Erlangen, 9 patients; Kerckhoff Clinic, Bad Nauheim, 5 patients; German Heart Center, Munich, 1 patient and Heart Center, Bad Oeynhausen, 1 patient).

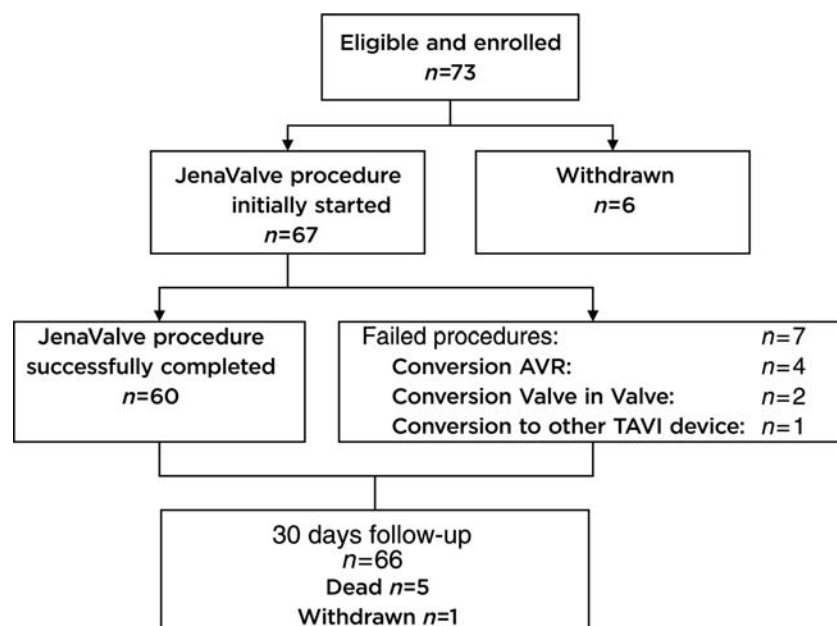


Figure 1: Flow chart.

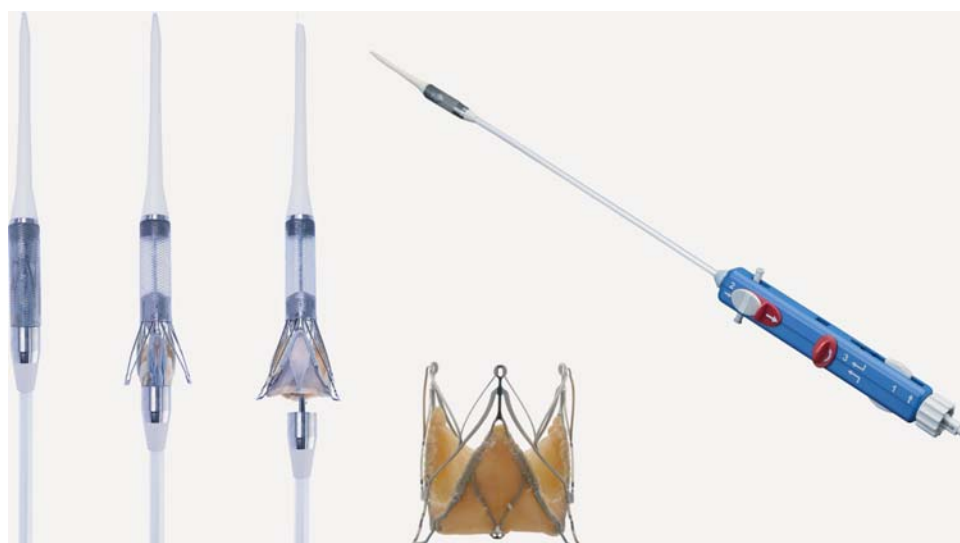

Figure 2: JenaValve™ prosthesis with porcine root valve and nitinol stent, delivery catheter.

All procedures were performed under general anaesthesia in hybrid operating rooms equipped for cardiologic interventions and cardiac operations. TEE was performed throughout the procedure. Transapical access was gained via left lateral minithoracotomy in the fifth or sixth intercostal space. Pleura and pericardium were opened and the apex was exposed using pericardial sutures. Two pledgeted purse-string sutures were placed apically and an epicardial pacemaker wire was positioned and tested for proper performance. After femoral artery puncture and the introduction of a 6F sheath, a pigtail catheter was advanced into the ascending aorta. A bolus of 5000–10 000 international units of heparin was administered intravenously in a weight-dependent manner to achieve an activated clotting time of >250 s.

After the apical puncture, a soft guidewire was advanced into the descending aorta and subsequently exchanged for a stiff guidewire. A 14F sheath was carefully introduced into the left ventricle followed by a balloon catheter. Pre-procedural balloon-valvuloplasty of the native valve was performed under rapid pacing. Sizing of the balloon was dependent on the size of the aortic annulus and the degree of calcification. After removal of the balloon, the delivery catheter with the loaded valve prosthesis was introduced over the wire into the left ventricle and advanced through the native valve into the ascending aorta. Complete valve deployment was performed under fluoroscopic control under beating heart conditions without rapid pacing. First, the positioning feelers were released and checked for correct orientation. By pulling back the catheter, the positioning feelers were placed deep into the sinuses of the native aortic root. Correct positioning was controlled by two fluoroscopic views in different angulations. Second, the lower stent part was released thereby clipping and attaching the native leaflets to the device simultaneously unfolding the porcine valve. Third, the upper stent part was opened and the device was completely deployed (Fig. 3). TEE and aortography were performed to reconfirm coronary flow, paravalvular and central regurgitation, transvalvular pressure gradients and effective valve opening area. In case of elevated transvalvular gradients or significant paravalvular leakage, re-balloon-valvuloplasty of the JenaValve™ was

performed. The delivery catheter was removed and ventricular haemostasis was achieved with the purse-string sutures. After the chest tube insertion surgical closure of the thoracotomy was carried out. Patients were treated with daily ASA 100 mg lifelong and 75 mg clopidogrel for at least 6 months post-procedure.

Follow-up

Patients underwent follow-up examinations including TTE and NYHA functional class status at the time of procedure, at discharge from hospital and at 30 days. Additional follow-up visits are scheduled for 3, 6 and 12 months. In order to generate accurate baseline and follow-up data comparisons, all echocardiographic data are reported from TTE. Adverse events were collected throughout the study.

Statistical analyses and data management

Continuous variables are expressed as mean \pm standard deviation. Categorical variables are presented as numbers and proportions (%). Two-sided 95% confidence intervals were calculated based on the binomial distribution. Changes in continuous variables between baseline and at 30 days were assessed using paired Student's *t*-test. Categorical variables were compared with the continuity-corrected χ^2 test for dependent samples. Statistical analyses were performed using statistical analysis software (SAS 9.2). A two-sided $P < 0.05$ was considered statistically significant. Data were monitored by an independent clinical research organization, an independent Data Safety Monitoring Board and major cardiac and cerebrovascular events adjudicated by an independent medical reviewer. The statistical analysis was performed by an independent statistician. All authors had full access to the complete data set and take responsibility for its integrity. All authors have read and agreed to the manuscript as written.

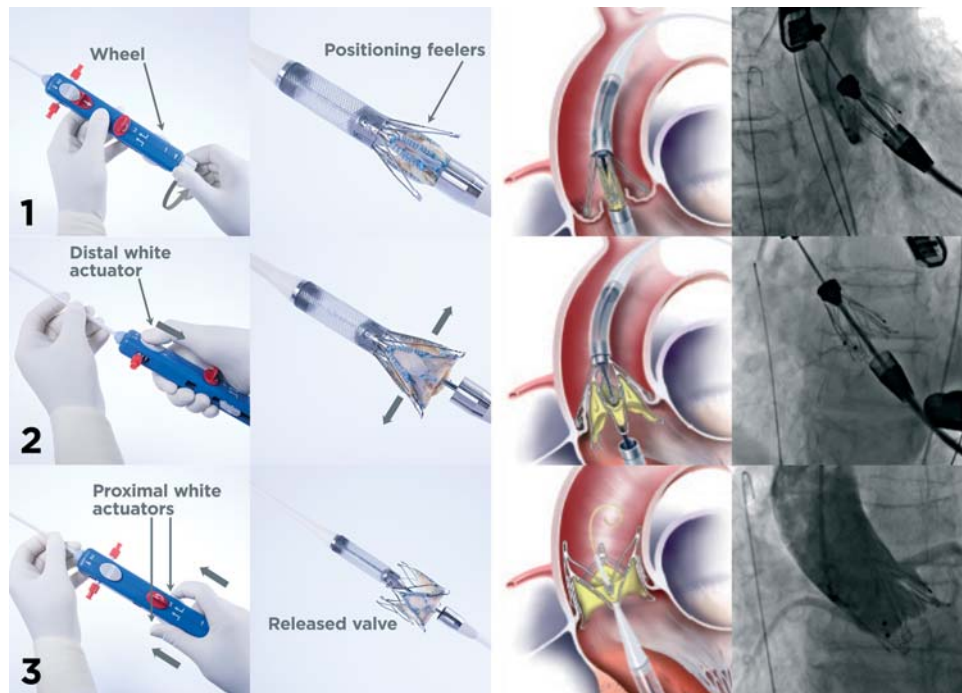


Figure 3: Deployment of the JenaValve™ in three steps.

RESULTS

Patients

Sixty-seven patients (35 men 32 women; mean age 83.1 ± 3.9 years) underwent TAVI with the JenaValve™ prosthesis. All patients suffered from severe symptomatic aortic valve stenosis. NYHA functional class III was present in the majority of patients (74.6%), class IV in 16.4% and class II in 9.0% of patients. Mean

left ventricular ejection fraction (LVEF) was $54.1 \pm 10.6\%$. Mean logistic EuroSCORE was $28.4 \pm 6.5\%$. Demographic and baseline characteristics including comorbidities are listed in Table 1.

Procedural results

Transapical implantation of the JenaValve™ prosthesis was successful in 60 of 67 patients (procedural success rate 89.6%). Mean implantation time (defined from time of insertion until the time of removal of the JenaValve™ delivery system) was 8.9 ± 6.9 min.

Conversion to surgical AVR due to valve dislocation was necessary in four patients (6%). Three patients recovered and were alive at 30-day follow-up, one died of non-cardiac cause on Day 6 post-procedure. Dislocations were caused by incorrect valve positioning ($n = 2$), bicuspid anatomy ($n = 1$) and difficulties with manipulation of the delivery catheter ($n = 2$). As a consequence, the design of the delivery catheter was changed to a more flexible housing simplifying delivery catheter removal through the valve prosthesis after deployment. One patient developed severe paravalvular regurgitation after supra-annular placement of the study valve and was treated with a successful transapical valve-in-valve implantation of a 26-mm Edwards Sapien prosthesis. Another patient underwent successful transapical valve-in-valve implantations with a 29-mm Edwards Sapien prosthesis after supra-annular migration of the JenaValve™ prostheses post-release. Both patients were alive and well at 30 days. It was not possible to deliver the JenaValve™ prosthesis to the correct annular position in one patient due to unsuitable (non-apical) ventricular access location. As per protocol, this patient was withdrawn from the study after discharge since the patient did not receive the study device.

In successfully treated patients, transvalvular pressure gradients significantly decreased from a mean of 40.6 ± 15.9 mmHg pre-

Table 1: Baseline characteristics and demographic data of the patients ($n = 67$)

Patients	(n) %
Age, years	83.1 ± 3.9
Male	(35) 52.2
Logistic EuroSCORE (%)	28.4 ± 6.5
NYHA class	
II	(6) 9.0
III	(50) 74.6
IV	(11) 16.4
Coronary artery disease	(36) 53.7
Prior CABG	(11) 16.4
Cerebrovascular disease	(14) 20.9
Peripheral vascular disease	(30) 44.8
Chronic obstructive pulmonary disease	(24) 35.8
Chronic renal insufficiency	(23) 34.3
Pulmonary hypertension	(23) 34.3
Diabetes	(23) 34.3
Atrial arrhythmia	(38) 56.7
Left ventricular ejection fraction, (%)	54.1 ± 10.6
Permanent pacemaker	(11) 16.4

CABG: coronary artery bypass grafting.

procedural to 10.0 ± 7.2 mmHg post-procedural ($P < 0.0001$). The effective orifice area (EOA) was increased from a mean of 0.7 ± 0.2 – 1.7 ± 0.6 cm² ($P < 0.0001$). Post-procedure the majority of patients showed either no [aortic regurgitation (AR) 0, 47.4%] or minor (AR ≤ 1 , 39.0%) paravalvular leakage and AR, while moderate AR 2+ was found in 13.6% of patients. No patient showed severe AR >2 +. Mean LVEF remained stable ($53.4 \pm 10.1\%$ pre-procedure vs. $55.9 \pm 10.3\%$ at Day 6, $n = 0.40$). Coronary ostia

were not obstructed in any of the procedures. Severe apical bleeding requiring cardiopulmonary bypass was necessary in two patients (3.0%). Both patients were initially successfully weaned from cardiopulmonary bypass; however, in one patient further haemodynamic support was required. During recannulation, a retrograde dissection of the descending aorta occurred leading to the patient's death. In one patient insertion of the diagnostic catheter led to rupture of the femoral artery and required surgical intervention. Procedural outcomes and characteristics are shown in Table 2, echocardiographic outcomes in Fig. 4.

Table 2: Procedural characteristics and outcomes ($n = 67$)

	All patients (n) %
Implanted valve size	
23-mm	(21) 31.3
25-mm	(31) 46.3
27-mm	(15) 22.7
Successful implantations	(60) 89.6
Conversion to open surgery	(4) 6.0
Conversion to TAVI	(1) 1.5
Valve-in-valve	(2) 3.0
Coronary ostium occlusion	(0) 0.0
Severe apical bleeding requiring extracorporeal bypass	(2) 3.0
Vascular complication	(2) 3.0
Retrograde dissection of descending aorta	(1) 1.5
Rupture of femoral artery	(1) 1.5

Follow-up at 30 days

All-cause mortality at 30 days was 7.6% (5 of 66 patients). Two patients died due to cardiac causes; one patient had an AV block III with a subsequent exit-block (Day 4) and one patient died of circulatory arrest (Day 4). Three patients died of non-cardiac causes [urosepsis (Day 16); retrograde dissection of the descending aorta caused by femoral cannulation for cardiopulmonary bypass (Day 0) and respiratory failure (Day 1)]. Two patients developed major cerebrovascular events (3.0%), one periprocedural and one at Day 2. New onset of renal failure requiring temporary haemodialysis occurred in three patients (4.5%). One patient developed endocarditis of the mitral valve which was treated medically. AV block, sick sinus syndrome and left bundle branch block (LBBB) required pacemaker implantation in

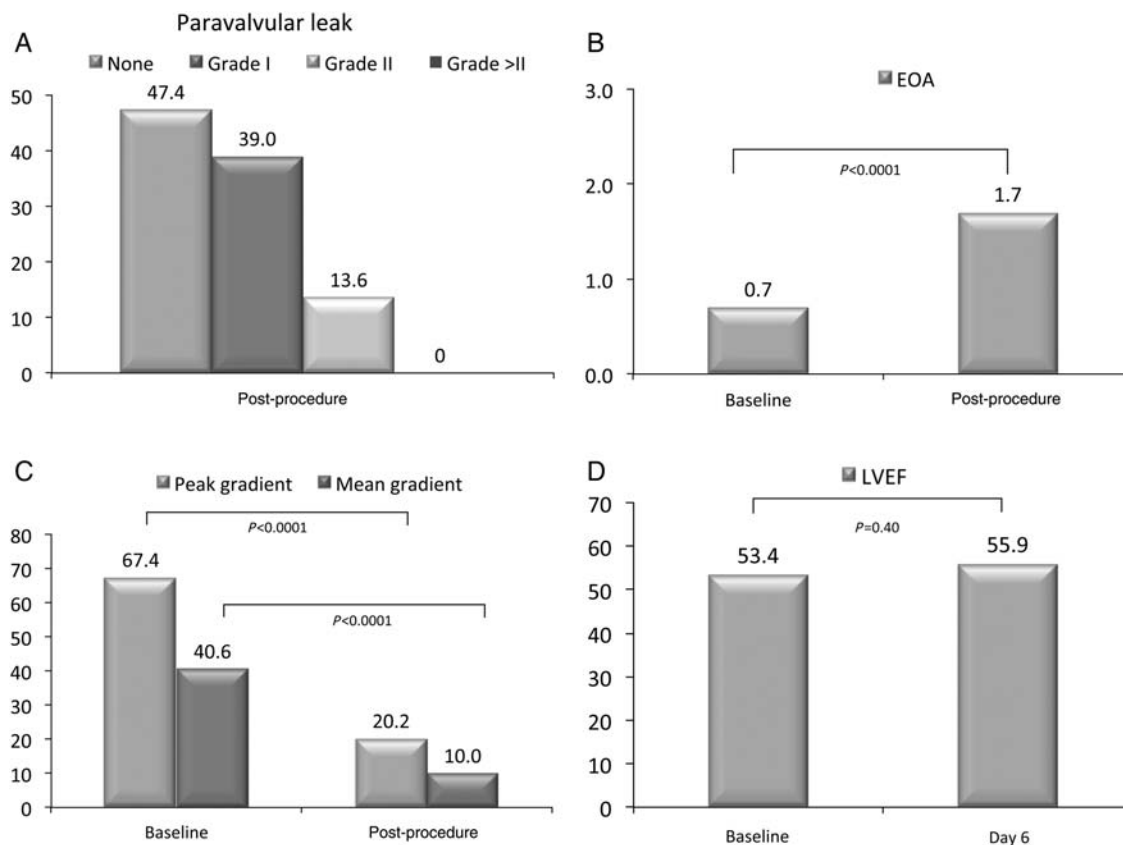


Figure 4: Echocardiographic outcomes variables: paravalvular leaks post procedure [%] (A), change in pre- and post-procedure EOA [cm²] (B), transvalvular gradients [mmHg] (C) and ejection fraction [%] (D).

Table 3: Major complications at 30 days^a (n = 66)

Outcomes	(n) %
Death	
All-cause death	(5) 7.6
Cardiac death	(2) 3.0
Stroke	(2) 3.0
Myocardial infarction	(0) 0
Conversion to open heart surgery	(4) 6.1
Renal failure requiring haemofiltration (new onset)	(3) 4.5
Endocarditis (mitral valve)	(1) 1.5
New pacemaker	(8) 12.1
New onset AV block	(5) 7.6
New onset LBBB	(1) 1.5
Persistent LBBB	(1) 1.5
Persistent sick sinus syndrome	(1) 1.5

^aThirty-day follow-up available for 66 patients.

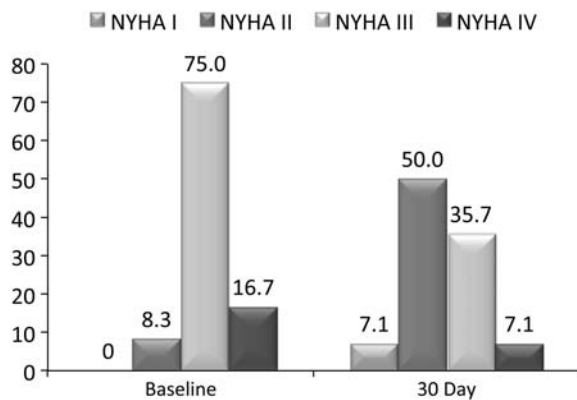


Figure 5: Change in NYHA functional class from baseline to 30-day follow-up.

eight patients (Table 3); two of these patients developed new AV block already after balloon valvuloplasty before implantation of the JenaValve™ prosthesis and two already showed sick sinus syndrome and LBBB before the procedure.

Patients were discharged from hospital after 10 ± 7 days (range 4–31 days). NYHA Functional Class improved significantly 30 days after valve implantation. The majority of patients (57.1%) presented with NYHA class I or II (7.1% NYHA class I, 50.0% NYHA class II), 35.7 with class III and 7.1% with NYHA class IV (Fig. 5).

DISCUSSION

TAVI has already become the treatment of choice in patients with severe AS at high risk for surgical AVR in many European countries and has proven superior results and better survival compared with medical treatment alone [9]. The proportion of elderly patients with significant comorbidities who are either not referred for surgical AVR or declined by surgeons can be as high as 30% [10]. Due to the demographic development in western

countries towards an aging population, a growing demand for less invasive treatment of AS can be anticipated.

The Medtronic CoreValve™ and the Edwards Sapien™ devices are currently the only two prostheses commercially available for TAVI. Design, technical differences and results have been previously described [11–13].

Retrograde transfemoral or transsubclavian TAVI is limited by the degree of calcification of the access vessels and the aorta and aortic root. In contrast, transapical TAVI can be safely performed in almost every patient as long as the apex is not diseased. The minimally invasive procedure can be performed through a very small lateral thoracotomy thereby further reducing the surgical trauma. Currently, only the Edwards Sapien prosthesis is approved for transapical TAVI.

For the very first series of transapical Edwards Sapien™ implantations, Webb *et al.* [13] and Walther *et al.* [14] reported 30-day mortality rates of 18.2 and 13.6%. Mortality decreased as a function of the learning curve and recently Walther *et al.* [14] could show a mortality rate of 9% for transapical TAVI. The SOURCE Registry representing the largest and most reliable data collection for TAVI using the Edwards Sapien™ valve reports a 30-day mortality of 6.3% for the transfemoral and 10.3% for the transapical group [15]. Differences in mortality were not related to the access site itself but to the differences in periprocedural risk; patients in the transapical group had a significantly higher logistic EuroSCORE and suffered from more comorbidities. More recently, results of the PARTNER (Placement of AoRTic TraNscatheter Valve) trial cohort A, a randomized comparison of TAVI and surgical AVR, showed a surprisingly low overall 30 days mortality rate of 3.4% for TAVI patients in the intention to treat analysis. However, the patients included in this trial were highly selected and 30-day mortality in the treated patient population turned out to be 3.7% for the transfemoral group and 8.7% for the transapical group [16]. Differences in mortality between both approaches reflected the elevated preprocedural risk and a high number of comorbidities in the transapical group.

Compared with these results a 30 days mortality of 7.6% in patients treated transapically with the JenaValve™ system is favourably low and reflects the safety of the system. Although participating centres had large experience with transapical TAVI, there was still a learning curve for use of the new system. This did not relate to an increase in procedural risk but to a reduced procedural success rate of 89.6%. Furthermore, the delivery catheter was modified to improve delivery catheter handling.

Paravalvular leakage remains a concern after TAVI with unknown long-term consequences. Significant AR occurs frequently after TAVI and is associated with increased in-hospital mortality. Although AR is only mild in the majority of patients significant AR $\geq 2+$ can be found in 17–25% of patients [17–19]. In contrast to currently available valve types, the JenaValve™ prosthesis is able to achieve anatomically correct position by actively attaching to the native leaflets of the valve between the feelers that are placed in the aortic sinuses and the valve stent. This clip mechanism allows for a low stent profile and reduces the amount of paravalvular leakage. In our series, the majority of patients (86.4%) showed no or only mild paravalvular regurgitation ($\leq 1+$) while no patient developed significant post-procedural AR ($> 2+$). In addition, the active fixation of the valve on the native leaflets prevents mitral valve impairment. Despite the low stent profile, the valve developed enough radial force to effectively reduce transvalvular gradients from 40.6 ± 15.9 to 10.0 ± 7.2 mmHg and to increase EOA from 0.7 ± 0.2 to 1.7 ± 0.6 cm².

Porcine root valves as used in the JenaValve™ prosthesis have been used for >30 years and have proven good long-term durability after surgical valve replacement [20–22]. The same durability is reported for bovine pericardium as used in the Edwards Sapien™ prosthesis; nevertheless, the heavy forces during valve crimping are known to leave structural damages in the connective tissue of the leaflets [23]. It is as yet unknown if this will negatively influence long-term functionality. Loading of the JenaValve™ prosthesis on the delivery catheter reduces leaflet tissue stress since the valve is only folded into a housing of 32Fr diameter.

While rapid pacing is essential for deployment of balloon-expanded valves, there is no need for this step when implanting a JenaValve™ prosthesis. In the presence of coronary artery disease (CAD) and/or reduced ventricular function rapid pacing may lead to ventricular fibrillation or acute cardiac decompensation. Although 54% of the patients suffered from CAD, none of these events happened during deployment of the JenaValve™ prosthesis. The use of nitinol stents seems to be related to elevated rates of postprocedural AV blocks since pacemaker implantation rates using the Medtronic CoreValve™ are reported to be as high as 30% [24]. Due to the low stent profile and leaflet clip mechanism, the nitinol stent of the JenaValve™ does not reach the left ventricular outflow tract and reduces radial forces in the annulus. In this study, 8 of 66 patients (12.1%) underwent postprocedural pacemaker implantation due to conduction disorders, while new onset of conduction disorders was only detected in 6 of 66 patients (9.1%), a rate that compares favourably to the Medtronic CoreValve™ which also uses a self-expanding nitinol stent. The distinct features of the JenaValve™ device require manipulation within the aortic root and ascending aorta and may pose a risk for stroke by plaque release. Fortunately, the stroke rate detected in the study was only 3% and did not differ from stroke rates reported for transapical Edwards Sapien™ implantations (2.6%) [14]. Despite some degree of manipulation in the ascending aorta, the atraumatic design of the delivery catheter prevented calcium release from the vessel wall. Antegrade transapical delivery plays an additional role in low stroke rates since retrograde passage of the aortic arch and ascending aorta is avoided. Nevertheless, larger patient numbers are needed to finally assess the neurological risk of the procedure.

Due to limited patient numbers, the urgent question, ‘in which patients should the JenaValve™ be favoured over the Edwards Sapien™ valve or *vice versa*?’ cannot be answered today. The low stent profile might be an advantage for the JenaValve™ system in patients with small annuli. In addition, the anatomically correct position in combination with the clip fixation of the native leaflets reduces the risk for coronary obstruction. Therefore, patients with small distances between the annulus and coronary ostia might be better treated with the JenaValve™ device. In contrast patients with extremely calcified valves or very inhomogeneous calcification patterns will most likely benefit more from a balloon expandable rather than self-expandable device. Only with growing experience, will we be able to finally figure out the differences in indications for each valve type.

In conclusion, transapical transcatheter implantation using the second-generation JenaValve™ prosthesis was safe and effective in this multicentre pivotal trial. The valve offers the advantage of anatomically correct feeler-guided positioning by active fixation of the natural valve leaflets thereby reducing the rate of paravalvular leakage. No rapid pacing is required during valve

deployment, assuring stable hemodynamic flow during valve implantation. Thirty-day results were promising, with low mortality and event rates. Longer follow-up is needed to evaluate potential benefits in terms of durability and valve performance. The JenaValve™ device offers a new treatment option for transapical TAVI for patients with severe AS and high surgical risk.

Funding

The study was funded by JenaValve Technology GmbH.

Conflict of interest: H.-R.F. is a shareholder of JenaValve Technology GmbH. All other authors report no conflict of interest.

REFERENCES

- [1] Rodés-Cabau J, Webb JG, Cheung A, Ye J, Dumont E, Feindel CM *et al.* Transcatheter aortic valve implantation for the treatment of severe symptomatic aortic stenosis in patients at very high or prohibitive surgical risk: acute and late outcomes of the multicenter Canadian experience. *J Am Coll Cardiol* 2010;55:1091–2.
- [2] Thomas M, Schymik G, Walther T, Himbert D, Lefevre T, Treede H *et al.* Thirty-Day Results of the SAPIEN Aortic Bioprosthesis European Outcome (SOURCE) Registry. A European Registry of Transcatheter Aortic Valve Implantation Using the Edwards SAPIEN Valve. *Circulation* 2010;122:62–9.
- [3] Ye J, Cheung A, Lichtenstein SV, Nietispach F, Albugami S, Masson JB *et al.* Transapical transcatheter aortic valve implantation: follow-up to 3 years. *J Thorac Cardiovasc Surg.* 2010;139:1107–13.
- [4] Zahn R, Gerckens U, Grube E, Linke A, Sievert H, Eggebrecht H *et al.* German Transcatheter Aortic Valve Interventions-Registry Investigators. *Eur Heart J* 2011;32:198–204.
- [5] Wendler O, Walther T, Schroefel H, Lange R, Treede H, Fusari M *et al.* The SOURCE Registry: what is the learning curve in trans-apical aortic valve implantation? *Eur J Cardiothorac Surg* 2011;39:853–9; discussion 859–60.
- [6] Lauten A, Ferrari M, Petri A, Ensminger SM, Gummert JF, Boudjemline Y *et al.* Experimental Evaluation of the JenaClip Transcatheter Aortic Valve. *Cath Cardiovasc Interv* 2009;74:514–9.
- [7] Kempfert J, Rastan AJ, Mohr FW, Walther T. A new self-expanding transcatheter aortic valve for transapical implantation - first in man implantation of the JenaValve™. *Eur J Cardiothorac Surg* 2011;40:761–3.
- [8] Nashef SA, Roques F, Michel P, Gauducheau E, Lemeshow S, Salamon R. European system for cardiac operative risk evaluation (EuroSCORE). *Eur J Cardiothorac Surg* 1999;16:9–13.
- [9] Leon MB, Smith CR, Mack M, Miller DC, Moses JW, Svensson LG *et al.* PARTNER Trial Investigators. Transcatheter aortic-valve implantation for aortic stenosis in patients who cannot undergo surgery. *N Engl J Med* 2010;363:1597–607.
- [10] Iung B, Baron G, Butchart EG, Delahaye F, Gohlke-Bärwolf C, Levang OW *et al.* A prospective survey of patients with valvular heart disease in Europe: the Euro Heart Survey on valvular heart disease. *Eur Heart J* 2003;24:1231–43.
- [11] Berry C, Asgar A, Lamarche Y, Marcheix B, Couture P, Basmadjian A *et al.* Novel therapeutic aspects of percutaneous aortic valve replacement with the 21F CoreValve Revalving System. *Catheter Cardiovasc Interv* 2007;70:610–6.
- [12] Walther T, Dewey T, Borger MA, Kempfert J, Linke A, Becht R *et al.* Transapical aortic valve implantation: step by step. *Ann Thorac Surg* 2009;87:276–83.
- [13] Webb JG, Altwegg L, Boone RH, Cheung A, Ye J, Lichtenstein S *et al.* Transcatheter aortic valve implantation. Impact on clinical and valve-related outcomes. *Circulation* 2009;119:3009–16.
- [14] Walther T, Kempfert J, Rastan A, Borger MA, Linke A, Ender J *et al.* Transapical aortic valve implantation at 3 years. *J Thorac Cardiovasc Surg* 2012;143:326–31.
- [15] Thomas M, Schymik G, Walther T, Himbert D, Lefevre T, Treede H *et al.* Thirty-day results of the SAPIEN aortic Bioprosthesis European Outcome

- (SOURCE) Registry: A European registry of transcatheter aortic valve implantation using the Edwards SAPIEN valve. *Circulation* 2010;122:62–9.
- [16] Smith CR, Leon MB, Mack MJ, Miller DC, Moses JW, Svensson LG *et al.* PARTNER Trial Investigators. Transcatheter versus surgical aortic-valve replacement in high-risk patients. *N Engl J Med* 2011;364:2187–98.
- [17] Abdel-Wahab M, Zahn R, Horack M, Gerckens U, Schuler G, Sievert H *et al.* German transcatheter aortic valve interventions registry investigators. Aortic regurgitation after transcatheter aortic valve implantation: incidence and early outcome. Results from the German transcatheter aortic valve interventions registry. *Heart* 2011;97:899–906.
- [18] Rajani R, Kakad M, Khawaja MZ, Lee L, James R, Saha M *et al.* Paravalvular regurgitation one year after transcatheter aortic valve implantation. *Catheter Cardiovasc Interv* 2010;75:868–72.
- [19] Bauer F, Lemerrier M, Zajarias A, Tron C, Eltchaninoff H, Cribier A. Immediate and long-term echocardiographic findings after transcatheter aortic valve implantation for the treatment of aortic stenosis: the Cribier-Edwards/Edwards-Sapien valve experience. *J Am Soc Echocardiogr* 2010;23:370–6.
- [20] Valfrè C, Ius P, Minniti G, Salvador L, Bottio T, Cesari F *et al.* The fate of Hancock II porcine valve recipients 25 years after implant. *Eur J Cardiothorac Surg* 2010;38:141–6.
- [21] Mykén PS, Bech-Hansen O. A 20-year experience of 1712 patients with the Biocor porcine bioprosthesis. *J Thorac Cardiovasc Surg* 2009;137:76–81.
- [22] Jamieson WR, Burr LH, Miyagishima RT, Germann E, Macnab JS, Stanford E *et al.* Carpentier-Edwards supra-annular aortic porcine bioprosthesis: clinical performance over 20 years. *J Thorac Cardiovasc Surg* 2005;130:994–1000.
- [23] Kiefer P, Gruenwald F, Kempfert J, Aupperle H, Seeburger J, Mohr FW *et al.* Crimping may affect the durability of transcatheter valves: an experimental analysis. *Ann Thorac Surg* 2011;92:155–60.
- [24] Bates MG, Matthews IG, Fazal IA, Turley AJ. Postoperative permanent pacemaker implantation in patients undergoing trans-catheter aortic valve implantation: what is the incidence and are there any predicting factors? *Interact Cardiovasc Thorac Surg* 2011;12:243–53.

APPENDIX. CONFERENCE DISCUSSION

Dr N.M. Van Mieghem (Rotterdam, The Netherlands): It is a very interesting concept, of course, with the feelers, and you get the tactile feedback, but it is a sheathless 32Fr system, so it looks horrendous to me as an interventional cardiologist. But I wonder, if you advance a sheath like that in the apex, what about myocardial necrosis? And, as you know, there was a paper by Rodés-Cabau in JACC earlier this year where there was myocardial necrosis in all the cases, and in our centre also we see cardiac enzymes in all our cases.

So I am wondering with this big device whether you have more myocardial necrosis and, if so, did you compare it to the Edwards system and would you have less myocardial necrosis with the Edwards system? And having said all that, in your opinion, is the system as it is right now a viable alternative to the Edwards system for transapical, and if so, when would you prefer it?

Dr Treede: A very good question, actually. The transapical approach I think is very safe and it is not dependent on the size of the sheath or the valve delivery system that you put in there. I am totally convinced that it does not make a difference for the apex if you put in an 18 Fr sheath or a 32Fr sheath, because you just dilate your puncture site and then you reclose it. So I am convinced that this doesn't make a difference. Of course, there is always necrosis when you cut in a heart or when you put a sheath in a heart, so we always measure some enzyme elevations. The question is whether this has any clinical impact on the patients. I know there is a paper out from the Munich group that has shown that there might be some patients that develop

myocardial infarction-like events. But I think personally that much relates to the area where you place your purse string sutures. In my opinion, you have to go strongly towards the apex and not too high up on the ventricle. The higher you get on the ventricle, the higher is the risk for such an event.

Regarding the second question, after 67 patients implanted, it is too early to really decide if this is a completely viable approach. I think it is, actually, I like the approach very much, because I think that we can overcome some of the difficulties that we have with the current devices. One difficulty, for example, is paravalvular leakage; we had a talk on this before. I think that nitinol-based devices that are fitted in a valve completely anatomically correct can overcome this a little bit at least. What I really like with this valve design is its low profile. The stent is not going into the left ventricular outflow tract. Even though in this study, with small patient numbers, we had a pacemaker rate of 9%, I think that we will see fewer pacemakers for these kind of devices in the future, we see less paravalvular leakage, and we can implant it without rapid pacing.

I just learned from the last presentation by Christoph Huber that rapid pacing now has a different perspective because it may probably prevent cerebral emboli, but I see more patients suffering from badly influenced haemodynamics due to rapid pacing than I have seen patients that have shown up with a stroke after the procedure. So I still think it is better to avoid rapid pacing during these procedures.

Dr S. Salizzoni (Torino, Italy): I am curious to know the outcomes of the four patients that underwent standard aortic valve replacement. Then, what were the technical problems you had with the patients you converted from Jena valve in inter-TAVI, which TAVI you performed (transapical or transfemoral), and which prosthesis did you use?

Dr Treede: Regarding your first question, these patients survived the procedure. The problem with the first generation of the delivery system was that we sometimes had difficulty in releasing the housing of the valve from the valve stent, and by pulling back the housing toward the ventricle, we displaced the stent. So this was sort of the main reason for the reoperations.

The patient with the TAVI-TAVI was at our own centre. This was a valve that was, due to the same mechanism, placed too high, and we then implanted a transapical Sapien that was able to fix the lowest end part onto the leaflet. So the patient now has two functioning valves. It is, of course, not a nice result, but finally everything went well and he is still doing fine. But this is, of course, something we don't like to see. There is no question about that.

Dr C. Huber (Bern, Switzerland): One short question. From our surgical experience with stenotic aortic valves, it looks like many of those valves have fusion of the commissures with a high degree of calcification. There is no really nice anatomical structure with the sinuses and the cusps bulging and so on. So do you think those three feelers can really find those locations you talk about? And another question: What would you say would be the best anatomical consideration, or what would be the worst anatomical consideration, in the decision to implant this kind of device instead of an Edwards device, as we are dealing on one side with cylindrical structures and now we have a triangular structure to implant somehow?

Dr Treede: A very good question, Christoph. That was one of my first concerns before we started the study, also, that probably heavily calcified valves are not good valve types for such a device, and finally we found out that this is not the case. There is a contraindication for this type of valve, which is a bicuspid valve, but this is, of course, a contraindication for other valve types, too. And there is no contraindication with regards to the degree of calcification or with the way the calcium is distributed over the valve. So it is still possible even in highly calcified valves. You might need some more post-dilatations in those patients; in this study we had a 40% post-dilatation rate. But we treated every patient that came, regardless of the degree of calcification, unless it was a bicuspid.