

Transcatheter mitral valve repair with the MitraClip® can be performed without general anesthesia and without conscious sedation

Jakob Ledwoch¹ · Predrag Matic¹ · Jennifer Franke¹ · Sameer Gafoor¹ · Stefan Bertog¹ · Markus Reinartz¹ · Laura Vaskelyte¹ · Ilona Hofmann¹ · Horst Sievert¹

Received: 9 July 2015 / Accepted: 9 September 2015 / Published online: 16 September 2015
© Springer-Verlag Berlin Heidelberg 2015

Abstract

Background General anesthesia is known to be associated with an increased risk for complications, especially in elderly and multi-morbid patients, the primary target population of the MitraClip® technique. The aim is to assess whether general anesthesia and even conscious sedation can be avoided during the MitraClip® procedure.

Methods A total of 91 consecutive patients who underwent MitraClip® implantation [median 77 years, (IQR 72–83), 40 % female] were retrospectively analyzed. The first 26 patients were treated in general anesthesia. Afterwards, local anesthesia was chosen as primary anesthetic approach. Altogether, 28 (31 %) patients received general anesthesia, local anesthesia was performed in 35 (38 %) patients with sedation and in 28 (31 %) patients without sedation.

Results The respective patient groups were similar regarding their baseline characteristics. Procedural success (successful implantation of at least one clip and post-procedure MR grade ≤ 2) was achieved in 89 % with no difference between the groups (93 % in general anesthesia, 89 % in local anesthesia with sedation, 86 % in local anesthesia without sedation, $p = ns$). No difference regarding hospital complications was noted. Local anesthesia with and without sedation was associated with less necessity for ICU/IMC stay (100 % in general anesthesia, 14 % in local anesthesia with sedation, 14 % in local

anesthesia without sedation; $p < 0.0001$). One-year estimated survival was not significantly different among the groups (63, 82 and 75 %; $p = ns$).

Conclusions Transcatheter mitral valve repair with the MitraClip® can be performed without general anesthesia and even without conscious sedation with similar procedural success and complication rates.

Keywords Mitral regurgitation · Transcatheter mitral valve repair · MitraClip · Anesthesia

Abbreviations

| | |
|------|---|
| GA | General anesthesia |
| ICU | Intensive care unit |
| IMC | Intermediate care |
| LA | Local anesthesia |
| MR | Mitral regurgitation |
| STS | Society of Thoracic Surgeons |
| TAVI | Transcatheter aortic valve implantation |
| TEE | Transesophageal echocardiography |
| TTE | Transthoracic echocardiography |
| VARC | Valve Academic Research Consortium |

Introduction

Catheter-based mitral valve repair with the MitraClip® (Abbott, Abbott Park, IL, USA) has emerged as a widespread alternative to open-heart surgery for the treatment of mitral valve regurgitation (MR). Particularly, those patients with high operative risk may benefit from this technique due to its less invasiveness [1, 2]. The majority of MitraClip® procedures has been performed in general

✉ Horst Sievert
info@cvcfrankfurt.de

Jakob Ledwoch
jakobledwoch@yahoo.de

¹ CardioVascular Center CVC, Sankt Katharinen Hospital, Seckbacher Landstraße 65, 60389 Frankfurt, Germany

anesthesia [3]. The motivation for this approach is mainly safety issues and the use of transesophageal echo (TEE). However, there is no clear evidence supporting this regime. General anesthesia itself may result in increased post-procedural morbidity, particularly in elderly and multi-morbid patients [4].

Experience from transcatheter aortic valve implantation (TAVI) has shown that after an initial phase of performing procedures solely under general anesthesia, interventions were increasingly performed in local anesthesia [5, 6]. Avoidance of general anesthesia may contribute to simplification of the procedure, timely detection of peri-procedural complications, avoidance of general anesthesia-associated complications, lower procedural costs and reduced staff resources.

So far, only two single-center reports accessing the use of local anesthesia with sedation for the MitraClip[®] procedure in a small number of patients (altogether 11 patients) are known in the current literature [7, 8]. This analysis is the first investigating the feasibility and safety of local anesthesia for MitraClip[®] implantation in a larger series. In addition, the present work will analyze if conscious sedation can be avoided in patients treated under local anesthesia.

Methods

Population

We retrospectively included all patients with significant MR who were consecutively treated with the MitraClip[®] system in our institution between October 2009 and December 2014. Baseline and procedure characteristics were retrospectively assessed with use of medical records and procedure protocols. The study was performed according to the Declaration of Helsinki. All patients gave written informed consent for the procedure and for the collection and processing of their anonymous data.

Pre-procedure assessment

Patients underwent echocardiographic assessment (transthoracic and transesophageal) for evaluation of the severity and etiology of MR, ventricular function and dimensions for conformation of suitability for the MitraClip[®] procedure. After changing our anesthetic regime (avoidance of general anesthesia), we specifically evaluated the tolerability of TEE in all patients during the screening process. Patients, who did not tolerate the TEE probe easily, were excluded from the new anesthetic approach.

Procedure and follow-up

Fluoroscopy and TEE were used for guidance during the implantation. After introduction of the device via the femoral vein and transseptal puncture, the MitraClip[®] was advanced over a guide catheter through the left atrium into the left ventricle. The clip was then fixed to both mitral leaflets. Procedural details have been described in detail previously [9].

After implantation TEE and transthoracic echocardiography (TTE) were used to assess the post-procedural MR grade. The need and duration for ICU/IMC stay, total length of hospital stay and all in-hospital complications were recorded. Procedure time was defined as time from femoral vein puncture until closure of the femoral access. Bleeding was defined according to the Valve Academic Research Consortium (VARC) criteria [10].

Follow-up was performed routinely 1 year following implantation. If patients were not available for clinical follow-up they were contacted by telephone. Outcome analysis included survival and need for rehospitalisation up to 12 months.

Anesthesia method

The first 26 procedures were performed with the use of general anesthesia from October 2009 until January 2011. After this initial phase, we changed our anesthetic protocol to local anesthesia with conscious sedation as primary approach. As local anesthesia with sedation seemed to be feasible in the first five patients treated at our center from January 2011 until February 2011 [11], sedative drugs were omitted for the MitraClip[®] procedure whenever possible thereafter. Consequently, three different anesthesia regimes are compared in the present work: General anesthesia, local anesthesia with sedation and local anesthesia without any sedation. After the change to local anesthesia as primary approach, two patients had to be performed primarily in general anesthesia due to poor tolerance of the TEE probe during the pre-procedure screening.

In all patients, topical anesthesia with lidocaine spray of the pharynx was performed. In case of a supplemental need for sedatives, midazolam and propofol were given mostly with a starting dose of 2 mg and 20 mg, respectively, to enable swallowing of the TEE probe. If patients further needed sedatives to tolerate TEE over the course of the procedure, boluses of 2 mg midazolam and 20 mg propofol were administered thereafter to achieve a sedation of –1 to –2 according to the Richmond Agitation Sedation Scale [12]. If analgesia or tranquilizer were required in patients treated in local anesthesia without sedation morphine or tramadol were used. For local anesthesia, 10 ml of

xylocaine 0.5 % was used until 2013 and 10 ml of scandicaine 1 % thereafter.

All procedures were performed with endotracheal intubation standby and an anesthesia team on site in case of conversion to general anesthesia. The anesthesia team was not in the catheter laboratory but they were called in together with their technical equipment if needed. Due to the logistics in our institution, only few minutes are needed until their arrival in the catheter laboratory. In patients treated without general anesthesia, peri-procedural monitoring consisted of automatic peripheral blood pressure measurement every 10 min, continuous oxygen saturation measurement by pulse oximetry and continuous ECG. In addition, pressure measurement of the right heart and pulmonary artery was performed prior to transseptal puncture.

Patients who were treated in general anesthesia were monitored in the ICU/IMC after the procedure. Patients treated in local anesthesia with or without sedation were transferred directly to the general ward.

The three groups were compared regarding baseline characteristics, procedural success (defined as implantation of at least one clip and post-procedure MR grade ≤ 2), local anesthesia failure (defined as intra-procedural conversion to general anesthesia), hospital complications and mid-term mortality. Key parameters for the evaluation of local anesthesia performance were procedural success, local anesthesia failure and in-hospital complications.

Statistical analysis

In the case of an intra-procedural conversion of local anesthesia to general anesthesia, patients were analyzed in the local anesthesia group on an intention to treat basis. The Shapiro–Wilk test was performed to differentiate normal from non-normal distribution of the data. The Chi-Square test was used for categorical variables and the Kruskal–Wallis or ANOVA test was performed for continuous variables. For comparison of mortality during the follow-up, Kaplan–Meier curves using the log-rank test were set up. All p values were calculated by two-tailed tests and statistical significance was defined at $p < 0.05$. Analysis was performed by SPSS software, version 22 (SPSS, Chicago, IL, USA).

Results

Baseline characteristics

Altogether, 91 consecutive patients were enrolled. Median age was 77 (72–83) years and 40 % (36/91) were female. Previous stroke and pulmonary hypertension were significantly more often present in the group of local anesthesia

without sedation compared to local anesthesia with sedation and general anesthesia (Table 1). Detailed baseline characteristics are presented in Table 1. All patients had a pre-procedure MR grade III or IV with degenerative etiology of MR in 61 % of patients treated in general anesthesia, 37 % of patients treated in local anesthesia with sedation and 29 % of patients treated in local anesthesia without sedation ($p = 0.04$). Further echocardiographic measurements are displayed in Table 2.

Feasibility of anesthesia

After conversion to the new anesthetic method in all but two patients, the procedure was initialized in local anesthesia (Fig. 1). These two patients were treated under general anesthesia because of discomfort during the pre-procedural TEE. In three patients (5 %) local anesthesia failed (one case in local anesthesia with sedation and two cases in local anesthesia without sedation): One patient treated in local anesthesia with sedation experienced severe hemodynamic compromise of unclear etiology after introduction of the MitraClip[®] into the left atrium with the need for intubation and application of inotropes. Another patient who underwent the procedure in local anesthesia without sedation required intubation and mechanical ventilation because of peri-procedural pulmonary edema without any sequelae. In both of these patients, the clip implantation was successful. A third patient treated in local anesthesia without sedation had to be converted to surgery due to left atrial perforation and this patient had to be anesthetized for open-heart operation.

Patients who required sedative drugs received a median dose of midazolam of 10 mg (8–15 mg) and a median dose of propofol of 150 mg (105–225 mg), respectively. Of the 28 patients who were treated in local anesthesia without sedation, 8 patients (29 %) required opiates (morphine and/or tramadol). Re-injection of local anesthesia was necessary very rarely.

Procedural outcome

The device was successfully implanted in 89 % of the cases (81/91) without significant difference between the groups (93 % in general anesthesia, 89 % in local anesthesia with sedation and 86 % in local anesthesia without sedation; $p = \text{ns}$). MR reduction was similar between the three groups (Table 3).

In four cases the MitraClip[®] was not implanted. Two of the four procedures had to be terminated and converted to open-heart surgery (surgery was successful in both cases). The reasons for termination were a significant atrial septal defect following transseptal puncture in one patient who was treated in general anesthesia and a left atrial perforation due

Table 1 Baseline characteristics

| | All patients (N = 91) | General anesthesia (N = 28) | Local anesthesia with sedation (N = 35) | Local anesthesia without sedation (N = 28) | P value |
|-----------------------------------|--------------------------|--------------------------------|--|---|---------|
| Age (years) | 77 (72–83) | 74 (67–80) | 78 (74–83) | 78 (73–85) | ns |
| Female | 40 % (36/91) | 39 % (11/28) | 40 % (14/35) | 39 % (11/28) | ns |
| STS score (%) | 5.1 (3.2–8.7) | 3.9 (1.5–6.9) | 6.7 (3.6–9.7) | 7.5 (4.2–10.3) | ns |
| NYHA \geq III | 84 % (76/91) | 79 % (22/28) | 91 % (31/35) | 79 % (22/28) | ns |
| Coronary artery disease | 60 % (55/91) | 61 % (17/28) | 63 % (22/35) | 58 % (16/28) | ns |
| Previous myocardial infarction | 34 % (31/91) | 43 % (12/28) | 37 % (13/35) | 21 % (6/28) | ns |
| Previous PCI | 33 % (30/91) | 32 % (9/28) | 31 % (11/35) | 36 % (10/28) | ns |
| Previous CABG | 31 % (28/91) | 25 % (7/28) | 37 % (13/35) | 29 % (8/28) | ns |
| Previous cardiac surgery | 35 % (32/91) | 25 % (7/28) | 49 % (17/35) | 29 % (8/28) | ns |
| Atrial fibrillation | 50 % (45/91) | 46 % (13/28) | 46 % (16/35) | 57 % (16/28) | ns |
| Diabetes mellitus | 29 % (26/91) | 36 % (10/28) | 17 % (16/35) | 36 % (10/28) | ns |
| Insulin-dependent | 18 % (16/91) | 32 % (9/28) | 11 % (4/35) | 11 % (3/28) | ns |
| PAOD | 23 % (21/91) | 18 % (5/28) | 26 % (9/35) | 25 % (7/28) | ns |
| Stroke | 7 % (6/91) | 0 % (0/28) | 3 % (1/35) | 18 % (5/28) | 0.014 |
| COPD | 25 % (23/91) | 21 % (6/28) | 26 % (9/35) | 29 % (8/28) | ns |
| Pulmonary hypertension | 59 % (51/87) | 41 % (11/27) | 59 % (19/32) | 75 % (21/28) | 0.036 |
| Chronic renal failure | 68 % (58/87) | 70 % (19/27) | 70 % (23/33) | 60 % (16/27) | ns |
| GFR (ml/min/1.73 m ²) | 51 (40–61) | 56 (44–61) | 51 (40–60) | 55 (46–62) | ns |

CABG coronary artery bypass graft, COPD chronic obstructive pulmonary disease, GFR glomerular filtration rate, NYHA New York Heart Association, PAOD peripheral arterial occlusive disease, PCI percutaneous coronary intervention, STS Society of Thoracic Surgeons

Table 2 Baseline echocardiographic specifics

| | All patients (N = 91) | General anesthesia (N = 28) | Local anesthesia with sedation (N = 35) | Local anesthesia without sedation (N = 28) | P value |
|-----------------------|--------------------------|--------------------------------|--|---|---------|
| MR severity | | | | | |
| III | 57 % (52/91) | 54 % (15/28) | 66 % (23/35) | 50 % (14/28) | ns |
| IV | 43 % (39/91) | 46 % (13/28) | 34 % (12/35) | 50 % (14/28) | ns |
| MR etiology | | | | | |
| Degenerative | 42 % (38/91) | 61 % (17/28) | 37 % (13/35) | 29 % (8/28) | 0.04 |
| Functional | 42 % (38/91) | 32 % (9/28) | 43 % (15/35) | 50 % (14/28) | ns |
| Combined | 16 % (15/91) | 7 % (2/28) | 20 % (7/35) | 21 % (6/28) | ns |
| Ejection fraction (%) | 52 \pm 17 | 51 \pm 18 | 56 \pm 16 | 50 \pm 17 | ns |

MR mitral regurgitation

to entanglement of the clip within the atrial septum in another patient which required conversion to general anesthesia as mentioned above. In two other patients, the device was not implanted due to a significant mitral stenosis in the first patient and no relevant decrease in MR despite multiple repositioning maneuvers of the MitraClip[®] system in the second patient. Beyond that, one patient who underwent the procedure in local anesthesia with sedation experienced a rupture of chordae during the placement of a second clip. This patient was hemodynamically stabilized in the ICU and transferred to surgery. Finally, five patients had a residual MR \geq 3 after clip implantation.

Patients treated in local anesthesia received more often more than one clip (Table 3). The duration of the procedure was significantly longer when performed under local anesthesia irrespective of the use of sedation compared to general anesthesia (Table 3). Length of hospitalization was shorter in patients treated in local anesthesia with sedation (median 6 days, IQR 3–7 days) in comparison to general anesthesia (median 7 days, IQR 6–11 days; $p = 0.003$) and local anesthesia without sedation (median 7 days, IQR 6–10 days; $p = 0.012$). The rate of ICU/IMC necessity after the procedure was higher when general anesthesia was used (Fig. 2).

Fig. 1 Progress of different anesthesia approaches. The first 26 patients were treated in general anesthesia. After a “run-in” phase of five patients who were treated in local anesthesia with sedation local anesthesia without sedation became the primary approach. Of 60 patients in this phase, 2 patients were treated in general anesthesia, 30 patients received sedatives (local anesthesia with sedation) and 28 patients were treated in local anesthesia only

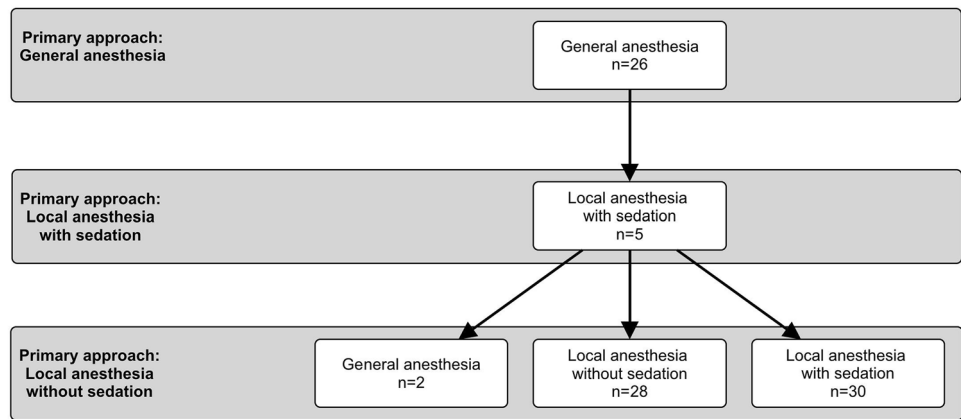


Table 3 Procedural outcome

| | All patients (N = 91) | General anesthesia (N = 28) | Local anesthesia with sedation (N = 35) | Local anesthesia without sedation (N = 28) | P value |
|----------------------------|--------------------------|--------------------------------|--|---|---------|
| Procedural success | 89 % (81/91) | 93 % (26/28) | 89 % (31/35) | 86 % (24/28) | ns |
| Post-implant MR severity | | | | | |
| 0/I | 46 % (42/91) | 46 % (13/28) | 49 % (17/35) | 43 % (12/28) | ns |
| II | 43 % (39/91) | 46 % (13/28) | 40 % (14/35) | 43 % (12/28) | ns |
| III | 9 % (8/91) | 4 % (1/28) | 9 % (3/35) | 14 % (4/28) | ns |
| IV | 2 % (2/91) | 4 % (1/28) | 3 % (1/35) | 0 % (0/28) | ns |
| ≤II | 89 % (81/91) | 93 % (26/28) | 89 % (31/35) | 86 % (24/28) | ns |
| Implantation of ≥2 Clips | 40 % (34/86) | 27 % (7/26) | 32 % (11/34) | 62 % (16/26) | 0.021 |
| Procedure time (min) | 135 (101–190) | 107 (91–162) | 143 (115–190) | 155 (108–202) | 0.013 |
| Fluoroscopy duration (min) | 20 (15–34) | 18 (16–28) | 18 (14–34) | 27 (19–42) | ns |

MR mitral regurgitation

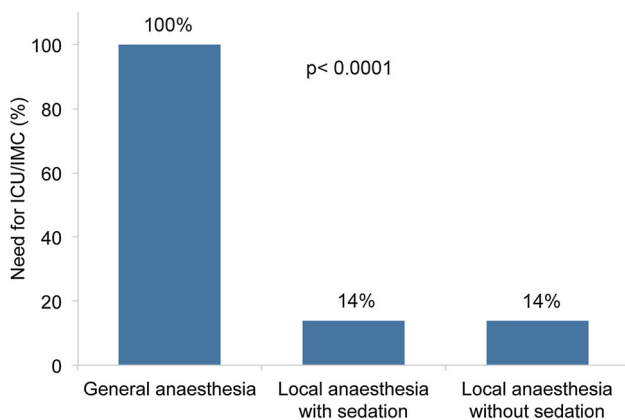


Fig. 2 Influence of anesthesia on ICU/IMC necessity. Local anesthesia with and without sedation is associated with less need for ICU/IMC

In-hospital complications

The rate of in-hospital complications was similar between the groups [32 % (9/28) in general anesthesia, 26 % (9/35)

in local anesthesia with sedation and 21 % (6/28) in local anesthesia without sedation; $p = ns$] (Table 4).

Left atrial perforation occurred in one patient who was then converted to open-heart surgery as mentioned previously. Bleeding complications occurred in 11 patients. Reasons for minor bleeding were injury of the urethra after urinary catheter placement and groin bleeding in three cases. Reasons for major bleeding were injury of the urethra after urinary catheter placement, groin bleeding, gastrointestinal bleeding due to disseminated intravascular coagulation, peri-procedural nasopharyngeal bleeding of unknown cause and hematemesis and epistaxis after intravenous thrombolysis. Reasons for life-threatening bleeding were peri-procedural hemopericardium in two patients: One as a consequence of a left atrial perforation as already described, the other was of unknown cause and was treated by pericardiocentesis without sequelae.

Two peri-procedural strokes with hemiparesis occurred in patients who underwent the procedure in local anesthesia. In one patient, the stroke originated most probably from thrombus formation on the clip, which was detected directly prior to the neurological event. The activated

Table 4 In-hospital complications

| | All patients (<i>N</i> = 91) | General anesthesia (<i>N</i> = 28) | Local anesthesia with sedation (<i>N</i> = 35) | Local anesthesia without sedation (<i>N</i> = 28) | <i>P</i> value |
|-------------------------|----------------------------------|--|--|---|----------------|
| All complications | 26 % (24/91) | 32 % (9/28) | 26 % (9/35) | 21 % (6/28) | ns |
| Partial clip detachment | 2 % (2/91) | 4 % (1/28) | 0 % (0/35) | 4 % (1/28) | ns |
| New Arrhythmia | 4 % (4/91) | 7 % (2/28) | 3 % (1/35) | 4 % (1/28) | ns |
| Pneumonia | 2 % (2/91) | 4 % (1/28) | 0 % (0/35) | 4 % (1/28) | ns |
| Other infection | 7 % (6/91) | 11 % (3/28) | 3 % (1/35) | 7 % (2/28) | ns |
| Pleural effusion | 4 % (4/91) | 11 % (3/28) | 3 % (1/35) | 0 % (0/28) | ns |
| Pulmonary embolism | 1 % (1/91) | 4 % (1/28) | 0 % (0/35) | 0 % (0/28) | ns |
| Pneumothorax | 1 % (1/91) | 4 % (1/28) | 0 % (0/35) | 0 % (0/28) | ns |
| Post-procedure delirium | 1 % (1/91) | 4 % (1/28) | 0 % (0/35) | 0 % (0/28) | ns |
| Bleeding | 12 % (11/91) | 24 % (6/28) | 9 % (3/35) | 7 % (2/28) | ns |
| TIA/stroke | 2 % (2/91) | 0 % (0/28) | 3 % (1/35) | 4 % (1/28) | ns |
| Other complication | 8 % (7/91) | 7 % (2/28) | 6 % (2/35) | 11 % (3/28) | ns |
| Death | 6 % (5/91) | 7 % (2/28) | 6 % (2/35) | 4 % (1/28) | ns |

TIA transient ischemic attack

anticoagulation time was 291 s in this patient. Instantaneous thrombolysis with urokinase led to an immediate improvement of symptoms. In the other patient, complete occlusion of the left internal carotid artery was detected in angiography directly after symptom onset. Pre-procedurally, the left internal carotid artery had a 70 % stenosis. As crossing of the occlusion by a wire to perform an angioplasty failed, immediate lysis was administered and the symptoms resolved rapidly. On the next day, both patients had no neurological sequelae.

In one patient, after several repositioning maneuvers, the clip could not be closed or pulled back into the sheath. Therefore, this clip was positioned at the atrial septum and, subsequently, two other clips were successfully implanted in standard fashion. At the end of the procedure, the first clip was fixed to the atrial septum with an atrial septal defect occluder.

In-hospital mortality was 6 % (5/91). All deaths occurred post-procedurally and were not device-related. Cause of death were sepsis after pseudomembranous colitis, pneumonia, sepsis following bronchitis leading to fatal renal failure (renal function was severely impaired prior to the procedure and the patient and family refused dialysis post-procedurally), severe hemodynamic compromise of unclear etiology and pulmonary embolism, respectively.

Mid-term mortality and rehospitalization

Altogether, eight patients were lost to follow-up (9 %). The type of anesthesia was not associated with a statistically significant change in estimated one-year survival (Fig. 3). Rehospitalisation due to cardiovascular complications within 1 year following the procedure occurred in three

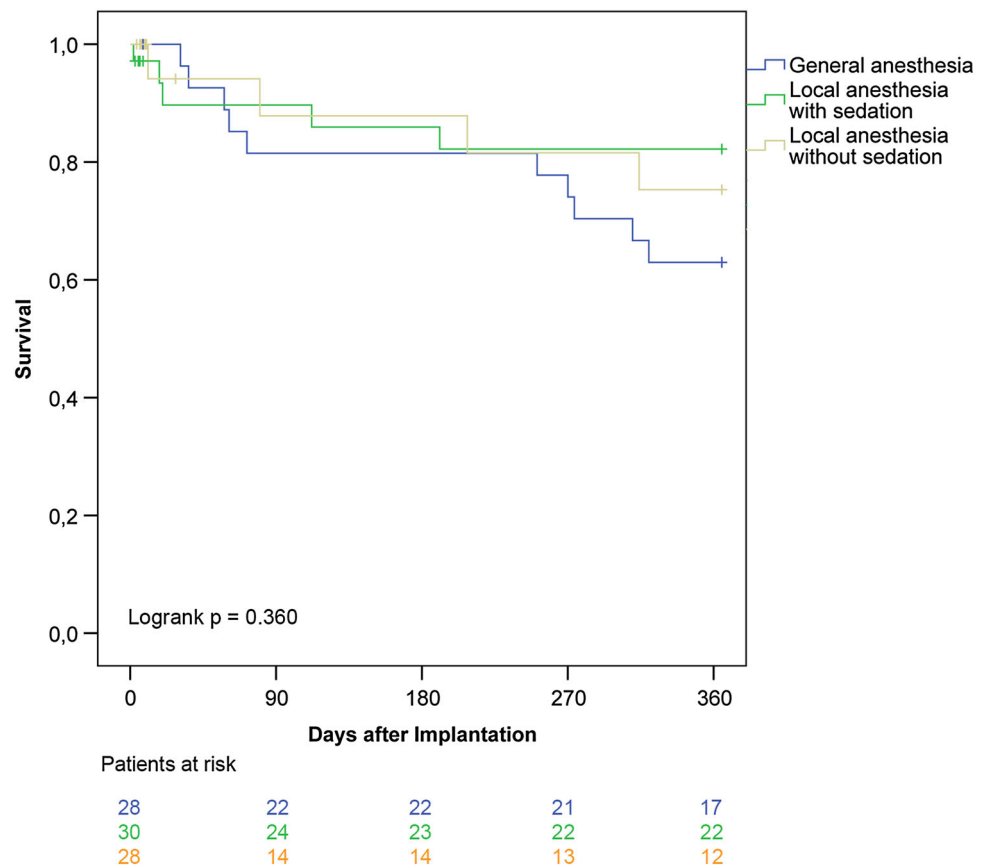
patients (all treated in local anesthesia). The causes were cardiac decompensation, ventricular fibrillation due to worsening of ejection fraction to 10 % (residual MR grade 1 remained unchanged in this patient, worsening of ejection fraction was most probably caused by progression of coronary heart disease) and partial clip detachment with increased MR and need for surgical repair.

Discussion

Transcatheter mitral valve repair with the MitraClip[®] provides a safe and effective alternative to surgery or medical therapy for mitral valve regurgitation in patients with high operative risk [13–16]. Usually, the procedure is performed in general anesthesia. Our report demonstrates proof of concept of MitraClip[®] implantation under local anesthesia. In fact, in many cases, the procedure can be performed without any sedative drugs. With this new approach, we are able to show the following in our series:

1. Performance of the MitraClip[®] technique in local anesthesia (with and without sedation) is as effective as in general anesthesia.
2. A large proportion of patients tolerates the procedure even without sedation.
3. Complication rates are similar between the anesthetic regimes.
4. Necessity for ICU/IMC is much lower in patients managed in local anesthesia (with and without sedation) in comparison to general anesthesia.
5. There is no significant difference in one-year mortality between the three groups.

Fig. 3 Kaplan–Meier survival curves of patients treated in general anesthesia, local anesthesia with sedation and without sedation. There is no significant difference in estimated 1-year survival



Implications of general anesthesia

The greatest advantage of the MitraClip[®] procedure is the possibility to treat elderly and multi-morbid patients with severe mitral regurgitation who are denied open-heart surgery. General anesthesia is currently the anesthetic regime of choice for the MitraClip[®] implantation. On the one hand, general anesthesia may facilitate the management of peri-procedural complications and the use of TEE. On the other hand, this approach itself carries a potential risk for complications, particularly in patients at advanced age, high morbidity or poor left ventricular function [4]—hence, those in whom the technique is preferably applied. The use of intensive sedatives during general anesthesia can induce hemodynamic instability, even leading to procedure termination [17]. In fact, in a report by Blazek et al., half of the patients developed hypotension episodes requiring inotropic support when using general anesthesia during the MitraClip[®] procedure. Hypotension was associated with decreased cognitive function post-procedurally owing to cerebral injury [18]. In the EVEREST II high-risk study, prolonged anesthesia contributed to procedural death in one patient [19]. Furthermore, laryngeal injury resulting from intubation is not uncommon [20, 21] and a laryngeal tear has already been reported in connection with the

MitraClip[®] procedure [19]. A further aspect is the increased staff effort for general anesthesia—at least one anaesthesiologist and one anesthesia nurse are required—leading to a comparably high financial and logistical burden. Looking exemplarily at the TAVI experience, avoidance of general anesthesia reduced catheter laboratory costs by 60 % [22]. Further cost savings may be achieved by avoidance of ICU/IMC stay after transcatheter procedures [23].

Feasibility of local anesthesia

The less invasive nature of the MitraClip[®] technique allows for performing the procedure without general anesthesia. The key issue of this current investigation was to analyze whether avoidance of general anesthesia and even sedation is practicable in a larger number of patients and if these anesthetic strategies are associated with an increase in complications.

Explaining the advantage of avoiding general anesthesia led to a high acceptance of this approach among our patients. After changing our protocol to local anesthesia, only 2 out of 65 patients were treated in general anesthesia because of discomfort of the TEE probe during the pre-procedural screening. In all others (97 %), the procedure

was initiated in local anesthesia. This indicates that general anesthesia is not obligatory for the use of peri-procedural TEE. Similarly, other transcatheter procedures, which require TEE guidance—percutaneous left atrial appendage closure or catheter ablation—are regularly performed without general anesthesia as well [24, 25]. Conversion to general anesthesia was necessary only in three cases. This was reasoned by complications independent from the anesthesia method. Because of immediate endotracheal intubation standby, anesthesia was induced promptly in those cases.

The successful and safe use of local anesthesia in the first five patients indicated feasibility of this approach. Therefore, sedation was avoided when tolerated by the patients in all following procedures. Hence, local anesthesia without conscious sedation became the primary anesthetic approach. After that “run-in” period of 5 patients, in 28 out of 58 patients with local anesthesia (48 %) sedation was completely avoided. This enables breathing maneuvers (breath holding or increased respiratory rate with decreased volumes) to avoid respiration-dependent movements of the heart in contrast to sedated patients. In our experience, this technique facilitates clip implantation as good as in patients treated in general anesthesia where breathing maneuvers are performed by the ventilator. Moreover, paradoxical reactions to sedatives can be prevented. For those reasons, we now choose local anesthesia without sedation as primary approach. When sedation is needed though, we try to administer the drugs only at the beginning of TEE probe insertion. Many patients can easily tolerate the TEE after swallowing the probe and remain awake for the rest of the procedure when the sedation abates. In the future, even more short-acting sedatives such as remifentanyl should be considered to limit sedation to the specific period of TEE insertion.

Procedural success and post-procedure care

Importantly, procedural success was not influenced by the anesthesia management in the present analysis and is comparable to other large multi-center registries (91 % in ACCESS-EU and 94 % in the German TRAMI registry) [13, 26]. We emphasize that procedural failure or complications were not related to any movement or discomfort of the patients who underwent the implantation without general anesthesia.

Procedure time in cases performed in local anesthesia with and without sedation was longer. However, we do not assume that this is due to the type of anesthesia. Significantly more patients performed in local anesthesia received two or more clips, which typically extends the duration of the procedure. The reason for the larger percentage of two implanted clips in patients without general anesthesia may

lie in the use of local anesthesia as primary approach in the later course of our experience. Over time, the regime among the MitraClip[®] operators changed to a strong MR reduction without the fear of iatrogenic mitral stenosis after clip implantation. Another cause may be the influence of general anesthesia on hemodynamics of the MR. It is known that general anesthesia decreases the loading conditions of the left ventricle leading to a reduced mitral regurgitant volume [27]. This causes an underestimation of the severity of the MR under general anesthesia. Hence, the full severity of MR can be measured peri-procedurally in patients treated under local anesthesia, which possibly results in the implantation of more than one clip to achieve a sufficient MR reduction. The impact of general anesthesia on loading conditions is even stronger in functional MR. Considerably more patients had a functional MR in the later course of our experience. Therefore, the use of local anesthesia might help us to correctly determine MR severity during the procedure and, consequently, to implant the appropriate number of clips particularly in these patients.

Patients treated in local anesthesia were most often transferred to the general ward directly after the procedure in contrast to patients after general anesthesia who, with no exceptions, required ICU/IMC stay. According to the report from Di Prima et al., all patients were transferred to ICU after the MitraClip[®] procedure with at least an overnight stay [28]. Among others, this was due to delayed extubation and increased necessity for inotropic support, which both can be avoided or at least reduced by the use of local anesthesia. ICU admission after the MitraClip[®] procedure is a standard in many centers in Germany [3].

Safety of local anesthesia

In the present analysis, the rate of in-hospital complications was comparable between the anesthetic regimes. The hospital mortality rate in our center (6 %) was higher than usually reported after the MitraClip[®] procedure (about 3 %) [29]. Two patients in general anesthesia, two patients in local anesthesia with sedation and one patient in local anesthesia without sedation died during the hospitalization, respectively. Hence, there is no significant difference in the rates between the three groups. Importantly, the causes of death were not related to the type of anesthesia.

Potential disadvantages of performing the procedure without general anesthesia such as vascular complications or cardiac perforation that result from agitation and/or body movement cannot be excluded. Left atrial perforation occurred in one patient treated with local anesthesia and sedation but was not associated to any movement of the patient. Another risk may lie in the possibility of aspiration

especially during longer procedures without general anesthesia and the protection of endotracheal intubation. Nevertheless, these adverse events were not seen in our experience.

Note should be taken to the cerebrovascular events, which occurred under local anesthesia. Timely treatment could only be initiated because the operator was able to communicate with the patient and immediately detected the hemiparesis. Without the interaction between an awake patient and the physician, cerebrovascular events are hardly recognizable during the procedure and the risk for delayed treatment of cerebral injury is increased. The reported stroke rate during the MitraClip® procedure ranges from 0 to 2.6 % and elderly patients carry a higher risk [19, 26, 30]. As in our experience, the etiology of such strokes may be thrombus formation on the MitraClip® system which has already been reported during [31] and after the implantation [32]. Finally, one-year survival rate was not affected by the anesthetic approach in our experience.

Limitations

Although our work represents the first larger series regarding this topic so far, the number of patients may still limit precise interpretation of outcome. Patients were not randomized with regard to the anesthesia regime. Instead, local anesthesia with and without sedation was used consistently in the later phase of our experience.

Conclusion

In the light of this report, transcatheter mitral valve repair with the MitraClip® can be performed without general anesthesia. In fact, even conscious sedation is not routinely required. Procedural success and safety were similar in general anesthesia, local anesthesia with sedation and local anesthesia without sedation. Furthermore, local anesthesia was associated with significantly less necessity for ICU/IMC stay. This proof of concept allows for investigating the new approach in a larger number of patients.

Compliance with ethical standards

Conflict of interest Jakob Ledwoch: none, Predrag Matic: none, Jennifer Franke: none, Sameer Gafoor: none, Stephan Bertog: none, Markus Reinartz: none, Laura Vaskelyte: none, Ilona Hofmann: none, Horst Sievert: Dr. Sievert's institution received study honorary, travel expenses, consulting fees from Access Closure, AGA, Angiomed, Ardian, Arstasis, Atritech, Atrium, Avinger, Bard, Boston Scientific, Bridgepoint, CardioKinetix, CardioMEMS, Coherex, Contego, CSI, EndoCross, EndoTex, Epitek, Evalve, ev3, FlowCardia, Gore, Guidant, Lumen Biomedical, HLT, Kensey Nash, Kyoto Medical, Lifetech, Lutonix, Medinol, Medtronic, NDC, NMT, OAS, Occlutech, Osprey, Ovalis, Pathway, PendraCare, Percardia, pfm Medical, Recor,

Rox Medical, Sadra, Sorin, Spectranetics, SquareOne, Trireme, Trivascular, Viacor, Velocimed, Veryan and stock options from CardioKinetix, Access Closure, Velocimed, CoAptus, Lumen Biomedical, Coherex

References

1. Conradi L, Treede H, Rudolph V et al (2013) Surgical or percutaneous mitral valve repair for secondary mitral regurgitation: comparison of patient characteristics and clinical outcomes. *Eur J Cardiothorac Surg* 44:490–496
2. Schillinger W, Hunlich M, Baldus S et al (2013) Acute outcomes after MitraClip therapy in highly aged patients: results from the German TRANscatheter Mitral valve Interventions (TRAMI) Registry. *EuroIntervention* 9:84–90
3. Boekstegers P, Hausleiter J, Baldus S et al (2014) Percutaneous interventional mitral regurgitation treatment using the Mitra-Clip system. *Clin Res Cardiol* 103:85–96
4. Jin F, Chung F (2001) Minimizing perioperative adverse events in the elderly. *Br J Anaesth* 87:608–624
5. Oguri A, Yamamoto M, Mouillet G et al (2014) Clinical outcomes and safety of transfemoral aortic valve implantation under general versus local anesthesia: subanalysis of the French Aortic National CoreValve and Edwards 2 registry. *Circ Cardiovasc Interv* 7:602–610
6. Yamamoto M, Meguro K, Mouillet G et al (2013) Effect of local anesthetic management with conscious sedation in patients undergoing transcatheter aortic valve implantation. *Am J Cardiol* 111:94–99
7. Rassaf T, Balzer J, Zeus T, et al (2014) Safety and efficacy of deep sedation as compared to general anaesthesia in percutaneous mitral valve repair using the MitraClip system. *Catheter Cardiovasc Interv* 84:E38–42
8. Ussia GP, Barbanti M, Tamburino C (2010) Feasibility of percutaneous transcatheter mitral valve repair with the MitraClip system using conscious sedation. *Catheter Cardiovasc Interv* 75:1137–1140
9. Feldman T, Wasserman HS, Herrmann HC et al (2005) Percutaneous mitral valve repair using the edge-to-edge technique: six-month results of the EVEREST Phase I Clinical Trial. *J Am Coll Cardiol* 46:2134–2140
10. Kappetein AP, Head SJ, Genereux P et al (2013) Updated standardized endpoint definitions for transcatheter aortic valve implantation: the Valve Academic Research Consortium-2 consensus document. *J Thorac Cardiovasc Surg* 145:6–23
11. Teufel T, Steinberg DH, Wunderlich N et al (2012) Percutaneous mitral valve repair with the MitraClip(R) system under deep sedation and local anaesthesia. *EuroIntervention* 8:587–590
12. Ely EW, Truman B, Shintani A et al (2003) Monitoring sedation status over time in ICU patients: reliability and validity of the Richmond Agitation-Sedation Scale (RASS). *JAMA* 289:2983–2991
13. Baldus S, Schillinger W, Franzen O et al (2012) MitraClip therapy in daily clinical practice: initial results from the German transcatheter mitral valve interventions (TRAMI) registry. *Eur J Heart Fail* 14:1050–1055
14. Surder D, Pedrazzini G, Gaemperli O, et al (2013) Predictors for efficacy of percutaneous mitral valve repair using the MitraClip system: the results of the MitraSwiss registry. *Heart* 99:1034–1040
15. Armoiry X, Brochet E, Lefevre T et al (2013) Initial French experience of percutaneous mitral valve repair with the MitraClip: a multicentre national registry. *Arch Cardiovasc Dis* 106:287–294

16. Grasso C, Capodanno D, Scandura S et al (2013) One- and twelve-month safety and efficacy outcomes of patients undergoing edge-to-edge percutaneous mitral valve repair (from the GRASP Registry). *Am J Cardiol* 111:1482–1487
17. Braun D, Lesevic H, Orban M et al (2014) Percutaneous edge-to-edge repair of the mitral valve in patients with degenerative versus functional mitral regurgitation. *Catheter Cardiovasc Interv* 84:137–146
18. Blazek S, Lurz P, Mangner N, et al (2014) Incidence, characteristics and functional implications of cerebral embolic lesions after the MitraClip procedure. *EuroIntervention* 10:1195–1203
19. Whitlow PL, Feldman T, Pedersen WR et al (2012) Acute and 12-month results with catheter-based mitral valve leaflet repair: the EVEREST II (Endovascular Valve Edge-to-Edge Repair) High Risk Study. *J Am Coll Cardiol* 59:130–139
20. Tadie JM, Behm E, Lecuyer L et al (2010) Post-intubation laryngeal injuries and extubation failure: a fiberoptic endoscopic study. *Intensive Care Med* 36:991–998
21. Jaber S, Jung B, Corne P et al (2010) An intervention to decrease complications related to endotracheal intubation in the intensive care unit: a prospective, multiple-center study. *Intensive Care Med* 36:248–255
22. Motloch LJ, Rottlaender D, Reda S et al (2012) Local versus general anesthesia for transfemoral aortic valve implantation. *Clin Res Cardiol* 101:45–53
23. Babaliaros V, Devireddy C, Lerakis S et al (2014) Comparison of transfemoral transcatheter aortic valve replacement performed in the catheterization laboratory (minimalist approach) versus hybrid operating room (standard approach): outcomes and cost analysis. *JACC Cardiovasc Interv* 7:898–904
24. Reddy VY, Doshi SK, Sievert H et al (2013) Percutaneous left atrial appendage closure for stroke prophylaxis in patients with atrial fibrillation: 2.3-Year Follow-up of the PROTECT AF (Watchman Left Atrial Appendage System for Embolic Protection in Patients with Atrial Fibrillation) Trial. *Circulation* 127:720–729
25. Wutzler A, Mueller A, Loehr L et al (2014) Minimal and deep sedation during ablation of ventricular tachycardia. *Int J Cardiol* 172:161–164
26. Maisano F, Franzen O, Baldus S, et al (2013) Percutaneous mitral valve interventions in the real world: early and 1 year results from the ACCESS-EU, a prospective, multicenter, non-randomized post-approval study of the MitraClip(R) therapy in Europe. *J Am Coll Cardiol* 62:1052–1061
27. Grewal KS, Malkowski MJ, Piracha AR et al (2000) Effect of general anesthesia on the severity of mitral regurgitation by transesophageal echocardiography. *Am J Cardiol* 85:199–203
28. Di Prima AL, Covello DR, Franco A, et al (2014) Do patients undergoing mitralclip implantation require routine ICU admission?. *J Cardiothorac Vasc Anesth* 28:1479–1483
29. Nickenig G, Estevez-Loureiro R, Franzen O et al (2014) Percutaneous mitral valve edge-to-edge repair: in-hospital results and 1-year follow-up of 628 patients of the 2011-2012 Pilot European Sentinel Registry. *J Am Coll Cardiol* 64:875–884
30. Orban M, Braun D, Sonne C et al (2014) Dangerous liaison: successful percutaneous edge-to-edge mitral valve repair in patients with end-stage systolic heart failure can cause left ventricular thrombus formation. *EuroIntervention*. 10:253–259
31. Huntgeburth M, Muller-Ehmsen J, Brase C, Baldus S, Rudolph V (2014) Thrombus formation at the MitraClip system during percutaneous mitral valve repair. *JACC Cardiovasc Interv*. 7:e111–e112
32. Hamm K, Barth S, Diegeler A, Kerber S (2013) Stroke and thrombus formation appending to the MitraClip: what is the appropriate anticoagulation regimen? *J Heart Valve Dis* 22:713–715