
Transmissible Venereal Tumor Induced Paraphimosis in Dogs

Kumar A.*, Sangwan V., Mahajan S.K., Singh N.D., Singh K., Anand A., Saini N.S.

Department of Veterinary Surgery and Radiology, College of Veterinary Science, Guru Angad Dev Veterinary and Animal Sciences University, Ludhiana-141004, Punjab, India

(Received 16 Juli 2011/ Accepted 14 December 2011)

Although transmissible venereal tumor (TVT) of external genitalia is most common in canine (McEntee *et al.*, 2002) but incidence of paraphimosis in TVT victims is rare. The present report puts on record TVT as a cause to paraphimosis in four dogs.

The present study included four male dogs having paraphimosis associated with TVT lesions. Affected dogs were middle aged with age between 3 to 7 years. These were either Mongrel (*N.*=3) or Dalmatian (*N.*=1) breeds. History revealed that paraphimosis occurred 2 to 5 days back. Urination was normal in all the animals. On clinical examination engorged penis protruding out of the prepuce was recorded. Fragile pink cauliflower like growths at the bulb of the penis suspected for TVT lesions were also observed (Fig. 1). The lesions were cleaned to remove debris and impression smear were taken by moderately pressing microscopic slides over the lesions for cytological examination. Typical TVT cells with a round nucleus, a single eccentric nucleolus, and a thin rim of light blue, vacuolated cytoplasm were observed (Fig. 2). In the Dalmatian dog, the tumor tissue was infested with maggots also. In all the animals, penis was red in color with no evidence of necrosis.

In three cases (two Mongrel dogs and one Dalmatian), the paraphimosis was relieved using lignocaine jelly as a lubricant without any sedation. In the Dalmatian, TVT lesions were infested with maggots thus Negasunt powder was applied before relieving paraphimosis. No incision on the prepuce orifice was required in these cases. The correction of paraphimosis was done as per method

described by Kahn (2010). The prepuce was slightly retracted further in the posterior direction and the first fingers of both the hands were used to hold the inverted prepucial opening. The simultaneous effort of fingers pushing the prepuce anteriorly and the thumbs of both hands pushing the bulb of penis posteriorly were required to replace the penis in the prepucial cavity. Two to three attempts were required for a successful outcome. In one Mongrel dog, attempts to replace the penis in the prepucial cavity using lignocaine jelly were not rewarding. Thus a small incision was made on the dorsal aspect of the prepucial opening to relieve paraphimosis under general anesthesia using atropine, xylazine and ketamine. The incised skin was apposed with a mattress suture using Nylon No. 1. All the four dogs were administered meloxicam at 0.2mg/kg, IM, once a day for 3 days. In addition, Dalmatian was also given Inj. Cefotaxime at 20mg/kg twice a day, IM for 3 days. All the dogs were given Inj. vincristine sulphate at 0.025mg/kg dissolved in 10 ml distilled water, intravenously, at weekly interval for 3 to 5 weeks as per the clinical regression of the tumor. The supportive medication included Tab Ranitidine 150 mg, orally twice daily and Syp. Liv 52, 1 tsf twice a day throughout the course of chemotherapy. All the dogs completely recovered from the paraphimosis as well as TVT without any complications.

Paraphimosis is the inability to completely retract the penis into the prepucial cavity which usually occurs following sexual excitement or mating. There are multiple etiologies associated to the condition like inversion of the skin of prepucial orifice which impairs venous drainage from the penis, mild congenital or acquired phimosis, and foreign objects around penis, neoplasia, trauma, chronic balanoposthitis and paralysis of retractor penis

*Corresponding author: Kumar A

Address: College of Veterinary Science, Guru Angad Dev Veterinary and Animal Sciences University, Ludhiana-141004, Punjab, India
E-mail address: drashwanikumar@rediffmail.com

muscles (Kustritz, 2001, Fossum, 2007). TVT as an etiology to paraphimosis has rarely been recorded in the literature. Boscos and Ververidis (2004) recorded only 0.8% incidence of paraphimosis due to TVT.

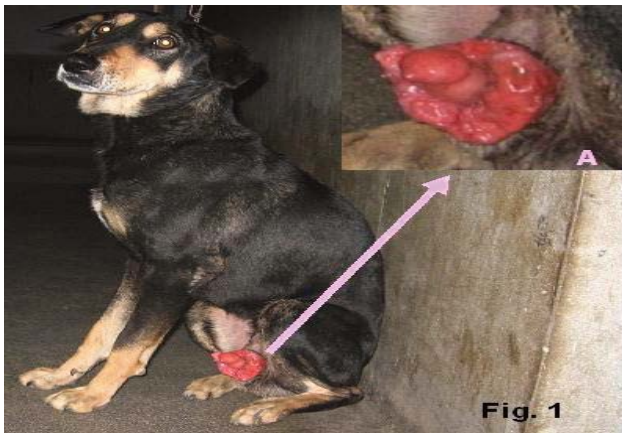

Fig. 1. Photograph showing circumcised growth at the base of penis causing paraphimosis (See inset Figure A).

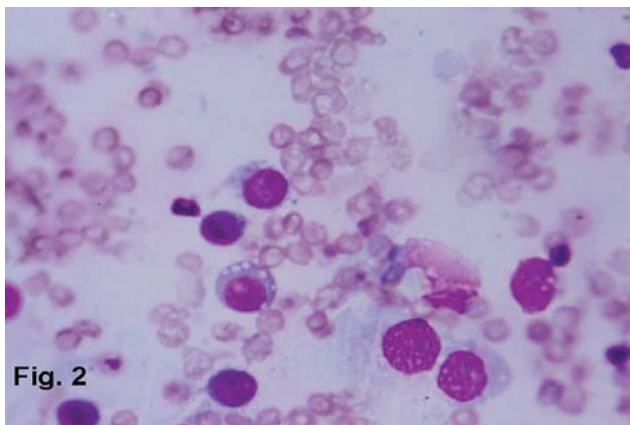


Fig. 2. Microphotograph of impression smear showing scattered round tumor cells suggestive of TVT.

In the present study, all the dogs were young adult to middle aged. Three out of four dogs were Mongrel and street dogs. Similarly previous studies report high incidence of genital TVT in free roaming, intact young dogs between 2 to 5 years of age and is transmitted by contact with infected genitalia during coitus (McEntee *et al.*, 2002, Rogers *et al.*, 1998, Fossum, 2007). Since it is a venereal tumor and mostly occurs in stray population in adulthood age when the dog is allowed to mate in the pack. A dog suffering from TVT lesions may not be able to retract the penis back into the prepuccial cavity after coitus or sexual excitement due to the presence of massive growth at the bulbus glandis which might have hindered the retraction of penis. De-Lorimier

and Fan (2007) opined that TVT may cause paraphimosis but Ndiritu (1979) reported that co-occurrence of paraphimosis in cases of TVT is statistically non-significant.

Presence of paraphimosis in three Mongrel or stray dogs of the present study, indicates that chronic untreated cases of genital TVT in male dogs may result in development of paraphimosis due to physical obstruction. No necrosis or discoloration of penis due to paraphimosis associated with TVT lesions was seen in any of the dog of the present study; however discoloration, necrosis and urethral obstruction have been reported in dogs with paraphimosis (Fossum, 2007). The TVT can be tentatively diagnosed from typical lesions and by fine needle aspiration or impression smear cytology (Rogers *et al.* 1998; McEntee *et al.* 2002; Fossum 2007). Vincristine sulphate has been reported to be safe and effective in the treatment of canine TVT lesions (Rogers *et al.*, 1998, Fossum, 2007).

References

- Boscos, C.M., Ververidis H.N., 2004. Canine TVT: Clinical findings, diagnosis and treatment. Proceedings of the 29th World Congress of World Small Animal Association.
- De-Lorimier, L.P., Fan, T.M., (2007. Canine transmissible venereal tumor. In: *Small Animal Clinical Oncology*, Fourth edition, Edited by Withrow, S.J., Vail, D.M., W.B. Saunders, New York.
- Fossum, T.W., 2007. Surgery of the Reproductive and genital systems. In: *Small animal Surgery*, Third edition, Mosby Elsevier, pp: 768-769.
- Kustritz, M.V.R., 2001. Disorders of the canine penis. *Veterinary Clinics of North America: Small Animal Practice* 31, 247-258.
- Kahn, C.M., 2010. The Merck Veterinary Manual, 10th Edition, Merck and Co. Inc, USA 1287-1288, 1294.
- McEntee, M.C., 2002. Reproductive oncology. *Clinical Techniques in Small animal Practice* 17, 133-149.
- Ndiritu, C.G., 1979. Lesions of the canine penis and prepuce. *Modern Veterinary Practice* 60, 712-715.
- Rogers, K.S., Walker, M.A. Dillon, H.B., 1998. Transmissible venereal tumor: A retrospective study on 29 cases. *Journal of American Animal Hospital Association* 34, 463-470.