

Transplantation of fetal neocortex in rhesus monkey

G. GOPINATH†, A. K. MAHAPATRA*, J. C. BHARADWAJ,
R. BANERJI, D. N. SHARMA** and P. N. TANDON*

Department of Anatomy, *Neurosciences Centre, **Central Animal Facility, All India
Institute of Medical Sciences, New Delhi 110 029, India

MS received 19 December 1988; revised 14 April 1989

Abstract. A feasibility study of neural transplantation in adult rhesus monkey was undertaken. Fresh and preserved neocortex containing multiplying and maturing neurons obtained from 55-70 gestation days were transplanted into the striatum, cerebellum and cerebral cortex of adult monkeys. Tissues were preserved for 4 days either at subzero temperature in the freezer compartment of the ordinary refrigerator in Ringer lactate or incubated in culture medium. While 2 monkeys out of 5 injected with preserved tissue had successful transplants after 4 months, all the 10 monkeys injected with fresh tissue had no transplants. The size of the two surviving transplants was small. The neurons in the transplants were mainly in clusters. Many of the cells were immature and some showed early degenerative changes. Neuronal processes were restricted to the transplants and thus showed lack of morphological integration with the host tissue. Further studies are in progress to define the nature of the embryonic tissue of primate which can grow and survive and also the role of neural grafts in functional recovery following experimental lesions of the brain regions.

Keywords. Rhesus monkey; fetal neocortex; neural transplantation.

Introduction

Attempts at neural transplantation were already made nearly a century ago. However, successful transplants were obtained only recently with the recognition that embryonic tissue with the potential to proliferate and differentiate was required as donor tissue. As a result, a voluminous literature is now available on neural transplantation in adult mammals, mostly in rodents (Wallace and Das, 1983; Sladek and Gash, 1984; Bjorklund and Stenevi 1985). Till recently hardly any information was available with respect to sub-human primates. Realising this deficiency, two years ago we initiated neural tissue transplantation in rhesus monkeys using embryonic neocortex as the donor tissue, which was at the same stage of development as the donor tissue used in the rat (Gopinath *et al.*, 1987). Based on the report of Rakic (1976) on the sequential development of the neocortex in rhesus monkey, gestation days between 55 and 70 days were selected initially for the donor tissue. Simultaneously the donor tissue was examined to confirm the structural details.

Materials and methods

Cyclicity of the female monkeys was determined by daily examination of the vaginal smear. The regularly cycling females were allowed to mate with the males and the

†To whom all correspondence should be addressed.

sperm positivity was checked in the vaginal smear the next morning. Accordingly the date of pregnancy was determined. Pregnancy was confirmed by per rectal palpation of the uterine size on 30th and 40th days of the positive vaginal smear. Caesarean sections of the pregnant monkeys were done on the desired dates under aseptic conditions after ketamine anaesthesia (10 mg/kg body weight). Postoperative course of these animals were uneventful and they resumed cyclicity eventually. Neocortex from 4 fetuses of 55, 64, 66 and 70 gestation days were used as donor tissue for transplantation at different sites in the host monkeys (table 1). The crown rump lengths of these fetuses ranged from 4.5-6.5 cm.

Table 1. Number of host monkeys, sites of transplantation and the nature of donor tissue transplanted and the results.

No. of hosts	Site	Nature of donor tissue	Results
4	Cerebellum	64 days-fresh	Nil
3	Caudate	64 days-subzero temperature	1
2	Caudate	64 days-culture medium	1
2	Cerebellum	66 days-fresh	Nil
3	Motor cortex	55 days-fresh	Nil
1	Motor cortex	70 days-fresh	Nil

Young primates weighing 2-4.5 kg were used as hosts for transplantation. The approximate age ranged between 1 and 2.5 years. Under pentobarbital anaesthesia (35 mg/kg body weight) either small burr-holes were drilled in the skull using stereotaxic coordinates for caudate nucleus, or flaps of the skull were removed to expose the cerebral or cerebellar sites for direct injection of the donor tissue. Just before transplantation the dura was cut to make the injection smooth. Meanwhile the fetus was delivered by caesarean section and the brain was rapidly removed and were immersed in chilled Ringer lactate solution. After removing the meninges and blood vessels, the neocortex from the frontal region was taken into a glass capillary tube attached to a syringe. Solid tissue 50-100 μ l was thus injected into the caudate using stereotaxic coordinates in each animal. Neocortex of about 100-200 μ l were used for transplantation to the cerebral cortex and cerebellum under direct vision.

Part of the remaining neocortical tissue was preserved in Ringer lactate in the freezer compartment of the ordinary refrigerator or by incubating in culture medium. After 4 days these tissues were transplanted into caudate nucleus using the stereotaxic coordinates. The frozen tissue kept in the freezer compartment of the refrigerator was rapidly thawed by keeping in a warm water bath (50-60°C) before injection. Some of the remaining fresh neocortical tissue was processed for light microscopy to study the stage of development of the donor tissue. Four more fetuses of approximate age group 60-100 gestation days, provided by the Central Drug Institute, Lucknow were also studied to determine the stage of development of the neocortex.

Four months after transplantation two hosts each transplanted in the caudate, cerebellum and cerebrum were sacrificed under deep anaesthesia. Thereafter the animals were sacrificed at monthly intervals. Intracardiac perfusion using buffered 4% paraformaldehyde fixative was done before removing the brains. Injection or the transplantation sites on the surface of the brain were located. Serial coronal

sections were cut to identify the transplant if present. The transplants when present with the surrounding host tissue were processed for light microscopy and the sections were stained with cresyl violet for cytoarchitecture and silver stains for fibers.

Table 1 gives the details of the sites and the number of hosts and the age of the donor tissue used in each host for transplantation.

Results

The earliest neocortex studied and transplanted belonged to a 55-day old fetus. Neocortex at this age appeared as a thin shell forming the wall of the lateral ventricle. Under the microscope a ventricular zone, an intermediate zone, a cortical plate and a molecular region were seen. The ventricular zone was a single cell layer of tall cells with a large number of mitotic figures. The cell-rich adjacent area, subventricular layer, showed round immature neuroblasts and spindle shaped migrating cells. The superficial part of this layer had mitotic figures. The remaining region was comparatively free of cells and the ones present were of the migrating type. Subventricular region and the cell-free area between the ventricular layer and the more superficial cortical plate are together termed intermediate zone. Cortical plate was a thick sheet of rounded cells. The marginal zone occupying the subpial position had only very few cells and was very thin (figure 1).

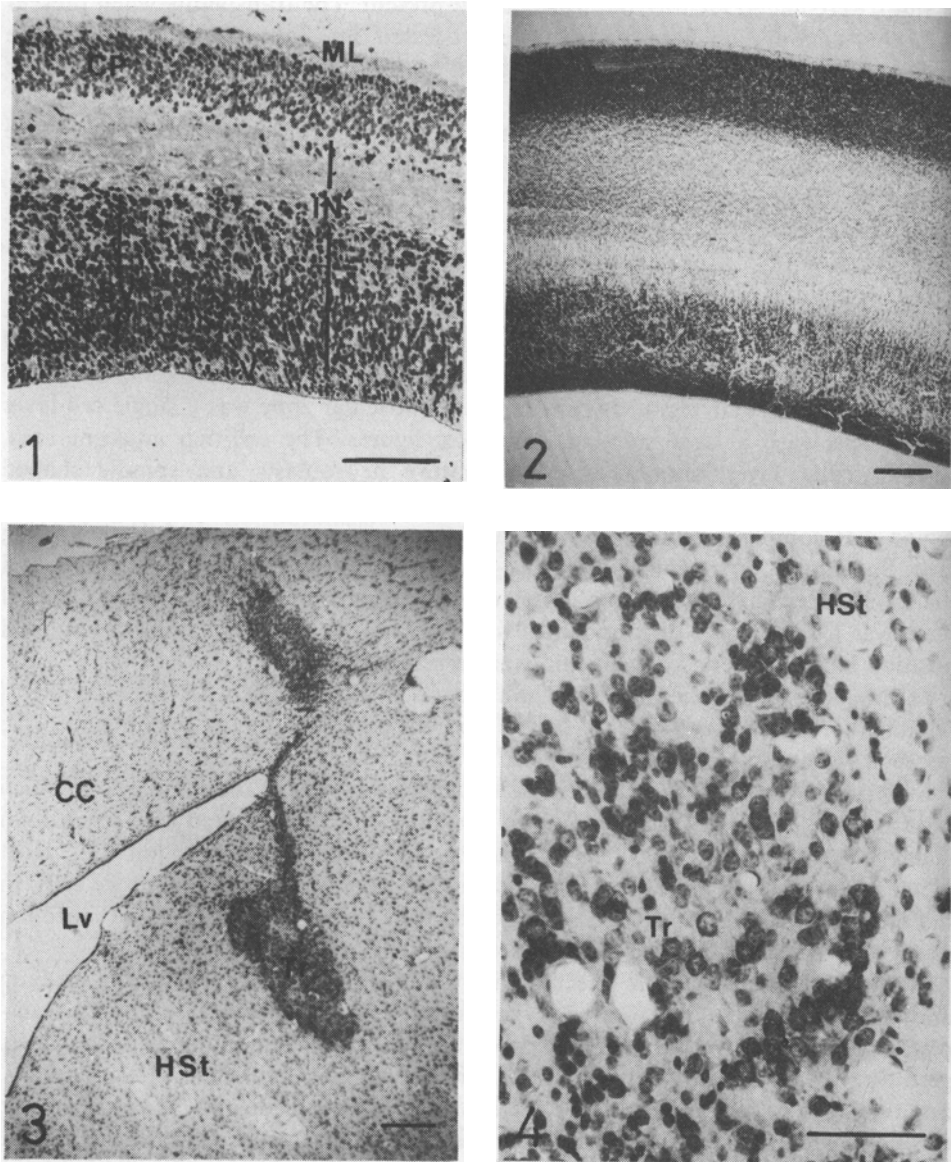
In the older fetuses the neocortex had increased in thickness with the widening of the different layers and differentiation of the cells (figure 2). As the age advanced the number of mitotic figures had declined.

Surprisingly there were no surviving transplants in any of the monkeys in which fresh neocortical tissue was injected. In 4 monkeys, 3 transplanted into cerebellum and one into cerebral cortex, narrow cavities were seen at the injection sites. Host tissue at the margins of these cavities showed destruction and inflammatory cells. In the remaining monkeys, except two injected with preserved donor tissue, injection sites could not be located in serial sections.

In two host monkeys, one injected with tissue maintained in the culture medium and the other with neocortex preserved at subzero temperature, surviving transplants were seen in the striatum. Neocortex used in both the monkeys belonged to gestation day 64. While major part of both transplants remained in the caudate, one transplant extended into the cortex through corpus callosum, showing growth through the needle track (figure 3). Both the transplants were small in size and were well delineated. In both the transplants neurons were mostly in groups and clusters when compared to the scattered distribution of neurons in the surrounding host tissue. Many of the neurons in the clusters had multiple nucleoli suggesting immaturity (figure 4). A few of the scattered neurons had swollen and vesiculated nuclei indicating early degenerative changes. At the margin of the transplants in the surrounding host tissue a few lymphocytes could be seen. The fibers observed in the silver stained preparations were mostly restricted to the transplants and were directed at right angles to the fibre bundles of the surrounding host tissue (figure 5).

Discussion

Studies of Rakic (1976) had already shown that the neocortex of the rhesus monkey



Figures 1-4. 1. Section of neocortex from 55-day old fetus showing ventricular zone (V), intermediate zone, (IN), cortical plate (CP) and molecular layer (ML). SV, Subventricular layer of the intermediate zone. Bar, 100 μm . 2. Cross section through the neocortex of 65-day old fetus at low power. The layers seen in figure 1 are still seen but much thicker and better formed. Bar, 200 μm . 3. Well-circumscribed transplant (Tr) in the striatum (HSt) of the host monkey. Lv, Lateral ventricle. The transplant can be seen extending into the corpus callosum (CC). Bar, 200 μm . 4. Higher magnification of the transplant (Tr) in the striatum (HSt). Clusters of neurons and neurons with multiple nucleoli can be seen. Bar, 50 μm .

grows actively during the period studied by us. In our study the maximum number of proliferating and migrating neurons ideal for grafting as indicated by Das *et al.*

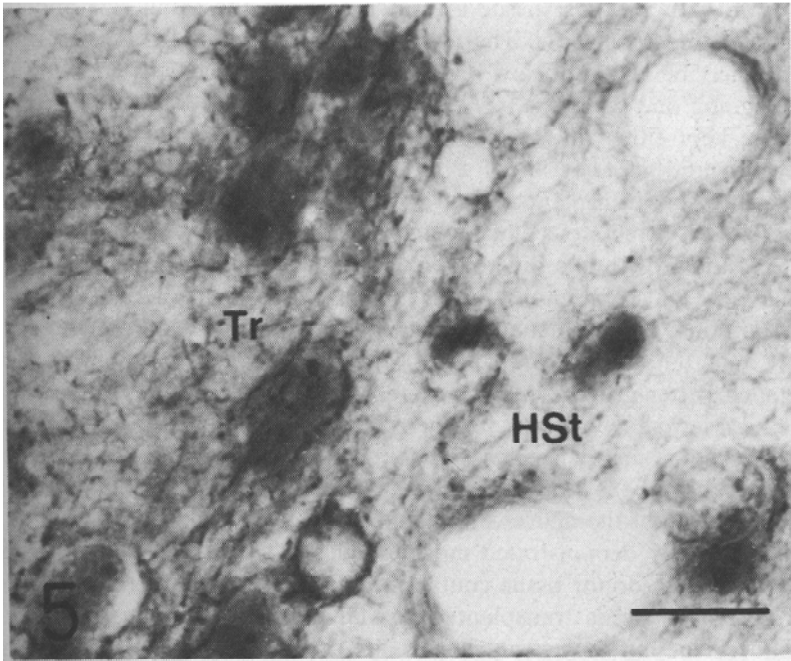


Figure 5. Silver-stained section showing fibres in the transplant (Tr). Fibres of the host striatum (HSt) are not seen as the section is at right angles to the fibre bundles. Bar, 10 μm .

(1980) in rat, is between 50 and 70 gestation days in the somatosensory and motor cortical areas of rhesus monkey. A recent study by Sladek *et al.* (1987) in African green monkeys reported recovery of primates (African green monkeys) from Parkinson-like syndrome induced by 1-methyl-4 phenyl-1,2,3,6-tetrahydropyridine (MPTP) following substantia nigra grafts from advanced gestational days when the nigral cells are already postmitotic (Levitt and Rakic 1982). This success was in spite of the statement by Bakay *et al.* (1987) that successful grafts can only be obtained if the fetal tissue belonged to the 'critical' period of development, which is the stage before the final mitosis. These conflicting reports indicate that for successful transplants in primates dividing cells may not be absolutely essential and that cells undergoing maturation are also as suitable provided the techniques of transplantation and the viability of the donor tissues are properly monitored. From the present study it can be concluded that there were sufficient number of viable neurons after preservation to give rise to surviving grafts at least till the end of the 4th month of transplantation. Houle and Das (1980) have reported that grafts grown from tissues preserved for 6 h at -70°C were comparable to that obtained from fresh donor tissue. Since we have been unsuccessful to obtain even a single surviving graft from the fresh tissue it is difficult to assess the growth potential of the frozen donor tissue in the present study. The presence of immature neurons in the transplant indicate that the maturation of the neurons had been delayed and not comparable to the more advanced maturation of the neurons seen in similar experiments in rat striatum with fresh donor tissue (Gopinath *et al.*, 1987). Structural details of transplants in rhesus monkeys are not available so far for comparison. Limited growth and lack

of integration with the host tissue are obvious from the small size and the clear delineation of the transplants. The few lymphocytes in the neighbourhood of the transplants may be a sign of slow rejection. This aspect needs to be investigated.

It is intriguing that while the fresh donor tissue used in 10 monkeys did not take, donor tissue kept either at subzero temperature or in culture medium for 4 days, survived and grew in two out of 5 monkeys. Victorov and Lyjin (1988) having obtained successful transplants in rat from tissues cultivated for 3h to 9 days, hypothesized that some molecules present in the fresh embryonic tissue may not be conducive to the growth in a different environment. Manasek and Cohen (1977), are also of the view that some molecules of the embryonic tissue may act as inhibitory factors in an alien environment. This view may be supported by the observations that in neonatal hosts as compared to the adults the embryonic donor tissue showed much better growth (McLoon and Lund 1983). The presence of immature neurons and a few showing early degenerative changes either suggest that the adult host tissue is not a conducive environment for the proper maturation and continued maintenance of the transplanted neurons in the primate or that preservation had rendered some of the neurons nonviable.

The present study demonstrated morphologically successful neural transplant in rhesus monkey with donor tissue containing a mixture of proliferating and migrating neurons. Fresh tissue transplanted has failed to grow in this series of study. Inflammatory reaction and cavity at the site of transplantation in a few animals could be due to infection rather than foreign body reaction since such reaction was not present in all. Studies are in progress using other areas of the primate brain as donor tissue to evaluate further the nature of donor tissue ideal for successful transplant and to assess the role of neural grafts in functional recovery in monkeys with experimental lesions of the brain.

Acknowledgement

This project was supported by the Indian Council of Medical Research, New Delhi,

References

- Bakay, R. A. E., Barrow, D. L., Fiandaca, M. S., Iuvone, P. M., Schiff, A. and Collins, D. C. (1987) *Ann. N.Y. Acad. Sci.*, **495**, 163.
- Bjorklund, A. and Stenevi, U. (1985) *Neural grafting in mammalian CNS* (Amsterdam: Elsevier).
- Das, G. D., Hallas, B. H. and Das, K. G. (1980) *Am. J. Anat.*, **158**, 135.
- Gopinath, G., Mahapatra, A. K., Nayar, U. and Tandon, P. N. (1987) *Indian J. Med. Res.*, **86**, 246.
- Houle, J. D. and Das, G. D. (1980) *Experientia*, **36**, 1114.
- Levitt, P. and Rakic, P. (1982) *Dev. Brain Res.*, **4**, 35.
- Manasek, F. J. and Cohen, A. M. (1977) *Proc. Natl. Acad. Sci. USA*, **74**, 1057.
- McLoon, S. C. and Lund, R. D. (1983) *J. Comp. Neurol.*, **217**, 376.
- Rakic, P. (1976) *Exp. Brain Res. (Suppl.)*, **1**, 244.
- Sladek, J. R. Jr., and Gash, D. M. (1984) *Neural transplants: Development and function* (New York: Plenum Press).
- Sladek, J. R. Jr., Collier, T. J., Elsworth, J. D., Roth, R. H. and Redmond, D. E. Jr. (1987) *Ann. N.Y. Acad. Sci.*, **495**, 623.
- Victorov, I. V. and Lyjin, A. A. (1988) *Indo-Soviet symposium on developmental neurobiology and neural transplant*, November 25-28, New Delhi.
- Wallace, R. B. and Das, G. D. (1983) *Neural tissue transplantation research* (New York: Springer).