Biliary complications after liver transplantation: With special reference to the biliary cast syndrome and techniques of secondary duct repair

Thomas E. Starzl, M.D., Ph.D., Charles W. Putnam, M.D., John F. Hansbrough, M.D., *Denver, Colo.,* **Kendrick A. Porter, M.D.,** *and* **H. A. S. Reid, M.R.C.Path.,** *London, England*

In 93 consecutive cases of orthotopic liver transplantation, there were 24 examples of biliary obstruction and eight of bile fistula formation. Six of the obstructed livers developed biliary cast formation so extensive that the smaller intrahepatic ducts became plugged to an extent that they could no longer have been treated by surgical means. In each of the six cases, the most important causative factor was neglected obstruction of the large bile ducts with the intrahepatic lesions apparently being late and secondary. Stone and/or cast formation also occurred in other obstructed livers in the presence of bile fistulas, but these deposits were limited to the large ducts where they could have been or were removed. Although homograft bile undoubtedly has increased lithogenicity at certain postoperative times, the data from the present study have shown that biliary sludge formation essentially is always associated with defective bile duct reconstruction, and the observations have underscored the urgency with which reoperation must be considered. Techniques of secondary intervention have been described, with emphasis on conversion of cholecystojejunostomy to choledochojejunostomy. This operation has permitted salvage of homografts in eight of nine trials and the survival of seven patients.

From the Veterans Administration Hospital and the Department of Surgery, University of Colorado Medical Center, Denver, Colo., and the Department of Pathology, St. Mary's Hospital and Medical School, London, England

BILIARY TRACT obstruction and fistulas have caused the death or marred the recovery of many patients after liver transplantation.[3, 5, 7–9, 10] With either complication, we[3, 8] and Williams, Waldram, and Calne and their associates[9, 10] have noted a tendency for the intrahepatic ducts to become filled with a soft chalklike debris, leading in some instances to obstructing casts of the whole intrahepatic tree. Waldram, Williams, and Calne[9] attributed the development of these deposits, at least in part, to nonsurgical factors such as altered bile composition brought on by rejection or by the enzyme action of bacteria. They speculated on the further possible roles of bile stasis and subtle injury to the bile duct epithelium during periods when the transplant is under immunologic attack.

If pathologic sludge and stone formation within liver homografts proved to be due primarily to an unavoidably increased bile lithogenicity in spite of technically perfect operations, a serious question would have to be raised about the inherent feasibility of the operation in more than the occasional case. For that reason, examples of the biliary cast syndrome were looked for among our first 93 recipients of orthotopic liver transplants with the purpose of determining the incidence and etiology of the problem. The cases then were examined alongside of all the other biliary duct complications of the same period which had not resulted in histopathologically evident intrahepatic sludge formation.

The over-all conclusion was that the biliary cast syndrome always or nearly always had a mechanical etiology at least in part. As a consequence, the second objective of this communication became to discuss tech-

Supported by research grants Nos. AM-17260 and AM-07772 from the National Institutes of Health, by grants Nos. RR-00051 and RR-00069 from the General Clinical Research Centers Program of the Division of Research Resources, National Institutes of Health, and by Veterans Administration projects Nos. MRIS 8118-01 and 7227-01.

Accepted for publication April 14, 1976.

Reprint requests: Thomas E. Starzl, M.D., Department of Surgery (C-305), University of Colorado Medical Center, 4200 E. Ninth Ave., Denver, Colo. 80220.

Table I. Patients who had intrahepatic bile cast syndrome

OT No.	Age at transplantation (yr.)	Last bilirubin	Reason to suspect biliary cast	Original duct hook-up	Explanation of obstruction	Time of sample after operation (days)*
8	1½	15	Autopsy finding	Cholecystoduodenostomy	Compression of cholecystoduodenostomy by metastatic liver cell carcinoma	400
12	1	3	Autopsy finding	Cholecystoduodenostomy	Stenosis of cystic duct	105
15	49	10	Autopsy finding	Cholecystoduodenostomy	Compression of common hepatic duct by metastatic liver cell carcinoma	339
30	1	22	Autopsy finding	Cholecystoduodenostomy	Stenosis of cystic duct caused by virus infection of cells lining larger bile ducts	37
43	15	7	Cystic duct obstruction; reoperated upon but died	Cholecystoduodenostomy	Stenosis of cystic duct caused by cytomegaloviral infection of lining cells	47
55	6	30	Autopsy finding	Choledochocholedochostomy	Anastomotic stricture	780

*All autopsy specimens.

niques by which reoperation could be carried out more effectively in the event of an initial failure of biliary reconstruction.

CASE MATERIAL

The 93 consecutive recipients, who all were operated upon at least 15 months ago, were the subject of a recent complete report with emphasis on survival and causes of failure.[8] There were 56 recipients who were 18 years old or less, and 40 of this pediatric group had the original diagnosis of biliary atresia. The 37 adults were 21 to 68 years old and carried the most frequent diagnoses of primary liver malignancy, alcoholic cirrhosis, and chronic aggressive hepatitis. The principles and details of care of these patients have been described previously.[5, 6, 8] Orthotopic transplant (OT) code numbers of specific patients have been used before and permit the identification of specific cases from publication to publication.[5, 8]

Biliary duct reconstruction was with the varied techniques cited elsewhere,[5, 7, 8] of which the most common have been cholecystoduodenostomy after ligation of the common duct, Roux-en-Y cholecystojejunostomy, and choledochocholedochostomy over T tube stents. As will be mentioned later, cholecystoduodenostomy no longer is considered to be an acceptable alternative.

CRITERIA FOR AND DIAGNOSIS OF INTRAHEPATIC CAST SYNDROME

The screening was based entirely upon examination of homografts that were sampled at autopsy, retransplantation, or biopsy. If debris and inspissated bile could not be seen within the intrahepatic ducts, other evidence suggesting large bile duct obstruction was not by itself grounds for inclusion.

Six patients whose ages ranged from one to 49 years qualified (Table I). Bile duct reconstruction had been with cholecystoduodenostomy in five patients and choledochocholedochostomy in the sixth. Biliary obstruction always was present. Apparently this usually was partial, inasmuch as the majority of the final serum bilirubin concentrations were in an intermediate range (Table I). Recurrent hepatoma was the obstructing agent in two patients, and a suture line stricture at an end-to-end common duct anastomosis was responsible in a third. There were three examples of narrowing of the cystic duct near its junction with the common duct, and in two of these (OTs 30 and 43) virus infestation with swelling and shedding of the lining epithelial cells was suspected of having played a role. One of these patients (OT 43) has been reported previously as Case 3 by Martineau and co-workers.[3] The clinical features of recurrent bacteremia and fever described by Martineau and associates were present in 5 of the 6 patients. The diagnosis was made before death only in patient OT 43. Reoperation of that patient 40 days before death had failed to remove the intrahepatic sludge. The tragic truth of the diagnosis was discovered in the other patients as long as 780 days after transplantation (Table I). In all six liver allografts, the common hepatic duct, the two main hepatic ducts, and the smaller bile ducts and ductules were dilated and filled with amorphous, yellowish green, rather crumbly material, and some soft stones.

Microscopically there was clear evidence of large biliary duct obstruction. The portal tracts were en-

Fig. 1. *A*, Three dilated intrahepatic bile ducts containing inspissated bile in liver OT 12. The portal tract is enlarged and contains excess fibrous tissue. (Hematoxylin and eosin. Original magnification ×30.) *B*, Dilated small bile duct lined by flattened epithelium in liver graft OT 8. Most of the inspissated bile in the lumen has fallen out during the processing of the section. Some extravasated bile is present in the upper left corner of the picture. (Hematoxylin and eosin. Original magnification ×80.)

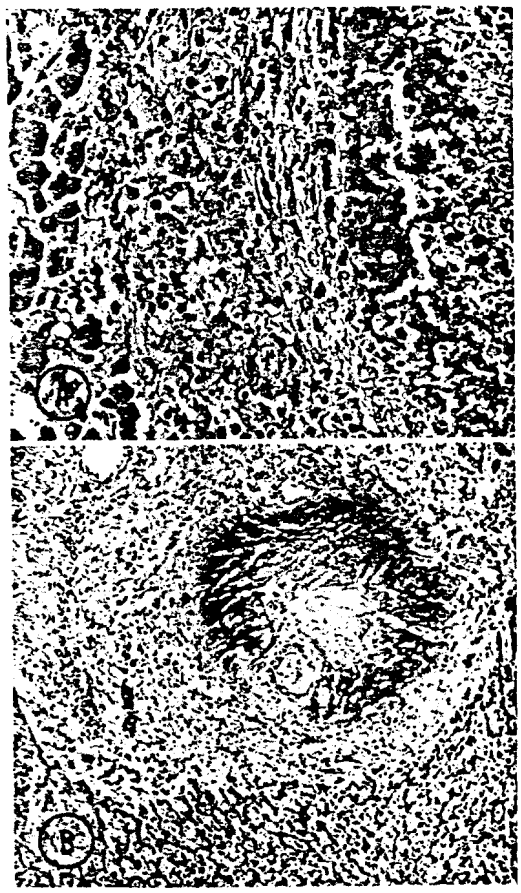

Fig. 2. *A*, Part of dilated large bile duct which lacks a lining layer of epithelium from liver graft OT 55. The lumen, on the right of the picture, is blocked by inspissated bile. (Hematoxylin and eosin. Original magnification ×80.) *B*, Ruptured small bile duct surrounded by an area of bile leakage in liver transplant OT 15. (Hematoxylin and eosin. Original magnification ×30.)

larged, contained excess connective tissue, and were infiltrated with small numbers of mononuclear cells and polymorphonuclear leukocytes. The intrahepatic bile ducts were dilated and filled with inspissated bile (Fig. 1, *A*). Many of the ducts were lined by flattened epithelium (Fig. 1, *B*), but others lacked a lining cellular layer (Fig. 2, *A*). Bile lakes, bile infarcts, and foci of fibrosis and calcification in areas of bile leakage all were present (Fig. 2, *B*). In most of the livers there was proliferation of small bile ducts at the periphery of the portal tracts. Centrilobular cholestasis, with bile in hepatocytes and Kupffer cells and extracellularly as thrombi in dilated canaliculi, was marked in two of the livers (OTs 8 and 12) and moderate or slight in the others. Chronic cholangitis was marked in three of the livers (OTs 8, 15, and 43).

In the hepatic allograft of patient OT 43, large basophilic intranuclear inclusions were present in many of the epithelial cells lining the cystic duct (Fig. 3, *A*) and gallbladder and in a few of the cells lining the intrahepatic biliary ductules. Many of the enlarged virus-infected cells had been shed into the lumen of the cystic duct and were causing obstruction. Thin sections of the infected cells examined in the electron microscope showed particles of a virus of the herpes group in the nucleus and cytoplasm. Cytomegalovirus was isolated from the cystic duct cells in human embryonic lung fibroblast culture. Subsequently, when the patient died, cells with intranuclear inclusions were found in the lungs and other tissues, and cytomegalovirus was grown from these structures.

The graft from patient OT 30 also showed basophilic

nuclear inclusions in the epithelium lining the biliary tract, but in this case the intrahepatic bile ducts and ductules in the portal tracts were affected most severely (Fig. 3, *B*). The lumina of the infected ducts were filled with shed virus-infected cells. Ultrastructural studies of the inclusions showed particles of a virus of the polyoma group and not cytomegalovirus.

In a third graft (OT 12), the cystic duct and gallbladder were chronically inflamed and the mucosa was ulcerated, but no evidence of virus infection was found.

In one of the grafts (OT 55), the small branches of the hepatic arteries were narrowed severely by intimal thickening composed of myointimal cells and connective tissue, and this change was accompanied by rupture of the internal elastic lamina. The arterial damage may have been caused by graft rejection. None of the other transplants showed any evidence of either past or active rejection.

Fibrous septa linked portal tracts in three of the longer surviving grafts, but none of the livers were cirrhotic.

RELATION TO TOTAL PROBLEM OF BILIARY RECONSTRUCTION

Thirty-two (34 percent) of the 93 patients in this consecutive series of liver replacements had the biliary duct complications listed in Table I, Table II, and the first footnote in Table II. Thus the six livers with fully developed intrahepatic bile duct casts represented less than a fifth of the incidence of problems with biliary reconstruction. Obstruction was a frequent complication of cholecystoenterostomy, usually at a narrowed cystic duct, and could be recognized by transhepatic cholangiography (Fig. 4, *A*, *B*, and *C*). Most of the fistulas (Table II) followed efforts to anastomose the common duct directly to the host common duct or duodenum. The difficulty of diagnosing many of these lethal complications was reflected in the fact that reoperation was not even attempted in so many cases.

Any kind of biliary tract complication usually was accompanied by the same findings of jaundice, fever, and bacteremia that were found in the patients with the fully developed intrahepatic biliary cast syndrome. Furthermore, when reoperation was attempted or when autopsy was performed, the same kind of sludge described earlier was encountered frequently, but this was confined to the large ducts or fistula tracts and apparently had not plugged smaller radicles within the liver insofar as could be determined from histopathologic examination. In one patient the biochemical composition of this sludge was predominantly cholesterol and bilirubin.

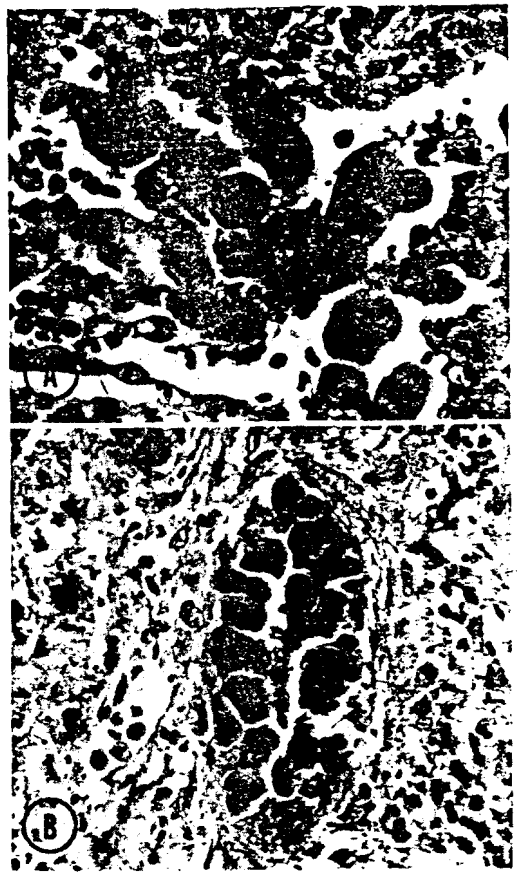

Fig. 3. Swollen biliary epithelial cells containing basophilic nuclear inclusions. *A*, Those from patient OT 43 are obstructing the cystic duct and are infected by cytomegalovirus. *B*, Those from patient OT 30 are occluding an intrahepatic bile ductule and are infected by a polyoma virus. (Hematoxylin and eosin. Original magnification ×900.)

TECHNIQUES OF BILIARY TRACT REOPERATION

There is no chance for survival in the immunosuppressed patient if biliary complications are not diagnosed and corrected promptly. No successful reoperations were recorded by Waldram, Williams, and Calne.[9] We did not achieve survival after reoperation until far along in our series. The main problems in our series and in the King's College–Cambridge series in England have been three in number and have required differing surgical treatment.

Acute bile fistula after choledochocholedochostomy. Broad drainage must be provided in the hope of avoiding fatal regional and systemic sepsis. One of our patients (OT 90) is well almost 1½ years after complete opening of an infected and bile-stained right subcostal wound.

Late fistula repair. If the fistula does not close, sub-

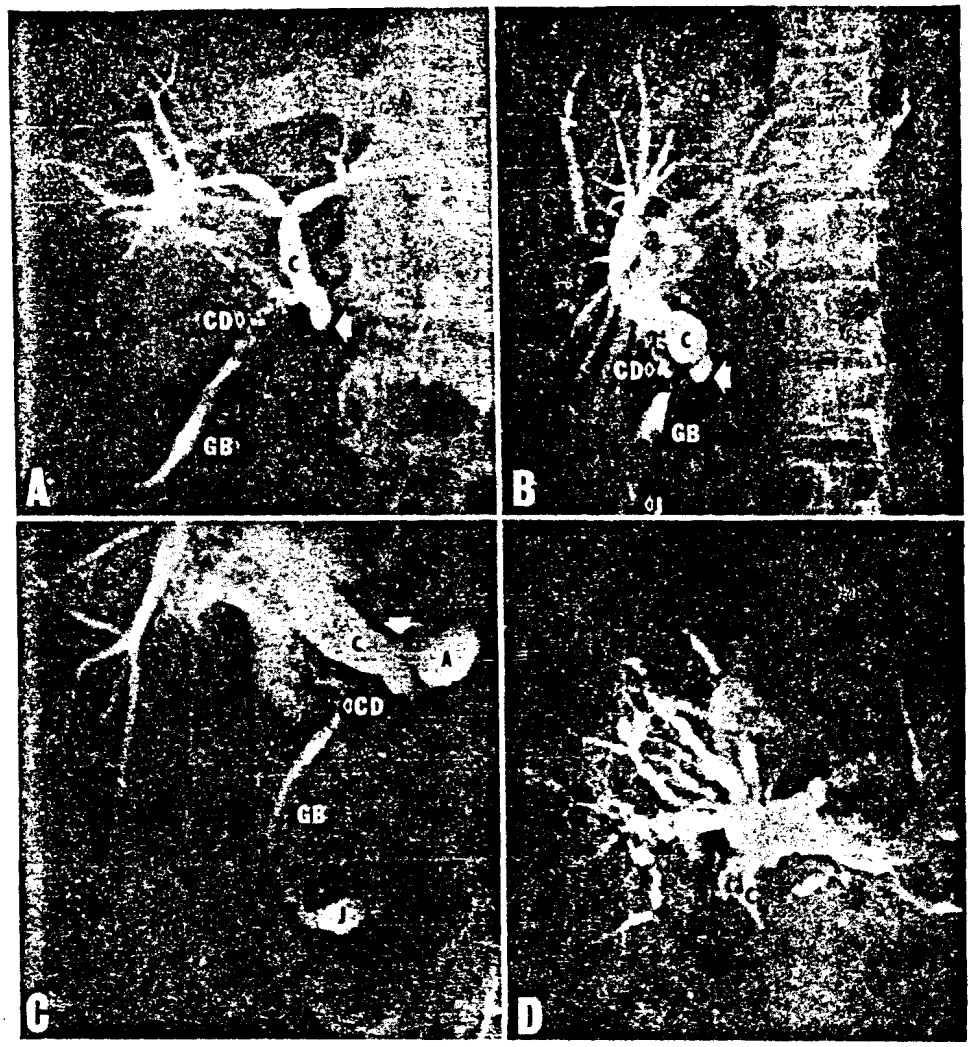

Fig. 4. Transhepatic cholangiograms in four patients whose original biliary reconstructions were with Roux-en-Y cholecystojejunostomy, as depicted in Fig. 6, *A*. *A*, minimal obstruction (OT 100). *B*, Moderate obstruction (OT 77). *C*, Severe obstruction with leak and abscess formation (A) near site of common duct ligation (OT 95). *D*, Very severe obstruction (OT 98). At reoperation the common duct was necrotic. [*(C)* = common duct; *(CD)* = cystic duct; (GB) = gallbladder; (J) = jejunum; large arrow = site of common duct ligation.] The livers shown in *A*, *B*, and *D* were salvaged by conversion to choledochojejunostomy, as shown in Fig. 6, *B*. These three patients are alive. The liver shown in Fig. 4, *C* was removed and replaced with a second homograft. The patient died one month later.

sequent late repairs may be possible by one of the techniques summarized by Maingot[2] and by Smith.[4] To our knowledge, direct operative control of a fistula in this way has been attempted in only one liver recipient, a patient of ours (OT 27) who had an effort at conversion of a cholecystoduodenostomy (Fig. 5, *A*) to choledochoduodenostomy plus dilatation of strictures of the right and left hepatic ducts almost 5 years after transplantation. The common duct sloughed, leaving a total bile fistula plus a complete duodenal fistula. The situation was partly controlled by Roux-en-Y choledochojejunostomy, closure of the duodenal defect, and reinforcement of the duodenal closure with the side of the Roux limb for a patch. The patient survived another year for a total of 6 years after transplantation. The reoperation provided incomplete relief of the obstruction and, in addition, the patient was left with a large internal sinus and fistula (Fig. 5, *B*). Retransplantation was decided upon, but the patient died before a donor became available. Much sludge and debris was in the sinus tract and the major ducts, but not in the small intrahepatic radicals.

Fig. 5. *A*, Transhepatic cholangiogram of a liver homograft almost 5 years after transplantation. Note the strictures of the main right and left ducts (*R* and *L*) and of the common duct (*CD*). The original biliary reconstruction was with cholecystoduodenostomy. *B*, The same liver several months after conversion to choledochojejunostomy using mucosal patch technique of Rodney Smith[4]. The duct strictures have not been relieved. In addition, a sinus tract and internal fistula are evident (*) with jejunal (j) communication.

Table II. Other bile duct complications which did not lead to intrahepatic casts among seventy-seven patients who eventually died*

	No. of patients	*Survival (days)*	*OT Nos.*	*No. of patients reoperated upon*
Obstruction†	14	10 39 2,190 61 34 73 546 408 62 111 20 84 62 47	22 25 27 41 44 49 54a§ 58 60 62a§ 79 84 87 88	8
Fistula‡	7	23 13 81 27 28 29 34	5 28 47 63 68 69 70	3

*Sixteen patients from the consecutive series of 93 are still alive from 15 months to 6 years after transplantation. Five (OT 56, 77, 90, 91, 92) of these long-term survivors have had successful secondary operations on the homograft duct system.

†All 14 of these livers had their original biliary reconstruction by cholecystoduodenostomy or Roux-Y cholecystojejunostomy. In patients OT 22, 25, and 79, the bile blockage was iatrogenic by accidental ligature.

‡Four of these anastomoses were choledochocholedochostomy, 2 were cholecystoduodenostomy, and one was choledochoduodenostomy.

§"a" refers to a first homograft that was removed and replaced with a second transplant. The corresponding survival days refer to the residence of the first liver.

Obstruction after cholecystoduodenostomy. Biliary obstruction of the kind caused by cystic duct stenosis necessitates removal of the gallbladder and detachment of the intestinal anastomosis. If the original reconstruction was with cholecystoduodenostomy, a procedure which we no longer use, our secondary operation was to anastomose the dilated common duct to the defect in the duodenum. Only one survivor (OT 56) emerged from six such attempts, and that patient eventually required conversion to Roux-en-Y choledochojejunostomy because of repeated bouts of cholangitis. The others died from regional and systemic infection, duodenal fistula, and inadequate biliary decompression.

Obstruction after roux-en-y cholecystojejunostomy. After the primary reconstruction shown in Fig. 6, *A*, a satisfactory fallback procedure is available and usually in a clean operative field by reusing the Roux limb for anastomosis to the dilated common duct (Fig. 6, *B*). A significant advantage is that the risk of duodenal fistula described in the preceding section is avoided. The use of the defunctionalized Roux limb protects the liver homograft from direct contamination by gastrointestinal contents.

A change from cholecystojejunostomy to choledochojejunostomy was made in four of the patients amongst the first 93 in our series (OTs 77, 87, 91, and 92). The only death was from a severe infection (OT 87). Five more patients treated subsequently (OTs 98, 99, 100, 101, 104) have had a similar conversion from cholecystojejunostomy to choledochojejunostomy. No deaths resulted, although one patient did die several months after retransplantation; the other four recipients are alive. The record of eight successes in nine tries with a hitherto nearly untreatable complication has prompted the following technical description

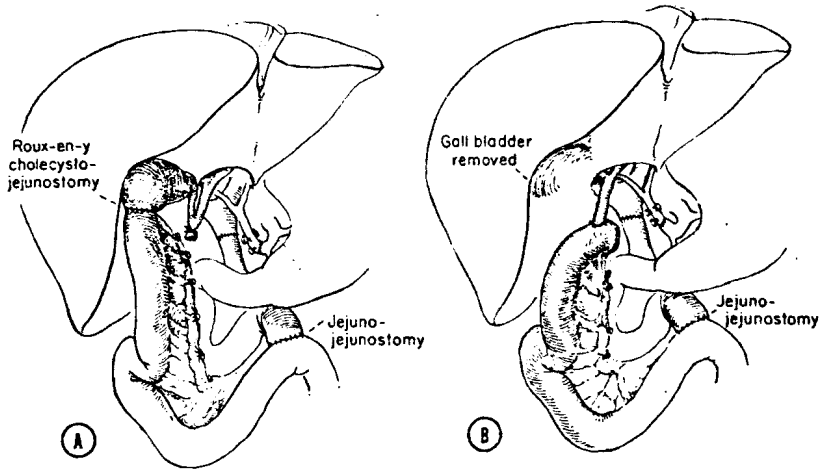

Fig. 6. *A*, Technique of cholecystojejunostomy that is most commonly used today for primary biliary duct reconstruction. *B*, Conversion to choledochojejunostomy with the same Roux limb as in *A*. The details of reoperation are shown in Fig. 7.

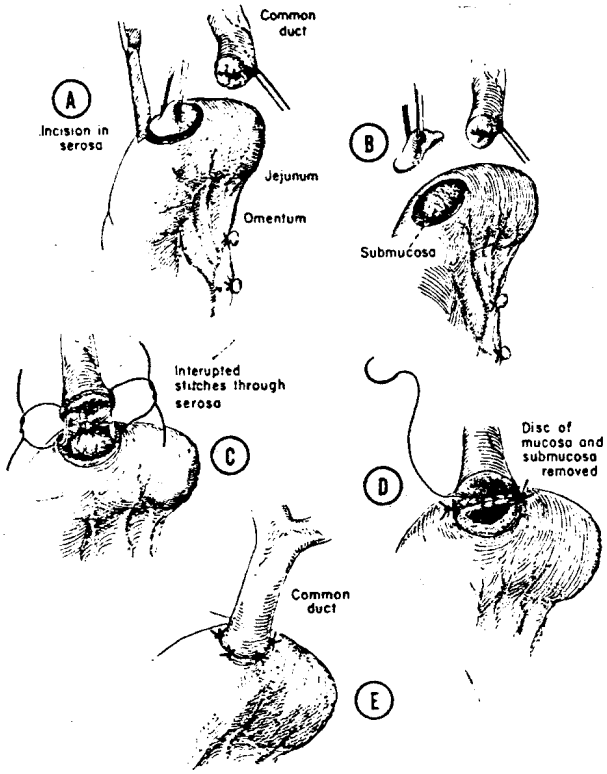

Fig. 7. Technique of choledochojejunostomy.

of the reoperation. The principles employed were worked out well by the great biliary surgeons of the past, as summarized by Maingot[2] and Smith.[4] Our emphasis will be placed upon modification of these well known techniques.

The previous right subcostal incision is reopened. The liver homograft surface is found and this plane is developed until the gallbladder is encountered. Retrograde cholecystectomy is started and then is completed after the cholecystojejunostomy is taken down. The common duct is transected at or just above the entrance of the cystic duct (Fig. 6, *B*). The dissection is inherently dangerous in this area and the portal venous and hepatic arterial anastomotic suture lines are seen frequently. In about half of the cases, small pockets of pus have been encountered near the earlier ligation of the common duct.

The end of the Roux limb is closed with an inner layer of No. 4-0 catgut and an external layer of silk (Fig. 6, *B*). A button of serosa and muscularis is excised (Fig. 7, *A*), exposing the submucosa (Fig. 7, *B*). Interrupted No. 6-0 swadged vascular silk sutures are used for a superficial outer layer (Fig. 7, *C*). A button of jejunal mucosa is now excised, and No. 5-0 or No. 6-0 chromic catgut is used to fashion a continuous inner layer (Fig. 7, *D*) which usually goes through full thickness of the common duct followed by an anterior silk layer (Fig. 7, *E*). The external silk layer has the effect of protruding the common duct into the jejunum. Stents usually are not used since the graft duct is short and stiff enough in consistency to resist distortion, twisting, or flattening.

Generous drainage is provided by leaving 2 or 3 inches of the subcostal incision open. In 2 or 3 days, twice daily irrigations of the subhepatic wound, which is allowed to close secondarily over the next one or 2 months, are begun.

The biochemical findings of biliary obstruction are relieved promptly by the operation (Fig. 8). With the obstructive factor under control, management of rejection or other causes of liver dysfunction becomes easier (Fig. 8). If there is still concern about the adequacy of

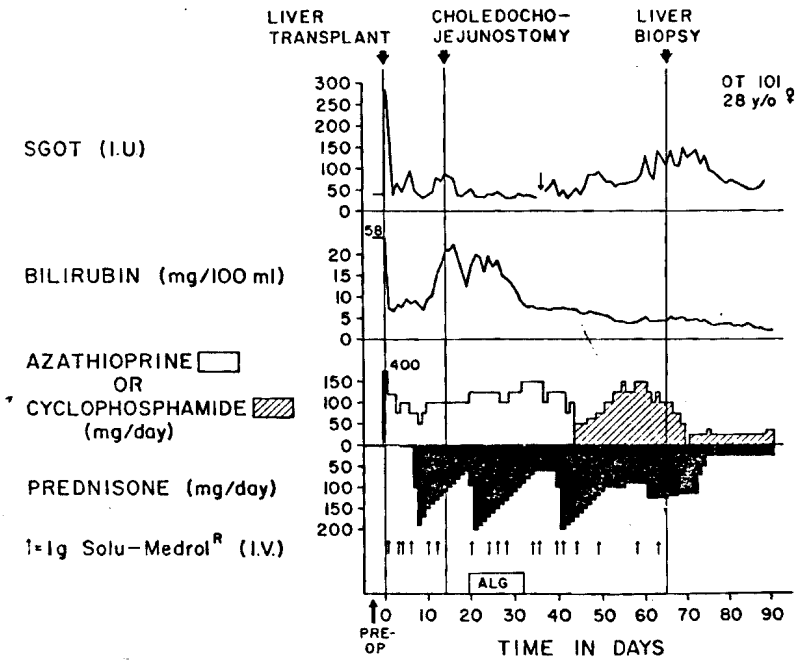

Fig. 8. Course of a patient (OT 101) who had initial biliary duct reconstruction with cholecystojejunostomy. Following operation bilirubin fell from 58 mg. per 100 ml. to less than 10 mg. per 100 ml. Secondary hyperbilirubinemia led to the transhepatic cholangiogram shown in Fig. 9, *A* and to conversion to choledochojejunostomy. The patient is well 6 months after operation. The liver biopsy was obtained because of residual liver function abnormalities and showed toxic hepatocellular changes. This diagnosis prompted the abrupt reduction of immunosuppressive drug doses.

biliary drainage, repeat transhepatic cholangiography may be performed (Fig. 9). In the example shown (Fig. 9), the final hook-up of choledochojejunostomy was considered to be perfect anatomically, even though the duct dilatation had not regressed.

DISCUSSION

The stifling impact of defective biliary tract reconstruction upon the development of liver transplantation is evident from the 34 percent biliary obstruction or fistula rate in our hands and from the figure of 40 percent recorded by Calne and Williams and their associates[9, 10] at Cambridge and King's College.

Until recently, the death rate from these complications has been nearly 100 percent. However, such problems presumably are technically based and are subject, therefore, to technical solutions, particularly if the first operation is chosen wisely. We still perform common duct-to-common duct anastomosis with a T tube stent under specially favorable anatomic conditions. However, for reasons alluded to briefly earlier in this article and described more completely elsewhere,[7] now we perform Roux-en-Y cholecystojejunostomy most frequently as the initial procedure.

If this approach is used, it is necessary to pay scrupulous attention after operation to the possibility of obstruction from the beginning with repeated transhepatic cholangiograms and liver biopsies when necessary. If obstruction develops, it has almost always been at the narrowed cystic duct (Fig. 4). Reoperation is feasible then. It has been enormously encouraging to see a rapidly growing number of such patients recover uneventfully after conversion from cholecystojejunostomy to choledochojejunostomy.

The studies of Javitt, Shiu, and Fortner[1] and Waldram, Williams, and Calne[9] have added a new and potentially disquieting dimension to considerations of biliary reconstruction. After liver transplantation both groups found shifts in the bile composition at various phases of recovery which they pointed out could contribute to or even be a primary cause of sludge and stone formation. The implicit derivative question was whether the precipitation in the biliary tree with or without obstruction was so widespread as a result of lithogenic conditions inherent in the procedure and the postoperative events that the chances of consistent success after liver transplantation would be nullified.

The findings in the liver grafts of our series have shown that biochemical abnormalities are not the main factors in the salting out of "biliary chalk," since an

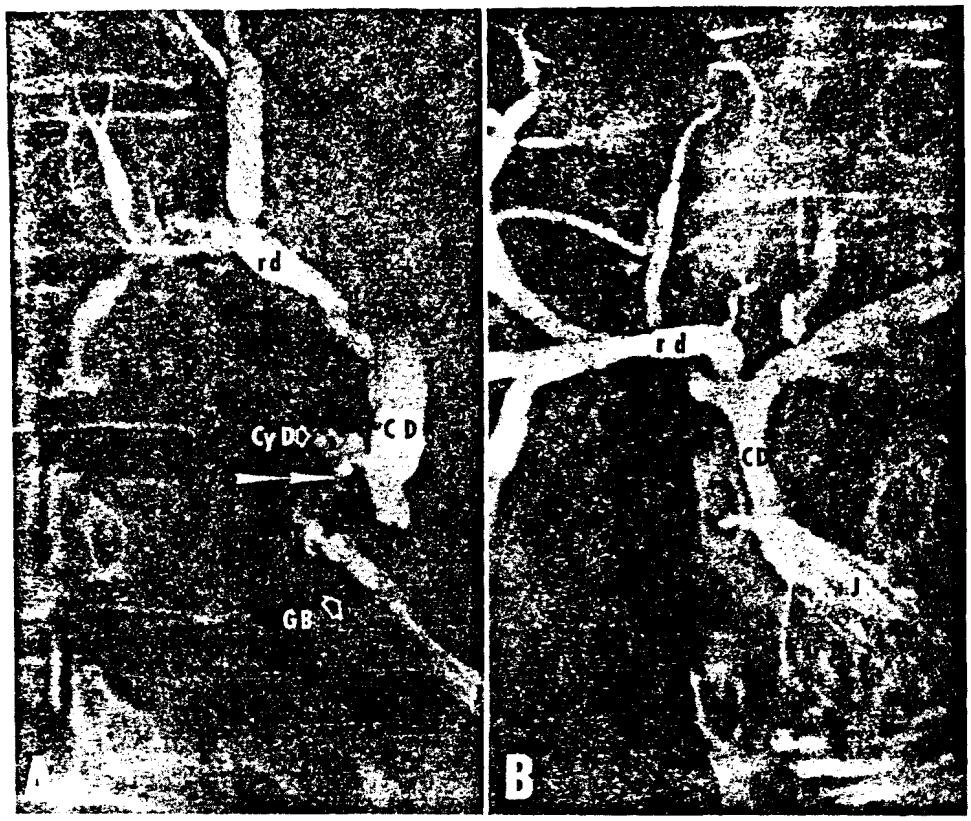

Fig. 9. Transhepatic cholangiograms of the patient whose course is shown in Fig. 8. *A*, Obstructed duct system two weeks after transplantation. *B*, Repeat transhepatic cholangiogram 3 months after relief of obstruction by conversion to choledochojejunostomy. The junction between the common duct *(CD)* and jejunum *(J)* is not detectable. [*(CyD)* = cystic duct; *(GB)* = gallbladder; (RD) = right hepatic duct branch which was compared on both studies. Note that there is residual dilatation.]

essentially mechanical etiology always has been identifiable. Grafts that had adequate biliary drainage did not have these findings. In our six examples of extensive intrahepatic bile casts, obstructions were found from differing causes that had been neglected for a long time. Livers that had biliary obstructions or fistulas of shorter duration did not have extensive intrahepatic sludging and debris, although stones and casts were in the larger ducts. In all of the cases of either fistula or obstruction, it was evident that the situations would have been correctable surgically with reoperation at the right time. All experienced hepatic surgeons have encountered the same sludging in nontransplant patients with chronic or recurrent bile duct obstruction and fistula formation.

This does not mean that the sludge formation in the transplanted liver previously reported by us and by the King's College–Cambridge group is not a problem. Rather it underscores the urgency with which reoperation must be considered, if there is a biliary tract complication, before the uncontrolled precipitation of bile constituents can occur. Heretofore, reintervention has been unavailing with rare exceptions, but these dismal prospects are improving.

We wish to thank Dr. Sylvia D. Gardner of the Virus Reference Laboratory, Central Public Health Laboratory, Colindale Avenue, London, for kindly carrying out the virus isolation studies.

REFERENCES

1. Javitt, N. B., Shiu, M. H., and Fortner, J. G.: Bile salt synthesis in transplanted human liver, Gastroenterology 60: 405, 1971.
2. Maingot, R.: Traumatic injuries of the gallbladder and bile ducts, *in* Maingot, R., editor: Abdominal operations, Vol. 1, New York, 1974, Appleton-Century-Crofts, Inc., p. 1120.
3. Martineau, G., Porter, K. A., Corman, J., et al.: Delayed biliary duct obstruction after orthotopic liver transplantation, SURGERY 72: 604, 1972.
4. Smith, R.: Mucosal graft operations for hilar strictures and for strictures of the hepatic ducts, *in* Maingot, R., editor: Abdominal Operations, Vol. 1, New York, 1974, Appleton-Century-Crofts, Inc., p. 1166.

5. Starzl, T. E., and Putnam C. W.: Experience in hepatic transplantation, Philadelphia, 1969, W. B. Saunders Company.
6. Starzl, T. E., Putnam, C. W., Halgrimson, C. G., et al.: Cyclophosphamide and whole organ transplantation in humans, Surg. Gynecol. Obstet. **133:** 981, 1971.
7. Starzl, T. E., Ishikawa, M., Putnam, C. W., et al.: Progress in and deterrents to orthotopic liver transplantation; with special reference to survival, resistance to hyperacute rejection, and biliary duct reconstruction, Transplant. Proc. **6:** 129, 1974.
8. Starzl, T. E., Porter, K. A., Putnam, C. W., et al.: Orthotopic liver transplantation in 93 patients, Surg. Gynecol. Obstet. **142:** 487, 1976.
9. Waldram, R., Williams, R., and Calne, R. Y.: Bile composition and bile cast formation after transplantation of the liver in man, Transplantation **19:** 382, 1975.
10. Williams, R., Smith, M., Shilkin, K. B., et al.: Liver transplantation in man: The frequency of rejection, biliary tract complications, and recurrence of malignancy based on an analysis of 26 cases, Gastroenterology **64:** 1026, 1973.