

## Treatment of Massive Pulmonary Embolism by Percutaneous Fragmentation of the Thrombus

Marco Antonio Oliveira Barbosa, Dinaldo Cavalcanti Oliveira, Audrey Torres Barbosa, Ricardo Pavanello, Antonio Kambara, Enilton Sergio Tabosa Egito, Edson Renato Romano, Ibraim Maschiarelli Pinto, José Eduardo Moraes Rego Sousa, Leopoldo Soares Piegas

Hospital do Coração, ASS - São Paulo, SP - Brazil

### Summary

**Objectives:** To evaluate the safety and efficacy of percutaneous thrombus fragmentation (PTF) for massive pulmonary embolism (PE) in patients with contraindications to the administration of thrombolytics.

**Methods:** Between July 1999 and August 2005, 10 patients (7 males, 3 females, age  $57 \pm 18$  years) with massive PE and contraindications to the administration of thrombolytics underwent PTF. A transthoracic doppler echocardiogram was used to evaluate arterial oxygen saturation (Sat  $O_2$ ), the Walsh index (WI), mean pulmonary artery pressure (PAP), mean systemic blood pressure (SBP) and right ventricular function (RVF) before and after the procedure. Statistical analysis was conducted using the paired Wilcoxon test, of which p was significant when  $\leq 0.05$ .

**Results:** After the PTF treatment there was an improvement in Sat.  $O_2$  [ $87.4 \pm 1.3\%$  vs  $92.3 \pm 3.1\%$  ( $p < 0.001$ )], WI [ $6.4 \pm 1.07$  vs  $4.4 \pm 1.42$  ( $p = 0.003$ )], PAP [ $31.8 \pm 4.6$  mmHg vs  $25.5 \pm 3.4$  mmHg ( $p < 0.001$ )] and SBP [ $73.9 \pm 8.7$  vs  $85 \pm 8.3$  ( $p = 0.001$ )]. The ten patients had severe RVF before the percutaneous treatment; however, within 10 days after PTF, 8 presented normal or discrete function and 1 presented mitigated function. There were no technical or vascular access site complications related to PTF. One patient died in the hospital (10%). The procedure was successful for the other nine patients.

**Conclusion:** The lack of adverse complications related to the procedure, proves that PTF is safe. The improvement in Sat  $O_2$ , WI, PAP, SBP and RVF in 90% of the cases demonstrates the efficacy of the procedure, indicating that it is an alternative treatment for massive PE in patients with contraindications for the administration of systemic thrombolytics.

**Key words:** Pulmonary embolism/therapy; thrombosis; femoral vein.

### Introduction

Pulmonary embolism (PE) is a consequence of a thrombus that forms in the venous system, dislodges and travels through the right heart cavities obstructing the pulmonary artery or one of its branches<sup>1</sup>.

PE is a serious cause of morbidity and mortality in the community as a whole with an estimated incidence rate of 0.5 per 1,000 people and mortality rate of 15% within three months. Records indicate that hospital mortality is greater than 30% in patients with massive PE and hemodynamic instability<sup>2</sup>.

The risk for patients with massive PE to develop cardiogenic shock is high. Usually, the damage to the pulmonary artery vasculature is greater than 50%. The most notable symptom is dyspnea; transitory cyanosis and syncope are common and systemic hypotension, requiring vasopressor drugs is the main sign. Mortality for some series can reach 60 to 70%, and most of the deaths occur during the initial evolution hours<sup>3</sup>.

The main objectives of massive PE treatment are: to promote quick lysis of the thrombus, improve right ventricular performance, avoid the recurrence of new episodes and lower the risk of chronic pulmonary artery hypertension development<sup>4</sup>.

PTF represents an additional treatment option for high risk massive PE patients with contra-indications for fibrinolytic drugs and also as an alternative to surgical embolectomy<sup>5</sup>.

The study includes patients with massive PE that were contraindicated for the use of thrombolytics and submitted to PTF therapy.

### Objectives

The objectives of the study were to evaluate the safety and efficacy of PTF to treat massive PE in patients with contraindications to thrombolytic therapy.

Comparative analysis, before and after the procedure, of the Walsh index (WI), mean pulmonary artery pressure (PAP), mean systemic blood pressure (SBP), right ventricular function (RVF) and  $O_2$  saturation (Sat.  $O_2$ ) was used to evaluate the efficacy of the procedure. Safety was evaluated through the measurement of possible complications related to the percutaneous procedure.

**Correspondência:** Dinaldo Cavalcanti Oliveira •

Rua Eliseu Guilherme, 123 CEP: 04004-030 – São Paulo, SP

E-mail: doliveira@hcor.com.br

Manuscript received February 28, 2006; revised manuscript received May 21, 2006; accepted August 17, 2006.

## Methods

This was an open, non-comparative, prospective study conducted between July 1999 and August 2005 (7 males, 3 females, age  $57 \pm 18$  years) and approved by the research ethics commission of the institution. Inclusion criteria were: massive PE confirmed by an angiograph (pulmonary artery occlusion  $\geq 50\%$  or equivalent angiographic score, mean pulmonary artery pressure  $\geq 25$  mmHg and shock index  $\geq 1$ ) and contraindications for the use of thrombolytics. All patients signed a free and informed consent form for the study.

SBP, PAP and  $\text{Sat.O}_2$  were measured before and after the procedure. Transthoracic doppler echocardiograms were performed before and after PTF (1st, 3rd, 5th, 8th and 10th days).

PTF success was defined as an angiographic reduction in the thrombus, a lower Walsh index and lower mean pulmonary artery pressure.

Statistical analysis was conducted using the paired Wilcoxon test and p was considered significant when  $\leq 0.05$ . The results are expressed as mean  $\pm$  standard deviation.

The patients were monitored in the hemodynamics laboratory until the procedure, electrocardiogram, peripheral oxygen saturation and invasive systemic blood pressure measurements were completed.

The femoral vein was punctured in accordance with the standard technique and maintained with a 7-French valve introducer. Using an angiographic catheter the pressures of the pulmonary artery and right heart cavities were recorded followed by a selective angiography of the pulmonary arteries, which identified the thrombus and measured the Walsh index.

The fragmentation catheter [Rotatable Pigtail William Cook Europe Denmark (Fig. 1) or Clot Buster Amplatz Thrombectomy Device (Fig. 2) or standard Pigtail] was positioned level with the artery obstruction and by rotating the catheter over its longitudinal axis and/or a series of axial movements to dislodge the occlusion; then, the thrombus fragmentation was performed.

Lastly, a new selective pulmonary angiography was

performed and pulmonary artery pressure was taken to evaluate the results of the procedure and the new Walsh index measurement.

After the introducer was removed from the femoral vein, local hemostasis was performed by manual compression.

The patients were sent to an intensive care unit after the procedure, where they remained for at least 5 days.

## Results

The contraindications for the use of systemic thrombolytics were: eight of the patients had undergone surgery in the previous 15 days (3 myocardial revascularizations, 1 cholecystectomy, 1 neurological surgery, 1 orthopedic surgery, 1 spinal column surgery and 1 prostatectomy), 1 had recent gastrointestinal bleeding ( $<1$  week) and 1 suffered cardiopulmonary arrest with a resuscitation time greater than 30 minutes.

The PTF procedure for the majority of the patients (60%) was performed using a standard pigtail catheter.

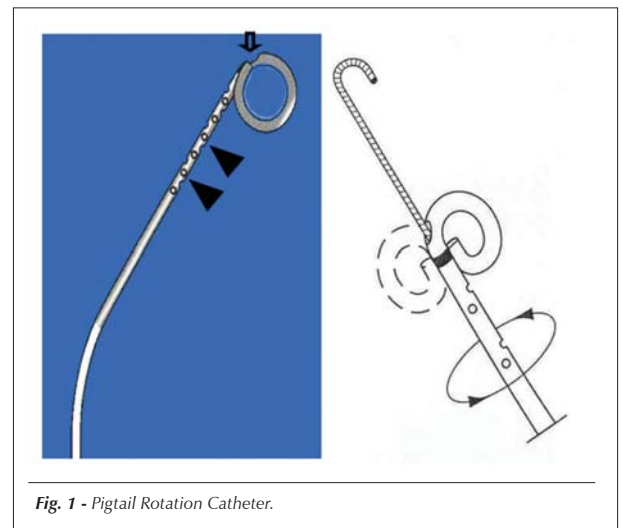


Fig. 1 - Pigtail Rotation Catheter.

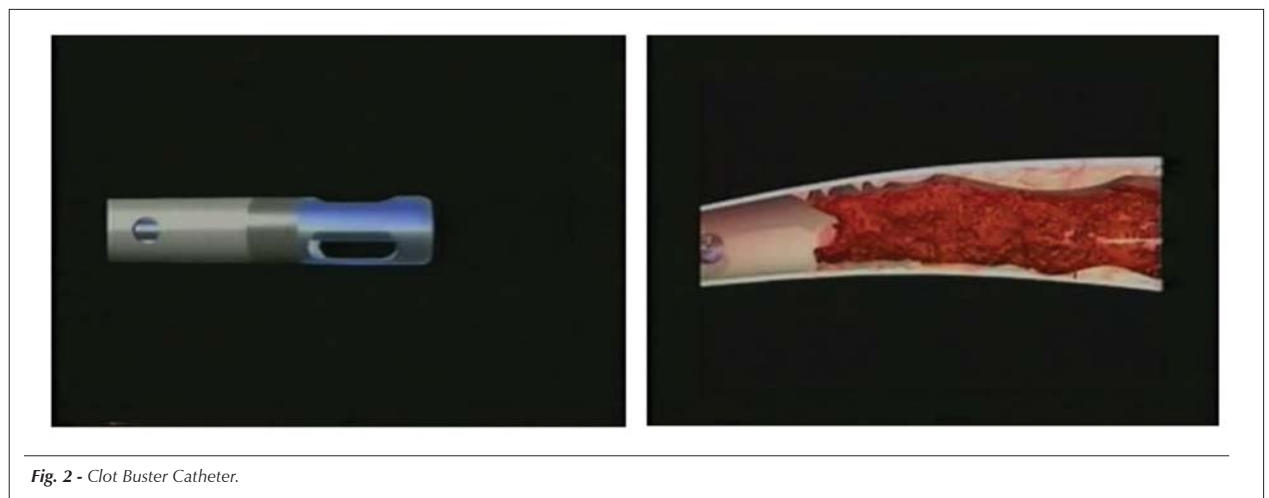


Fig. 2 - Clot Buster Catheter.

## Original Article

After the procedure the Walsh index (WI) for 10 lungs (8 patients) lowered from  $6.4 \pm 1.07$  to  $4.4 \pm 1.42$  ( $p = 0.003$ ). Table 1 demonstrates WI for the lungs and patients analyzed.

Table 1 - Walsh Index according to the lungs analyzed

Patients	Right Lung		Left Lung	
	Before PTF	After PTF	Before PTF	After PTF
AMA	-	-	7	6
MAG	6	4	8	4
GJFC	-	-	7	5
IAP	6	2	-	-
MJCG	4	3	7	5
LCF	-	-	6	4
ACK	6	4	-	-
NPL	7	7	-	-

In the comparative analysis before and immediately following the percutaneous procedure there was an improvement in Sat. O<sub>2</sub> [ $87.4\% \pm 1.3$  to  $92.3\% \pm 3.1$  ( $p < 0.001$ )], PAP [ $31.8 \pm 4.6$  mmHg to  $25.5 \pm 3.4$  mmHg ( $p < 0.001$ )] and SBP [ $73.9 \pm 8.7$  mmHg to  $85 \pm 8.3$  mmHg ( $p = 0.001$ )]. Figure 3 illustrates the Sat O<sub>2</sub> before and after the procedure and Figure 4 demonstrates a pulmonary angiography from one of the patients in this series.

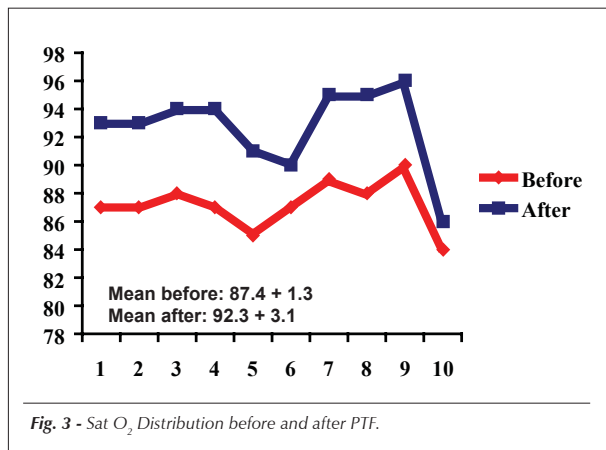


Fig. 3 - Sat O<sub>2</sub> Distribution before and after PTF.

In 9 patients (90%), RVF on the 10th day after the PTF procedure presented significant improvement (Tab. 2).

In this series, one patient died in the hospital (10% mortality). This was the only patient that did not benefit from the percutaneous therapy and was sent for classic embolectomy surgery.

There were no technical or vascular access site complications related to PTF.

The recommended prophylactic treatment for new PE was the use of coumarin based drugs for at least 12 months.

Table 2 - Comparison of right ventricular function, according to the echocardiogram before and after PTF

Patients	Before PTF	After PTF
MAG	Severe	Mild
GJFC	Severe	Normal
SD	Severe	Normal
LCF	Severe	Mild
AMA	Severe	Mild
JCA	Severe	Normal
MJCG	Severe	Normal
ACK	Severe	Mild
IAP	Severe	Mitigated
NPL	Severe	Severe

During clinical follow-up ( $18.5 \pm 14.4$  months) of the patients, the majority (80%) evolved without dyspnea or any other complaint attributed to pulmonary alterations.

## Discussion

Patients with massive PE and hemodynamic instability receive the greatest benefits from thrombolytic therapy. Right ventricular dysfunction increases the risk of death in these patients and thrombus lysis is the determining factor for survival. The risk of death was reduced by as much as five fold with endovenous thrombolytic in comparison to endovenous heparin treatment<sup>2</sup>.

The concept of percutaneous fragmentation of the thrombus situated in central pulmonary arteries, developed from studies conducted on animals<sup>6</sup>, facilitates its spontaneous or pharmacological lysis. Rode and associates performed percutaneous thrombus fragmentation on 20 patients with massive PE. The results of the study demonstrate a reduction in the Walsh index from 7.4 to 5 and improvement in the hemodynamic parameters (Tab. 3)<sup>7</sup>.

Dr. Fava's group studied 16 patients with massive PE who underwent PTF. Most (88%) were administered urokinase in the pulmonary artery. There was improvement in the Walsh index [ $13.7 \pm 1.4$  to  $6.1 \pm 2.2$  ( $p < 0.0001$ )], PAP [ $48.2 \pm 13.4$  mmHg to  $18.5 \pm 7.2$  mmHg ( $p < 0.0001$ )], SBP [ $69.9 \pm 17.8$  mmHg to  $95.6 \pm 5.3$  mmHg ( $p < 0.05$ )] and Sat O<sub>2</sub> [ $60.1 \pm 12.1$  mmHg to  $88.7 \pm 23.4$  mmHg ( $p = 0.01$ )]<sup>5</sup>.

Tajima and associates performed PTF followed by a local infusion of rTPA and thrombus aspiration in 25 patients with massive PE and hemodynamic impairment. Improvements were obtained in the Miller score [ $22.2$  to  $13.6$  ( $p < 0.01$ )] and PAP [ $32.6$  to  $23.4$  mmHg ( $p < 0.01$ )], which led the authors to propose the hybrid procedure as a therapeutic alternative for massive PE<sup>8</sup>.

In the present study, that included patients with massive PE and hemodynamic impairment, PTF improved the Walsh index [ $6.4 \pm 1.07$  to  $4.4 \pm 1.42$  ( $p = 0.003$ )], Sat O<sub>2</sub> [ $87.4 \pm 1.3$  to  $92.3$

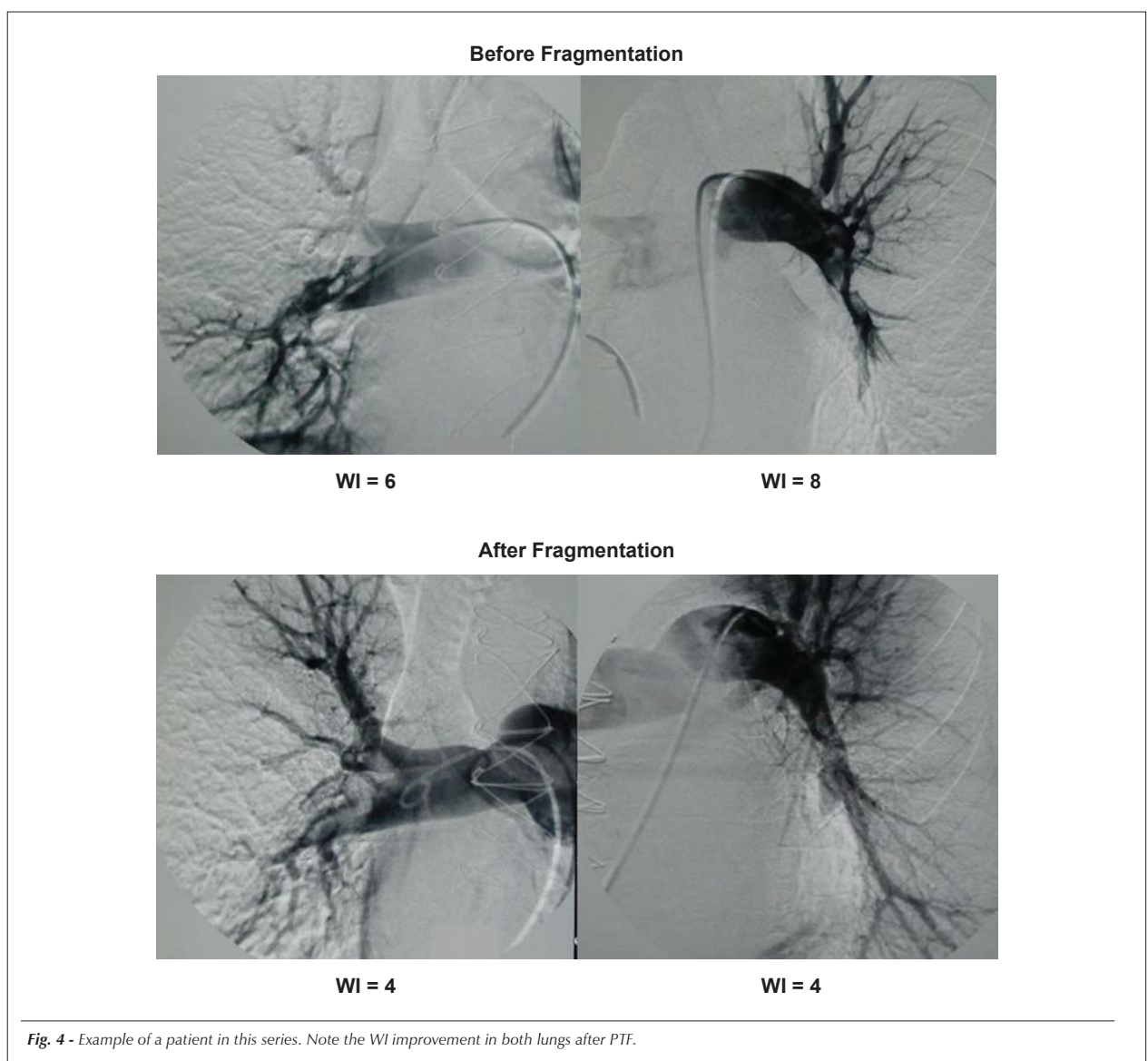


Fig. 4 - Example of a patient in this series. Note the WI improvement in both lungs after PTF.

Table 3 - Hemodynamic parameters

Variable	Before PTF	After PTF
Shock Index	1.28 ± 0.53	0.95 ± 0.38 *
Heart Rate (bpm)	124 ± 26*	111 ± 33
Mean PAP (mmHg)	31 ± 6	28 ± 8 *
Systolic PAP (mmHg)	50 ± 13	45 ± 12 *
Diastolic PAP (mmHg)	22 ± 6	18 ± 6 *
MBP (mmHg)	74 ± 16	87 ± 15 *
SBP (mmHg)	105 ± 21	122 ± 23 *
DBP (mmHg)	59 ± 15	69 ± 13 *

\*p ≤ 0,05; PAP = pulmonary artery pressure, MBP – mean blood pressure, SBP = systolic blood pressure, DBP = diastolic blood pressure.

± 3.1 (p < 0.001)), SBP [73.9 ± 8.7 mmHg to 85 ± 8.3 mmHg (p = 0.001)], PAP [31.8 ± 4.6 to 25.5 ± 3.4 (p < 0.001)] and right ventricular function. The difference between this and other studies is that PTF was not associated with the administration of local or systemic thrombolytics or thrombus aspiration.

Brady and associates performed fragmentation of a central thrombus and dispersed the fragments to the periphery of the pulmonary tree in 3 patients with massive PE and observed significant improvement in cardiac output<sup>9</sup>.

The mortality of massive PE, that determines cardiogenic shock, can reach as high as 60 to 70% in some series<sup>10</sup>. Therapies that cause thrombus lysis in the pulmonary artery tree are determining factors for better clinical evolution<sup>2</sup>. The patients in these studies presented contraindications to thrombolytics which are the therapy of choice and represent a high mortality group if the thrombus is not dissolved<sup>3</sup>. PTF was able to improve the hemodynamic parameters of the patients,

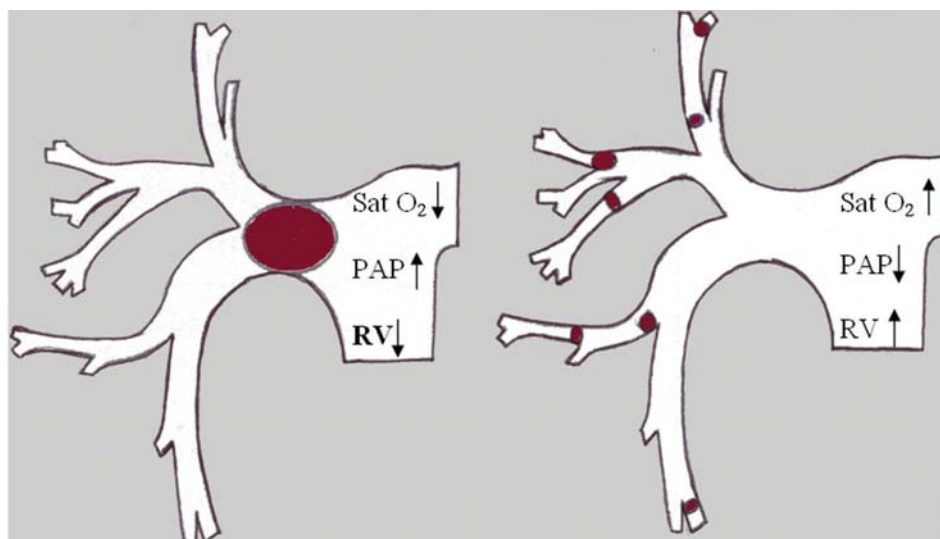


Fig. 5 - PTF Mechanism (transformation of large central embolism into various small thrombi).

which suggests possible benefits in the clinical evolution.

Fragmentation of a central thrombus and displacement of its fragments to the periphery results in an increase of non-obstructed cross sectional area in the pulmonary tree, (Fig. 5) since the cross sectional area of a 1 millimeter pulmonary artery is twice that of a central artery. For patients with severe right ventricle dysfunction, this abovementioned phenomenon that improves hemodynamics can contribute to patient survival as the increase in total thrombus surface area promoted by the percutaneous fragmentation accelerates its pharmacological and/or spontaneous lysis<sup>11</sup>.

There are catheters that were specifically designed for PTF procedures (catheters of choice) that are able to cross the thrombus with a guide wire and rotate 360° over the longitudinal axis and/or make a series of crosswise movements to dislodge the occlusion. The advantage of the standard pigtail is the lower cost when compared to other systems; however, its efficiency in pulmonary artery thrombus fragmentation is questionable. In this study the preferential use of the pigtail catheter was based on its low cost and the limited availability of the specific catheters. PTF using a pigtail catheter was associated with good efficacy and safety; however, it presented greater technical difficulty. The authors believe that the specifically designed catheters to perform the procedure are preferential owing to their technical advantages, improved efficiency and lower risk

of complications. The use of the standard pigtail is reserved for special cases.

The lack of complications related to the percutaneous technique in this and other studies in medical literature demonstrates the safety of PTF; however, due to the small number of patients studied, additional studies are required to confirm this theory.

For the patients in this study, as well as others documented in medical literature, the risk of death is high. PTF therapy, whether it is or is not associated with the administration of local or systemic thrombolytics has highly satisfactory angiographic, hemodynamic and clinical results.

We believe that PTF therapy can contribute to improved hemodynamic angiographic and clinical parameters in patients with massive PE and hemodynamic impairment; however, this therapy is still in the clinical investigation phase and therefore cannot be recommended for routine use in clinical practice. Studies that evaluate a significant number of patients and compare this technique to classic therapies are required in order to determine the real value of PTF in the treatment of massive PE.

#### Potential Conflict of Interest

No potential conflict of interest relevant to this article was reported.

## References

1. Sociedade Brasileira de Cardiologia. Diretriz de Embolia Pulmonar. Arq Bras Cardiol. 2004; 83 (supl 1): 1-8.
2. Wan S, Quinlan DJ, Agnelli GMD, Eikelboom JW. Thrombolysis compared with heparin for the initial treatment of pulmonary embolism. Circulation. 2004; 110: 744-9.
3. Goldhaber SZ. Pulmonary embolism. In: Braunwald E, Zipes DP, Libb P, Bonow RO. (eds) Heart disease: a text book of cardiovascular disease medicine. 7th ed. Philadelphia: Saunders Company; 2005. p. 1789-806.

4. Baruzzi ACA, Knobel E, Erlichman MR. Tromboembolismo pulmonar. In: Knobel E, Souza JM, Andrei AM. (eds) *Terapia intensiva em cardiologia*. São Paulo: Atheneu; 2003. p. 269-80.
5. Fava M, Loyola S, Flores P, Huete I. Mechanical fragmentation and pharmacologic thrombolysis in massive pulmonary embolism. *J Vasc Interv Radiol*. 1997; 8: 261-6.
6. Rode TS, Janssens U, Schild HH, Basch S, Hanrath P, Günther RW. Fragmentation of massive pulmonary embolism using a pigtail rotation catheter. *Chest*. 1998; 114: 1427-36.
7. Rode TS, Janssens U, Duda SH, Erley CM, Günther RW. Massive pulmonary embolism - percutaneous emergency treatment by pigtail rotation catheter. *J Am Coll Cardiol*. 2000; 36: 375-80.
8. Tajima H, Murata S, Kumazaki K, Nakazawa K, Abe Y, Komada Y, et al. Hybrid treatment of acute massive pulmonary thromboembolism- mechanical fragmentation with a modified rotating pigtail catheter, local fibrinolytic therapy, and clot aspiration followed by systemic fibrinolytic therapy. *AJR Am J Roentgenol*. 2004; 183 (3): 589-95.
9. Brady AJ, Crake T, Oakley CM. Percutaneous catheter fragmentation and distal dispersion of proximal pulmonary embolus. *Lancet*. 1991; 338: 1186-9.
10. Pinheiro BV, Carvalho EV. Tromboembolia pulmonar [on line]. (2003). Acesso em 2005 outubro 12. Disponível em: <http://www.pneumoatual.com.br>.
11. Singhal S, Henderson R, Horsfield K, Harding K, Cumming G. Morphometry of the human pulmonary arterial tree. *Circ Res*. 1973; 33: 190-7.