

Treatment of Lateral Epicondylitis

GREG W. JOHNSON, MD, KARA CADWALLADER, MD, SCOT B. SCHEFFEL, MD,
and TED D. EPPERLY, MD, *Family Medicine Residency of Idaho, Boise, Idaho*

Lateral epicondylitis is a common overuse syndrome of the extensor tendons of the forearm. It is sometimes called tennis elbow, although it can occur with many activities. The condition affects men and women equally and is more common in persons 40 years or older. Despite the prevalence of lateral epicondylitis and the numerous treatment strategies available, relatively few high-quality clinical trials support many of these treatment options; watchful waiting is a reasonable option. Topical nonsteroidal anti-inflammatory drugs, corticosteroid injections, ultrasonography, and iontophoresis with nonsteroidal anti-inflammatory drugs appear to provide short-term benefits. Use of an inelastic, nonarticular, proximal forearm strap (tennis elbow brace) may improve function during daily activities. Progressive resistance exercises may confer modest intermediate-term results. Evidence is mixed on oral nonsteroidal anti-inflammatory drugs, mobilization, and acupuncture. Patients with refractory symptoms may benefit from surgical intervention. Extracorporeal shock wave therapy, laser treatment, and electromagnetic field therapy do not appear to be effective. (*Am Fam Physician* 2007;76:843-48, 849-50; 853. Copyright © 2007 American Academy of Family Physicians.)

► **Patient information:** Handouts on tennis elbow, written by the authors of this article, are provided on pages 849 and 853.

► **See related editorial** on page 773.

Lateral epicondylitis is one of the most common overuse syndromes seen in primary care, with an annual incidence of 1 to 3 percent; the condition affects men and women equally.¹ Patients with lateral epicondylitis are typically 40 years or older and have a history of repetitive activity during work or recreation. The condition is sometimes called tennis elbow, although it often occurs with activities such as other racket sports and golf. Repetitive wrist dorsiflexion with supination and pronation causes overuse of the extensor tendons of the forearm and subsequent microtears, collagen degeneration, and angiofibroblastic proliferation. If untreated, lateral epicondylitis persists for an average of six to 24 months.²

Diagnosis

Lateral epicondylitis presents as a history of occupation- or activity-related pain at the lateral elbow. Symptoms are usually reproduced with resisted supination or wrist dorsiflexion, particularly with the arm in full extension. The pain is typically located just distal to the lateral epicondyle over the extensor tendon mass. Imaging studies are rarely required for diagnosis. Recent review articles have addressed the use of patient

history, differential diagnosis, and physical examination in the diagnosis of lateral epicondylitis.^{3,4}

Treatment

There is relatively little evidence from well-designed clinical trials to support the numerous treatment strategies employed for lateral epicondylitis. Although watchful waiting is a viable option, systematic reviews, meta-analyses, and randomized controlled trials (RCTs) have evaluated the effectiveness of other treatment options such as oral, topical, and injectable medications; physical therapy; and surgery.

WATCHFUL WAITING

One RCT found that at one year a watchful-waiting approach was comparable with physical therapy and superior to corticosteroid injection in alleviating a patient's main complaint.⁵ Patients in the watchful-waiting group visited their primary care physician once during the six-week intervention period.⁵ Avoidance of aggravating activities and practical solutions were recommended. Patients received acetaminophen or a nonsteroidal anti-inflammatory drug (NSAID), if necessary, although they were encouraged to wait for spontaneous improvement.⁵

SORT: KEY RECOMMENDATIONS FOR PRACTICE

Clinical recommendation	Evidence rating	References
The following interventions are probably helpful for lateral epicondylitis: watchful waiting, short-term topical NSAIDs, corticosteroid injection (short-term relief), exercise regimens, NSAID iontophoresis, ultrasonography.	Short-term topical NSAIDs: A Watchful waiting, corticosteroid injection, exercise regimens, NSAID iontophoresis, ultrasonography: B	5-9, 15, 19-21
The following interventions are possibly helpful: short-term oral NSAIDs; inelastic, nonarticular, proximal forearm strap (tennis elbow brace); topical nitrates; acupuncture; botulinum toxin type A injection (Botox); surgery.	Short-term oral NSAIDs, strap, topical nitrates, acupuncture, botulinum toxin type A injection: B Surgery: C	6, 7, 15-17, 20, 25, 28, 30, 31
The following interventions are unlikely to be helpful: extracorporeal shock wave therapy, laser therapy.	Extracorporeal shock wave therapy: A Laser therapy: B	7, 14, 15, 19, 20

NSAID = nonsteroidal anti-inflammatory drug.

A = consistent, good-quality patient-oriented evidence; B = inconsistent or limited-quality patient-oriented evidence; C = consensus, disease-oriented evidence, usual practice, expert opinion, or case series. For information about the SORT evidence rating system, see page 749 or <http://www.aafp.org/afpsort.xml>.

NSAIDS

Topical NSAIDs may provide short-term pain relief.^{6,7} Three studies have examined the effects of diclofenac (Solaraze) and benzydamine (not available in the United States) for up to three weeks. The median follow-up period was only two weeks, and long-term outcomes were not reported. No significant differences were found in grip strength or range of motion, and none of the studies evaluated quality of life or time to return to work.

Evidence is conflicting on the use of oral NSAIDs for lateral epicondylitis. In two studies, slow-release diclofenac (Voltaren), 150 mg daily, significantly improved short-term pain and function.^{6,7} However, there was no difference in pain between naproxen (Naprosyn), 500 mg daily, and placebo.^{6,7} Patients receiving corticosteroid injections showed greater perception of benefit at four weeks than patients receiving oral NSAIDs, but this benefit did not persist in the longer term.^{6,7}

CORTICOSTEROID INJECTION

Local corticosteroid injection has short-term (two to six weeks) benefits in pain reduction, global improvement, and grip strength compared with placebo and other conservative treatments.⁷⁻⁹ However, these benefits do not persist beyond six weeks. A study showed that, compared with an orthosis (i.e., an inelastic, nonarticular, proximal forearm strap [tennis elbow brace]), injection decreased pain at two weeks, but patient-perceived outcomes were no different at six

months.¹⁰ Several studies found that oral NSAIDs and physiotherapy have greater benefits than corticosteroid injection at intermediate-term follow-up (greater than six weeks) and long-term follow-up (greater than six months), respectively.^{5,11,12} Studies comparing various corticosteroid injections found no clinically significant differences.^{8,9} Although corticosteroid injections are effective in the short-term, their long-term effectiveness and advantages over other conservative treatments are uncertain.

EXTRACORPOREAL SHOCK WAVE THERAPY

Data do not support the use of extracorporeal shock wave therapy for the treatment of lateral epicondylitis. Although a systematic review found that the therapy was beneficial, the review included 19 case series and only one RCT.¹³ A 2005 systematic review that included nine RCTs found strong evidence against using extracorporeal shock wave therapy¹⁴; this conclusion is supported by other recent systematic reviews.^{7,15}

ORTHOSES

Despite the widespread use of orthoses, multiple systematic reviews have been unable to provide conclusions about the benefits of orthoses for lateral epicondylitis.^{7,10,15} Use of an inelastic, nonarticular, proximal forearm strap (*Figure 1*) may decrease pain and increase grip strength after three weeks.¹⁶ Bracing for up to six weeks also may improve the patient's ability to perform daily activities.¹⁷ However, conflicting evidence suggests

that straps are no better than sham bracing or other conservative therapies for lateral epicondylitis and may be inferior in the short term to corticosteroid injection and topical NSAIDs.^{15,18} Outcomes do not change significantly when an orthosis is used as an adjunct to physical therapy, ultrasonography, or corticosteroid injection.^{17,18}

LASER THERAPY

Evidence does not support the use of laser therapy for the treatment of lateral epicondylitis. A recent systematic review found that laser therapy had no effect on pain at six weeks; longer-term results were conflicting.¹⁹ Pooled data from six studies on short- and long-term outcomes show no difference between laser therapy and placebo.¹⁵ These results are reinforced by another systematic review that found evidence against the use of laser therapy alone or in conjunction with other conservative modalities.²⁰

PHYSICAL THERAPY

Table 1 summarizes the physical therapy modalities that are effective for the treatment of lateral epicondylitis.^{15,19-22}

Exercise. Physical therapy regimens, including strength training and stretching, are commonly used to treat lateral epicondylitis. Evidence suggests that exercise programs can reduce pain, but the improvement in grip strength is less clear.^{15,19,20} Regimens

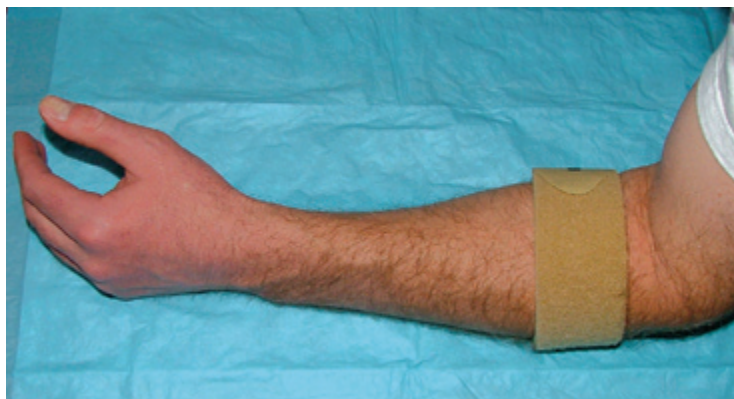


Figure 1. An inelastic, nonarticular, proximal forearm strap (tennis elbow brace) for patients with lateral epicondylitis.

should focus on eccentric instead of concentric phases. An accompanying patient handout includes exercises for lateral epicondylitis.

Electrotherapy. Electrotherapeutic modalities, including electromagnetic field therapy and iontophoresis, are also often employed to treat lateral epicondylitis. Three studies have shown pain reduction and improvement in subjective function with NSAID iontophoresis (using diclofenac or pirofen [not available in the United States]) after two to four weeks.^{15,20} There is no good evidence supporting the use of corticosteroid iontophoresis.^{15,20} One meta-analysis and one systematic review found limited evidence against the use of electromagnetic field therapy.^{5,20}

Table 1. Effective Physical Therapy Modalities for Treatment of Lateral Epicondylitis

Modality	Frequency	Duration	Comments
NSAID iontophoresis ^{15,20}	10 to 20 treatments	Two to four weeks	Studies that showed benefits used diclofenac (Solaraze) or pirofen (not available in the United States)
Stretching and strengthening exercises ^{15,19,20}	One or more times daily, three days a week	Six weeks or more	A single instructive session followed by an in-home regimen may suffice; the regimen should focus on eccentric instead of concentric phases
Ultrasonography ^{15,19-22}	Two or three times per week	Four to six weeks (eight to 18 treatments)	Augmentation with corticosteroids or deep tissue massage provides no additional benefit; ultrasonography is less effective than exercise

NSAID = nonsteroidal anti-inflammatory drug.

Information from references 15 and 19 through 22.

Ultrasonography. Ultrasonography is thought to have thermal and mechanical effects on the target tissue leading to increased metabolism, circulation, extensibility of connective tissue, and tissue regeneration.²³ The best available data suggest that ultrasonography provides modest pain reduction over one to three months.^{15,19-21} Exercise appears to be more effective than ultrasonography for pain relief.^{15,19} Combining ultrasonography with deep transverse friction massage or corticosteroids is no better than ultrasonography alone.^{15,22}

Watchful waiting is a viable approach for patients with lateral epicondylitis.

Mobilization. Deep transverse friction massage is thought to realign abnormal collagen fiber structure, break up adhesions and scar tissue, and increase healing with hyperemia.²² There is insufficient evidence to form conclusions about deep transverse friction massage for the treatment of lateral epicondylitis.²²

ACUPUNCTURE

A consensus statement from the National Institutes of Health states that study results are promising enough to consider acupuncture as an appropriate option for the treatment of lateral epicondylitis.²⁴ However, conflicting evidence exists, and recommendations for or against this therapy cannot be made. Two systematic reviews and one meta-analysis found that acupuncture leads to short-term (three days to two months) pain reduction.^{15,20,25} Two additional systematic reviews acknowledge that acupuncture might provide short-term benefit, but they conclude that there is insufficient evidence on the use of acupuncture for the treatment of lateral epicondylitis.^{7,26}

AUTOLOGOUS BLOOD INJECTION

It is hypothesized that autologous blood injections may trigger the inflammatory cascade and initiate healing of degenerative tissue via mediators in the blood or localized trauma from the injection itself. One case series, including 29 patients who had failed other conservative modalities, reported a 79 percent improvement in pain scores over

an average of 9.5 months; some patients required multiple injections.²⁷ However, clinical trials that include a comparison group receiving placebo injections are lacking, and until these trials are completed, autologous blood injections cannot be recommended.

BOTULINUM TOXIN TYPE A INJECTION

Botulinum toxin type A (Botox) is thought to facilitate healing by temporarily paralyzing the common extensor origin.^{28,29} Two small RCTs are available but have conflicting results.^{28,29} One of these studies found that botulinum toxin type A injection decreases pain scores at four and 12 weeks compared with saline injection²⁸; however, the second study found no difference between the two therapies in pain, quality of life, or grip strength at 12 weeks.²⁹ More data are needed before botulinum toxin type A injection can be recommended to treat lateral epicondylitis.

TOPICAL NITRATES

Animal studies suggest that nitric oxide stimulates collagen synthesis by wound fibroblasts and, therefore, may play a role in healing extensor tendons. One RCT suggests that topical nitrate patches may be effective in patients with lateral epicondylitis, but confirmatory studies are needed. The RCT of 86 patients compared a nitroglycerin transdermal patch with a placebo patch. The nitroglycerin patch reduced elbow pain with activity at two weeks, reduced epicondylar tenderness at six and 12 weeks, and increased wrist extensor mean peak force and total work at 24 weeks. At six months, 81 percent of treated patients were asymptomatic during activities of daily living.³⁰

SURGERY

Surgery is often recommended when conservative strategies fail to relieve lateral epicondylitis symptoms after six to 12 months. There are numerous surgical approaches, including open, percutaneous, and arthroscopic techniques. Most procedures excise abnormal tissue within the origin of the extensor carpi radialis brevis tendon at the lateral epicondyle or release the tendon altogether. Case

series have suggested favorable outcomes with few adverse effects.³¹ Despite these conclusions, no RCTs have been performed.^{7,31}

Approach to the Patient

Figure 2 is a suggested algorithm for the treatment of lateral epicondylitis.^{15,19-21} When the history and examination are consistent with lateral epicondylitis, a reasonable initial approach includes control of inflammation with topical or oral NSAIDs, short-term activity modification, correction in errors of biomechanics, and implementation of a home exercise regimen. An inelastic, non-articular, proximal forearm strap may be considered.

If symptoms persist, physical therapy, including ultrasonography, or NSAID iontophoresis may be appropriate. Short-term pain relief from corticosteroid injection may help the patient initiate physical therapy. Less contemporary strategies, including topical nitroglycerin and acupuncture, may also be considered. If symptoms continue despite numerous treatment approaches, referral may be warranted.

The Authors

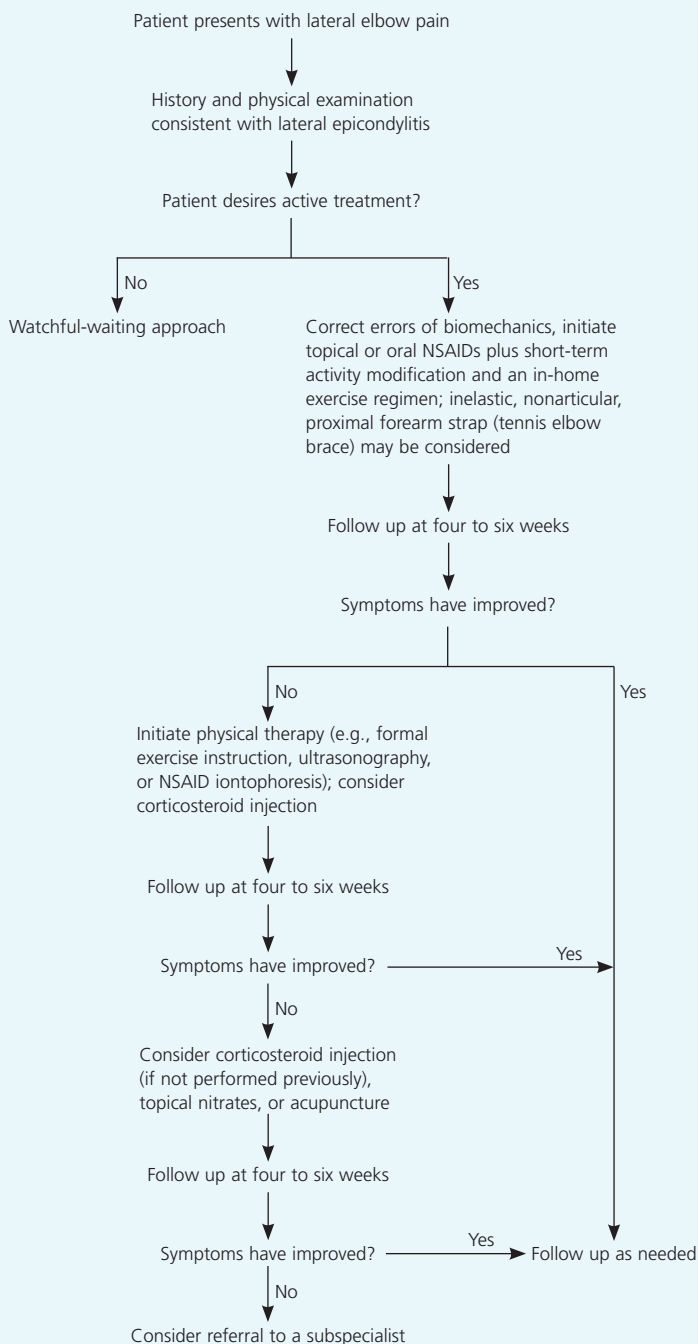
GREG W. JOHNSON, MD, is in private practice in Boise, Ida., and is a community faculty member for the Family Medicine Residency of Idaho, Boise. He received his medical degree from the University of Washington School of Medicine, Seattle. Dr. Johnson completed the Family Medicine Residency of Idaho program and its Primary Care Sports Medicine Fellowship program.

KARA CADWALLADER, MD, is a faculty member at the Family Medicine Residency of Idaho. She received her medical degree from the University of California, San Francisco, School of Medicine. Dr. Cadwallader completed the Tacoma (Wash.) Family Medicine Residency program.

SCOT B. SCHEFFEL, MD, is director of the Family Medicine Residency of Idaho's Primary Care Sports Medicine Fellowship. He received his medical degree from the University of Washington School of Medicine. Dr. Scheffel completed the Family Medicine Residency of Idaho program and its Primary Care Sports Medicine Fellowship program.

TED D. EPPERLY, MD, is chairman and program director of the Family Medicine Residency of Idaho and is a clinical professor at the University of Washington School of Medicine. He received his medical degree from the University of Washington School of Medicine and completed a family medicine residency at Madigan Army Medical Center, Fort Lewis, Wash.

Treatment of Lateral Epicondylitis



NOTE: Watchful waiting is a viable option and may be considered at any step.

Figure 2. Algorithm for the treatment of lateral epicondylitis. (NSAID = nonsteroidal anti-inflammatory drug.)

Information from references 15 and 19 through 21.

Address correspondence to Greg. W. Johnson, MD, Idaho Family Physicians, 130 E. Boise Ave., Boise, ID 83706 (e-mail: greg.johnson@fmidaho.org). Reprints are not available from the authors.

Author disclosure: Nothing to disclose.

REFERENCES

- Allander E. Prevalence, incidence, and remission rates of some common rheumatic diseases or syndromes. *Scand J Rheumatol* 1974;3:145-53.
- Hudak PL, Cole DC, Haines AT. Understanding prognosis to improve rehabilitation: the example of lateral elbow pain. *Arch Phys Med Rehabil* 1996;77:586-93.
- Wilson JJ, Best TM. Common overuse tendon problems: a review and recommendations for treatment. *Am Fam Physician* 2005;72:811-8.
- Chumbley EM, O'Connor FG, Nirschl RP. Evaluation of overuse elbow injuries. *Am Fam Physician* 2000;61:691-700.
- Smidt N, van der Windt DA, Assendelft WJ, Deville WL, Korthals-de Bos IB, Bouter LM. Corticosteroid injections, physiotherapy, or a wait-and-see policy for lateral epicondylitis: a randomised controlled trial. *Lancet* 2002;359:657-62.
- Green S, Buchbinder R, Barnsley L, Hall S, White M, Smidt N, et al. Non-steroidal anti-inflammatory drugs (NSAIDs) for treating lateral elbow pain in adults. *Cochrane Database Syst Rev* 2001;(4):CD003686.
- Assendelft W, Green S, Buchbinder R, Struijs P, Smidt N. Tennis elbow. *Clin Evid* 2004;(11):1633-44.
- Assendelft WJ, Hay EM, Adshead R, Bouter LM. Corticosteroid injections for lateral epicondylitis: a systematic overview. *Br J Gen Pract* 1996;46:209-16.
- Smidt N, Assendelft WJ, van der Windt DA, Hay EM, Buchbinder R, Bouter LM. Corticosteroid injections for lateral epicondylitis: a systematic review. *Pain* 2002;96:23-40.
- Struijs PA, Smidt N, Arola H, Dijk CN, Buchbinder R, Assendelft WJ. Orthotic devices for the treatment of tennis elbow. *Cochrane Database Syst Rev* 2002;(1):CD001821.
- Hay EM, Paterson SM, Lewis M, Hosie G, Croft P. Pragmatic randomised controlled trial of local corticosteroid injection and naproxen for treatment of lateral epicondylitis of elbow in primary care. *BMJ* 1999;319:964-8.
- Verhaar JA, Walenkamp GH, van Mameren H, Kester AD, van der Linden AJ. Local corticosteroid injection versus Cyriax-type physiotherapy for tennis elbow. *J Bone Joint Surg Br* 1996;78:128-32.
- Boddeker I, Haake M. Extracorporeal shockwave therapy in treatment of epicondylitis humeri radialis. A current overview. *Orthopade [German]* 2000;29:463-9.
- Buchbinder R, Green SE, Youd JM, Assendelft WJ, Barnsley L, Smidt N. Shock wave therapy for lateral elbow pain. *Cochrane Database Syst Rev* 2005;(4):CD003524.
- Bisset L, Paungmali A, Vicenzino B, Beller E. A systematic review and meta-analysis of clinical trials on physical interventions for lateral epicondylalgia. *Br J Sports Med* 2005;39:411-22.
- Borkholder CD, Hill VA, Fess EE. The efficacy of splinting for lateral epicondylitis: a systematic review. *J Hand Ther* 2004;17:181-99.
- Struijs PA, Kerkhoffs GM, Assendelft WJ, Van Dijk CN. Conservative treatment of lateral epicondylitis: brace versus physical therapy or a combination of both—a randomized clinical trial. *Am J Sports Med* 2004;32:462-9.
- Struijs PA, Smidt N, Arola H, van Dijk CN, Buchbinder R, Assendelft WJ. Orthotic devices for tennis elbow: a systematic review. *Br J Gen Pract* 2001;51:924-9.
- Smidt N, Assendelft WJ, Arola H, Malmivaara A, Greens S, Buchbinder R, et al. Effectiveness of physiotherapy for lateral epicondylitis: a systematic review. *Ann Med* 2003;35:51-62.
- Trudel D, Duley J, Zastrow I, Kerr EW, Davidson R, MacDermid JC. Rehabilitation for patients with lateral epicondylitis: a systematic review. *J Hand Ther* 2004;17:243-66.
- van der Windt DA, van der Heijden GJ, van den Berg SG, ter Riet G, de Winter AF, Bouter LM. Ultrasound therapy for musculoskeletal disorders: a systematic review. *Pain* 1999;81:257-71.
- Brosseau L, Casimiro L, Milne S, Robinson V, Shea B, Tugwell P, et al. Deep transverse friction massage for treating tendinitis. *Cochrane Database Syst Rev* 2002;(4):CD003528.
- Maxwell L. Therapeutic ultrasound: its effects on the cellular and molecular mechanisms of inflammation and repair. *Physiotherapy* 1992;78:421-6.
- National Institutes of Health Consensus Conference. Acupuncture. *JAMA* 1998;280:1518-24.
- Trinh KV, Phillips SD, Ho E, Damsa K. Acupuncture for the alleviation of lateral epicondyle pain: a systematic review. *Rheumatology* 2004;43:1085-90.
- Green S, Buchbinder R, Barnsley L, Hall S, White M, Smidt N, et al. Acupuncture for lateral elbow pain. *Cochrane Database Syst Rev* 2002;(1):CD003527.
- Edwards SG, Calandruccio JH. Autologous blood injections for refractory lateral epicondylitis. *J Hand Surg* 2003;28:272-8.
- Wong SM, Hui AC, Tong PY, Poon DW, Yu E, Wong LK. Treatment of lateral epicondylitis with botulinum toxin: a randomized, double-blind, placebo-controlled trial. *Ann Intern Med* 2005;143:793-7.
- Hayton MJ, Santini AJ, Hughes PJ, Frostick SP, Trail IA, Stanley JK. Botulinum toxin injection in the treatment of tennis elbow. A double-blind, randomized, controlled, pilot study. *J Bone Joint Surg Am* 2005;87:503-7.
- Paoloni JA, Appleyard RC, Nelson J, Murrell GA. Topical nitric oxide application in the treatment of chronic extensor tendinosis at the elbow: a randomized, double-blinded, placebo-controlled clinical trial. *Am J Sports Med* 2003;31:915-20.
- Buchbinder R, Green S, Bell S, Barnsley L, Smidt N, Assendelft WJ. Surgery for lateral elbow pain. *Cochrane Database Syst Rev* 2002;(1):CD003525.