

# Triage strategy for urgent management of cardiac tamponade: a position statement of the European Society of Cardiology Working Group on Myocardial and Pericardial Diseases

**Arsen D. Ristić<sup>1†</sup>, Massimo Imazio<sup>2†\*</sup>, Yehuda Adler<sup>3</sup>, Aristides Anastasakis<sup>4</sup>, Luigi P. Badano<sup>5‡</sup>, Antonio Brucato<sup>7</sup>, Alida L. P. Caforio<sup>6</sup>, Olivier Dubourg<sup>8‡</sup>, Perry Elliott<sup>9</sup>, Juan Gimeno<sup>10</sup>, Tiina Helio<sup>11</sup>, Karin Klingel<sup>12</sup>, Aleš Linhart<sup>13</sup>, Bernhard Maisch<sup>14</sup>, Bongani Mayosi<sup>15‡</sup>, Jens Mogensen<sup>16,17</sup>, Yigal Pinto<sup>18</sup>, Hubert Seggewiss<sup>19</sup>, Petar M. Seferović<sup>1</sup>, Luigi Tavazzi<sup>20</sup>, Witold Tomkowski<sup>21</sup>, and Philippe Charron<sup>22</sup>**

<sup>1</sup>Department of Cardiology, Clinical Center of Serbia and Belgrade University School of Medicine, Belgrade, Serbia; <sup>2</sup>Department Cardiology, Maria Vittoria Hospital, Via Luigi Cibrario 72, Turin 10141, Italy; <sup>3</sup>Chaim Sheba Medical Center, Tel Hashomer and Sackler University, Tel Aviv, Israel; <sup>4</sup>Unit of Inherited Cardiovascular Diseases, 1st Department of Cardiology, Athens University Medical School, Athens, Greece; <sup>5</sup>Department of Cardiac, Thoracic and Vascular Sciences, University of Padua, School of Medicine, Padua, Italy; <sup>6</sup>Division of Cardiology, Department of Cardiological, Thoracic and Vascular Sciences, Centro 'V. Gallucci', University of Padova-Policlinico, Padua, Italy; <sup>7</sup>Division of Internal Medicine, Ospedale Papa Giovanni XXIII, Bergamo, Italy; <sup>8</sup>AP-HP Hospital Ambroise Paré, UFR des Sciences de la Santé Simone Veil, UVSQ; <sup>9</sup>The Heart Hospital, University College London Hospitals Trust, London, UK; <sup>10</sup>Department of Cardiology, University Hospital Virgen de Arrixaca, Murcia, Spain; <sup>11</sup>Division of Cardiology, Department of Medicine, Helsinki University Central Hospital, Meilahti Hospital, Helsinki, Finland; <sup>12</sup>Department of Molecular Pathology, Institute for Pathology, University Hospital Tübingen, Germany; <sup>13</sup>Second Department of Medicine, Department of Cardiovascular Medicine, General University Hospital and the First Faculty of Medicine, Charles University, Prague, Czech Republic; <sup>14</sup>Department of Internal Medicine-Cardiology, Universitätsklinikum Gießen and Marburg GmbH, Philipps University, Marburg, Germany; <sup>15</sup>Department of Medicine, Groote Schuur Hospital, Cape Town, South Africa; <sup>16</sup>Department of Cardiology, Odense University Hospital, Odense, Denmark; <sup>17</sup>Faculty of Health Sciences, Institute of Clinical Research, University of Southern Denmark, Denmark; <sup>18</sup>Department of Cardiology, Academic Medical Centre, Amsterdam, The Netherlands; <sup>19</sup>Medical Department 1, Leopoldina Hospital, Schweinfurt, Germany; <sup>20</sup>Maria Cecilia Hospital—GVM Care and Research, Ettore Sansavini Health Science Foundation, Cotignola, Italy; <sup>21</sup>Cardio-Pulmonary Intensive Care, Division at the National Tuberculosis and Lung Diseases Research Institute, Warsaw, Poland; and <sup>22</sup>Université de Versailles-Saint Quentin, Hopital Pitié-Salpêtrière, Paris, France

Received 18 July 2013; revised 24 February 2014; accepted 3 May 2014; online publish-ahead-of-print 7 July 2014

## Introduction

Prompt recognition of cardiac tamponade is critical since the underlying haemodynamic disorder can lead to death if not resolved by percutaneous or surgical drainage of the pericardium. Cardiac tamponade is a condition caused by the compression of the heart due to slow or rapid accumulation of fluid (exudate), pus, blood, clots, or gas within the pericardial space resulting in impaired diastolic filling and cardiac output due to increased intrapericardial pressure.<sup>1–3</sup>

Pericardial diseases of any aetiology may cause cardiac tamponade, but with highly variable incidence reflecting the local epidemiological background (Table 1).<sup>3–6</sup> However, all interventional procedures

(i.e. percutaneous coronary intervention, transcatheter aortic valve implantation, pacemaker/implantable cardioverter defibrillator implantation, arrhythmias ablation, endomyocardial biopsy) are emerging causes of cardiac tamponade.<sup>7</sup> Although rare, cardiac tamponade may also occur in pregnancy and in post-partum.<sup>8,9</sup> Thus cardiologists should be aware of this possibility including specific contraindications for pregnancy (i.e. avoid the use of colchicine and X-ray exposure using echo-guided procedure).<sup>13,14</sup>

Management of cardiac tamponade can be challenging because of the lack of the validated criteria for the risk stratification that should guide clinicians in the decision-making process: (i) which patients need immediate drainage of the pericardial effusion? (ii) Is echocardiography sufficient for guidance of pericardiocentesis or

The opinions expressed in this article are not necessarily those of the Editors of the *European Heart Journal* or of the European Society of Cardiology.

\* Corresponding author. Tel: +39 (0)11 4393391; fax: +39 (0)11 4393334, E-mail: [massimo\\_imazio@yahoo.it](mailto:massimo_imazio@yahoo.it)

† Contributed equally to this statement as the coordinator and the leader of the Study group on pericardial diseases of the European Society of Cardiology Working group on Myocardial and Pericardial Diseases.

‡ Contributed as Internal Reviewers.

Published on behalf of the European Society of Cardiology. All rights reserved. © The Author 2014. For permissions please email: [journals.permissions@oup.com](mailto:journals.permissions@oup.com).

**Table 1** Causes of pericardial disease and precipitating factors causing cardiac tamponade

Likely to progress to cardiac tamponade
Neoplastic diseases
Infections (i.e. viral: EBV, CMV enteroviruses, HIV, bacterial, especially tuberculosis)
Iatrogenic hemopericardium
Post-traumatic pericardial effusion
Post-cardiotomy syndrome
Hemopericardium in aortic dissection and rupture of the heart after acute myocardial infarction
Renal failure
Rarely progressing to cardiac tamponade
Systemic autoimmune disease
Autoreactive pericardial effusions
Hypo- or hyperthyreosis
Early and late pericarditis (Dressler's syndrome) in acute myocardial infarction
Any other aetiology of pericardial disease (i.e. cholesterol pericarditis, chylopericardium)
Never progressing to cardiac tamponade
Pericardial transudates caused by heart failure or pulmonary hypertension
Pericardial transudates in the last trimester of normal pregnancy
Precipitating factors
Drugs
Antihypertensive medications
Anticoagulants, thrombolytics, etc.
Injury
Complex PCI
Pacemaker implantation
Endomyocardial biopsy
Recent cardiac surgery
Indwelling instrumentation
Blunt chest trauma
Septicaemia
Dehydration, diuretics (reduced circulating volume)

should patient be taken to the cardiac catheterization laboratory? (iii) Who should be transferred to specialized/tertiary institution or surgical service? (iv) What type of medical support is necessary during transportation?

Current European guidelines published in 2004 by the European Society of Cardiology<sup>3</sup> do not cover these issues and no additional guidelines are available from major medical and Cardiology societies. Therefore, the aim of this position statement is to provide updated, evidence-based recommendations, when available, for triage and clinical management of patients with cardiac tamponade.

## Clinical diagnosis

Cardiac tamponade includes a haemodynamic spectrum ranging from incipient or preclinical tamponade (pericardial pressure equals right atrial pressure but it is lower than left atrial pressure)

to haemodynamic shock with significant reduction of stroke volume, blood pressure, and evident pulsus paradoxus (when pericardial pressure is higher than 10–12 mmHg and in the presence of compression of right heart chambers).<sup>1–3</sup> A detailed discussion on diagnostic issues, differential diagnosis, and available pertinent literature for this condition is included in Supplementary material online, *file*.

### Recommendation (clinical diagnosis)

- (1) Cardiac tamponade should be suspected in patients presenting with hypotension, jugular venous distension, pulsus paradoxus, tachycardia, tachypnea, and/or severe dyspnoea;
- (2) Additional signs may include low QRS voltages, electrical alternans, enlarged cardiac silhouette on chest X-ray.

### Recommendation (imaging)

- (1) Echocardiography is the diagnostic method of choice in suspected cardiac tamponade and should be carried out without delay.
- (2) CT and CMR are not part of the routine evaluation of patients with suspected cardiac tamponade; they are useful to rule out concomitant diseases involving the mediastinum and lungs in patients with large pericardial effusions (i.e. cancer or aortic dissection).

### Recommendation (differential diagnosis)

- (1) Differential diagnosis should include constrictive pericarditis, congestive heart failure, and advanced liver disease with cirrhosis.

## Scoring system, triage, and management of cardiac tamponade

### Immediate drainage of pericardial effusion in cardiac tamponade: indications, contraindications, and the scoring system

Urgent pericardiocentesis or drainage of pericardial effusion is indicated for each patient with established diagnosis of cardiac tamponade and haemodynamic shock. The decision to drain an effusion and to do it immediately, urgently, or schedule the procedure electively must take into account the clinical presentation, changes in the haemodynamic status over time (in the range of several minutes to several hours depending on the aetiology), the risk–benefit ratio of the procedure, and the echocardiographic findings. Aortic dissection and post-infarction rupture of the free wall are indications for urgent surgical drainage that should not be delayed in any way by pericardiocentesis (percutaneous drainage of pericardial effusion).<sup>4</sup> If the surgical management of the aortic dissection is not promptly available or the patient is too unstable to survive the transfer to surgery, pericardiocentesis and controlled pericardial drainage of very small amounts of the hemopericardium can be attempted to temporarily stabilize the patient.<sup>10</sup> Pericardiocentesis is especially recommended when a purulent, tuberculous, or neoplastic pericarditis is suspected, or in patients, who remain symptomatic, despite medical treatment.<sup>3,6,11,12</sup> Due to the high incidence of tamponade (about

one-third) during the follow-up of large effusions ( $>20$  mm) without cardiac tamponade,<sup>13</sup> planning elective drainage is reasonable in such patients. Pericardial drainage may not be necessary when the effusion is larger, there is no haemodynamic impairment, and it resolves spontaneously or under anti-inflammatory treatment.<sup>3,11,12</sup> Since cardiac tamponade can develop slowly, and the symptoms and signs are neither highly sensitive nor specific, Halpern *et al.*<sup>14</sup> introduced a scoring index to guide the decision for pericardial drainage, based on effusion size, echocardiographic assessment of haemodynamics, and clinical factors. On the basis of currently available data, and the consensus of experts, we propose a new stepwise scoring system for the triage of patients requiring pericardiocentesis (Figure 1). The scoring system should be applied for the triage cardiac tamponade without haemodynamic shock, where immediate pericardiocentesis is mandatory and life-saving.

### Recommendation (indication for drainage)

- (1) Pericardial drainage is indicated for each case with established diagnosis of cardiac tamponade. If the patient is haemodynamically stable, the procedure should be performed within 12–24 h from diagnosis, after obtaining laboratory results including the blood counts.
- (2) Indications for urgent surgical treatment of cardiac tamponade include hemopericardium due to type A aortic dissection, ventricular free wall rupture in acute myocardial infarction, trauma, or purulent effusion in unstable septic patients, and loculated effusions that cannot be managed percutaneously.
- (3) In patients with cardiac tamponade, a stepwise scoring system may be useful for the triage of patients (Figure 1). A total score  $\geq 6$  warrants immediate pericardiocentesis in the absence of contraindications. In rapidly deteriorating patients with iatrogenic hemopericardium or any other very unstable patient, pericardial drainage should be performed without any delay for laboratory tests but treating anticoagulation (protamine), prolonged INR (fresh frozen plasma), and/or anaemia (plasma-free blood transfusion) simultaneously with the drainage of the pericardium.

### Indications to transfer the patients to a specialized or tertiary institution

If cardiac tamponade is diagnosed in a local hospital or primary care facility with limited experience in the drainage of pericardial effusion or in the presence of any of the contraindications (uncorrected coagulopathy, ongoing anticoagulant therapy with INR  $>1.5$ , thrombocytopenia  $<50\,000/\text{mm}^3$ , small, posterior, and/or loculated effusions), and the patient is clinically stable to allow pericardiocentesis be delayed, the patient should be promptly transferred to a specialized institution accompanied by a physician. During the transportation, the patient should be protected from heat and dehydration, and spared from any unnecessary stress. ECG and blood pressure monitoring should be performed throughout the transfer time. If the patient is clinically unstable and pericardiocentesis cannot be delayed, then emergency pericardiocentesis becomes a life-saving procedure and should be performed under echo guidance.<sup>15</sup>

### Selection of the percutaneous vs. surgical technique, in the absence of specific indications for surgery

If the pericardial effusion cannot be reached by a needle or a catheter, surgical drainage is required, usually through a subcostal incision. Furthermore, surgical drainage is desirable in patients with purulent pericardial fluid, intrapericardial bleeding, and in those with clotted hemopericardium or thoracic conditions that make pericardiocentesis difficult or ineffective. Open surgical drainage has the additional benefit of resecting a portion of the pericardium for histological examination, breaking up loculations, evacuation of haematoma, and placing a large drainage tube, which is especially important in purulent pericarditis.<sup>4</sup>

Limited data are available on the comparison between the two techniques. The disadvantages of the open surgical procedures remain general anaesthesia (risk of sudden hypotension in patients with large effusions/cardiac tamponade), a need to perform a 6- to 8-cm vertical incision in the upper abdomen as well as to resect the xiphoid process in some cases. The advantage of the open surgical procedure over pericardiocentesis in enabling large pericardial samples for pathohistological examination is currently reduced by the introduction of pericardial and epicardial biopsy using flexible percutaneous pericardioscopy.<sup>16,17</sup>

### Approach and the guidance for pericardiocentesis

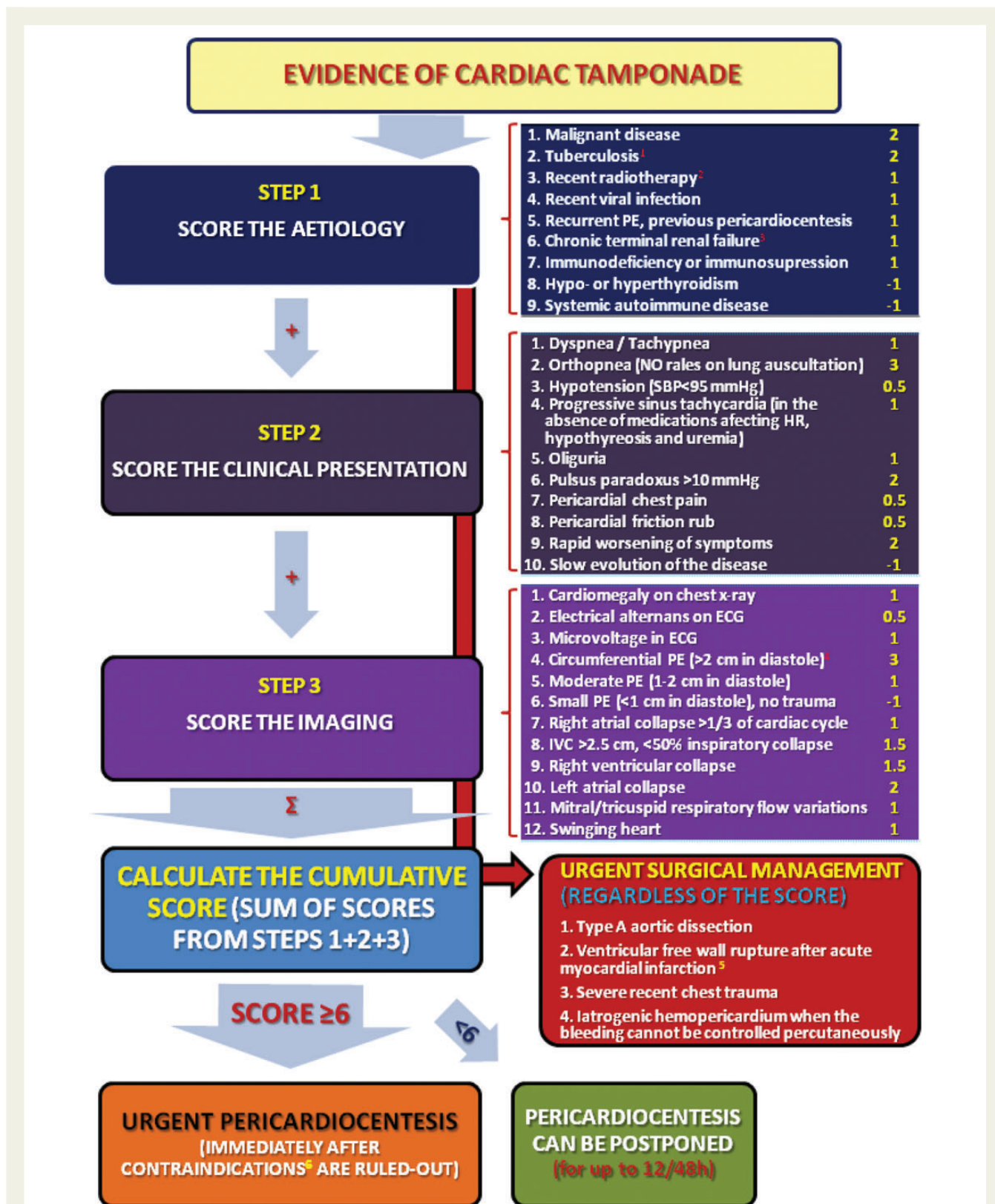
Pericardiocentesis was performed for decades as a 'blind' procedure, almost exclusively from the subxiphoid area, which remained the most frequently used method. Currently however, echocardiography is widely available and except in very rare urgent cases with clear diagnosis (e.g. complications of interventional procedures), pericardiocentesis should not be attempted without echocardiographic guidance. Echocardiography should identify distribution and size of the effusion. The most useful location for pericardiocentesis is the one closest to the largest amount of the effusion, and therefore echocardiography identifies the most suitable approach for pericardiocentesis (in most patients subxiphoid or apical). Nowadays, pericardiocentesis should not be performed as a blind procedure.<sup>15</sup>

Urgent pericardiocentesis can be safely and successfully performed as a simple echo-guided procedure or the patient can be taken to the catheterization laboratory and fluoroscopy (real-time) guidance be added to the orientation initially obtained by echocardiography (Supplementary material online, Movies S3 and S4). Depending on the distribution of the effusion, it can be drained percutaneously using the intercostal (apical) or subxiphoid approach or surgically in the presence of massive adhesions or contraindications for pericardiocentesis. A pig-tail catheter should be inserted for drainage of the effusion; if this tool is not available in an emergency setting, a standard 7F central venous catheter can be used. Recently, Huang *et al.*<sup>18</sup> emphasized the importance of early diagnosis and rescue pericardiocentesis for acute cardiac tamponade during radiofrequency ablation, using the fluoroscopic heart silhouette characteristics associated with cardiac tamponade and fluoroscopy-guided pericardiocentesis.

**Recommendation (guidance for pericardiocentesis)**

(1) Echocardiography is mandatory to guide pericardiocentesis and select the approach (intercostal vs. subxiphoid), except in case of life-threatening tamponade.

(2) Fluoroscopy can be considered for early diagnosis and rescue pericardiocentesis especially for iatrogenic effusions after specific interventional techniques (i.e. radiofrequency ablation, other percutaneous interventions), although echocardiography should be immediately available as well.



## How to prevent complications

Utilization of echocardiography with or without additional fluoroscopy is mandatory for safe and successful pericardiocentesis. During the procedure, the injection of agitated saline solution with a small amount of air microbubbles in the pericardial sac can confirm the correct placement of the catheter. When a cardiac chamber is perforated, the perforating catheter should not be removed until the fluid is drained and the pericardial sac is secured with another catheter in case the perforation can cause increased bleeding into the pericardium.<sup>16</sup> Depending on the type, size, and location of the cardiac lesion, if percutaneous puncture and drainage are successful, the perforating catheter can be withdrawn and surgery avoided by prompt drainage and autotransfusion of pericardial blood. However, if the patient is still unstable, surgical repair should not be further deferred.

Even in medical emergencies, strict aseptic and antiseptic conditions have to be maintained during pericardiocentesis. The routine part of the preparation for the procedure should include, whenever possible, a basic laboratory screen, especially taking care of the coagulation status. In the presence of severe coagulation disorders, pericardiocentesis has to be postponed until sufficient blood for transfusion, platelets, or coagulation factors are provided.

Although pericardiocentesis is usually well-tolerated, pulmonary oedema, circulatory collapse, and acute RV and LV dysfunction have been reported after drainage. Vagal reactions are also possible complications that may require prompt treatment with i.v. atropine and fluids. Large volume pericardiocentesis can be followed by transient severe acute LV systolic failure in the absence of any prior history of LV dysfunction. During pericardiocentesis, rapid evacuation of more than 1 L effusion should be avoided and prolonged catheter drainage may be considered until pericardial fluid return is <20–30 mL/day.<sup>3,19</sup> All patients, especially those with underlying cardiac disease, including myocarditis, should be monitored for post-drainage decompensation.

The most serious complications of pericardiocentesis are the laceration and perforation of the myocardium and the coronary vessels. In order to prevent laceration, no lateral movements of the needle should be made while approaching the effusion. As soon as the tip of the needle is in the pericardial space, a soft-tip J guidewire should be promptly inserted. In addition, patients can experience air embolism, pneumothorax, arrhythmias (usually vasovagal bradycardia), and puncture of the peritoneal cavity or abdominal viscera. In-

ternal mammary artery fistulas, acute pulmonary oedema, and purulent pericarditis have been also reported.<sup>16</sup>

In the Marburg experience of pericardiocentesis performed under fluoroscopic control ( $n = 234$  patients), there was no mortality and the incidence of major complications was significantly reduced by using the epicardial halo phenomenon and the tangential approach in the lateral view. Major complications included three cases (1.3%) of cardiac perforation or arterial bleeding (none requiring surgery but all could be solved by autotransfusion), one major vagal reaction (0.4%), but no pneumothorax.<sup>17</sup>

## Prolonged drainage of the effusion and prevention of recurrences

Rafique *et al.*<sup>19</sup> confirmed in 157 consecutive patients that prolonged pericardial drainage significantly reduced the recurrence rate of cardiac tamponade (12% in patients with vs. 52% in patients without extended drainage). Absence of prolonged drainage, incomplete drainage of pericardial effusion, loculated effusion, and malignancy independently correlated with recurrence of cardiac tamponade at 1 year. Prolonged pericardial drainage has been especially recommended for the management of neoplastic effusions, in order to prevent recurrence. Expert opinion supports application of the technique for idiopathic effusions. When indicated, prolonged drainage is performed until the volume of effusion obtained by intermittent pericardial aspiration (every 4–6 h) falls to <25–30 mL per day.<sup>3,19</sup> During prolonged drainage, bacterial infection prevention by empiric antibiotic prophylaxis is controversial since the risk is considered very low with appropriate antiseptic procedures.

### Recommendation (prolonged drainage)

- (1) Drainage of more than 1 L effusion from the pericardial space should be avoided and prolonged catheter drainage should be provided for the remaining effusion.
- (2) Prolonged pericardial drainage can be discussed in selected cases, especially for the management of neoplastic effusions, in order to prevent recurrence of tamponade.

### Recommendations for training

Pericardial drainage is a technically demanding and potentially dangerous procedure that should be routinely performed only by skilled physicians. Emergency pericardiocentesis is a life-saving procedure and each cardiologist working in hospitals, especially with

**Figure 1** A proposed three-step scoring system for the triage of patients requiring urgent percutaneous or surgical drainage of pericardial effusion. Diagnosis of cardiac tamponade is based on the integration of clinical symptoms, signs, and echo findings. Total score  $\geq 6$  indicates urgent pericardiocentesis in the absence of contraindications. Urgent surgical treatment of cardiac tamponade is recommended, regardless of the score, in type A aortic dissection, ventricular free wall rupture after acute myocardial infarction, severe recent chest trauma, and iatrogenic hemopericardium when the bleeding cannot be controlled percutaneously. PE, pericardial effusion; SBP, systolic blood pressure; HR, heart rate; IVC, inferior caval vein.<sup>1</sup>An optional shortcut through the scoring system for the areas of the world with endemic tuberculosis has been previously proposed (64). In this setting, urgent pericardiocentesis is recommended if the following clinical and echo criteria are met: (1) heart rate > 90 bpm, (2) systolic blood pressure < 100 mmHg, (3) pulsus paradoxus, (4) jugular venous pressure > 4 cm plus echo confirmation of circumferential pericardial effusion measuring > 1 cm anterior to the right ventricle in the subcostal view and any of the following echo criteria: (a) swinging heart, (b) RV or LV diastolic collapse, (c) > 25% variation in mitral and tricuspid flow velocities with respiration.<sup>2</sup>Radiotherapy involving the mediastinal area.<sup>3</sup>Terminal renal failure regardless of the dialysis.<sup>4</sup>Scores 4–12 in step 3 are obtained during echocardiography.<sup>5</sup>Pericardial effusion > 1 cm in diastole in the first week after a large acute myocardial infarction.<sup>6</sup>In the absence of uncorrected coagulopathy, anticoagulant therapy with INR > 1.5, thrombocytopenia < 50 000/mm<sup>3</sup>, small, posterior, and loculated effusions, or effusions resolving under anti-inflammatory treatment.

Emergency Departments, should be able to perform it properly, thus appropriate training should be planned.

We propose that a minimum of five pericardiocentesis procedures should be incorporated in the training curriculum for specialization in cardiology or emergency medicine.<sup>20</sup>

## Conclusions

A new step-wise scoring system has been proposed in this statement to provide additional support to clinicians about the selection of high-risk patients that would need an immediate intervention and of those patients that should be transferred to specialized institutions. Definitive treatment is pericardiocentesis or surgical drainage of pericardial effusion that are life-saving procedures. Further prospective validation of the proposed management strategy is warranted.

## Supplementary material

Supplementary material is available at *European Heart Journal* online.

**Conflict of interest:** none declared.

## References

- Spodick DH. Acute cardiac tamponade. *N Engl J Med* 2003;**349**:684–690.
- Shabetai R. Pericardial effusion: haemodynamic spectrum. *Heart* 2004;**90**:255–256.
- Imazio M, Adler Y. Management of pericardial effusion. *Eur Heart J* 2013;**34**:1186–1197.
- Maisch B, Seferović PM, Ristić AD, Erbel R, Rienmüller R, Adler Y, Tomkowski WZ, Thiene G, Yacoub MH; Task Force on the Diagnosis and Management of Pericardial Diseases of the European Society of Cardiology. Guidelines on the diagnosis and management of pericardial diseases executive summary; The Task force on the diagnosis and management of pericardial diseases of the European society of cardiology. *Eur Heart J* 2004;**25**:587–610.
- Hoit BD. Pericardial disease and pericardial tamponade. *Crit Care Med* 2007;**35**:S355–S364.
- Imazio M, Cecchi E, Demichelis B, Ierna S, Demarie D, Ghisio A, Pomari F, Coda L, Belli R, Trincherio R. Indicators of poor prognosis of acute pericarditis. *Circulation* 2007;**115**:2739–2744.
- Imazio M, Hoit BD. Post-cardiac injury syndromes. An emerging cause of pericardial diseases. *Int J Cardiol* 2013;**168**:648–652.
- Ristić AD, Seferović PM, Ljubić A, Jovanović I, Ristić G, Pankuweit S, Ostojčić M, Maisch B. Pericardial disease in pregnancy. *Herz* 2003;**28**:209–215.
- Imazio M, Brucato A, Rampello S, Armellino F, Trincherio R, Spodick DH, Adler Y. Management of pericardial diseases during pregnancy. *J Cardiovasc Med (Hagerstown)* 2010;**11**:557–562.
- Hayashi T, Tsukube T, Yamashita T, Haraguchi T, Matsukawa R, Kozawa S, Ogawa K, Okita Y. Impact of controlled pericardial drainage on critical cardiac tamponade with acute type A aortic dissection. *Circulation* 2012;**126**(11 Suppl. 1):S97–S101.
- Imazio M, Spodick DH, Brucato A, Trincherio R, Adler Y. Controversial issues in the management of pericardial diseases. *Circulation* 2010;**121**:916–928.
- Imazio M, Mayosi BM, Brucato A, Markel G, Trincherio R, Spodick DH, Adler Y. Triage and management of pericardial effusion. *J Cardiovasc Med (Hagerstown)* 2010;**11**:928–935.
- Sagrìstà-Sauleda J, Angel J, Permanyer-Miralda G, Soler-Soler J. Long-term follow-up of idiopathic chronic pericardial effusion. *N Engl J Med* 1999;**341**:2054–2059.
- Halpern DG, Argulian E, Briasoulis A, Chaudhry F, Aziz EF, Herzog E. A novel pericardial effusion scoring index to guide decision for drainage. *Crit Pathw Cardiol* 2012;**11**:85–88.
- Silvestry FE, Kerber RE, Brook MM, Carroll JD, Eberman KM, Goldstein SA, Herrmann HC, Homma S, Mehran R, Packer DL, Parisi AF, Pulerwitz T, Seward JB, Tsang TS, Wood MA. Echocardiography-guided interventions. *J Am Soc Echocardiogr* 2009;**22**:213–231; quiz 316–7. Erratum in: *J Am Soc Echocardiogr* 2009;**22**:336.
- Maisch B, Ristić AD, Seferović PM, Tsang TS. *Interventional Pericardiology: Pericardiocentesis, Pericardioscopy, Pericardial Biopsy, Balloon Pericardiotomy, and Intrapericardial Therapy*. Springer Medizin Verlag, Heidelberg, 2011.
- Maisch B, Rupp H, Ristić AD, Pankuweit S. Pericardioscopy and epic- and pericardial biopsy—a new window to the heart improving etiological diagnoses and permitting targeted intrapericardial therapy. *Heart Fail Rev* 2013;**18**:317–328.
- Huang XM, Hu JQ, Zhou F, Qin YW, Cao J, Zhou BY, Zhao XX, Zheng X. Early diagnosis and rescue pericardiocentesis for acute cardiac tamponade during radiofrequency ablation for arrhythmias. Is fluoroscopy enough? *Pacing Clin Electrophysiol* 2011;**34**:9–14.
- Rafique AM, Patel N, Biner S, Eshaghian S, Mendoza F, Cercek B, Siegel RJ. Frequency of recurrence of pericardial tamponade in patients with extended versus nonextended pericardial catheter drainage. *Am J Cardiol* 2011;**108**:1820–1825.
- European Society of Cardiology; Committee for Education; Authors/Task Force Members; Gillebert TC, Brooks N, Fontes-Carvalho R, Fras Z, Gueret P, Lopez-Sendon J, Salvador MJ, van den Brink RB, Smiseth OA; Observer on behalf of the UEMS (Cardiology Section); Griebenow R; Review Coordinators; Kearney P, Vahanian A; Contributors and reviewers: Bauersachs J, Bax J, Burri H, Caforio AL, Calvo F, Charron P, Ertl G, Flachs-kampf F, Giannuzzi P, Gibbs S, Gonçalves L, González-Juanatey JR, Hall J, Herpin D, Iaccharino G, Iung B, Kitsiou A, Lancellotti P, McDonough T, Monsuez JJ, Nuñez JJ, Plein S, Porta-Sánchez A, Priori S, Price S, Regitz-Zagrosek V, Reiner Z, Ruilope LM, Schmid JP, Simes PA, Sousa-Ouva M, Stepinska J, Szymanski C, Taggart D, Tenders M, Tokgözoğlu L, Trindade P, Zeppenfeld K; ESC staff; Joubert L, Carrera C. ESC Core Curriculum for the General Cardiologist (2013). *Eur Heart J* 2013;**34**:2381–2411.