



Trismus Due to Bilateral Coronoid Hyperplasia

Moon Gi Choi, Dong Hyuck Kim, Eun Jung Ki, Hae Myung Cheon

Department of Oral and Maxillofacial Surgery, Wonkwang University Dental Hospital

Abstract

Bilateral coronoid hyperplasia causes painless progressive trismus, resulting from coronoid process impingement on the posterior aspect of the zygomatic bone. The etiology of coronoid hyperplasia is unclear, with various theories proposed. An endocrine stimulus, increased temporalis activity, trauma, genetic inheritance and familial occurrence have all been proposed, but no substantive evidence exists to support any of these hypotheses. Multiplanar reformatting of axial scans and 3-dimensional reconstruction permit precise reproduction of the shape and size of the coronoid and malar structures, and relationships of all structures of the temporal and infratemporal fossae. This case shows remarkably increased mouth opening by coronoidectomy in a patient who complained of trismus due to hyperplasia of coronoid process.

Key words: Mandible, Trismus, Hyperplasia

Introduction

Coronoid hyperplasia appears clinically as a slow but progressive reduction in mandibular opening resulting from contact of the enlarged coronoid process with temporal surface of the malar bone, or with medial surface of the zygomatic arch[1].

The most common symptom of bilateral coronoid hyperplasia is limitation of mandibular opening[2]. Other clinical features described by Rowe[3] include absence of pain, no occlusal abnormality, infringement of the coronoid process on the posterior aspect of the zygomatic process, and a predilection for males.

This study is a case of trismus due to bilateral hyperplasia of the coronoid process, treated by coronoidectomy, and resulting in remarkably increased mouth opening.

Case Report

A 31-year-old Asian male visited the Department of Oral and Maxillofacial Surgery for evaluation of restricted mandibular opening. Maximal effort produced 20 mm of vertical interincisal opening, which could not be increased by external force. The extent of right and left excursions and protrusion was 4 mm. The patient's main complaints was limited mouth opening, and he did not report pain. The limitation of mouth opening started when the patient was a middle school student, but he could not remember the exact time. The amount of mouth opening continued to decrease over time. Initially, he could eat anything, but now he cannot eat large volume food due to trismus. He denied a familial history of trismus and previous trauma to head and neck area. The patient was otherwise healthy

RECEIVED November 27, 2013, REVISED April 21, 2014, ACCEPTED July 23, 2014

Correspondence to Moon Gi Choi

Department Oral and Maxillofacial Surgery, Wonkwang University Dental Hospital
895 Muwang-ro, Iksan 570-711, Korea
Tel: 82-63-859-2921, Fax: 82-63-857-4002, E-mail: omschoi@wonkwang.ac.kr

Copyright © 2014 by The Korean Association of Maxillofacial Plastic and Reconstructive Surgeons. All rights reserved.

© This is an open access article distributed under the terms of the Creative Commons Attribution Non-Commercial License (<http://creativecommons.org/licenses/by-nc/3.0>) which permits unrestricted non-commercial use, distribution, and reproduction in any medium, provided the original work is properly cited.

and past medical history was non-specific. Laboratory findings were normal. There was no temporomandibular joint (TMJ) pain or tenderness and no muscular tenderness or spasm.

Panoramic X-ray showed elongation of right and left coronoid process. On 3-dimensional computed tomography (3D CT) scan, the enlarged coronoid process overlay the zygomatic process and blocked mouth opening when the patient opened his mouth to approximately 20 mm (Fig. 1, 2). Radiographs of the TMJ showed normal findings. A diagnosis of bilateral coronoid hyperplasia was confirmed from clinical and radiographic examinations.

The patient was admitted to the Department of Oral and Maxillofacial Surgery after one week and surgery was performed. Anesthesia was induced after a blind nasal endotracheal intubation. Because mouth opening was not improved after administration of a muscle relaxant (Rocuronium), trismus did not originate from a muscular problem. A full thickness mucoperiosteal incision was made along the external oblique ridge from premolar to

the highest point on the anterior aspect of ramus of the mandible on both sides. Mucoperiosteum was reflected to expose the medial and lateral aspect of the ramus and coronoid process. The temporalis muscle insertion was detached from anterior portion of the ramus and coronoid process. A channel retractor was placed into the sigmoid notch to protect lateral soft tissue.

A Seldin (Walter Lorenz Surgical Instrument; Biomet, Warsaw, IN, USA) retractor was used to protect medial soft tissues while sufficiently exposing coronoid process. The osteotomy cut was conducted from sigmoid notch to anterior aspect of the ascending ramus with straight saw. A bone Kocher clamp (Walter Lorenz Surgical Instruments) was used to remove coronoid process after removal of the remaining attachments of the temporalis muscle (Fig. 3). Immediately after coronoidectomy, the maximum mouth opening was 41 mm and smooth excursive movement was observed (Fig. 4).

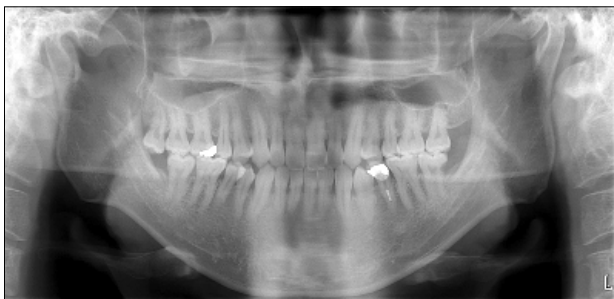

Fig. 1. Panoramic X-ray demonstrating bilateral hyperplasia of the coronoid processes.

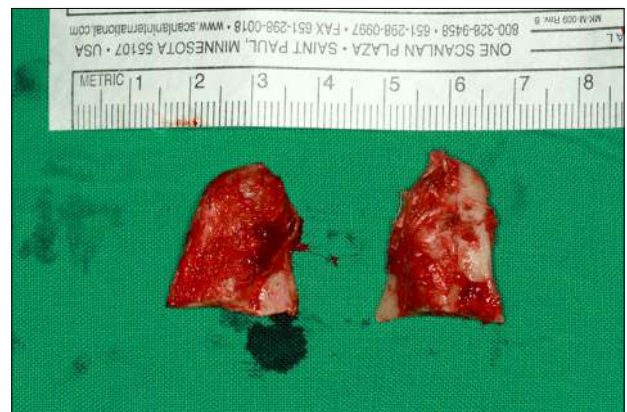

Fig. 3. Lateral view of resected coronoid processes.

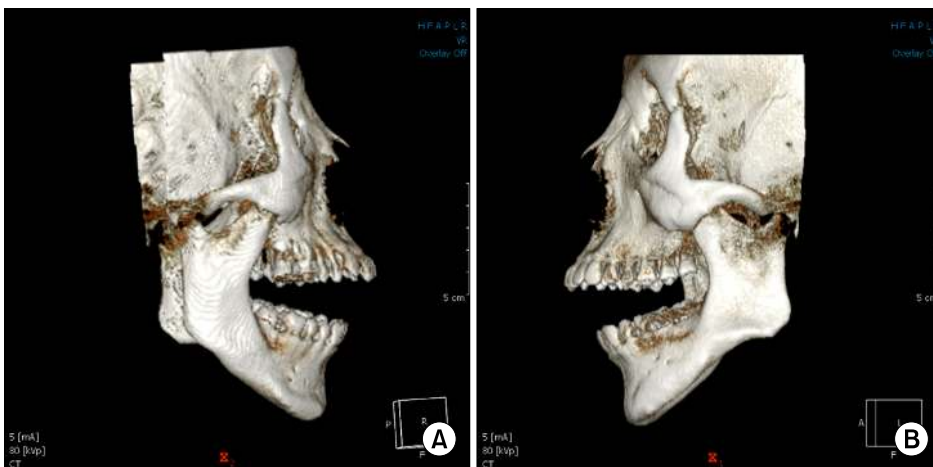


Fig. 2. Three-dimensional computed tomography scan showing elongated coronoid process blocking mandibular movement during forced opening. When mouth opening approaches 20 mm, enlarged coronoid processes impinge on the zygomatic bones. (A) Right. (B) Left.

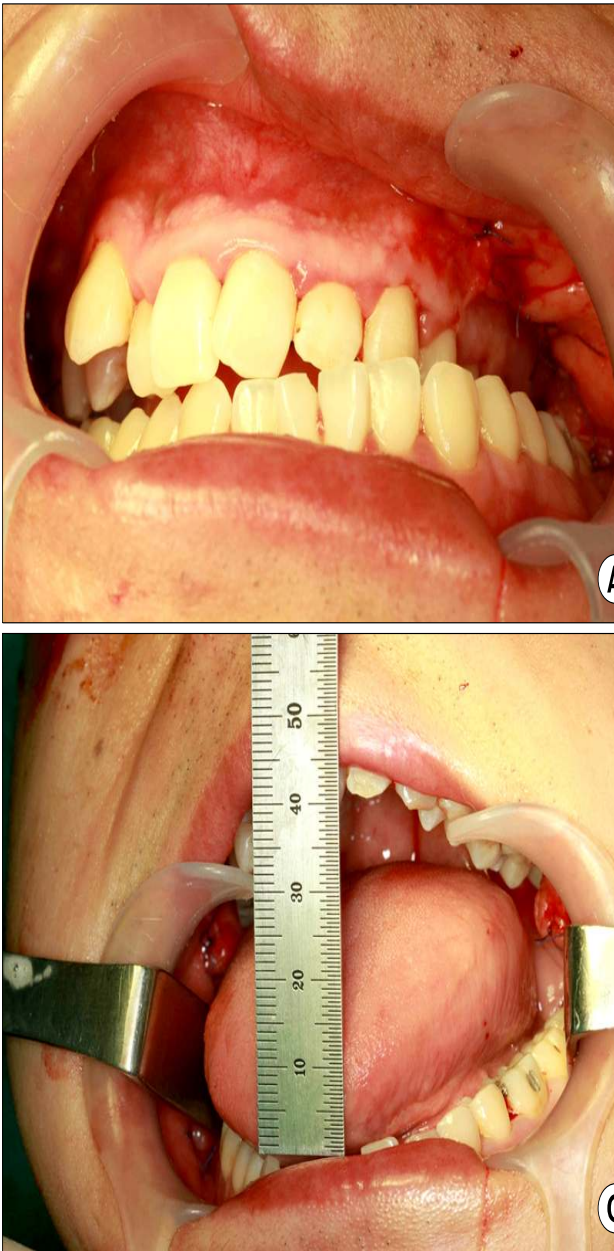


Fig. 4. Intra-operative view. (A, B) Lateral movement was not restricted. (C) Maximum mouth opening was 41 mm.

The flap was closed with 3-O Vicryl acid suture. Post-operatively, the patient was advised to exercise the mouth opening with tongue blades. For the first eight weeks, mouth opening was slightly decreased to less than 30 mm, but thereafter, the maximum mouth opening was maintained at about 40 mm. At the one year exam, lateral movement and protrusion were symmetric and within normal range. The patient was able to open his mouth to 41 mm (Fig. 5). On post-operative panoramic X-ray and 3D CT,

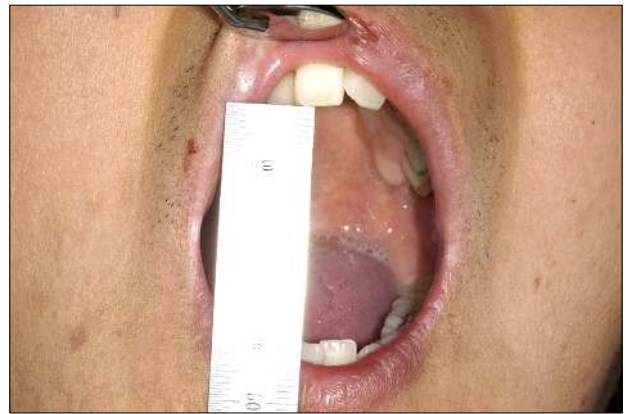

Fig. 5. Post-operative view showing opening of 41 mm was maintained 1 year after surgical removal of coronoid processes.

mechanical blocking by elongated coronoid process disappeared (Fig. 6).

Discussion

Bilateral hyperplasia of the coronoid processes of the mandible is an uncommon condition that results in limitation of mouth opening due to impingement of enlarged coronoid processes on the zygomatic bones[4]. Some patients do not seek treatment until it causes obvious problems[5]. Coronoid hyperplasia appears to be a disorder predominately of young male adults. The peak age of presentation is in the middle of the third decade for both unilateral and bilateral cases. However, it usually takes nine years for bilateral and almost seven years with unilateral cases for patient to seek treatment[5]. Totsuka and Fukuda[4] reported that the most outstanding features are the striking predilection for males and onset of symptom of the condition near puberty.

A number of clinical features suggest diagnosis of coronoid process hyperplasia. Restricted mouth opening is almost inevitable, although this is typically long-standing and of insidious onset. Unilateral coronoid hyperplasia often shows facial asymmetry, and on opening the mandible may rotate to the affected side. Facial pain is occasionally observed. Both unilateral and bilateral cases of coronoid hyperplasia have marked male preponderance and female bilateral coronoid hyperplasia is relatively rare[5].

The etiology of hyperplasia of the coronoid process remains unknown. Shira and Lister[6] argued that this abnor-

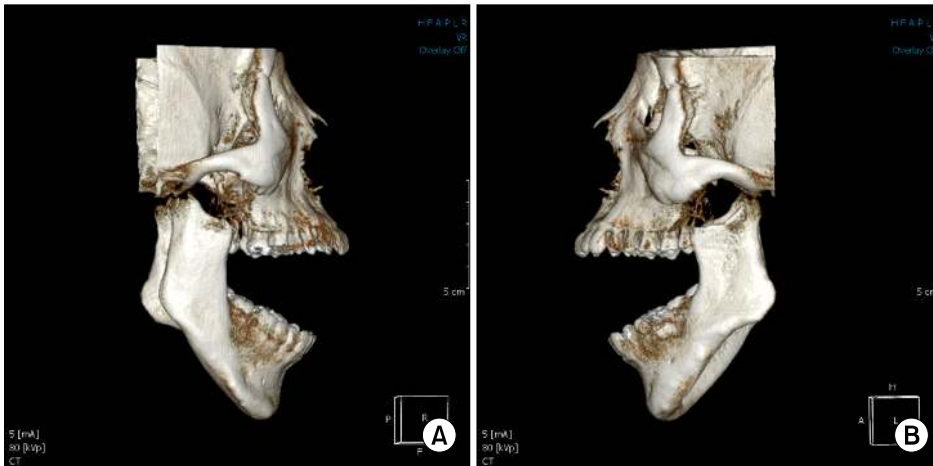


Fig. 6. Coronoid process impingement on the posterior aspect of the zygomatic bone disappeared after coronoidectomy. (A) Right. (B) Left.

mality could be a developmental defect in which cartilaginous growth centers in the coronoid processes persist, causing continued growth and hyperplasia. Lyon and Sarnat[7] later suggested increased activity of the temporal muscles as an etiologic factor. However, electromyographic examination in patients with bilateral coronoid hyperplasia reveals normal masticatory muscles function[8]. Isberg *et al.*[9] suggested that elongation of the coronoid process could be either congenital or secondary to protracted disc displacement. They also argued that trismus is caused by hyperactivity of the temporalis muscles. However, electromyographic analysis showed normal activity of this muscle[1]. Rowe[3] suggested an endocrine influence and trauma triggers bilateral coronoid hyperplasia[10]. Marra[11] suggested that heredity is important in pathogenesis of bilateral coronoid hyperplasia.

Differential diagnoses to rule out for coronoid hyperplasia include ankylosis and pseudo-ankylosis of TMJ[7]. Trismus can be either extra- or intra-articular pathology. Extra-articular causes of limited opening are myofascial pain disorder and coronoid hyperplasia. Intra-articular reasons include internal derangement, intra-articular pathology, and TMJ ankylosis[12]. Coronoid hyperplasia should be differentiated from Jacob disease where trismus is caused by pseudo-joint formation[13]. Microscopic examination of Jacob disease shows formation of a pseudo-cartilaginous joint between coronoid process and the zygoma. This pseudo-joint is characterized by reactive new bone on the surface of the coronoid process and a fibro-cartilaginous cap, probably as a consequence of traumatic injury with chronic friction between the two

bones[12]. In contrast, coronoid hyperplasia shows histologically normal bone[5].

Surgical intervention is the treatment of choice for coronoid enlargement. In bilateral coronoid hyperplasia, limitation of mandibular movement is caused by mechanical impingement of the enlarged coronoid processes on the posterior surface of the zygoma. Therefore, removal of enlarged portion of the coronoid processes is the only effective form of treatment[4]. Simple coronoidectomy is enough to correct the coronoid-malar interference[5].

When a patient presents with slow but progressive reduction in mandibular opening and clinical features and panoramic X-ray suggesting coronoid hyperplasia, CT scan is recommended without other radiographic examinations. Direct axial and coronal CT scans, multiplanar reformatting of axial scans and 3D reconstruction permit precise reproduction of the shape and size of the coronoid and malar structures of interest, and relationships of all structures of the temporal and infratemporal fossae[14]. The enlarged portion of the coronoid processes usually consists of mature bone. Although a cartilaginous component is found in some cases, it is thought to be reactive in origin[7].

Intraoral approach to coronoidectomy affords enough access for resection of the coronoid process and a cuff of temporalis tendon. Alternatively, an external approach using a coronal flap is advantageous in reducing risk of hematoma formation and intraoral scarring that can lead to relapse[15]. If the hyperplastic area is bulbous and large, an extraoral approach may be necessary[16]. The intraoral approach offers direct access without the risk of facial nerve injury or scars on the face[17], but herniation of the buccal

fat pad into the surgical site can be annoying when the dissection is carried too far superiorly and medially[18].

Due to the prolonged disuse of temporalis muscle and post-operative scarring, post-operative physiotherapy is mandatory. In addition, prognosis is associated with the range of mouth opening immediately after surgery[4]. If post-operative mouth opening is up to 40 mm, the prognosis is excellent. However, if post-operative mouth opening is less than 35 mm, the prognosis may not be satisfactory[4]. Therefore, increasing the patient's mouth opening to over 40 mm using a mechanical device is recommended immediately after bilateral coronoidectomy. Post-operative mouth opening exercise with a mechanical extensor must be started days after surgery. Maintaining the mouth open over 40 mm during surgery is also effective in stretching atrophied muscles. In one study, while post-operative physical therapy increased the initial inter-incisal opening, the amount of opening returned to the preoperative situation[19]. Hematoma and subsequent fibrosis causes relapse in many cases[5]. Mouth opening exercise is required for 12 months to prevent formation of fibrous tissue that limits mouth opening[19].

In conclusion, intraoral coronoidectomy followed by prolonged post-operative physiotherapy produced satisfactory and stable long-term results in coronoid process hyperplasia by correcting coronoido-malar interference.

Acknowledgements

This work was supported by a research grant of Wonkwang University in 2013.

References

1. Gerbino G, Bianchi SD, Bernardi M, Berrone S. Hyperplasia of the mandibular coronoid process: long-term follow-up after coronoidotomy. *J Craniomaxillofac Surg* 1997;25:169-73.
2. Kreutz RW, Sanders B. Bilateral coronoid hyperplasia resulting in severe limitation of mandibular movement. Report of a case. *Oral Surg Oral Med Oral Pathol* 1985;60:482-4.
3. Rowe NL. Bilateral developmental hyperplasia of the mandibular coronoid process. A report of two cases. *Br J Oral Surg* 1963;1:90-104.
4. Totsuka Y, Fukuda H. Bilateral coronoid hyperplasia. Report of two cases and review of the literature. *J Craniomaxillofac Surg* 1991;19:172-7.
5. McLoughlin PM, Hopper C, Bowley NB. Hyperplasia of the mandibular coronoid process: an analysis of 31 cases and a review of the literature. *J Oral Maxillofac Surg* 1995;53:250-5.
6. Shira RB, Lister RL. Limited mandibular movements due to enlargement of the coronoid processes. *J Oral Surg (Chic)* 1958;16:183-91.
7. Lyon LZ, Sarnat BG. Limited opening of the mouth caused by enlarged coronoid processes: report of case. *J Am Dent Assoc* 1963;67:644-50.
8. Hall RE, Orbach S, Landesberg R. Bilateral hyperplasia of the mandibular coronoid processes: a report of two cases. *Oral Surg Oral Med Oral Pathol* 1989;67:141-5.
9. Isberg A, Isacson G, Nah KS. Mandibular coronoid process locking: a prospective study of frequency and association with internal derangement of the temporomandibular joint. *Oral Surg Oral Med Oral Pathol* 1987;63:275-9.
10. Tucker MR, Guilford WB, Howard CW. Coronoid process hyperplasia causing restricted opening and facial asymmetry. *Oral Surg Oral Med Oral Pathol* 1984;58:130-2.
11. Marra LM. Bilateral coronoid hyperplasia, a developmental defect. *Oral Surg Oral Med Oral Pathol* 1983;55:10-3.
12. Choi JG, Kim SY, Perez-Atayde AR, Padwa BL. Bilateral coronoid process hyperplasia with pseudocartilaginous joint formation: Jacob disease. *J Oral Maxillofac Surg* 2013;71:316-21.
13. Escuder i de la Torre O, Vert Klok E, Mari i Roig A, Mommaerts MY, Pericot i Ayats J. Jacob's disease: report of two cases and review of the literature. *J Craniomaxillofac Surg* 2001;29:372-6.
14. Kraut RA. Bilateral coronoid hyperplasia: report of two cases. *J Oral Maxillofac Surg* 1985;43:612-4.
15. Hayter JP, Robertson JM. Surgical access to bilateral coronoid hyperplasia using the bicoronal flap. *Br J Oral Maxillofac Surg* 1989;27:487-93.
16. Ramon Y, Horowitz I, Oberman M, Freedman A, Tadmor R. Osteochondroma of the coronoid process of the mandible. *Oral Surg Oral Med Oral Pathol* 1977;43:692-7.
17. Hernández-Alfaro F, Escuder O, Marco V. Joint formation between an osteochondroma of the coronoid process and the zygomatic arch (Jacob disease): report of case and review of literature. *J Oral Maxillofac Surg* 2000;58:227-32.
18. Meyer RA. Osteochondroma of coronoid process of mandible: report of case. *J Oral Surg* 1972;30:297-300.
19. Bronstein SL, Osborne JJ. Mandibular limitation due to bilateral coronoid enlargement: management by surgery and physical therapy. *Cranio* 1984-1985;3:58-62.