

## Two-year follow-up of subthalamic deep brain stimulation in Parkinson's disease

HERZOG, Jan, *et al.*

---

## Reference

HERZOG, Jan, *et al.* Two-year follow-up of subthalamic deep brain stimulation in Parkinson's disease. *Movement disorders*, 2003, vol. 18, no. 11, p. 1332-1337

DOI : 10.1002/mds.10518

PMID : 14639676

Available at:

<http://archive-ouverte.unige.ch/unige:95885>

Disclaimer: layout of this document may differ from the published version.

of 2), the cingulate cortex (>5, score of 2), and the middle frontal cortex (>5, score of 2). Semiquantitatively, the number of  $\alpha$ -synuclein-immunopositive cortical Lewy bodies gave a score of at least 10 and satisfied the consensus guidelines for the pathological diagnosis of PDD.<sup>6</sup>

### Discussion

We present a patient with progressive parkinsonism and dementia who developed an unusual and severe cervical dystonia. The presence of fluctuations in cognition and alertness, visual hallucinations, and myoclonus supported the clinical diagnosis of PDD<sup>6</sup>; however, the severity of his cervical dystonia and the presence of urinary incontinence raised the possibility of MSA. The diagnosis of PDD was ultimately confirmed at autopsy.

Although the pharmacological mechanisms underlying dystonia in PD and other forms of parkinsonism are poorly understood, it is possible that dystonia results from striatal dopamine deficiency. Unfortunately, our patient's neck posture was completely resistant to treatment with levodopa (although we were unable to raise the drug to high levels due to dose-limiting sedation) and to injection of botulinum toxin.

Cranial and cervical dystonia are well described in parkinsonism,<sup>3</sup> particularly MSA.<sup>2,4</sup> In PD, dystonia may occur early in the course of the illness or as a complication of levodopa treatment.<sup>7</sup> When confronted with a head that is anteriorly flexed, the question often arises whether the neck extensors are weak or whether the head is being pulled forward. Neck extensor myopathy has been described in patients with MSA and also in levodopa-responsive Parkinson's disease.<sup>8</sup> In our patient, the absence of weakness of neck extensors and the progressive and severe lateral and anterior tilt were most consistent with dystonia.

### Legends to the Video

**Segment 1.** The patient at age 63 years. Mild parkinsonism is present without tremor. His posture is mildly stooped, and his gait is slightly slow.

**Segment 2.** The same patient at age 65 years. Progression in parkinsonian signs is evident. Mild right truncal tilt is accompanied by moderate anterolateral tilting of his neck.

**Segment 3.** The patient at age 70 years. Marked right anterolaterocollis and hypertrophy of the scalene muscles is evident.

### References

- Gomez-Tortosa E, Irizarry MC, Gomez-Isla T, Hyman BT. Clinical and neuropathological correlates of dementia with Lewy bodies. *Ann NY Acad Sci* 2000;920:9–15.
- Quinn N. Disproportionate antecollis in multiple system atrophy. *Lancet* 1989;i:844.
- Jorens PG, Eycken MP, Pariezel GA. Antecollis in parkinsonism. *Lancet* 1989;i:1320–1321.
- Rivest J, Quinn N, Marsden CD. Dystonia in Parkinson's disease, multiple system atrophy, and progressive supranuclear palsy. *Neurology* 1990;40:1571–1578.
- Quinn NP. Parkinsonism and dystonia, pseudoparkinsonism and pseudodystonia. *Adv Neurol* 1993;60:540–543.
- McKeith IG, Galasko D, Kosaka K, et al. Consensus guidelines for the clinical and pathological diagnosis of dementia with Lewy bodies (DLB): report of the consortium on DLB international workshop. *Neurology* 1996;47:1113–1124.
- Carella F, Giovannini P, Girotti F, Testa D, Caraceni T. Dystonia and Parkinson's disease. *Adv Neurol* 1993;60:558–561.
- Lava NS, Factor SA. Focal myopathy as a cause of anterocollis in parkinsonism. *Mov Disord* 2001;4:754–782.

---

## Manic Episode With Psychotic Symptoms Induced by Subthalamic Nucleus Stimulation in a Patient With Parkinson's Disease

Jan Herzog, MD,<sup>1</sup> Julia Reiff, MD,<sup>2</sup> Paul Krack, MD,<sup>1</sup> Karsten Witt, MD,<sup>1</sup> Bettina Schrader, MD,<sup>3</sup> Dieter Müller, MD,<sup>4</sup> and Günther Deuschl, MD<sup>1\*</sup>

<sup>1</sup>Department of Neurology, Christian-Albrechts-Universität Kiel, Kiel, Germany

<sup>2</sup>Department of Psychiatry, Christian-Albrechts-Universität Kiel, Germany

<sup>3</sup>Department of Neurosurgery, Christian-Albrechts-Universität Kiel, Kiel, Germany

<sup>4</sup>Department of Neurosurgery, University of Hamburg, Hamburg, Germany

**Abstract:** Deep brain stimulation of the subthalamic nucleus (STN-DBS) is an established therapy for Parkinson's disease (PD). A manic episode with psychotic symptoms induced by STN-DBS occurred in a previously psychiatrically healthy patient, focusing on the role of STN-DBS in influencing not only motor but also emotional behaviour. © 2003 Movement Disorder Society

**Key words:** deep brain stimulation; subthalamic nucleus; mania; bipolar disorder; clozapine

### Case Report

A 65-year-old woman with a 14-year history of Parkinson's disease had been treated 10 years previously with a right thalamotomy for severe rigidity and tremor of the left side of the body. This operation led to sufficient control of symptoms for the next 3 years. Subsequently, bilateral akinesia worsened, left- and right-sided tremor deteriorated, and fluctuations occurred. Medication before operation was 375 mg levodopa (L-dopa), 3 mg pergolide, 150 mg amantadine, and 15 mg

---

Current address for Paul Krack: Department of Clinical and Biological Neurosciences, Service de Neurologie, Centre Hospitalier Universitaire de Grenoble, Grenoble, France.

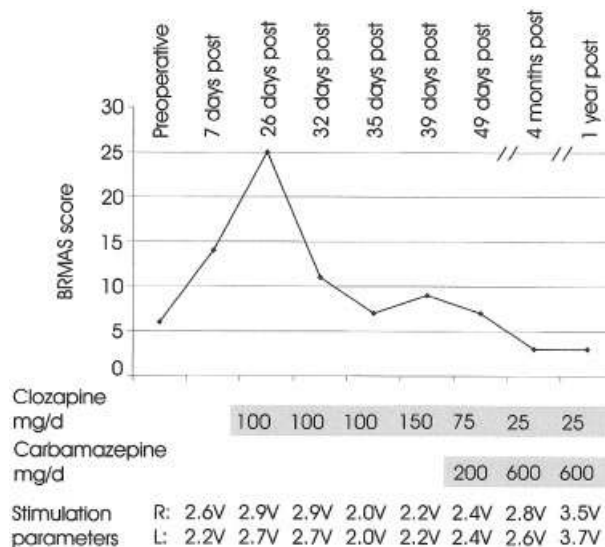
\*Correspondence to: Prof. Dr. G. Deuschl, Department of Neurology, Christian-Albrechts University of Kiel, Niemansweg 147, 24105 Kiel, Germany. E-mail: g.deuschl@neurologie.uni-kiel.de

Received 30 January 2003; Revised 6 March 2003; Accepted 6 May 2003

selegiline. Because of severe *on-off* fluctuations and disabling dyskinesias, deep brain stimulation of the subthalamic nucleus (STN-DBS) was carried out at our centre. Neuropsychological testing revealed normal findings other than a slight disturbance of frontal executive functions. Neither psychotic episodes nor benign hallucinations induced by L-dopa had been reported by the patient and the caregivers before surgery. The patient did not present any symptoms of a psychotic or affective disorder, but the patient's mother had a history of bipolar affective disorder, indicating a genetic predisposition to affective disorders.

STN-DBS was initiated 6 days after implantation of leads. It was followed by a rapid and marked improvement of motor functions associated with dyskinesia. Because there was some residual tremor and gait hesitation in *off-drug* condition, dopaminergic medication was not completely withdrawn. Stimulation amplitude for the right and left electrode was set to 2.6 and 2.2 V, respectively (monopolar mode using one contact with a pulse width of 60  $\mu$ sec and a frequency of 130 Hz). Seven days after switching on the neurostimulator, however, a remarkable mood change took place. In parallel with motor improvement, her mood was elevated to a degree that was abnormal for the patient. She was excessively talkative and it was not possible to interrupt her while she was speaking. Pergolide, selegiline, and amantadine were stopped. She was treated with a monotherapy of  $5 \times 100$  mg L-dopa. Gradually, in the course of the next 3 weeks, hypomania turned into a manic episode with psychotic symptoms. The patient's mood was euphoric and her speech more rapid, her thought was easily distracted, flights of ideas appeared, associations loosened, and her ability to concentrate faded. Orientation and memory were intact. She lost normal social inhibitions, was in love with two neurologists, and tried to embrace and kiss people. She was hyperactive and restless, she left the clinic several times without permission and engaged in unrestrained buying of clothing. Because of her disorganised behaviour she messed up her room, and she occupied her neighbour's bed. The patient alleged that important events were forthcoming and that she had to settle her affairs. The family wanted to remove her credit card to protect her from financial ruin. Her judgement was impaired, but she had little insight into her disorder and had low frustration tolerance. She was suspicious, tense, and hostile, and had the delusion that her sons were conspiring against her and said that they tried to get her money by threat of force. There was a decreased need for sleep and the patient felt rested after only 3 to 4 hours of sleep. The Bech-Rafaelsen Mania Scale (BRMAS) was used for monitoring the course of this mania. The score changed from (estimated retrospectively) 6/44 preoperatively to 25/44 postoperatively (Fig. 1).

Attempts to decrease stimulation parameters or medication led to worsening of her motor state. Stimulation arrest led to a reappearance of severe parkinsonism. Moreover, it was associated with a rapid deterioration of her mood with anhedonic feelings but without any improvement in mania. Because of its unfavourable impact both on motor and emotional state of the patient, stimulation arrest was not tolerated for more than half an hour. For this reason, clozapine therapy was begun with a small dose and built up gradually to 150 mg/day. Psychotic symptoms disappeared, but now mixed features with symptoms of both mania and depression were present at the same time. The patient was often emotionally labile, switching from laughter and euphoria to crying and depression in minutes. Periods of



**FIG. 1.** The Bech-Rafaelsen Mania Scale (BRMAS) and treatment of manic symptoms in our patient. The BRMAS comprises 11 simple items for assessment of the severity of manic states.<sup>15</sup> The scale includes the evaluation, for example, of motor activity, mood such as hostility or well being, sleep, sexual activity, and social contacts. A score lower than 15 indicates hypomania, a score around 20 indicates moderate mania, and a score of about 25 indicates severe mania.

hyperactivity were followed by phases of complete fatigue, deep sadness, and grumbling that her situation had never been worse. Gradually, depressive symptoms tended to predominate. Because of the onset of mixed features with symptoms of mania and depression at the same time, with a gradual predominance of depressive symptoms turning into a depressive episode, we diagnosed an organic bipolar affective disorder.

For this reason, we reduced clozapine slowly to 25 mg and began a combination with the mood stabiliser carbamazepine, although the combination is not recommended because of its association with agranulocytosis. With this combination, the affective disorder remitted within the next 3 months. Carbamazepine was discontinued after 14 months whereas medication with 25 mg clozapine was continued. In 3 years, she has not experienced further manic or depressive episodes. Motor symptoms in the *off* medication state are well controlled by stimulation with an improvement of 59% in comparison with the baseline. Stimulation amplitude was increased to 3.7 V on each side using the same active contacts. Actual dopaminergic medication encompasses 350 mg L-dopa as well as 4 mg cabergoline.

## Discussion

We present a case report of a 65-year-old patient who gradually developed a first episode of mania with psychotic symptoms after STN-DBS. Several authors have described psychiatric alterations after STN-DBS. Houeto and colleagues<sup>1</sup> found a decompensation of pre-existing psychiatric disorders such as depression, anxiety disorders, or drug dependence. A case with mirthful laughter when stimulated with higher than therapeutic stimulation parameters has been described<sup>2</sup> in 2 patients, whereas chronic stimulation led to a hypomanic behaviour.

Even mania after deep brain stimulation of the STN has been observed elsewhere. Romito and associates<sup>3</sup> described 2 patients with manic symptoms, which appeared progressively some days after initiation of STN stimulation without any psychotic symptoms. Stimulation arrest did not acutely influence manic symptoms. Kulisevsky and coworkers<sup>4</sup> described 3 cases of mania in a series of 15 patients. In these patients, stimulation of the contacts, which were misplaced caudal to the STN in the midbrain level, led to a reversible manic state. Manic behaviour disappeared in one patient after stimulation of a different contact located in the level of the STN. The authors concluded that manic disorders might be caused by affection of structures in the ventral midbrain regions.

In view of the magnitude of motor response and induction of dyskinesia, in the present case, stimulation within the STN is considered responsible for psychiatric symptoms. Lesioning of the STN by infarction or tumour has been reported to induce psychic alterations characterised by agitation,<sup>5</sup> manic state, and logorrhoea.<sup>6</sup> STN-DBS may similarly release or activate not only motor behaviour but also affective control of behaviour. Given the small volume of the STN,<sup>7</sup> it is unlikely that deep brain stimulation selectively influences its dorsolateral sensorimotor part,<sup>8</sup> without any influence on the limbic territory.<sup>2</sup> It is well known that various basal ganglia circuits do exist and the orbito-frontal basal ganglia circuit<sup>9</sup> is likely involved in the control of emotion and motivation. Acute challenge with either L-dopa or STN-DBS seems to influence mood in a similar way.<sup>10</sup> Remarkably, manic symptoms did not immediately change in response to switching stimulation on and off. This may indicate that contrary to motor symptoms, changes in the limbic circuit take longer to become efficacious and are not instantly reversible. Finally, neither a behavioural disorder after this life-changing event of deep brain stimulation nor a mania unrelated to deep brain stimulation can be excluded. The latter seems to be unlikely in a 65-year-old patient without individual history of affective disorders.

Studies have demonstrated the safety and efficacy of clozapine in improving drug-induced psychosis in PD without worsening of Parkinson's symptoms.<sup>11,12</sup> Cumulative data indicate that clozapine is effective in reducing symptoms of acute mania and in the treatment of drug-resistant mood disorders.<sup>13,14</sup> In our case, however, clozapine led to a full remission of psychotic symptoms, but only to a partial response of manic symptoms. Therefore, considering the major features of an organic bipolar affective disorder in that case, carbamazepine was added to the therapeutic regime and led to a marked improvement of the patient's condition.

This case shows that a manic psychosis can be caused by stimulation of the STN and probably not by stimulation of adjacent structures. It will be important to recognise cases with mania in the future to assess whether the described cases occur frequently or just as incidental observations. Obviously, such cases can be treated successfully with a combination of carbamazepine and clozapine; however, relevant side effects of this therapy, such as a higher incidence of agranulocytosis, should be considered.

## References

- Houeto J, Mesnage V, Mallet L, et al. Behavioural disorders, Parkinson's disease and subthalamic stimulation. *J Neurol Neurosurg Psychiatry* 2002;72:701-707.
- Krack P, Kumar R, Ardouin C, Dowsey PL, McVicker JM, Benaïd AL, Pollak P. Mirthful laughter induced by subthalamic nucleus stimulation. *Mov Disord* 2001;16:867-875.
- Romito L, Raja M, Daniele A, et al. Transient mania with hypersexuality after surgery for high frequency stimulation of the subthalamic nucleus in Parkinson's disease. *Mov Disord* 2002;17:371-374.
- Kulisevsky J, Berthier M, Gironell A, Pascual-Sedano B, Molet J, Pares P. Mania following deep brain stimulation for Parkinson's disease. *Neurology* 2002;59:1421-1424.
- Martin J. Hemichorea resulting from a local lesion of the brain (syndrome of the body of Luys). *Brain* 1927;50:637-651.
- Trillet M, Vighetto A, Croisile B, Charles N, Aimard G. Hemiballismus with logorrhoea and thymo-affective disinhibition caused by hematoma of the left nucleus subthalamicus. *Rev Neurol (Paris)* 1995;151:416-419.
- Yelnik J. Functional anatomy of the basal ganglia. *Mov Disord* 2002;17(Suppl.):15-21.
- Rodriguez-Oroz MC, Rodriguez M, Guridi J, et al. The subthalamic nucleus in Parkinson's disease: somatotopic organization and physiological characteristics. *Brain* 2001;124:1777-1790.
- Limousin P, Greene J, Pollak P, Rothwell J, Benabid AL, Frackowiak R. Changes in cerebral activity pattern due to subthalamic or internal pallidum stimulation in Parkinson's disease. *Ann Neurol* 1997;42:283-291.
- Funkiewiez A, Ardouin C, Krack P, et al. Acute psychotropic effects of bilateral subthalamic nucleus stimulation in Parkinson's disease. 6th International Congress of Parkinson's Disease and Movement Disorders, Barcelona, 12 June, 2000.
- The French Clozapine Parkinson Study Group. Clozapine in drug-induced psychosis in Parkinson's disease. *Lancet* 1999;353:2041-2042.
- The Parkinson Study Group. Low-dose clozapine for the treatment of drug-induced psychosis in Parkinson's disease. *N Engl J Med* 1999;340:757-763.
- Weizman R, Weizman A. Use of atypical antipsychotics in mood disorders. *Curr Opin Investig Drugs* 2001;2:940-945.
- Kim E, Zvil AS, McAllister TW, Glosser DS, Stern M, Hurtig H. Treatment of organic bipolar mood disorders in Parkinson's disease. *J Neuropsychiatry Clin Neurosci* 1994;6:181-184.
- Bech P, Rafaelsen OJ, Kramp P, Bolwig TG. The Mania Rating Scale: scale construction and inter-observer agreement. *Neuropharmacology* 1978;17:430-431.