



Revista Brasileira de Farmacognosia

BRAZILIAN JOURNAL OF PHARMACOGNOSY

www.journals.elsevier.com/revista-brasileira-de-farmacognosia



Original article

Ulcer protective potential of standardized hesperidin, a citrus flavonoid isolated from *Citrus sinensis*

Papiya Bigoniya*, Kailash Singh

Department of Pharmacology, Radharaman College of Pharmacy, Bhopal, India

ARTICLE INFO

Article history:

Received 21 November 2013

Accepted 10 February 2014

Keywords:

Antioxidant

Flavonoid

Citrus sinensis

Cytoprotective

Hesperidin

ABSTRACT

Free radicals play an important role in stomach ulcer formation. The present investigation validates the anti ulcer activity of hesperidin, isolated from *Citrus sinensis* (L.) Osbeck, Rutaceae, through the assessment of its antioxidant potential over stomach mucosal tissue by histological examination. Hesperidin was isolated from the dried peel of *C. sinensis*, and authenticated by TLC, IR and HPLC. The anti-ulcerogenic potential of this fruit was assessed using indomethacin and hypothermic restrain stress-induced ulceration models on rats at 150, 300 and 450 mg/kg dose orally. The parameters measured were gastric pH, volume, free and total acidity, ulcer index, and mucin, glutathione, super oxide dismutase, catalase and protein content. Hesperidin at 300 and 450 mg/kg dose showed significant ($p < 0.01-0.001$) increase in pH, decrease in acidity and ulcer index against indomethacin and hypothermic restrain stress, along with histological evidence of cytoprotection. Glutathione, super oxide dismutase, catalase and mucin levels increased significantly at 450 mg/kg ($p < 0.05-0.001$) after indomethacin ulceration, whereas hypothermic restrain stress only increased glutathione and mucin levels. Hesperidin prevents oxidative cell injury by significant rise of super oxide dismutase, glutathione and catalase levels in gastric mucosa. Hesperidin allowed the regeneration of ulcerated tissue, and prevented hemorrhagic injury of gastric mucosa. The potential anti-ulcer effect of hesperidin may be due to antioxidant, mucoprotective and cytoprotective activities.

© 2014 Sociedade Brasileira de Farmacognosia. Published by Elsevier Editora Ltda. All rights reserved.

Introduction

Worldwide interest in natural products as preventive and therapeutic agent has given a greater appreciation of the rich cultural heritage of traditional medicinal system (Chaturvedi et al., 2007). Potential bioactive phytocompounds lead to the development of new therapeutic drugs emphasizing the

need of scientific analysis of herbs with pharmacological effects to discover new active compounds (Falcao et al., 2008). Consumption of citrus fruits decreases the risk of cancer, inflammation, heart disease and ulcers, which has increased their use as precursors of flavonoids. Citrus juice is considered to be a rich source of antioxidants, including vitamin C, phenolic compounds and carotenoids, which have

* Corresponding author.

E-mail: p_bigoniya2@hotmail.com (P. Bigoniya).

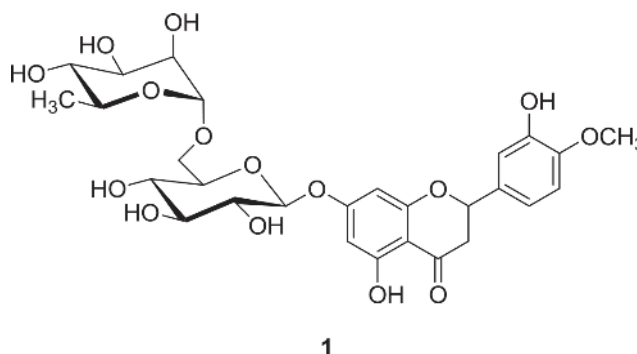
many health benefits (Gattuso et al., 2007). Citrus herbal products prepared from mature or immature citrus peels have been traditionally used for liver rejuvenation (Dan and Andrew, 1986). During the processing of citrus fruit in juice and other food industries, peels are the primary byproducts, normally discarded after consuming the fruits. Many studies have shown that bioactive flavonoids present in the citrus peel possess strong antioxidant, antiatherogenic, anti-viral, anti-aggregation, anti-mutagenic, anti-ulcer and antitumor effects (Del-Rio et al., 1992; Zia, 2006; Parmar and Kar, 2008).

Flavonoids are a group of about 4,000 naturally occurring compounds that have a wide range of biological effects, including anti-ulcer activity. Plants synthesize flavonoids as an adaptive response to stress conditions (infection, wounding, water stress, cold stress). In recent years flavonoids have attracted the interest of researchers because they have promising powerful antioxidant properties that protect the human body from free radicals by their hydrogen donating abilities (Jeong et al., 2007). They are important constituents of the human diet (a daily diet should provide approximately 1 g of flavonoids per day) and are also found in several medicinal plants used in folk medicine around the world. Many epidemiological studies have shown that consumption of plants rich in phenolic compounds is associated with a lower risk of degenerative diseases such as cancer (Harris et al., 2007), cardiovascular disease (Naruszewicz et al., 2007), immune dysfunction (Kale et al., 2008) and allergic (Sokmen et al., 2004) complications. Free radicals play an important role in ulcer formation and erosive lesions in the gastrointestinal tract. Flavonoids like naringin, quercetin, silymarin, anthocyanosides and sophoradin derivatives have been reported to have anti-ulcer properties (Borrelli and Izzo, 2000).

Citrus sinensis (L.) Osbeck, Rutaceae, is a small, shallow-rooted evergreen shrub or tree about 6-13 m high with an enclosed conical top and mostly spiny branches. Leaves are smooth, oval, dark green and glossy, with a distinctive smell often similar to the fruit. Fruits are reddish-green to yellowish-green, round, 4-12 cm in diameter, and have a leathery peel 6 mm thick, tightly adherent, protecting the juicy inner pulp (Anonymous, 2006). Hesperidin (1) is a flavanone glycoside found abundantly in sweet orange and lemon, and is an inexpensive by-product of citrus products (Garg et al., 2001). Hesperidin may be associated with potential benefits for the prevention of diseases, like decreased capillary permeability, inflammation, microbial infection and carcinogenic effects. A number of researchers have examined the antioxidant activity and radical scavenging properties of hesperidin using a variety of assay systems (Orallo et al., 2004; Hirata et al., 2005; Cho, 2006).

Rossi et al. (1957) reported the effect of hesperidin on histamine-induced gastric ulcers in guinea pigs. Hesperidin (1) and neohesperidin dihydrochalcone allowed reduction of cold restraint-induced ulcer, but was ineffective on absolute ethanol-induced ulcer (Suárez et al., 1996). Lee et al. (2009) reported the inhibitory effect of neohesperidin and poncirin, isolated from *Poncirus trifoliata*, against HCl/ethanol-induced gastric lesions. Furthermore, Ping-Wei San, a Chinese decoction containing hesperidin, reduced gastric ulceration induced by indomethacin (Cheng et al., 2011). These reports showed

experimental evidence of the beneficial effects of hesperidin against peptic ulcer. The present investigation was carried out to validate the anti-ulcer activity of hesperidin isolated from *C. sinensis* assessing its antioxidative potential in stomach mucosal tissue, along with histological examination of stomach mucosa, to evaluate the regenerative and cytoprotective effect on damaged mucosa. The present investigation was carried out to test and validate the anti-ulcer activity of hesperidin isolated from *C. sinensis* on two gastric ulcer models. The ulcer models used were, indomethacin to induce oxidative damage by inhibition of *in situ* synthesis of cytoprotective prostaglandins in stomach mucosa; and cold restraint to induce physiological stress related to the autonomic nervous system.



Materials and methods

Collection and authentication

The fresh fruits of *Citrus sinensis* (L.) Osbeck, Rutaceae, were collected from November between December, 2010 at Bhopal (M.P.). The botanical identity was confirmed from Saifia College of Science, Peer Gate, Bhopal (M.P.), by Prof. Ziaul Hassan and sample stored for future reference with authentication no. 192/BOT/SAIFIA/2010. Macroscopic characteristics of the fresh and dried peels were noted. Chopped green peels were dried for 36 h under the sunlight, followed by shade drying. Dried peels were powdered in a mixture grinder, packed in paper bags and stored in an air tight container until use.

Drugs and chemicals

Drug samples of omeprazole and indomethacin were obtained from Dr. Reddy's Laboratory, Hyderabad and Jagsonpal Pharmaceutical Ltd., New Delhi respectively. Hesperidin standard and Ehrlich's reagent were purchased from Himedia Lab, Mumbai. Tris buffer, sodium di-hydrogen phosphate (NaH_2PO_4), trichloroacetic acid (TCA), disodium hydrogen phosphate (Na_2HPO_4) and poly-ethylene glycol-400 were purchased from E. Merck, Mumbai. The source of 5.5'-dithio bis-2-nitrobenzoic acid (DTNB) was Sigma-Aldrich, Sweden. Alcian blue, thiobarbituric acid and ruthenium red was procured from Loba Chemie Pvt. Ltd, Mumbai and all other solvents and reagents obtained were of GR grade.

Extraction and isolation of hesperidin

Dried powdered peel was placed in a reflux condenser with petroleum ether for 1 h, filtered, dried at room temperature, and the yield was calculated. Methanol extract was subjected to phytochemical evaluation for alkaloids, tannins, phenolics, saponins, carbohydrates, steroids, flavonoids and glycosides, following the method of Kokate et al. (2001). Peel extract was re-extracted with methanol for 3 h, filtered and washed with hot methanol. Filtrate was concentrated and dried. Dried residue was mixed with 50 ml of 6% acetic acid to precipitate crude hesperidin (1). Crude hesperidin was filtered using a Buchner funnel, washed with 6% acetic acid, dried to constant weight.

Purification of hesperidin

Dimethylformamide was added to crude hesperidin (7 ml/g) prepared by warming it at 60°C and treated for 30 min. with activated charcoal previously boiled with dilute hydrochloric acid. Glacial acetic acid was added to the formamide solution to make it slightly acidic. The solution was then filtered through a celite filter, diluted with an equal volume of water, and was allowed to stand for a few hours in order to crystallize. The crystals of hesperidin were filtered, washed with hot water and the percentage yield was calculated (Ikan, 1991).

The isolated hesperidin was subjected to ferric chloride test and magnesium-hydrochloric acid reduction test (Shinoda test) following the method of Hendrickson and Kesterson (Hendrickson and Kesterson, 1954).

Authentication of hesperidin

Preparation of stock solution

Hesperidin powder (standard and isolated) 12.5 mg was dissolved in 5 ml of dimethyl sulfoxide (DMSO), diluted with 20 ml of methanol, and filtered through Whatman filter paper to recover a hesperidin solution of 500 µg/ml.

Thin layer chromatography (TLC)

Plates freshly coated with Silica Gel G₂₅₄ were allowed to air dry at room temperature, transferred to an oven for activation, and kept at 110°C for 30 min. Commonly used solvent system for identification and quantification flavonoids, n-butanol:acetic acid:water (4:1:5) was used for co-thin layer chromatograph to compare R_f values of standard and isolated hesperidin (Nataraj et al., 2009). Stock solution (20 µl) was spotted; plates were placed into the developing chamber and allowed to run until it reached a height of about 10 cm from the point of spotting. Methanol sulphuric acid (10%) was used as a spraying agent. After development, the plates were kept in an oven maintained at 110°C in order to achieve optimal color development.

Identification of hesperidin

Melting point was determined with the help of a digital melting point apparatus (Microteknik, India). Hesperidin stock solution 1 ml was diluted to 10 ml with methanol to get a solution of 50 µg/ml and UV spectra were assessed with a Shimadzu (UV-1800 Pharmaspec, Japan) spectrophotometer. The IR spectra were recorded on a Shimadzu (Bruker ALPHA-FTIR, Germany)

spectrometer using a KBr pellet at a scanning speed of 2 mm/s and with resolution set at 4 cm⁻¹.

HPLC of hesperidin

The chromatography analysis was performed on a Shimadzu (Japan) liquid chromatography system, equipped with ProMinent (LC-20AD) pump, SPD-M20A photodiode array UV/VIS detector working in the range 190-800 nm, a quaternary solvent delivery system, degasser (DGU-20A5) and a rheodyne injection valve fitted with a 20 µl injection loop. The chromatographic data was recorded and processed with LC solution integrated software. Baseline resolution of hesperidin was obtained at 25 ± 2°C using stainless steel Luna column (250 mm × 4.6 mm), packed with octadecylsilane bonded to porous silica (5 µm). A secondary gradient solvent system consisting of 2% (v/v) of aqueous glacial acetic acid, pH 2.58 (A) and acetonitrile (B) in a A:B ratio of 100%: 0% for initial 0-15 min followed by A 100-70%: B 0-30% in 15-45 min was used. The mobile phase was passed through 0.45 PVDF filter, and degassed before use. The 20 µl sample solution (50 µg/ml) was injected; flow rate was kept constant at 1 ml/min with oven temperature 40°C and effluents monitored at 285 nm following the slightly modified method of Gorinstein et al. (2006).

Pharmacological study

Experimental animals

Laboratory-bred healthy Wistar rats of both sexes, weighing between 180-250 g. Animals were kept in laboratory conditions at 24 ± 2°C, relative humidity 60 ± 5%, 12:12 photoperiodic condition, in well ventilated animal house in polypropylene cages with paddy husk as bedding and access to food and water *ad libitum*. During the experimental period the animals were fed standard feeding pellets procured from Hindustan Lever, India. The experimental protocol was approved by the Institutional Animal Ethical Committee (IACE/RCP/Oct 2010/10), at Radharaman College of Pharmacy, Bhopal (M.P). All conditions were in accordance to CPCSEA norms and "WHO guidelines for the care and use of animals in scientific research".

Preparation of test and standard drug suspension

Hesperidin was moderately solubilized in water, the test sample was prepared as an aqueous suspension using 0.25% Tween-80. Omeprazole and indomethacin were given as oral suspensions using 1% aqueous CMC.

Acute toxicity study

The LD₅₀ was determined according to the guidelines of Organization for Economic Co-operation and Development (OECD), following the up and down method (OECD guideline N° 423). A limit test was performed at 2000 mg/kg, *p.o.* to categorize the toxicity class (LD₅₀) of hesperidin (Diener et al., 1995).

Indomethacin induced gastric ulcers

Rats were randomly divided in six groups of six subjects each, subjected to 24 h of fasting and orally treated as follows.

Group I: Vehicle control (1% CMC 0.5 ml/100 g)

Group II: Indomethacin (25 mg/kg)

Group III: Indomethacin + omeprazole (20 mg/kg)

Group IV: Indomethacin + hesperidin (150 mg/kg)

Group V: Indomethacin + hesperidin (300 mg/kg)

Group VI: Indomethacin + hesperidin (450 mg/kg)

Indomethacin was administered to all the animals from Group II to VI, 30 min before omeprazole (Group III) and hesperidin 150, 300 and 450 mg/kg (Group IV-VI) treatment. Vehicle control group was treated only with 1% CMC (0.5 ml/100 g). Under light ether anesthesia, after 6 h all animals were sacrificed by decapitation, and the stomach was isolated after suturing the lower esophageal end (Dengiz and Gursan, 2005). The stomach was cut open along the greater curvature, gastric contents were collected in a graduated centrifuge tube to measure pH, volume, and total and free acidity. The stomach surface was cleaned with cold normal saline solution to determine ulcer scoring, and a part of the stomach mucosa was preserved in 10% formalin for histopathology. Another part of the stomach tissue was preserved in ice cold saline for estimation of mucin content. Stomach tissue homogenate was used for measuring reduced glutathione (GSH), super oxide dismutase (SOD), catalase and protein content.

Hypothermic Restraint Stress (HRS) induced ulcer

Rats were randomly divided in five groups of six subjects each, subjected to 24 h of fasting and orally treated as follows.

Group I: HRS + vehicle (1% CMC 0.5 ml/100 g)

Group II: HRS + omeprazole (20 mg/kg)

Group III: HRS + hesperidin (150 mg/kg)

Group IV: HRS + hesperidin (300 mg/kg)

Group V: HRS + hesperidin (450 mg/kg)

Animals of Group I were treated with vehicle 1% CMC (0.5 ml/100 g) and all the other animals from Group II to V were administered with drugs in the above mentioned scheme for seven consecutive days, and 1 h before stress-induced ulcer induction on the 8th day of experiment. Rats were immobilized in a restraint cage at 4°C for 3 h (Senay and Levine, 1967). Stomach content was collected to measure pH, volume, total and free acidity, and stomach tissue was scored for ulcerative index, and mucin estimation, among other biochemical parameters measured on tissue homogenate.

Estimation of pH, gastric volume, total and free acidity

The gastric juice was collected and its volume was measured. The pH of the gastric juice was recorded using digital pH meter. Gastric content was centrifuged, diluted (1 ml diluted with 9 ml of distilled water) and clear supernatant was titrated against 0.01 N NaOH, using Toper's reagent till orange color, which corresponds to free acidity, and further titrated to pink color with phenolphthalein. Total volume of NaOH corresponds to total acidity (Hawk, 1965).

Acidity is expressed as: Vol. of NaOH × Normality × 100/0.1 mEq/l/100 g.

Ulcer scoring and percentage inhibition

The number of ulcers per stomach was quantified and the severity of the lesions was observed microscopically. The scoring of ulcers was done as described by Kulkarni (Kulkarni, 2002), as 0 for normal colored stomach, 0.5 for red coloration, 1 for spot ulcer, 1.5 for hemorrhagic streaks, 2 for ulcer between

> 3 but < 5mm and 3 for ulcer > 5mm. Mean ulcer score for each animal was expressed as ulcer index. The percentage healing was calculated as:

Percent inhibition = $\frac{\text{Ulcer area of control} - \text{Ulcer area of treated}}{\text{Ulcer area of control}} \times 100$

Morphological examination

The stomach was opened and washed with running tap water, placed on a flat glass plate to view the morphological alterations induced by different treatments. Photographs were taken using digital camera (10 mega pixel 5× zoom).

Histopathological evaluation

Gastric tissue samples were fixed in neutral buffered formalin for 24 h. The washed tissues were embedded in paraffin blocks and sections of 5 µm thick were cut using an optical rotary microtome. The sections were stained with haematoxylin and eosin (Nanji et al., 2002). The slides were examined microscopically for pathomorphological changes such as congestion, hemorrhage, edema, and erosions using an arbitrary scale for severity assessment for these changes.

Estimation of biochemical parameters

Stomach tissue was homogenized in ice cold 0.15 M Tris-HCl (pH 7.4) to give 10% w/v homogenate. The homogenate was then centrifuged at 10000g for 15 min at 4°C in a refrigerated centrifuge (Remi, India). Supernatant was collected for GSH, SOD, catalase and protein content determination.

Glutathione reduces H₂O₂ directly to water or reacts directly with free radicals such as O₂^{*}, OH^{*}, O^{-*} by a radical transfer process, which yields thiol radicals. These thiol radicals, present in glutathione, form a colored complex with DTNB, which is measured colorimetrically at 412 nm (Tietze, 1969). One enzymatic unit of SOD is the amount of protein in the form of enzyme present in 100 µl of sample, required to inhibit the reduction of 24 micromolar nitro-blue tetrazolium (NBT) by 50%, and is expressed as unit/mg of protein. All these estimations were done using a Shimadzu (UV-1800 pharmaspec) spectrophotometer. Superoxide dismutase was estimated following the method of Misra and Fridovich (1979). Catalase was determined following the method of Aebi (Aebi, 1983). Decomposition of H₂O₂ by catalase is directly proportional to decrease in absorbance at 340 nm. The results were expressed as unit of H₂O₂ decomposed/min/mg of protein, using 71 as molar extinction coefficient of H₂O₂. The total protein content was measured following method of Lowry et al. (1951).

Mucin content in gastric wall mucus was determined according to the modified procedure of Corne et al. (1974). Some glandular segments of stomach were removed and weighed and transferred immediately to 10 ml of 0.1% w/v Alcian blue solution (0.16 M sucrose solution, buffered with 0.05 M sodium acetate pH 5) for 2 h immersion. Excess dye was removed by two successive rinses with 10 ml of 0.25 M sucrose, dye complexed with the mucus was extracted with 10 ml of 0.5 M magnesium chloride by shaking intermittently for 2 h. The blue extract was then shaken vigorously with an equal volume of diethyl ether a resulting emulsion was centrifuged at 3600 g for 10 min. The absorbance of the aqueous layer was recorded

at 580 nm, and the quantity of Alcian blue extracted per gram of glandular tissue was then calculated.

Statistical analysis

The results are presented as mean \pm SEM. The data were analyzed by ANOVA (one-way analysis of variance). The statistical analysis was performed using Tukey-Kramer multiple comparison tests for all parameters. The values were considered significant at the levels of $p < 0.05$.

Results

Macroscopic characters of peel

Outer surface of fresh peel was bright greenish yellow, internally white. Dried peel was yellow with inner surface terse and white. The peels are irregular in shape and are found in the form of strips or pieces. The odor is aromatic and characteristic with aromatic bitter taste.

Phytochemical profile of methanol extract and isolated hesperidin

Methanol extract was obtained as semisolid brownish black mass with characteristic aromatic odour. The methanol extract gave positive result for the presence of carbohydrates, glycosides, steroids, tannins, flavonoids and polyphenols with absence of alkaloids having percentage yield of 18.12%. Isolated hesperidin was a light yellowish amorphous powder (yield 10.24%), it gave wine red color in ferric chloride test and bright violet color in Shinoda test as described by Hendrickson and Kesterson (1954). Melting point was found to be 245-246°C. Natural hesperidin normally extracted with its chalcone, which can vary the melting point from 243 to 257°C depending on different isolation conditions in contrast to chemically synthesized colorless hesperidin crystal melting at 261-262°C (Hendrickson and Kesterson, 1954).

Identification by TLC, UV, IR and HPLC of hesperidin

Sample hesperidin gave R_f value 6.1 compared to standard hesperidin 6.0 in solvent system *n*-butanol:acetic acid:water (4:1:5). The UV absorption maxima of isolated hesperidin were 283.6 nm. The IR spectrum of isolated hesperidin showed a strong band of OH_{str} at 3378 cm^{-1} , CH aliphatic at 2924 cm^{-1} , C=C aromatic at 1608, 1516, 1447 cm^{-1} , C=O_{str} at 1648 cm^{-1} , C-O_{str} at 1282, 1292, 1197, 1131, and 1093 cm^{-1} similar to standard hesperidin (1). HPLC chromatogram showed retention time at 25.055 and 25.562 min for standard and isolated hesperidin, respectively.

Acute toxicity

Subjects were closely observed for 4 h, and for fourteen days afterwards for delayed toxicity. There was no sign of toxicity observed. It was concluded that lethal dose was higher than 2000 mg/kg. A dose range of 150-450 mg/kg, p.o. was selected for the evaluation of the pharmacological activity study as isolated hesperidin was free of acute oral toxicity.

Anti-ulcerogenic potential

Indomethacin caused induction of ulceration in sham treated animal, showing significant increase in pH ($p < 0.001$), volume of gastric content ($p < 0.05$), free and total acidity ($p < 0.05$ -0.01), and with the ulcer index, 4.16 ± 1.29 . The anti-ulcer property of hesperidin was evident from its extremely significant ($p < 0.001$) reduction in total acidity and pH at 300 and 450 mg/kg doses compared with the sham group. Free acidity and ulcer index was reduced significantly ($p < 0.01$) at 450 mg/kg dose only. Hesperidin has non-significant effect on increased gastric content volume by indomethacin (Table 1).

The results in Table 2 showed significant reduction of GSH, SOD ($p < 0.001$) and catalase ($p < 0.05$) level in indomethacin treated group indicating toxicity of indomethacin at cellular level by reduction of free SH concentration. The protective

Table 1

Effects of different concentration of essential oil of *Piper aduncum* L. on egg-hatching of *Haemonchus contortus* from sheep.

Treatment (mg/kg)	Gastric juice				Ulcer index	% protection
	pH	Volume (ml/100 g)	Free acidity	Total acidity		
			(Meq/l/100 g)			
Vehicle control	3.34 ± 0.02	1.73 ± 0.02	9.67 ± 1.06	21.31 ± 2.40	-	-
Indomethacin (25)	1.15 ± 0.04 ^c	2.45 ± 0.24 ^a	15.86 ± 2.36 ^a	34.51 ± 3.66 ^b	4.16 ± 1.29	-
Omeprazole (20)	5.06 ± 0.26 ³	1.14 ± 0.08 ^{ns}	5.59 ± 0.08 ³	12.08 ± 1.24 ³	1.16 ± 0.02 ³	81.16
Hesperidin (150)	3.60 ± 0.08 ³	1.93 ± 0.02 ^{ns}	10.95 ± 2.25 ^{ns}	22.64 ± 2.50 ¹	3.12 ± 0.03 ^{ns}	32.46
Hesperidin (300)	4.06 ± 0.09 ³	1.71 ± 0.04 ^{ns}	9.54 ± 1.03 ^{ns}	18.82 ± 2.12 ³	2.57 ± 0.05 ^{ns}	58.20
Hesperidin (450)	4.63 ± 0.13 ³	1.68 ± 0.05 ^{ns}	6.13 ± 0.93 ²	15.14 ± 1.63 ³	1.83 ± 0.06 ²	70.22

Note. Values are expressed as Mean \pm SEM six rat each treatment group. ^a $p < 0.05$, ^b $p < 0.01$ and ^c $p < 0.001$ compared to vehicle control. ¹ $p < 0.05$, ² $p < 0.01$ and ³ $p < 0.001$ compared to indomethacin treated group and ns = non-significant for both.

Table 2

Effect of hesperidin on biochemical parameters of indomethacin induced gastric ulcer on rats.

Treatment (mg/kg)	GSH (Umol/g protein)	SOD (U/mg protein)	CAT (U/mg protein)	Mucin (µg/g gastric tissue)	Protein (mg/100 mg gastric tissue)
Vehicle control	3.24 ± 0.57	223.45 ± 12.02	18.63 ± 2.02	380.50 ± 15.14	16.82 ± 2.11
Indomethacin (25)	0.56 ± 0.01 ^b	112.64 ± 10.64 ^b	9.21 ± 1.57 ^a	232.21 ± 14.05 ^b	8.15 ± 1.45 ^a
Omeprazole (20)	2.98 ± 0.46 ³	219.23 ± 11.95 ³	17.65 ± 2.25 ¹	392.68 ± 15.16 ³	14.50 ± 2.86 ^{ns}
Hesperidin (150)	0.64 ± 0.03 ^{ns}	211.54 ± 12.33 ³	12.34 ± 1.86 ^{ns}	246.54 ± 13.28 ^{ns}	10.19 ± 1.34 ^{ns}
Hesperidin (300)	0.75 ± 0.02 ^{ns}	216.65 ± 11.98 ³	12.51 ± 1.05 ^{ns}	255.28 ± 12.54 ^{ns}	10.24 ± 1.58 ^{ns}
Hesperidin (450)	1.85 ± 0.11 ¹	221.28 ± 13.73 ³	18.28 ± 2.18 ¹	319.64 ± 13.17 ²	13.85 ± 1.73 ^{ns}

Note. Values are expressed as Mean ± SEM six rat each treatment group. ^a*p*<0.05 and ^b*p*<0.001 compared to vehicle control. ¹*p*<0.05, ²*p*<0.01 and ³*p*<0.001 compared to indomethacin treated group and ns = non-significant for both.

effect of hesperidin (450 mg/kg) was evident with the significant rise in the level of SOD (*p* < 0.001), GSH and catalase (*p* < 0.05), compared to the sham group. The normal level of mucin µg/gm gastric tissue (380.50 ± 15.14) was extreme significantly reduced by indomethacin (232.21 ± 14.05) whereas hesperidin significantly normalized (319.64 ± 13.17) at 450 mg/kg dose comparable to omeprazole. Level of gastric tissue protein was also reduced by indomethacin and hesperidin was unable to affect it significantly.

Unlike indomethacin HRS induced ulceration has not increased the volume of gastric juice, but elevated pH extreme significantly (*p* < 0.001). Free and total acidity was moderately (*p* < 0.05) elevated along with 5.16 ± 1.2 ulcer index. The anti-ulcer property of hesperidin in HRS model is evident from its significant reduction in pH at all three doses (*p* < 0.001), and total acidity and ulcer index (*p* < 0.01-0.001) at 300 and 450 mg/kg doses (Table 3).

Hypothermic stress ulcer was involved with significant reduction of GSH (*p* < 0.01), but not SOD and catalase in combination with decrease in mucin and protein (*p* < 0.01-0.001 respectively). Hesperidin treated animals showed significantly increased level of GSH, protein (0.05) and mucin (0.001) only at highest dose 450 mg/kg, other doses were ineffective (Table 4).

Gastric wall mucosa plays a main role in the protection of the gastric walls from aggressive factors that are responsible for gastric damage. The mucous layer forms a barrier between gastric wall and acid. Normal animal gastric mucosa showed clear and proper arrangement of cells (Figs. 1A and 2A) in photographic representations. Indomethacin induced redness, spot and hemorrhagic ulcers (Fig. 1B). HRS induced moderate ulceration only with red strikes (Fig. 1E). Omeprazole at 20 mg/kg dose and hesperidin at 450 mg/kg dose nearly normalized mucosa only with redness (Figs. 1C, 1D and 1F, 1G).

Table 3

Effect of hesperidin on various parameters of hypothermic restraint stress (HRS) induced ulcer on rats.

Treatment (mg/kg)	Gastric juice				Ulcer index	% protection
	pH	Volume (ml/100 g)	Free acidity (Meq/l/100 g)	Total acidity		
Vehicle control	3.34 ± 0.02	1.73 ± 0.02	9.67 ± 1.06	21.31 ± 2.40	-	-
Indomethacin (25)	2.22 ± 0.02 ^b	2.85 ± 0.94 ^{ns}	10.86 ± 1.36 ^a	31.51 ± 3.66 ^a	5.16 ± 1.2	-
Omeprazole (20)	5.78 ± 0.04 ³	1.34 ± 0.08 ^{ns}	6.49 ± 0.08 ^{ns}	16.08 ± 1.21 ³	1.13 ± 0.02 ³	78.30
Hesperidin (150)	3.50 ± 0.02 ³	1.83 ± 0.02 ^{ns}	9.95 ± 2.25 ^{ns}	21.64 ± 2.40 ^{ns}	4.12 ± 0.03 ^{ns}	39.46
Hesperidin (300)	4.12 ± 0.08 ³	1.71 ± 0.04 ^{ns}	6.14 ± 1.03 ^{ns}	17.82 ± 2.11 ²	2.27 ± 0.05 ²	58.53
Hesperidin (450)	4.73 ± 0.11 ³	1.48 ± 0.05 ^{ns}	4.23 ± 0.93 ¹	13.54 ± 1.64 ³	2.03 ± 0.06 ²	67.25

Note. Values are expressed as Mean ± SEM six rat each treatment group. ^a*p*<0.05 and ^b*p*<0.001 compared to vehicle control. ¹*p*<0.05, ²*p*<0.01 and ³*p*<0.001 compared to indomethacin treated group and ns = non-significant for both.

The histopathological observation showed damage and perforation of the gastric mucosal layer caused by indomethacin (Fig. 2B) in treated rat, whereas HRS induced hemorrhage and edematous appearance of the gastric tissue (Fig. 2E). Hesperidin-treated animals showed moderate

recovery of mucosal damage in comparison to well organized mucosa of omeprazole against indomethacin (Figs. 2C and 2D). Omeprazole (20 mg/kg) and hesperidin (450 mg/kg) allowed regeneration but damage to the mucosa was only moderately recovered (Figs. 2F and 2G).

Table 4

Effect of hesperidin on biochemical parameters of hypothermic restraint stress (HRS) ulcer on rats.

Treatment (mg/kg)	GSH (Umol/g protein)	SOD (U/mg protein)	CAT (U/mg protein)	Mucin (μg/g gastric tissue)	Protein (mg/100 mg gastric tissue)
Vehicle control	3.24 ± 0.57	223.45 ± 12.02	18.63 ± 2.02	380.50 ± 15.14	16.82 ± 3.11
Indomethacin (25)	1.51 ± 0.01 ^a	197.61 ± 10.64 ^{ns}	15.21 ± 1.57 ^{ns}	213.21 ± 14.07 ^b	6.13 ± 1.55 ^a
Omeprazole (20)	2.84 ± 0.42 ¹	206.23 ± 12.95 ^{ns}	16.65 ± 2.25 ^{ns}	354.68 ± 14.16 ²	12.50 ± 1.46 ^{ns}
Hesperidin (150)	1.69 ± 0.02 ^{ns}	210.51 ± 11.78 ^{ns}	12.34 ± 2.86 ^{ns}	244.54 ± 12.28 ^{ns}	9.19 ± 1.34 ^{ns}
Hesperidin (300)	1.77 ± 0.02 ^{ns}	219.65 ± 12.74 ^{ns}	14.43 ± 2.15 ^{ns}	253.28 ± 11.54 ^{ns}	10.24 ± 1.85 ^{ns}
Hesperidin (450)	2.75 ± 0.13 ¹	224.28 ± 13.84 ^{ns}	17.28 ± 2.19 ^{ns}	318.54 ± 14.17 ²	14.85 ± 1.78 ¹

Note. Values are expressed as Mean ± SEM six rat each treatment group. ^a*p*<0.01 and ^b*p*<0.001 compared to vehicle control. ¹*p*<0.05 and ²*p*<0.001 compared to indomethacin treated group and ns = non-significant for both.

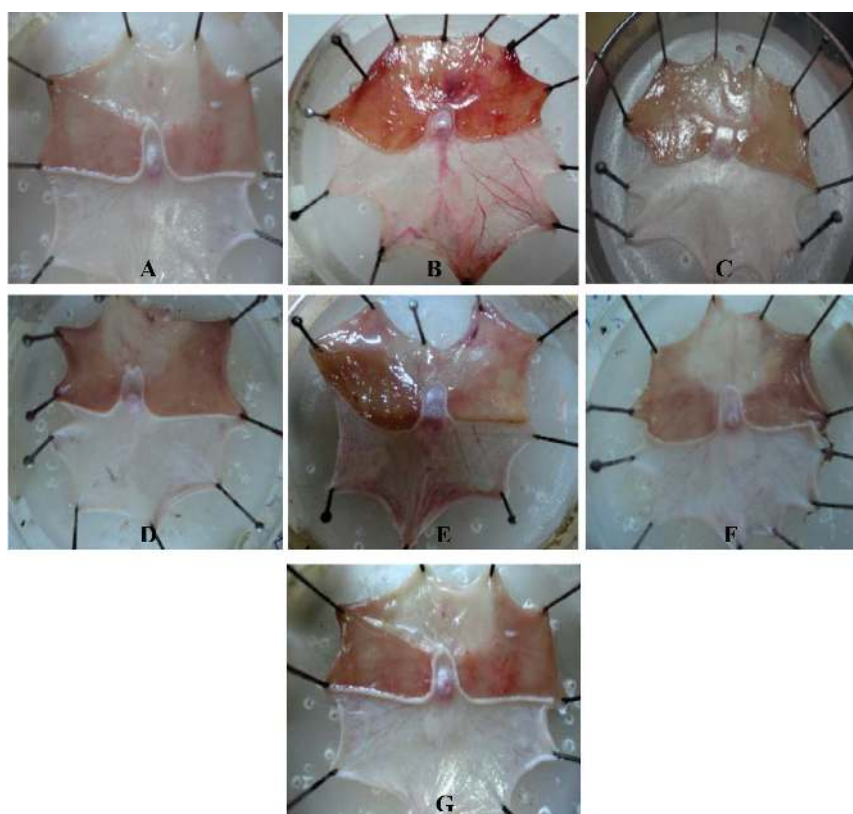


Figure 1 – Gastric mucosal layer. A, Stomach mucosa of vehicle control animal without any lesion or redness. B, The severely hemorrhagic mucosal layer of indomethacin-induced ulcerated animal; C and D, Omeprazole (20 mg/kg) and hesperidin (450 mg/kg) significantly prevent hemorrhagic damage of the mucosa; E, Hypothermic Restraint Stress (HRS) induced moderate ulceration of the gastric tissue; F, The gastro-protective drug omeprazole (20 mg/kg) effectively normalizes damaged mucosal layer; G, The hesperidin (450 mg/kg) treated animal showed only some redness in gastric mucosa.

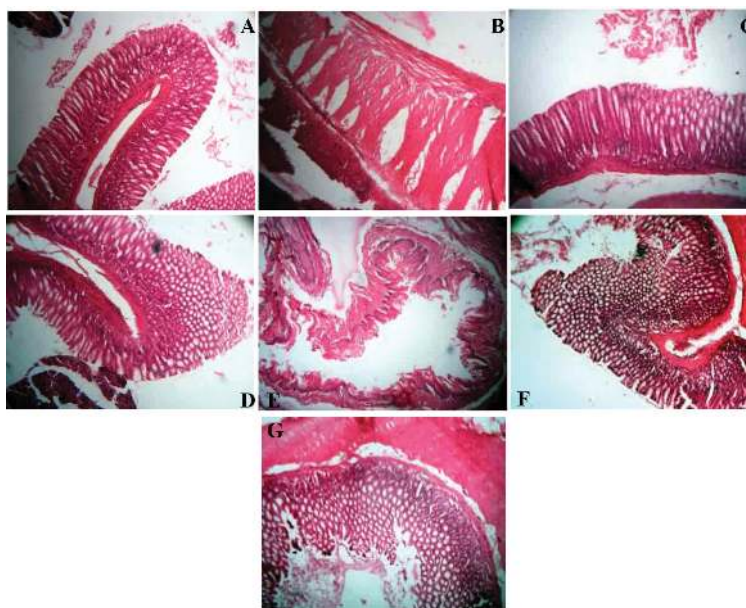


Figure 2 – Histopathologic photomicrograph of gastric mucosal layer. A, Stomach mucosa of vehicle control animals showed clear and proper arrangement of cells; B, The cells were damaged and created opaque regions in gastric mucosa of indomethacin-induced ulcer animal groups; C, The standard gastro-protective drug omeprazole (20 mg/kg) effectively restores damaged cells of gastric mucosa layer; D, The hesperidin (450 mg/kg) treated animal showed regeneration of ulcerative cells and moderately arranged layer in gastric mucosa; E, Degeneration, hemorrhage and edematous appearance of the gastric tissue in Hypothermic Restraint Stress (HRS) induced ulcer model were shown in figure. F and G, Omeprazole (20 mg/kg) and hesperidin (450 mg/kg) showed regeneration and prevented the formation of hemorrhagic damage and edema but with damaged mucosa.

Discussion

Plants are sources of some well known anti-ulcer drugs such as: liquorice (dehydroglycerrizinic acid), *Piper betel* L. (piperine), *Emblia officinalis* (emblin), *Terminalia bellerica* and *Terminalia chebula* mostly in the category of glycosides and flavonoids (Maurya and Srivastava, 2011). Hesperidin (1) is a flavanone glycoside abundant in sweet orange and lemon, and is an inexpensive by-product of citrus cultivation. The present investigation was designed to explore the anti-ulcer activity of hesperidin isolated from *C. sinensis* on stress and oxidative damage-induced gastric ulcer models, looking into its potential antioxidant and anti-inflammatory properties.

A peptic ulcer is an imbalance between aggressive factors and the maintenance of the mucosal integrity through the endogenous defense mechanism, although in most of the cases the etiology of ulcer is unknown (Bafna and Balaraman, 2005). Although anti-ulcer treatment has improved, peptic ulcers along with their complication still involve significant mortality. The discovery of novel and more effective anti-ulcer drugs is accompanied by the introduction of newer experimental methods to evaluate the anti-ulcer activity on different types of ulcers, and elucidation of their possible modes of action. Various mechanism are involved in ulcer production in different experimental models, hence it is not possible to assess anti-ulcer activity of a particular component studying a single mechanism (Parmar and Desai, 1993).

The major underlying factor of ulcer formation is the generation of free radicals. Oxygen-derived free radicals play an important role in the pathogenesis of injury of various tissues, including the digestive system. In addition, involvement of oxygen free radicals such as the superoxide anion, hydrogen peroxide, and hydroxyl radical are well established in the pathogenesis of ischemic injury of gastrointestinal mucosa, as in other models of mucosal damage induced by indomethacin. Hypothermic restraint stress and indomethacin-induced stress activates free radical in the rat's empty stomach, which further induces ulcer formation (Senay and Levine, 1967; Bhargava et al., 1973). The parameters used for the evaluation of anti-ulcer activity were: ulcer index, pH, gastric volume, free and total acidity along with antioxidant defensive enzyme levels, and histopathology. Indomethacin induced ulceration was associated with the increase in the gastric volume, free acidity, total acidity, ulcer index and decreases in pH, GSH, SOD, catalase, mucin and protein, compared to the control group.

Indomethacin inhibits the synthesis of cytoprotective prostaglandins, induced by COX-1 and COX-2 in the gastric tissue (Whittle, 1981). Reactive oxygen species (ROS) possess an important role in the pathogenesis of mucosal damage caused by indomethacin, ethanol and other irritating agents besides the inhibition of COX enzymes (Terano et al., 1989; Yoshikawa et al., 1993). Hesperidin at 300 and 450 mg/kg dose significantly increased the pH, and decreased total and free acidity, as well as ulcer index on indomethacin-induced ulcerated rat stomach.

In the present study, the level of GSH, SOD, catalase, mucin and protein level was significantly reduced by indomethacin in rat's gastric tissues. Indomethacin, like non-steroidal analgesic and anti-inflammatory drugs, is reported to decrease the level of GSH, SOD and catalase in tissue (Takeuchi et al., 1991; Dengiz et al., 2007). The reduced level of GSH, SOD, catalase, mucin and protein was also significantly elevated by hesperidin at 450 mg/kg dose. Hesperidin at 300 and 450 mg/kg dose showed 58.20 and 70.22% ulcer protection, respectively, indicating its cytoprotective effect.

HRS induces ulceration by implementing both emotional as well as physiological stress. Stress provokes release of free radicals, which causes mucosal cell damage, and instability of antioxidant enzyme status (Das and Banerjee, 1993). HRS induced ulcerated animals showed an increase of free and total acidity, and ulcer index, along with a decrease in pH while volume of gastric content was unaffected. GSH acts as an important endogenous defensive substance against the ROS and its level was found to be reduced in rats subjected to HRS (Sahin and Gumuslu, 2007). Stress caused both sympathetic and parasympathetic stimulation of the stomach leading to local hypoxia. The GSH level was found to be significantly reduced in rats subjected to stress along with mucin and protein. The ischemic condition caused an increase in the levels of H_2O_2 , which in conjugation with O_2 generates OH^\cdot ions, which oxidized various cellular constituents such as proteins, and membrane lipids. Lipid peroxidation causes loss of membrane fluidity and allows the emergence of ulcers (Tandon et al., 2004). Though HRS is reported to reduce thiobarbituric acid reactive substance (TBARS), GSH, SOD and catalase (Sood et al., 2010), in the present study HRS did not affect SOD and catalase levels but decreased GSH, mucin and protein levels significantly. Hesperidin at 450 mg/kg dose showed 67.25% protection against stress induced ulceration with effective reduction in pH, acidity, mucin and protein level. Hesperidin in both the models had no significant effect on volume of gastric content indicating absence of anti-secretory effect.

Macroscopic and histopathological evidence showed that 450 mg/kg dose of hesperidin protected mucosal layer from spot and hemorrhagic ulcers caused by indomethacin and hypothermic stress, and also reduced the damage to glandular tissue of stomach wall. Gastric mucosa plays a vital role in the protection of gastric wall from aggressive factors responsible for damage by forming a barrier (Hills, 1993). Integration of mucosa essentially provides protection to the inner glandular and muscular layer of stomach wall. Hesperidin treatment not only maintained gastric mucosa but also helped in the regeneration of the damaged region, proving its cytoprotective effects by maintaining efficient gastric mucosal microvascular integrity.

Results indicate that a low dose of hesperidin (150 mg/kg) was not effective in treating ulcer, a medium dose was moderately effective compared to omeprazole but the higher dose 450 mg/kg very efficiently protects the stomach from ulcers due to its antioxidant activity. Ulcer index is one of the confirmatory parameters of ulcerogenesis by noxious elements. HRS induced more severe ulceration compared to indomethacin whereas oxidative damage was more

evident with indomethacin. Several mechanisms have been proposed to explain the gastro-protective effect of flavonoids, among them are: free radical scavenging, increase in mucosal prostaglandin content, improvement in gastric tissue microcirculation and cytoprotection, for which flavonoids could have a therapeutic potential ideal for treatment of gastrointestinal diseases. Hesperidin (1), the most abundant natural flavonoids, prevents oxidative injury and cell death by scavenging oxygen radicals, protecting against lipid peroxidation and chelating metal ions (Fraga et al., 1987; Korkina and Afanas'ev, 1997; Miller and Rice-Evans, 1997). The study outcome proposes that anti-ulcer effect of hesperidin is due to antioxidant, mucoprotective and cytoprotective effects on gastric mucosa but no anti-secretory effect.

Conclusion

All these observations emphasize the potential ulcer protective effect of hesperidin against indomethacin and HRS, which is associated with antioxidant and free radical scavenging ability in the stomach mucosal tissue. Antioxidant potential has played a significant role in preventing ulcer by hesperidin as the ulcer protection was higher against indomethacin which produces ulceration primarily due to local oxidative damage. Hypothermic stress ulceration depends not only on hypoxic damage but also on the activation of autonomic nervous system. In this case, hesperidin has moderate effect as it may not inhibit the autonomic system related activated hypersecretory response in gastric mucosa. Detailed molecular and receptor level mechanistic studies are required to explore the potential anti-ulcer therapeutic applicability of hesperidin.

Authors' contributions

KS contributed in collecting plant sample and identification, confection of herbarium samples, performing the laboratory work, conduction of biological studies, chromatographic analysis and initial paper drafting. PB contributed in study design, supervision of laboratory work, data analysis, drafted the paper and contributed to critical reading of the manuscript. All the authors have read the final manuscript and approved the submission.

Conflicts of interest

The authors declare no conflicts of interest.

Acknowledgment

Heartiest thanks are also due to Aristo Pharmaceuticals Ltd., Bhopal, for providing the gift sample of omeprazole used for the study.

R E F E R E N C E S

- Aebi, H.U., 1983. Catalase. In: Bergmeyer, H.U., (ed.) *Methods in enzymatic Analysis*. Vol 3. New York: Academic Press, p. 276-286.
- Anonymous, 2006. *The Wealth of India: Raw Materials*. New Delhi: Council of Scientific and Industrial Research, India, p. 625-626.
- Bafna, P.A., Balaraman, R., 2005. Anti-ulcer and anti-oxidant activity of pepticare, a herbomineral formulation. *Phytomedicine* 12, 264-270.
- Bhargava, K.P., Gupta, M.B., Tangri, K.K., 1973. Mechanism of ulcerogenic activity of indomethacin and ocyphenbutazone. *Eur. J. Pharmacol.* 22, 191-195.
- Borrelli, F., Izzo, A.A., 2000. The Plant kingdom as a source of anti-ulcer remedies. *Phytother. Res.* 14, 581-591.
- Chaturvedi, A., Kumar, M., Hawani, G., Chaturvedi, H., Goel, R.K., 2007. Effect of ethanolic extract of *Eugenia jamolana* seeds on gastric ulceration and secretion in rat. *Ind. J. Physiol. Pharmacol.* 51, 131-140.
- Cheng, T., Wen-Li, L., Liu, H.Y., Kun-Teng, W., Chun-Chao, C., Ching-Chiung, W., 2011. Gastroprotective effects of Ping-Wei San on indomethacin-induced gastric ulcer. *Food Drug Anal.* 19, 509-516.
- Cho, J., 2006. Antioxidant and neuroprotective effects of hesperidin and its aglycone hesperetin. *Arch. Pharm. Res.* 29, 699-706.
- Corne, S.J., Morrissey, S.M., Woods, R.J., 1974. A method for the quantitative estimation of gastric barrier mucus. *J. Physiol.* 242, 116-117.
- Dan, B., Andrew, G., 1986. *Chinese Herbal Medicine: Materia Medica*. Seattle: Eastland Press, p 334-335.
- Das, D., Banerjee, R.K., 1993. Effect of stress on the antioxidant enzymes and gastric ulceration. *Mol. Cell. Biochem.* 1125, 115-125.
- Del-Rio, A., Obdulio, B.G., Castillo, J., Marin, F.R., Ortuno, A., 1992. Uses and properties of citrus flavonoids. *J. Agric. Food. Chem.* 45, 4505-4515.
- Dengiz, G.O., Gursan, N., 2005. Effect of *Momordica charantia* L. on indomethacin- induced ulcer model in rat. *Turk. J. Gastroenterol.* 16, 85-88.
- Dengiz, G.O., Odabasoglu, F., Halici, Z., Cadirci, E., Suleyman, H., 2007. Gastroprotective and antioxidant effects of montelukast on indomethacin-induced gastric ulcer in rats. *J. Pharmacol. Sci.* 105, 94-102.
- Diener, W., Mischke, U., Kayser, D., Schleder, E., 1995. The evaluation of the OECD modified version of acute toxicity class method (oral). *Arch. Toxicol.* 69, 729-734.
- Falcao, H.S., Leite, J.A., Barbosa-Filho, J.M., Athayde-Filho, F.P., Chaves, M.C.O., Moura, M.D., Ferreira, A.L., de Almeida, A.B., Souza-Brito, A.R., Melo Diniz M.F.F., Batista, L.M., 2008. Gastric and duodenal anti-ulcer activity of alkaloids. *Molecules* 13, 3198-223.
- Fraga, C.G., Martino, V.S., Ferraro, G.E., Coussio, J.D., Boveris, A., 1987. Flavonoids as antioxidants evaluated by *in vitro* and *in situ* liver chemiluminescence. *Biochem. Pharmacol.* 36, 717-720.
- Garg, A., Garg, S., Zaneveld, L.J., Singla, A.K., 2001. Chemistry and pharmacology of the Citrus flavonoid hesperidin. *Phytother. Res.* 15, 655-669.
- Gattuso, G., Barrec, D., Gargiulli, C., Leuzzi, U., Caristi, C. 2007. Flavonoid composition of citrus juices. *Molecules* 12, 1641-73.
- Gorinstein, S., Huang, D., Leontowicz, H., Leontowicz, M., Yamamoto, K., Soliva-Fortuny, R., Martin Belloso, O., Martinez Ayala, A.L., Trakhtenberg, S., 2006. Determination of naringin and hesperidin in citrus fruit by high performance liquid chromatography. The antioxidant potential of citrus fruit. *Acta Chromatogr.* 17, 108-124.
- Harris, C.S., Mo, F., Migahed, L., Chepelev, L., Haddad, P.S., Wright, J.S., Willmore, W.G., Arnason, J.T., Bennett, S.A., 2007. Plant phenolics regulate neoplastic cell growth and survival: A quantitative structure-activity and biochemical analysis. *Can. J. Physiol. Pharmacol.* 85, 1124-38.
- Hawk, P.B., 1965. Hawk's Physiological Chemistry. In: Oster BL (eds.) 14th ed. New York: McGraw-Hill Book Co., p. 483.
- Hendrickson, R., Kesterson, J.W., 1954. *Hesperidin, the principal glycoside of oranges*. Bulletin 545. Florida/Gainesville: University of Florida, Agricultural Experiment Stations, p. 1-43.
- Hills, B.A., 1993. Gastric mucosal barrier: evidence for *Helicobacter pylori* ingesting gastric surfactant and deriving protection from it. *Gut.* 34, 588-593.
- Hirata, A., Murakami, Y., Shoji, M., Kadoma, Y., Fujisawa, S., 2005. Kinetics of radical-scavenging activity of hesperetin and hesperidin and their inhibitory activity on COX-2 expression. *Anticancer Res.* 25, 3367-3374.
- Ikan, R., 1991. *Natural products: A laboratory guide*. 2nd ed. London: Academic Press.
- Jeong, J.M., Choi, C.H., Kang, S.K., Lee, I.H., Lee, J.Y., Jung, H., 2007. Antioxidant and chemosensitizing effects of flavonoids with hydroxy and/or methoxy groups and structure-activity relationship. *J. Pharm. Pharm. Sci.* 10, 537-546.
- Kale, A., Gawande, S., Kotwal, S., 2008. Cancer phytotherapeutics: Role for flavonoids at the cellular level. *Phytother. Res.* 22, 567-577.
- Kokate, C.K., Purohit, A.P., Gokhale, S.B., 2001. *Text Book of Pharmacognosy: Carbohydrate and derived products, drugs containing glycosides, drugs containing tannins, lipids, proteins alkaloids*. 7th ed. India: Nirali Prakashan, p. 133-166, 167-254, 255-269, 272-310, 428-523.
- Korkina, L.G., Afanas'ev, I.B., 1997. Antioxidants and chelating properties of flavonoids. *Adv. Pharmacol.* 38, 151-163.
- Kulkarni, S.K., 2000. *Hand book of Experimental Pharmacology*. 3rd ed. Delhi: Vallabh Prakashan, p. 148-150.
- Lee, J.H., Lee, S.H., Kim, Y.S., Jeong, C.S., 2009. Protective effects of neohesperidin and poncirin isolated from the fruits of *Poncirus trifoliata* on potential gastric disease. *Phytother. Res.* 23, 1748-1753.
- Lowry, O.H., Rosenbrough, N.J., Farr, A.L., Randall, R.J., 1951. Protein measurement with folin phenol reagent. *J. Biol. Chem.* 193, 265-275.
- Maurya, U., Srivastava, S., 2011. Traditional Indian herbal medicine used as antipyretic, anti-ulcer, antidiabetic and anticancer: A review. *Int. J. Res. Pharmacy Chem.* 1, 1152-1159.
- Miller, N.J., Rice-Evans, C.A., 1997. The relative contribution of ascorbic acid and phenolic antioxidants to the total antioxidant activity of orange and apple fruit juices and blackcurrant drink. *Food Chem.* 60, 331-337.
- Misra, H.P., Fridovich, I., 1979. The role of superoxide anion in the autoxidation of epinephrine and a simple assay for superoxide dismutase. *J. Biol. Chem.* 254, 3170-3175.
- Nanji, A.A., Jakelainen, K., Fotouhinia, M., Rahemtulla, A., Thomas, P., Tipoe, L.G., Su, G.L., Dannenberg, A.J., 2002. Increased severity of alcoholic liver injury in female rats: Role of oxidative stress, endotoxin and chemotoxin. *Am. J. Physiol-Gastrointest. Liver. Physiol.* 281, G1348-1356.
- Naruszewicz, M., Laniewska, I., Millo, B., Dłuzniewski, M., 2007. Combination therapy of statin with flavonoids rich extract from chokeberry fruits enhanced reduction in cardiovascular risk markers in patients after Myocardial Infarction (MI). *Atherosclerosis* 194, 179-184.
- Nataraj, H.N., Murthy, R.L.N., Setty, S.R., 2009. *In vitro* quantification of flavonoids and phenolic content of Suran. *Int. J. Pharm.Tech. Res.* 1, 1063-1067.

- Orallo, F., Alvarez, E., Basaran, H., Lugnier, C., 2004. Comparative study of the vasorelaxant activity, superoxide-scavenging ability and cyclic nucleotide phosphodiesterase-inhibitory effects of hesperetin and hesperidin. *Naunyn Schmiedebergs Arch. Pharmacol.* 370, 452-463.
- Parmar, H.S., Kar, A., 2008. Medicinal values of fruit peels from *Citrus sinensis*, *Punica granatum* and *Musa paradisiaca* with respect to alteration in tissue lipid peroxidation and serum concentration of glucose, insulin, and thyroid hormones. *J. Med. Chem.* 11, 376-381.
- Parmar, N.S., Desai, J.K., 1993. A review of the current methodology for the evaluation of gastric and duodenal anti-ulcer agents. *Ind. J. Pharmacol.* 25, 120-135.
- Rossi, G.V., Packman, E.W., Goldberg, M.E., 1957. Studies on the effects of ascorbic acid and hesperidin upon histamine-induced gastric ulcers in guinea pigs. *Am. J. Pharm. Sci. Support. Public Health* 129, 89-94.
- Sahin, E., Gumuslu, S., 2007. Immobilization stress in rat tissues: Alterations in protein oxidation, lipid peroxidation and antioxidant defense system. *Comp. Biochem. Physiol. Part C: Toxicol. Pharmacol.* 144, 342-347.
- Senay, S.E., Levine, R.J., 1967. Synergism between cold and restraint for rapid production of stress ulcer in rats. *Proc. Soc. Exp. Biol. Med.* 124, 1221-1223.
- Sokmen, M., Serkedjieva, J., Daferera, D., Gulluce, M., Polissiou, M., Tepe, B., Akpulat, H.A., Sahin, F., Sokmen, A., 2004. *In vitro* antioxidant, antimicrobial, and antiviral activities of the essential oil and various extracts from herbal parts and callus cultures of *Origanum acutidens*. *J. Agric. Food. Chem.* 52, 3309-3312.
- Sood, S., Muthuraman, A., Gill, N.S., Bali, M., Sharma, P.D., 2010. Effect of *Citrus karna* peel extract on stress induced peptic ulcer in rat. *J. Biol. Sci.* 10, 231-236.
- Suárez, J., Herrera, M.D., Marhuenda, E., 1996. Hesperidin and neohesperidin dihydrochalcone on different experimental models of induced gastric ulcer. *Phytother. Res.* 10, 616-618.
- Takeuchi, K., Ueshima, K., Hironaka, Y., Fujioka, Y., Matsumoto, J., Okabe, S., 1991. Oxygen free radicals and lipid peroxidation in the pathogenesis of gastric mucosal lesions induced by indomethacin in rats. Relation to gastric hypermotility. *Digestion* 49, 175-184.
- Tandon, R., Khanna, H.D., Dorababu, M., Goel, R.K., 2004. Oxidative stress and antioxidant status in peptic ulcer and gastric carcinoma. *Ind. J. Physiol. Pharmacol.* 48, 115-118.
- Terano, A., Hiraishi, H., Ota, S., Shiga, J., Sugimoto, T., 1989. Role of superoxide and hydroxyl radicals in rat gastric mucosal injury induced by ethanol. *Gastroenterol. Jpn.* 24, 488-493.
- Tietze, F., 1969. Enzymic method for quantitative determination of nanogram amounts of total and oxidized glutathione: applications to mammalian blood and other tissues. *Anal. Biochem.* 27, 502-522.
- Whittle, B.J., 1981. Temporal relationship between cyclooxygenase inhibition, as measured by prostacyclin biosynthesis, and the gastrointestinal damage induced by indomethacin in the rat. *Gastroenterology* 80, 94-98.
- Yoshikawa, T., Naito, Y., Kishi, A., Tomii, T., Kaneko, T., Iinuma, S., Ichikawa, H., Yasuda, M., Takahashi, S., Kondo, M., 1993. Role of active oxygen, lipid peroxidation, and antioxidants in the pathogenesis of gastric mucosal injury induced by indomethacin in rats. *Gut.* 34, 732-737.
- Zia, U.R., 2006. Citrus peel extract-a natural source of antioxidant. *Food Chem.* 99, 450-454.