



## UvA-DARE (Digital Academic Repository)

### Ultrasonic dissection for endoscopic surgery

Gossot, D.; Buess, G.; Cuschieri, A.; Leporte, E.; Lirici, M.; Marvik, R.; Meijer, D.W.; Melzer, A.; Schurr, M.O.

**DOI**

[10.1007/s004649901002](https://doi.org/10.1007/s004649901002)

**Publication date**

1999

**Published in**

Surgical Endoscopy and other interventional Techniques

[Link to publication](#)

**Citation for published version (APA):**

Gossot, D., Buess, G., Cuschieri, A., Leporte, E., Lirici, M., Marvik, R., Meijer, D. W., Melzer, A., & Schurr, M. O. (1999). Ultrasonic dissection for endoscopic surgery. *Surgical Endoscopy and other interventional Techniques*, 13, 412-417. <https://doi.org/10.1007/s004649901002>

**General rights**

It is not permitted to download or to forward/distribute the text or part of it without the consent of the author(s) and/or copyright holder(s), other than for strictly personal, individual use, unless the work is under an open content license (like Creative Commons).

**Disclaimer/Complaints regulations**

If you believe that digital publication of certain material infringes any of your rights or (privacy) interests, please let the Library know, stating your reasons. In case of a legitimate complaint, the Library will make the material inaccessible and/or remove it from the website. Please Ask the Library: <https://uba.uva.nl/en/contact>, or a letter to: Library of the University of Amsterdam, Secretariat, Singel 425, 1012 WP Amsterdam, The Netherlands. You will be contacted as soon as possible.

## Ultrasonic dissection for endoscopic surgery

D. Gossot, G. Buess, A. Cuschieri, E. Leporte, M. Lirici, R. Marvik, D. Meijer, A. Melzer, M. O. Schurr  
(The E.A.E.S. Technology Group)

Saint-Louis Hospital, 1 Av. Cl. Vellefaux, F-75010 Paris, France

Received: 5 March 1998/Accepted: 24 July 1998

**Abstract.** With the development of endoscopic surgery, new hazards of high-frequency (HF) electrosurgery have been recognized. The potential risks of monopolar electrosurgery, the limitations of bipolar technique, and the need to reduce instrument interchange have favored the use of ultrasonic technology, which becomes more and more popular. This work aims at presenting the main features of the currently available ultrasonically activated scalpels, as well as their advantages, limitations, and indications.

**Key words:** Ultrasounds — Ultrasonic dissection — Laparoscopy — Endoscopic surgery

### Background

High-frequency (HF) electrosurgery has been used for years as one of the most relevant tools for the surgeon. Until now, most of the complications related to the use of HF electrosurgery were skin burns [19]. These result from inadequate use of the ground plate and can be avoided in most cases. With the recent development of surgical endoscopy, new questions about the use of HF electrosurgery have been raised. Not only skin burns have been reported but also internal organ burns, which had not previously been described.

In 1995, a survey by the American College of Surgeons on electrosurgical complications stated that 18% of respondent surgeons had personally experienced an electrosurgical burn in a patient during laparoscopy [30]. These data may be an overestimate because a surgeon may attribute to HF electrosurgery a complication caused by a direct injury from a Veress needle, a trocar, or any instrument. However, the survey highlights a real and new concern in surgery.

Among the causes of electrosurgical burns are the following [12, 16, 30]:

1. Direct thermal injury from an instrument tip that is briefly out of the field of vision of the operator
2. Insulation failure
3. Direct contact, if an energized active electrode is inadvertently brought into contact with the laparoscope or any other conductive instrument
4. Capacitive coupling, defined as the passage of current across the insulated part of a unipolar instrument electrode to an adjacent conductor. This conductor may be a metal tube surrounding the insulated part of the electrode or a biologic tissue (e.g., a bowel loop).

These newly recognized hazards of HF electrosurgery have led to suggested precautions [30]. It is recommended that a bipolar technique be used whenever possible [12]. If a monopolar technique is used, it is advisable to choose the lowest power setting and low voltage [30]. However, the forementioned survey of the American College of Surgeons stated that (a) 86% of surgeons prefer monopolar to bipolar technology, and (b) when using a monopolar technique the coagulation mode (i.e., higher power [20–40 W]) is preferred to the cut mode.

Bipolar technique has been recommended as most efficient way to reduce electrosurgical risks. By passing from one jaw to another, the current does not spread to surrounding tissues. In addition, bipolar current does not generate capacitive coupling. However, despite its recognized advantages, bipolar electrosurgery has not been accepted in laparoscopic surgery. Only 14% of surgeons use bipolar or laser techniques [30]. Most complain that bipolar HF electrosurgery is difficult to use, is time consuming, and produces excessive charring [25]. The hazards of monopolar HF electrosurgery, the limitations of bipolar technique, the need to reduce instrument interchange [4] are three reasons that make the ultrasonic scalpel an appealing tool for endoscopic surgery.

Ultrasonic waves are above the audible range (20,000 Hz). They are produced by applying electrical energy to either a piezoelectric or a magnetic transducer. An electric

field or a potential difference applied across a crystal produces a mechanical deformation. Alternating electric fields produce alternating mechanical vibrations of the same frequency. A piezoelectric material, such as a thin slab of quartz, can convert a high-frequency alternating electric signal to an ultrasonic wave of the same frequency. Mechanical vibrations have various effects on tissues such as cutting or coagulation. There are two very different ultrasonic surgical technologies available: the ultrasonic cavitation aspirator and the ultrasonically activated scalpel. Although the ultrasonically activated scalpel tends to be the more popular, it is helpful to understand the differences between the two systems.

### The ultrasonic cavitation aspirator

The ultrasonic cavitation aspirator (UCA) is composed of a generator providing electrical energy to a handpiece. The handpiece houses an ultrasonic transducer vibrating at a frequency of 23,500 to 25,000 Hz. The energy is conducted via a hollow tube to a tapered hollow tip that provides aspiration. The vibration of the tip at 23 Hz produces a longitudinal displacement of 200 to 360  $\mu\text{m}$ . The very rapid forward and backward motion of the hollow tip in contact with the tissue produces changes in tissue pressures, thus fragmenting cells and expanding tissue planes. This phenomenon is named cavitation. The cavitation effect results from the creation and implosion of bubbles in liquid. The compression of gases inside the bubbles creates intense heat that denatures proteins. Cavitation mainly occurs in cells with a high water content [20].

The UCA has very little coagulation effect because of cooling by saline irrigation and because of the narrow tissue contact. The UCA is tissue selective because it preferentially breaks cells with a high water content such as adipose tissue. Thus collagen-rich tissues such as nerves or endothelial cells are preserved. The combined powerful suction integrated with the UCA tip aspirates the resulting cell debris. The collagen-rich structures therefore are cleaned up and well identified. These properties make the UCA useful in neurosurgery, liver surgery, and tumor debulking. Regarding liver surgery, two studies have evaluated the use of the UCA for hepatic resection and both found decreased blood loss [6, 14].

Few papers have reported the use of the UCA in surgical endoscopy. Wetter et al. [31] found the UCA helpful during laparoscopic cholecystectomy for dissection of Calot's triangle when the cystic duct and artery were enveloped by fatty tissue. Cuschieri et al. [5] found the UCA very helpful for skeletonization of vessels during laparoscopic colorectal surgery and thoracoscopic esophagectomy. Suzuki et al. [27] reported that the UCA facilitates adrenal separation from the perinephric fat as well as identification and dissection of the adrenal vessels during laparoscopic adrenalectomy. Similar findings were reported by Takeda et al. [29].

However, there are three limitations to the use of the UCA in endoscopic surgery. First, the currently available systems are bulky and cannot be integrated easily within a video trolley. Second, the cavitation effect produces some mist, and although the particles disappear rapidly, there is

some concern about the possible transport of cells by the particles, as has recently been reported with smoke [3]. Third, the UCA has no hemostatic effect and little ability to cut connective tissue, so there is still a need for another means of coagulating and cutting. This limitation is acceptable in open surgery but is a major drawback in endoscopic surgery wherein instrument changes may need to be limited as much as possible [4, 25]. There have been some attempts to overcome this limitation by developing combination devices. An instrument whose tip can accept both an HF electrode and an ultrasonic applicator has been developed by Erbe [7] and other companies (USU, Olympus and CUSA System 300, Valleylab).

Overall, the UCA, although interesting in its concept, seems to have too many limitations for surgical endoscopy. The ultrasonically activated scalpel is more appropriate.

### The ultrasonically activated scalpel

#### *Principle*

The ultrasonically activated scalpel (UAS) is composed of a power supply generator, a piezoelectric transducer housed in the handpiece, and a functional tip (Fig. 1). The transducer consists of a stack of piezoelectric crystals sandwiched between two metal cylinders. It converts electrical energy into mechanical vibration at a frequency ranging from 23.5 to 55.5 kHz, depending on the system (Table 1). The vibration amplitude varies from 80 to 200  $\mu\text{m}$  (Fig. 2). The mechanical vibration is conducted via an extending rod to a scissor blade or a hook blade.

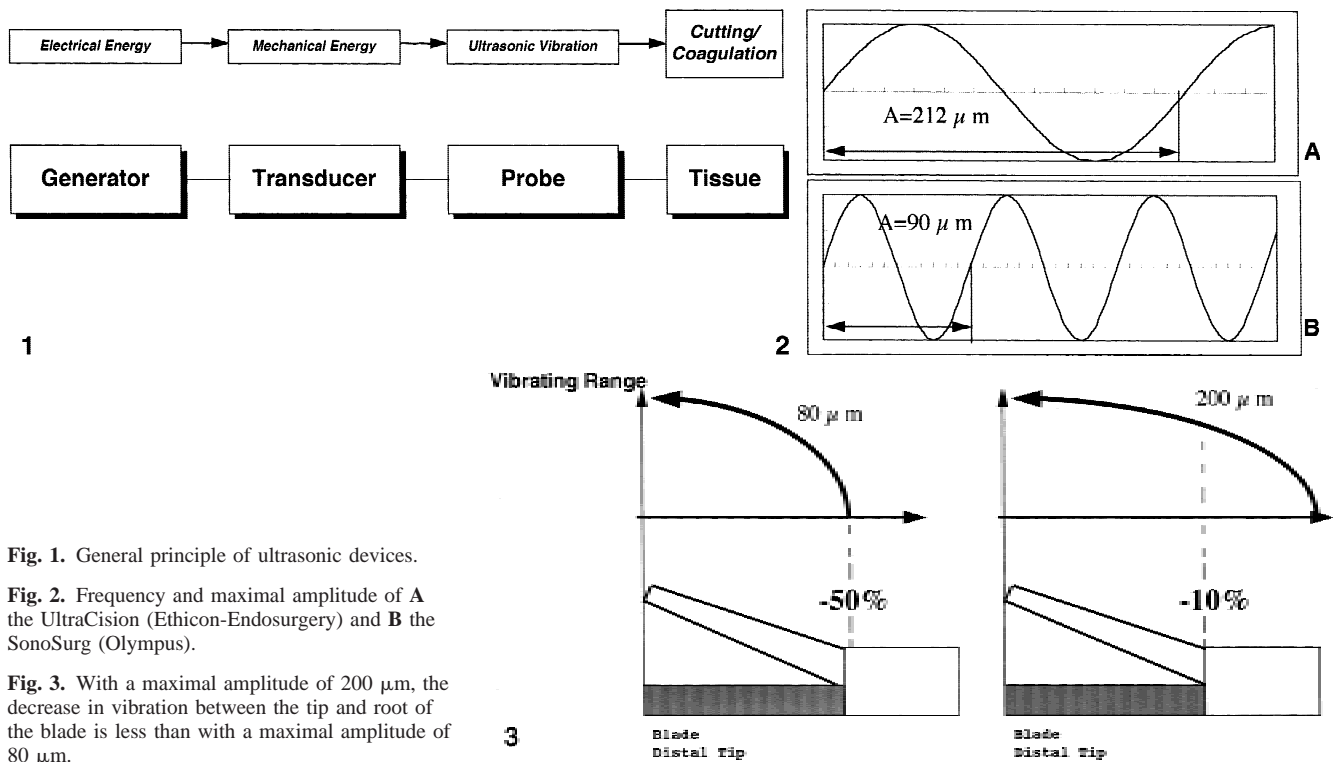
To have a coagulating effect, the blade must be of sufficient size. Amaral and Chrostek [2] have shown that hemostasis is poor when a sharp edge is used because cutting occurs before coagulation. A blade having a small surface area with a blunt edge applies the vibration to such a small area that it causes only cavitation without a coagulation effect. For the same reason, some manufacturers prefer to apply mechanical vibration of high amplitude so as to distribute the vibration better all along the blade length (Fig. 3). The efficiency of an ultrasonic device depends not on its frequency or amplitude alone, but on a combination of both. Indeed, coagulation, which results from the cavitation effect, depends on the velocity of sound. The latter is defined by the formula:  $V = A_{\text{max}} \times 2\pi F \times \text{Cos}(2\pi Ft)$ .

For example, applying the maximal amplitudes and frequencies of the SonoSurg (Olympus) and UltraCision (Ethicon) to this formula gives comparable velocities. With an appropriate scissor blade or hook blade or ball, a coagulation effect is produced as the rapid vibration of the blade denatures tissue proteins by breaking hydrogen bonds. This leads to the formation of a sticky coagulum that seals vessels. It has been demonstrated experimentally that the UAS can seal vessels up to 5 mm in diameter [18].

One main advantage of UAS technology is the possibility of developing endoscopic shears that can be used as dissector, grasping forceps, coagulation forceps, and scissor, all in a single instrument.

#### *Advantages of the ultrasonically activated scalpel*

The lack of current transmission is the major advantage of the UAS. This allows coagulation of vessels very close to



**Fig. 1.** General principle of ultrasonic devices.

**Fig. 2.** Frequency and maximal amplitude of **A** the UltraCision (Ethicon-Endosurgery) and **B** the SonoSurg (Olympus).

**Fig. 3.** With a maximal amplitude of 200  $\mu\text{m}$ , the decrease in vibration between the tip and root of the blade is less than with a maximal amplitude of 80  $\mu\text{m}$ .

**Table 1.** Main features of the three currently available ultrasonically activated scalpels

	UltraCision (Ethicon)	AutoSonix (USSC)	SonoSurg (Olympus)
Diameter (mm)	10	5	11
Frequency (kHz)	55.5	55.5	23.5
Maximum amplitude ( $\mu\text{m}$ )	80	150	200
HF connection	No	No	Yes
Use	Disposable	Disposable	Reusable (autoclavable)
Axial rotation	No	Yes	Yes
Cutting mechanism	By sharp blade	By increasing power	By increasing power
Additional instruments	Yes	Yes	No


the stomach, bowel, or biliary tract without the risks inherent in HF electrocautery [1].

Ultrasonically activated devices also work at a temperature below 80°C, compared with 100°C for electrocautery. As a result, there is no risk of thermal damage to adjacent organs. Meltzer et al. [17] compared experimental seromyotomies using electrocautery and the UAS and found four times less lateral thermal damage with the UAS. Another advantage resulting from the low temperature is that charring is minimized because the collagen denaturation that produces charring and desiccation occurs at 60 to 80°C. Amaral and Chrostek [2] have suggested that minimized charring may explain the low rate of postoperative adhesions compared with electrocautery and laser. By making skin incisions in an animal model, Hambley et al. [13] demonstrated that the UAS produces a 1-mm thermal injury versus 10 mm for electrocautery. The charring observed with bipolar cautery is responsible for some failures of hemostasis because the instrument tip tends to adhere to the

coagulum and weaken it when the instrument is manipulated to disengage it from the vessel [25]. This is never observed with the UAS.

The fact that the UAS does not produce smoke is an interesting feature that ensures better visibility and may also contribute to the reduction of postoperative adhesions [2]. However, cavitation leads to the production of some mist. The latter is more acceptable than smoke because it vanishes much more rapidly than the smoke produced by HF cautery. However, the mist remains a disturbing side effect. There is also some concern about the possible transport of cells in the mist [3].

When used with a scissor-type tip, the UAS is one of the few available multifunctional laparoscopic instruments. It can be used as grasper, dissector, coagulating device, and cutter. This versatility averts complex and time-consuming maneuvers that may cause intraoperative difficulties. Swanstrom and Pennings [28] compared the use of UltraCision and clips for control of short gastric vessels. They



**Fig. 4.** Generator and shears of the AutoSonix system (USSC).

**Fig. 5.** Generator and shears of the SonoSurg system (Olympus).

**Fig. 6.** The multifunctional blade of UltraCision shears (Ethicon-Endosurgery).

**Fig. 7.** **A** Reusable 5-mm hook and **B** coagulating ball of the UltraCision (Ethicon-Endosurgery).

have found that clipping was responsible for more active vessel bleeding and more hematoma formation than was UAS. Laycok et al. [15] in a similar study, showed that the time required for division of short gastric vessels was significantly shorter with a UAS (UltraCision) than with a multiclip applicator.

#### *Limitations of ultrasonic shears*

In clinical practice, some limitations of ultrasonic shears become apparent.

As with bipolar cautery, some experience is needed to master the scissors. Failures are possible, either because power is applied for too short a period or grip strength is

inadequate [25]. When using the scissors for the first time, it is thus advisable to start by coagulating small vessels whose hemostasis could be achieved easily and safely in case of technical error.

Until now, only hooks and balls have been available with 5-mm instruments. Scissors were available only with a 10- or 11-mm shaft. With the current trend for reducing instrument diameter, these sizes may be cumbersome, obstructing the operative field. The new AutoSonix (USSC) scissors have a 5-mm diameter. It is unknown whether reusable systems will, for reliability reasons, accept small-diameter shears.

Another limitation of the currently available shears is the relatively massive design of their tip that makes dissection somewhat rough. The main reason is that mechanical

vibrations can be transmitted only via a straight line. Thus a curved tip is not suitable. However, a better-designed tip may be feasible.

The fourth and final limitation of ultrasonic shears is their cost. The total price of an ultrasonic generator is similar to the price of an HF generator. But disposable items are expensive. The price of ultrasonic shears is higher than that of a clip applicator and close to that of an endoscopic stapler. Richards et al. [21] compared the cost of ultrasonic shears (UltraCision) and an endoscopic stapler (EndoGIA, USSC) for laparoscopic hysterectomy. The cost per procedure was \$315 and \$585, respectively due to the price of additional cartridges for the endostapler. Laycock et al. [15] showed that during a laparoscopic Nissen procedure, the respective costs of the UltraCision and a clip applicator were \$734 and \$922. Thus, despite their high price, ultrasonic shears can compete in cost with other instruments such as clip applicators or vascular endostaplers. Now that reusable scissors are coming onto the market (the SonoSurg scissors can be reused around 20 times), this cost should be noticeably reduced.

#### *Indications for the ultrasonically activated scalpel*

Several applications of the UAS have been reported. Amaral [1] reported a series of 200 consecutive laparoscopic cholecystectomies using an ultrasonic hook (UltraCision). In the last 100 patients of this series, electrocautery was never necessary. A comparative study of 50 laparoscopic cholecystectomies performed with electrocautery and ultrasonic dissection was unable to show any difference in the postoperative course, except that the postoperative white cell count was significantly higher after electrocautery than after ultrasonic dissection [1].

The UAS is mainly helpful when there are numerous vessels to deal with, especially when these vessels are surrounded by fatty tissue. Several publications have reported the use of the UAS for laparoscopic funduplications [15, 28], splenectomies [11, 23], and colectomies [8–10]. For Nissen fundoplication, Laycock et al. [15] demonstrated that the use of ultrasonic shears for short vessel control resulted in a quicker procedure and led to less bleeding. In a similar comparative study it was reported that ultrasonic shears provoked less active bleeding and less hematoma than clips [28]. Many studies have reported the usefulness of ultrasonic shears in laparoscopic gynecology [21, 22, 24, 26]. Richards et al. [21] showed that ultrasonic shears allowed a laparoscopic hysterectomy to be performed with intraoperative bleeding equivalent to that produced by an endostapler.

#### *Features of the currently available ultrasonically activated scalpels*

Currently, three UAS are available: UltraCision (Ethicon-Endosurgery), AutoSonix (USSC) (Fig. 4) and SonoSurg (Olympus) (Fig. 5). Their features are summarized in Table 1. The general design of the three generators is similar. The SonoSurg has the advantage of a reduced size that allows it to be incorporated into a video trolley (Fig. 5).

The UltraCision shears can be used in three different

positions (flat, blunt and sharp edge) that can be selected with a wheel located on the handpiece (Fig. 6). The blade of AutoSonix and SonoSurg have only a standard position with a blunt edge. The cut mode is obtained not by rotating the blade to the sharp edge, but by switching by means of a pedal from coagulation mode (60–70% of maximal power) to cut mode (100%). The AutoSonix shears are 5 mm in diameter. The SonoSurg has an additional HF connection that may be useful in case of unexpected bleeding that requires quick hemostasis. The AutoSonix and UltraCision systems accept a range of additional instruments (hook, ball) that are reusable (Fig. 7).

#### References

1. Amaral (1995) Laparoscopic cholecystectomy in 200 consecutive patients using an ultrasonic activated scalpel. *Surg Lap Endosc* 5: 255–262
2. Amaral JF, Chrostek C (1997) Experimental comparison of the ultrasonically-activated scalpel to electrocautery and laser surgery for laparoscopic use. *Minim Invasive Ther Allied Technol* 6: 324–331
3. Champault G, Taffinder N, Zioli M, Riskalla H, Catheline JMC (1997) Cells are present in the smoke created during laparoscopic surgery. *Br J Surg* 84:993–995
4. Claus GP, Sjoerdsma W, Jansen A, Grimbergen CA (1995) Quantitative standardised analysis of advanced laparoscopic procedures. *Endosc Surg Allied Technol* 3:210–213
5. Cuschieri A, Shimi S, Banting S, VanderHelpen G (1993) Endoscopic ultrasonic dissection for thoracoscopic and laparoscopic surgery. *Surg Endosc* 7: 197–199
6. Fan ST, Lai EC, Lo CM, Chu KM, Liu CL, Wong J (1996) Hepatectomy with an ultrasonic dissector for hepatocellular carcinoma. *Br J Surg* 83: 117–120
7. Farin G (1994) Ultrasonic dissection in combination with high-frequency surgery. *Endosc Surg Allied Technol* 2: 211–213
8. Fowler DL (1996) Laparoscopic right hemicolectomy. In: Toouli J, Gossot D, Hunter JH (eds) *Endosurgery*. Churchill Livingstone, New York, pp 665–673
9. Fowler DL, White S (1994) Laparoscopic sigmoid resection with the harmonic scalpel. *Surg Endosc* 8: 503 [abstract]
10. Geis WP, Kim HC, McAfee PC, Kang JG, Brennan EJ (1996) Synergistic benefits of combined technologies in complex minimally invasive surgical procedures. *Surg Endosc* 10: 1025–1028
11. Gossot D, Fritsch S, Sarfati E, Célérier M (1998) Laparoscopic splenectomy: optimal vascular control using the lateral approach and ultrasonic dissection. *Surg Endosc* (in press)
12. Grosskinsky CM, Hulka JF (1995) Unipolar electrocautery in operative laparoscopy: capacitance as a potential source of injury. *J Reprod Med* 40: 549–552
13. Hambley R, Hebda PA, Abell E, Cohen B, Jegasothy BV (1988) Wound healing of skin incisions produced by ultrasonically vibrating knife, scalpel, electrocautery, and carbon dioxide laser. *J Dermatol Surg Oncol* 14: 11
14. Hodgson WJ, Morgan J, Byrne D, DelGuercio LR (1992) Hepatic resections for primary and metastatic tumors using the ultrasonic surgical dissector. *Am J Surg* 163:246–250
15. Laycock WS, Trus TL, Hunter JG (1996) New technology for the division of short gastric vessels during laparoscopic Nissen fundoplication: a prospective randomized trial. *Surg Endosc* 10: 71–73
16. Meijer DW, Bannenberg JJG (1996) HF Electrocautery for endoscopic surgery. In: Toouli J, Gossot D, Hunter J (eds) *Endosurgery*. Churchill Livingstone, New York, pp 97–102
17. Meltzer RC, Hoenig DM, Chrostek CA, Amaral JF (1994) Porcine seromyotomies using an ultrasonically activated scalpel. *Surg Endosc* 8: 253
18. Mueller W, Frizsch G (1994) Medicotechnical basics of surgery using invasive ultrasonic energy. *Endosc Surg Allied Technol* 2: 205–210
19. Nduka CC, Super PA, Monson JRT, Darzi AW (1994) Cause and prevention of electrocautery injuries in laparoscopy. *J Am Coll Surg* 179: 161–170
20. Payne JH (1994) Ultrasonic dissection. *Surg Endosc* 8: 416–418
21. Richards SR, Simpkins SS (1995) Comparison of the harmonic scissors

- sors and endostapler in laparoscopic supracervical hysterectomy. *J Am Assoc Gynecol Laparosc* 3: 87–90
22. Robbins ML, Ferland RJ (1995) Laparoscopic-assisted vaginal hysterectomy using the laparoscopic coagulating shears. *J Am Assoc Gynecol Laparosc* 2: 339–343
  23. Rothenberg SS (1996) Laparoscopic splenectomy using the harmonic scalpel. *J Laparoendosc Surg* 6: S61–S63
  24. Schwarz RO (1994) Total laparoscopic hysterectomy with the harmonic scalpel. *J Gynecol Surg* 10: 33–34
  25. Spivak H, Richardson WS, Hunter JG (1998) The use of cautery, laparoscopic coagulating shears, and vascular clips for hemostasis of small and medium-sized vessels. *Surg Endosc* 12: 183–185
  26. Stringer NH (1994) Laparoscopic myomectomy with the harmonic scalpel: a review of 25 cases. *J Gynecol Surg* 10: 241–245
  27. Suzuki K, Fujita K, Ushiyama T, Mugiya S, Kageyama S, Ishikawa A (1995) Efficacy of an ultrasonic surgical system for laparoscopic adrenalectomy. *J Urol* 154: 484–486
  28. Swannstrom LL, Pennings JL (1995) Laparoscopic control of short gastric vessels. *J Am Coll Surg* 181: 347–351
  29. Takeda M, Go H, Imai T, Komevama T (1994) Experience with 17 cases of laparoscopic adrenalectomy: use of ultrasonic aspirator and argon beam coagulator. *J Urol* 152: 902–905
  30. Tucker RD (1995) Laparoscopic electro-surgical injuries: survey results and their implications. *Surg Laparosc Endosc* 5: 311–317
  31. Wetter LA, Payne JH, Kirshenbaum G, Podoll EF, Bachinsky T, Way LW (1992) The ultrasonic dissector facilitates laparoscopic cholecystectomy. *Arch Surg* 127:1195–1198