
Ultrasonic Ostectomy for the Surgical Approach of the Maxillary Sinus: A Technical Note

Fernando Torrella, MD, DDS*/Julio Pitarch, MD, DDS*/Guillermo Cabanes, MD, DDS*/Eduardo Anitua, MD, DDS**

Because of its physical and mechanical properties, the odontologic applications of ultrasound are increasing. A new application of odontologic ultrasonic generators involves the lateral approach of the maxillary sinus in sinus augmentation. The procedure may provide important advantages over conventional ostectomy using diamond drills, as it reduces the risk of perforating the Schneiderian membrane, improves vision and hygiene of the operating area, and provides a more conservative and controlled osseous incision.
(INT J ORAL MAXILLOFAC IMPLANTS 1998;13:697-700)

Key words: implant, osseous graft, sinus ostectomy, ultrasound

The surgical lift of the maxillary sinus floor is currently an accepted technique in implant surgery in the rehabilitation of the posterior area of the edentulous maxilla. It is a relatively simple and predictable surgical technique. In 1977, Tatum¹ reported penetration of the maxillary sinus with a modified Caldwell-Luc technique (unfinished fenestration osteotomy in the maxilla's external face) to raise the sinus membrane, creating an empty hole in the floor of the antral cavity. After it was refilled with different grafting materials, the anchorage area for placing implants in areas with poor osseous crest height was increased.²⁻⁵

Those who use this procedure know that one of its most common complications is perforation of the Schneiderian membrane when separating it or when making the osseous window for reaching the sinus with the round diamond drill during the rotating ostectomy stage.^{2,3,5,6} To reduce this complication, the creation of a vestibular ostectomy by using an odontologic ultrasonic generator is proposed.

Ultrasound has been used widely in various fields of medicine, for example, in the treatment of some musculoskeletal disorders, for selective tissue resec-

tion in neurosurgery and hepatic surgery, and in the controlled fragmentation of renal calculus.⁷⁻⁹ In odontology, its applications have increased to include the radicular scrape, instrumentation and filling of the radicular duct, decementation and cementation of prosthodontic restorations, finishing of margins in prosthetic cuttings, and preparation of the retrograde cavity in apicectomies.

Described herein is a new application of ultrasonic generators in odontology and their use in the surgical technique for lateral approach of the maxillary sinus. Based on particular features and clinical experience, it is suggested that the sinus fenestration ostectomy made by ultrasound technique has advantages over the conventional technique using a rotating drill.

Materials and Methods

The fenestration ostectomy for sinus approach is performed using the active tip of a conventional periodontal ultrasonic generator augmented with an independent irrigation system with sterile saline solution. The convenience of an ultrasonic ostectomy can be realized through an analysis of the physical and mechanical phenomenon generated by the ultrasound at the active tip of the device.^{7,8,10-13}

Ultrasonic Vibration at the Active Tip. Micro-movements of 20 to 200 μm and a frequency of more than 20,000 Hz (20,000 micromovements per second) are present at the device tip. In this way, the ostectomy line is made by microfracturing and dispersing the osseous table in a progressive, precise,

*Professor, Department of Oral Surgery, University of Valencia, Valencia, Spain.

**Guest Professor, Department of Oral Surgery, University of Valencia, Valencia, Spain.

Reprint requests: Dr Eduardo Anitua, San Antonio, 15-5°, 01005 Vitoria, Spain. E-mail: eduardoanitua@jet.es

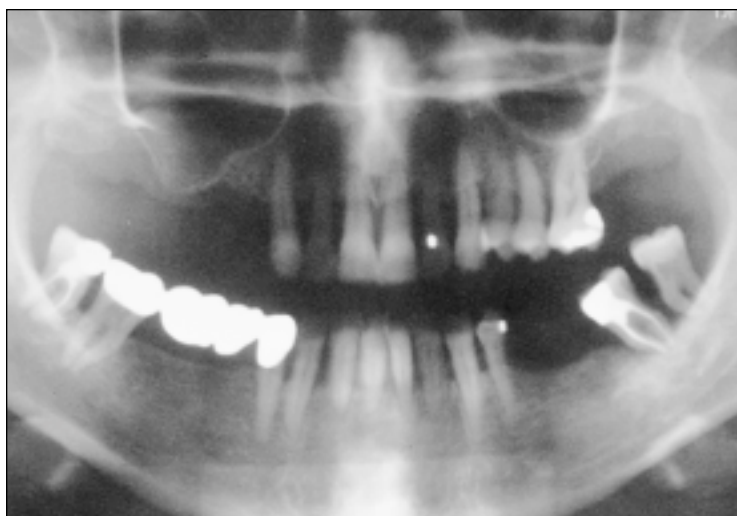


Fig 1 Preoperative orthopantomograph. Note the great pneumatization of the right maxillary sinus and the minimal subsinusual osseous thickness of 2 mm.

and controlled way. Greater tactile control and minimal risk of perforating the Schneiderian membrane, even if touched with the ultrasonic tip, may be realized. Although microfracture of the bone can occur, soft tissue damage is circumvented, in the same way as with the oscillating saws when used by traumatologists to cut plaster dressings without damaging the patient's skin. The number of oscillations at the active end, and thus its cutting capacity, can be controlled by selecting the "power" setting on the device.

Effects of the Irrigation Liquid. Mechanical vibration of the water transforms the liquid into an aerosol with a greater capacity for cleaning blood and detritus in the operating area. Cavitation, the creation of depressions in the liquid, produces bubbles of saturated steam, which turn into microscopic bubbles and thereby increase the mechanical effect of the device.

The tips of the ultrasonic devices are made of high-quality surgical steel. The thinnest active tip of the device's handpiece is used, so as to concentrate the ultrasonic effects on the most definitive area possible, thus increasing its efficacy and precision. The ultrasonic tip is positioned perpendicular to the osseous surface (contrary to what is done during a tartrectomy) to take advantage of the instrument's maximum power and the "hammer effect" achieved in this direction. A high irrigation flow is maintained to obtain the greatest cavitation effect and to cool the tip.

Operative Technique

After the operative area is reached by means of a full-thickness flap, access to the cavity is provided by ultrasonic osteotomy with the active tip of the gener-

ator placed perpendicular to the osseous level and with abundant sterile irrigation (Figs 1 and 2). A complete osteotomy along the perimeter of the osseous window (including the upper site) is initiated and deepened until tactile sensation of the Schneiderian membrane, which will be respected by the ultrasonic tip, is obtained.

Once the fenestration is completed, the osseous window is dislocated with an instrument (Fig 3), the Schneiderian membrane in the sinus floor is separated until the membrane together with the osseous window are raised, and in this way another empty site is obtained to place the new implant (Fig 4). With a direct view into the sinus cavity, a bed is made for placement of an implant at that level, and manual drilling, which offers more tactile control, is used to finish. This reduces the vibrations over the bone, which has poor crestal thickness and should be maintained. Before the implant is placed, the most internal areas of the antral opening are filled, since doing so once the implant is placed would be difficult. Demineralized cortical bone and bovine hydroxyapatite in equal parts, combined with autologous bone obtained using an osseous trap during the drilling, are used as grafting materials.

Bone obtained from the tuberosity of the same side is used (Fig 5) to assure primary stability of the implant, essential for its osseointegration. A central perforation of the graft is made in the same diameter as that of the implant to be used. This piece of perforated bone is placed inside the sinus cavity so that the self-tapping implant, after passing through the perforation of the subsinus osseous crest, also pierces the hole of the osseous piece (Fig 6), thus obtaining primary anchorage, which in this case would not be possible using only a compacted powder graft.

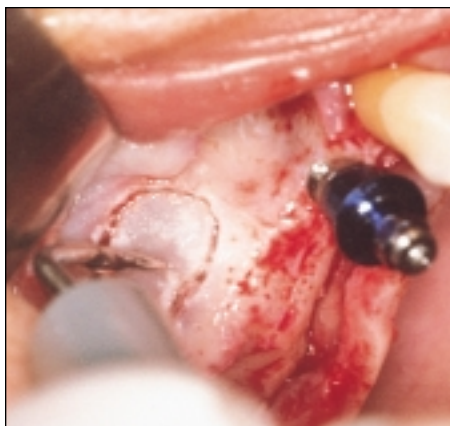

Fig 2 Osteotomy line for sinus access achieved with the active tip of an ultrasonic generator.

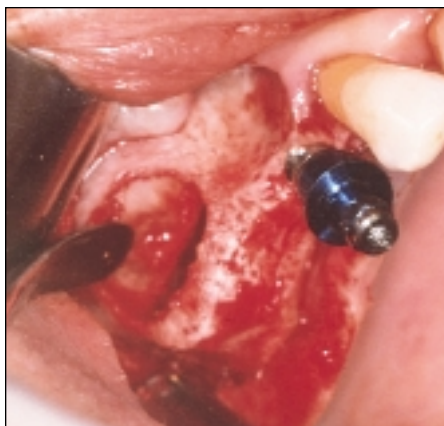

Fig 3 Dislocation of the osseous window.

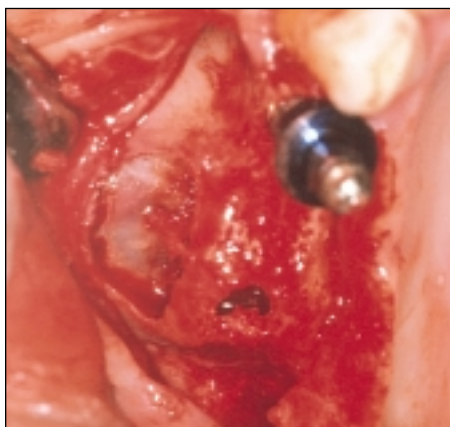


Fig 4 Implant site preparation completed with manual drilling.

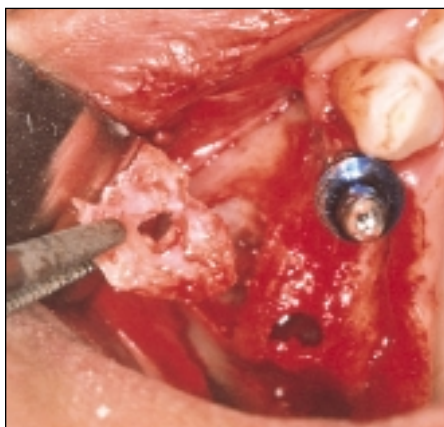


Fig 5 A piece of bone from the tuberosity obtained with a chisel. Sinusal placement of the piece of bone with central perforation for implant stabilization.

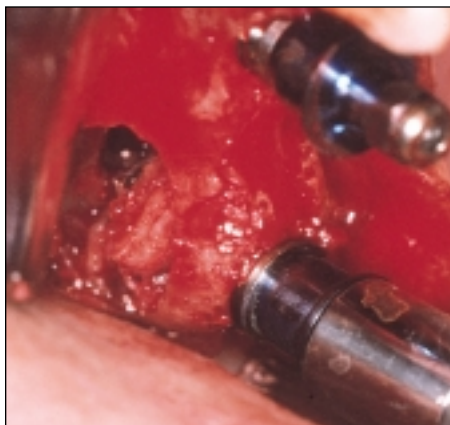

Fig 6 A self-tapping implant (5 × 13 mm) passes through subsinus bone and bone placed inside the sinus.

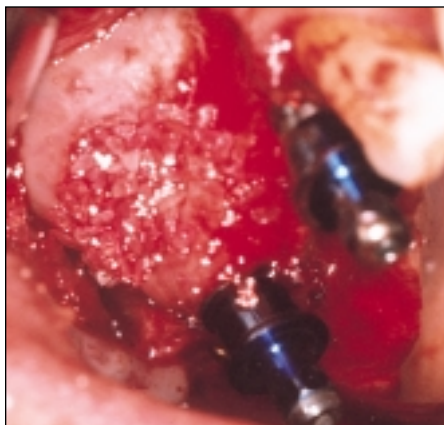

Fig 7 Stabilized implant and sinus refilling with compacted grafting material to the vestibular osseous wall level.

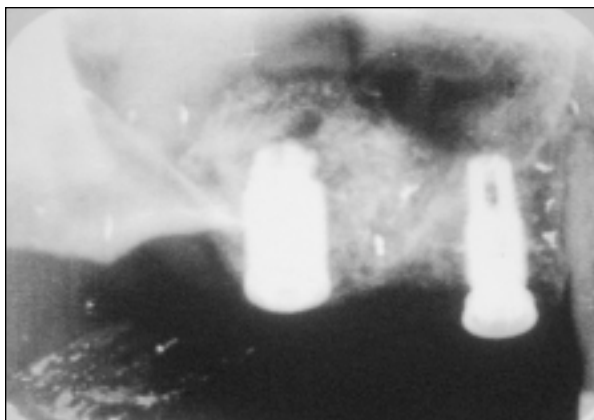


Fig 8 Immediate postsurgical intraoral radiograph demonstrating the obtained sinus lift.

Once the implant has been placed in the correct position and its anchorage and stability verified, the sinus refill with the grafting material mentioned above is continued until the same level of the vestibular osseous wall is reached, covering the entire defect with a resorbable collagen bilaminar membrane and repositioning the soft tissues with sutures (Fig 7). The degree of sinus augmentation is shown in Fig 8.

Discussion

The application of odontologic ultrasonic generators in the fenestration osteotomy for the maxillary sinus is an interesting application of ultrasound in odontology that may offer the following advantages over conventional sinus augmentation surgery:

Reduces the risk of perforating the Schneiderian membrane. This is the primary advantage this technique offers, and it is possible because of a higher tactile sensibility and control during the ultrasonic osteotomy and the relative capacity of the ultrasonic tips to avoid damaging the soft tissues even though they can perforate bone. Also advantageous is the possibility of completing the osteotomy for the entire perimeter of fenestration, eliminating the necessity of performing a greenstick fracture of the upper portion of the osseous window, as in the rotating osteotomy that increases the risk of membrane perforation.¹⁴

Better view and hygiene of the operative area during osteotomy. Visualization is enhanced because of the "cleaning" mechanical effect of the irrigation liquid under the action of the ultrasounds. Furthermore, since it creates an aerosol and not an air-water pressure spray, as occurs in the rotating osteotomy, the risk of subcutaneous emphysema resulting from irrigation is reduced.

A thinner and more conservative osseous incision is created than with the round drill used for the rotation osteotomy.

The possible disadvantages of the ultrasonic osteotomy compared with the rotating procedure are relatively unimportant and widely outweighed by the advantages. The ultrasonic osteotomy does require more time and special care when applying it to patients with pacemakers, although actually almost all of these devices are provided with anti-interference-protection filters. (A device provided with an independent sterile saline solution irrigation system is needed to maintain asepsis during the surgery.)

It is better to use an ultrasonic generator of the latest generation type electric piece (quartz glasses generator) rather than the magnetostrictive type (ferro-nickel thin sheets), since the former has more power, produces less heat on the tip, and sends out vibrations from the active tip that are easier to direct to only one plane in space. This means more cutting capacity with less bone destruction.^{10,11}

Although this technique seems easy with a smaller risk of complications, it is a recent technique and a long-term study of patients treated is needed to determine its safety and advantages over other techniques.

References

1. Tatum H. Maxillary and sinus implant reconstructions. *Dent Clin North Am* 1986;30:207-229.
2. Smiler DG, Johnson PW, Lozada JL, Misch C, Rosenlicht JL, Tatum OH Jr, et al. Sinus lift grafts and endosseous implants. Treatment of the atrophic posterior maxilla. *Dent Clin North Am* 1992;36:151:208-188.
3. Salazaray LV, Lozada LJ. Sinus Lifting Technique. Madrid: Unidad de Implantología Oral y Prótesis Biointegrada, 1993.
4. Gay EC. Subjects of Oral Surgery, vol 2. Barcelona: Signo, 1993:1151-1160.
5. Abensur D, Valentin P. Les élévations de plancher sinusal en implantologie: Protocole chirurgical et résultats histologiques. *Acta Odontol-Stomatol* 1993;184:532-543.
6. Mische CE. Contemporary Implantology. Madrid: Mosby/Doyma, 1995:541-567.
7. Díez de los Ríos A. Introduction to the Biophysics and to the Medical Physics. Málaga: University of Málaga, 1983:149-159.
8. Macdonald SGG, Burns DM. Physics for the Sciences of Life and Health. Mexico: Fondo Educativo Interamericano SA, 1978:413-422.
9. Sabiston DC. Treatise of Surgical Pathology, 13th ed. Mexico: Interamericana, 1988:269.
10. Mallo L, Chicon JA. Technology in the periodontal office: All you need to know about de sonic and ultrasonic units. *Periodontia* 1996;6:87-94.
11. Gay EC. Application of ultrasonic in periapical surgery. *Eur J Odontol* 1996;8:207-214.
12. Kane JW, Sternbein MM. Physics, ed 2. Barcelona: Reverte SA, 1992:507-523.
13. Catala de Alemany J. Physics. Madrid: Foundation García Muñoz, 1988:385-386.
14. Anitua E. Implant Surgery and Prosthesis: A New Perspective. Vitoria: Puesta al Día Publications SL, 1988:77-99.