



## Ultrasonographic Differential Diagnosis of Superficial Swellings in Farm Animals

Magda M. Ali, Abd El-Hakiem, M.A.H.

Department of Animal Surgery, Faculty of Veterinary Medicine, Assiut University, 71526 Assiut, Egypt.

### Abstract

This report describes the ultrasonographic differential diagnosis of different types of swellings affecting (28) farm animals. The swellings were, abscess (11), cyst (2), hematoma (2), hernia (9) and urethral diverticulum (4). The swellings varied sonographically according to the type, duration, content and location. Cases suffering the same type of swellings may have some degree of difference in echogenicity according to the period of the swelling. Abscesses appeared as hypo/hyperechoic structures with distinct hyperechoic well-developed capsule. Recent hematomas were anechoic with a well demarcated wall, with increased duration, the hematoma gradually became more echoic and textured. The hernial ring was determined as a discontinuation of the abdominal wall echogenicity and the hernial contents were clearly evaluated via ultrasonography. Recent cysts resembled hematoma in compartmentalization but the location and case history helped the differential diagnosis. Urethral dilatation appeared sonographically as an anechoic to hypoechoic homogenous structure with well demarcated wall and acoustic enhancement. Ultrasonography could be considered a successful, noninvasive, rapid technique for differential diagnosis of different types of swellings in farm animals. It could be easily used under field conditions to screen the lesions before the surgical operations and to follow up the cases after surgery.

**Keywords:** Ultrasound; hematoma; hernia; abscess; farm animals

### Introduction

Ultrasound is a noninvasive diagnostic technique which has been widely used for diagnosis of many lesions in the veterinary field. It is well tolerated by the animal and could be easily performed in the field (Streeter and Step, 2007). Ultrasound is frequently performed in combination with radiography for evaluation of internal structures of abdominal masses as well as for confirmation of pregnancy diagnosis in different animal species (Scott, 2012).

Ultrasound could provide information about the size, shape, location and architecture of the structures being examined. It is best at distinguishing solid form cystic structures and provides internal details not demonstrated radiographically (McAuliff, 2004). Ultrasound is also extremely valuable for guiding fine needle aspiration or biopsies. The

aspiration needle can be observed as it passes through or into the lesion and samples can be obtained from specific sites within an organ or mass (Hager *et al.*, 1985). One of great advantages of ultrasound is its ability to distinguish fluids from soft tissues when physical examinations are inconclusive.

Most space occupying soft tissue masses are easily distinguished from the surrounding organs because of demonstrable interfaces and an altered echogenicity (Scott, 2012). A variety of swellings (abscesses, hematomas, hernias and cysts) have been diagnosed in different species of farm animals, these swellings varied in echogenicity in ultrasonographic diagnosis (McAuliff, 2004). Hematomas and abscess are the most common disorders seen after muscular trauma in large animals. Clinically the presentation of hematoma and abscess can be similar. Alternatively, the pain and soft tissue swelling of a deep muscle abscess can mimic fracture clinically. In such instance ultrasound has proven to be useful in the diagnosis of abscesses,

\*Corresponding author: Magda M. Ali

E-mail address: magdaali70@yahoo.com

hematomas and soft tissue neoplasia (Kofler, 2009). In this study, our primary objective was intended to study the ultrasonographic differential diagnosis of different swellings affecting some farm animals.

## Materials and methods

In the present study, 28 farm animals of different species admitted to the teaching veterinary hospital, within the period from April 2007 to March 2012 were included in the study. All animals had case history of presence of one or multiple swellings on different parts of the body.

An ultrasonographic examination was performed on non-sedated, standing animal using a 3.5- 5 MHz sector transducer or a 8- 10 MHz linear transducers after the application of transmission gel. The hair was clipped from the area where the transducer was to be applied; for optimal transmission of ultrasound waves, remaining hair may be removed using a razor or depilatory cream. Diagnosis was confirmed during surgery and by aspiration of the contents under the visual control of ultrasound. Examination of animals was done in standing position.

## Results

Swellings recorded in this study were: abscess (11), cyst (2), hematoma (2), hernia (9) and urethral diverticulum (4). The swellings varied in shape and size according to the period of the swellings and the seat of them.

The animals were classified according to the types of swelling as shown in table Table 1.

Table 1. Summaries the types of affections affecting different animals

Type of Swelling	Animals				No of animals
	Cattle and buffaloes	sheep	Goat	Horse	
Abscess	3	4	3	1	11
Hernia	2	2	2	3	9
Hematoma	2	0	0	0	2
Cyst	1	0	1	0	2
Urethral diverticulum	2	1	1	0	4
Total	10	7	7	4	28

The swellings varied sonographically according to the type, duration, content and location, cases suffering the same type of swelling may has some degree of difference in echogenicity according to the period of the swelling.

Abscesses appeared sonographically as hypo/hyperechoic structures with distinct hyperechoic distinct and well-developed capsule, which appeared as an echogenic line that demarcated the contents of the abscess from the neighboring tissues (Figs. 1A, B). The echogenic character of the contents of the abscesses varied in echogenicity according to the duration of the abscess. Recent (acute) abscesses were hypoechoic and homogeneous creating a moderate degree of acoustic enhancement below the swelling (Fig. 1. C, D). Old (chronic) abscesses appeared hyperechoic with a well demarcated echogenic wall (figs. 1E, F). Internal septae were seen in cases of chronic abscesses. The absorption of fluid content in abscesses with deposition of minerals increased the echogenicity. This view was also observed in recent abscesses affecting sheep and goat due to *Corynebacterium ovis*.

In cases suffering hernias, the hernial ring was determined as a discontinuation of the abdominal wall echogenicity. The hernial contents as intestinal loops were clearly visualized via ultrasonography. These loops appeared in longitudinal echogenic lines or circles according to the orientation of the transducer either in the sagittal or transverse plane (Fig. 2. A, B, C, D). In addition, the variation in the appearance of the intestinal contents was visible via ultrasonography; e.g. gas, fluid and ingesta appeared hyperechoic, anechoic and heteroechoic respectively. In four cases where the cause of the hernia was trauma, the hernial contents were irreducible. In these cases the hernia ring was thick and more hyperechoic in comparison to the surrounding tissues; the presence of more or less hypoechoic inflammatory exudates in these forms of hernias resembled the abscess in the ultrasonographic examination.

Hematomas differed sonographically according to the location, case history and duration. Recent hematomas appeared anechoic with a well demarcated wall, with increased duration, the hematoma gradually became more echoic and textured. Later on, most hematomas shrank and became hyperechoic. The large round to ovoid sac is divided by septa into small compartments so the term compartmentalization of the hematoma was derived from this process. Hematoma developed in the heavy musculature areas as the gluteal, thigh and shoulder region often appeared as hypoechoic diffuse non demarcated structure due to infiltration of

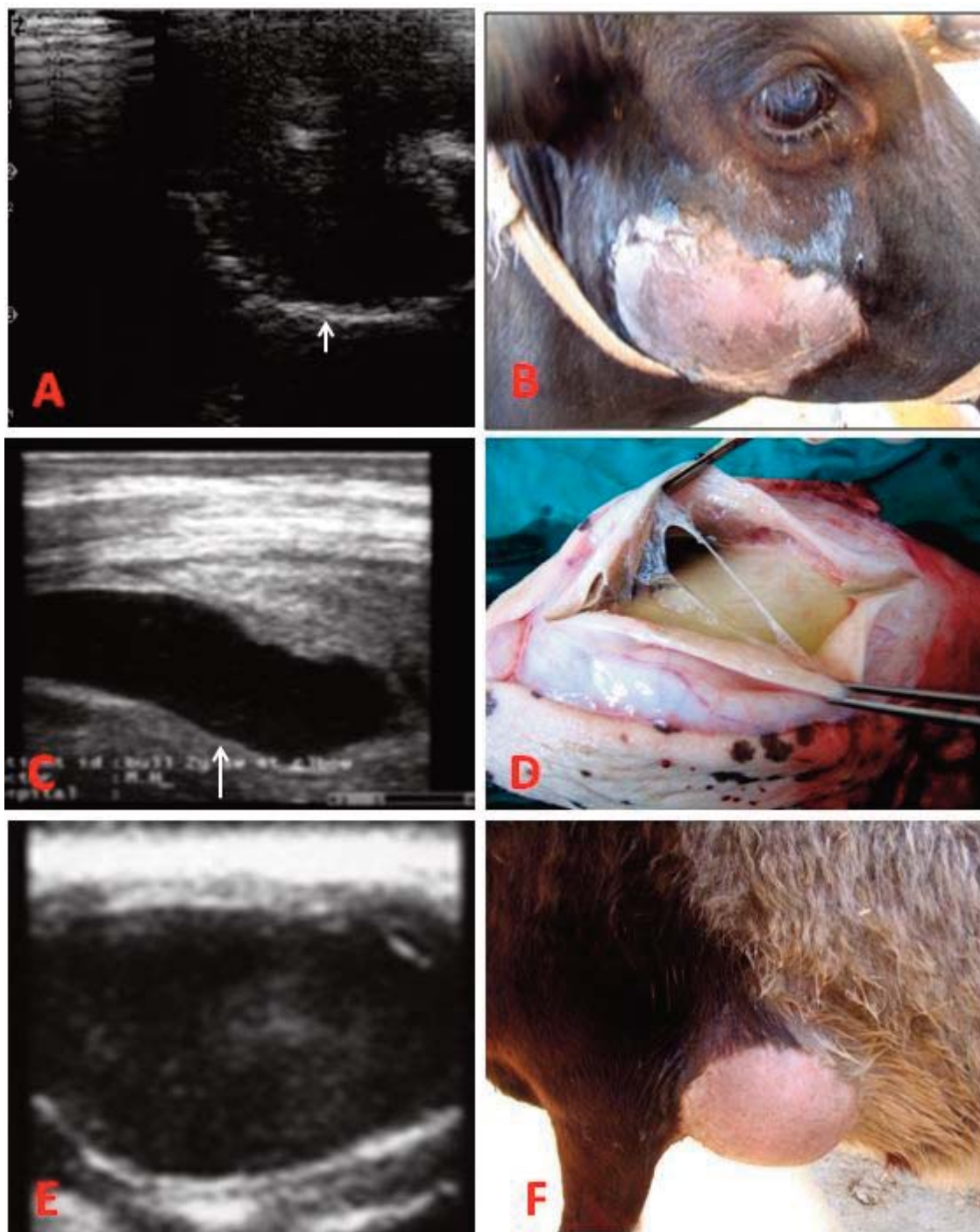


Fig. 1. A, C, F): Ultrasonographic view of abscesses appeared as hypo/hyperechoic structures (white arrow, C), with distinct hyperechoic and well-developed capsule (white arrow 1a), which appeared as an echogenic line that demarcated the contents of the abscess from the neighboring tissues (E). B, D, E): Abscess in different animals.

the escaped blood between the muscle fibers (Figs. 2. E, F and Fig. 3. A, B).

Cysts appeared as recent hematoma in compartmentalization. The difference between the hematoma and cyst is in the predilection seat, duration and case history of previous trauma. Moreover, there was some difference on the ultrasound such as the septa in the cyst were thick and hyperechoic than in the hematoma and there was a marked acoustic enhancement in case of the cyst.

In the chronic form of cyst, the fluid contents decreased while the internal fibrosis increased this increased the echogenicity in ultrasound examination (Fig. 3. C, D).

Urethral diverticulum appeared as an oval or circumscribed swelling on the perineal region which extends from just below the anus downward. The size of the swelling varied according to the filling or the emptying of the diverticulum. Urethral dilatation appeared sonographically as an anechoic



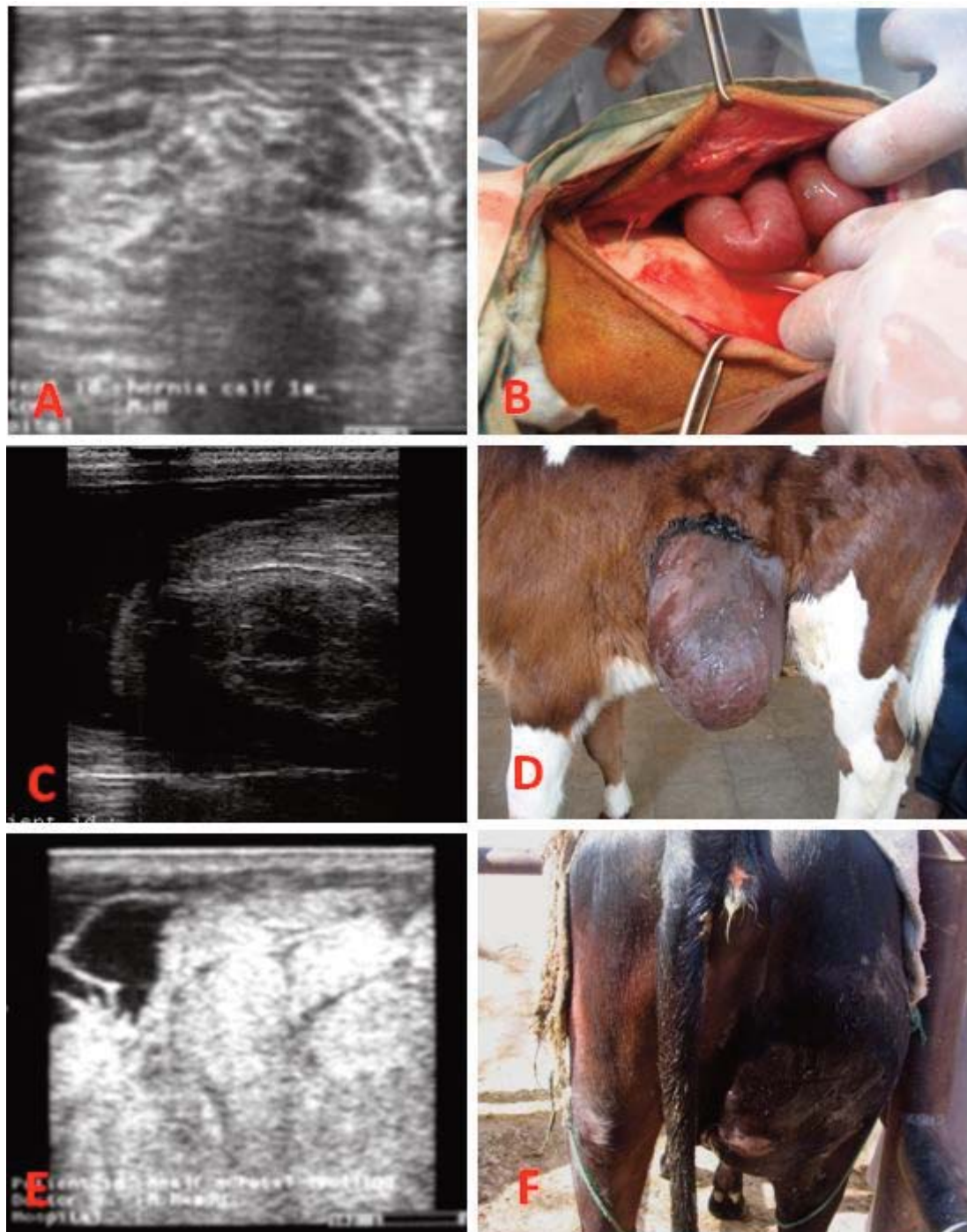


Fig. 2. A, C): Ultrasonographic view showing the intestinal loops appeared in longitudinal echogenic lines or circles according to the orientation of the transducer either in the sagittal or transverse plane. B, D): Hernia in sheep. E): Ultrasonographic view of hematoma (F) appeared as hypoechoic diffuse non demarcated structure due to infiltration of the escaped blood between the muscle fibers.

to hypoechoic homogenous structure with well demarcated wall and acoustic enhancement especially in the transverse plane. The connection between the diverticulum and the urinary bladder appeared as a narrow anechoic area with a demarcated wall (Fig. 3. E, F). Variation in the echogenicity with appearance of hyperechoic crystals was usually attributed to the variation in the concentration of the urine and concurrent diseases of the urinary tract as in cases of cystitis. In all cases needle aspiration under

sonographic vision control ensured the diagnosis and was followed by surgical intervention.

## Discussion

The ultrasonographic appearance of swellings in this study, varied according to the type, duration, contents and location. Even in case of same types of swelling, the ultrasonographic features could have some degree of difference (Burk and Ackre-

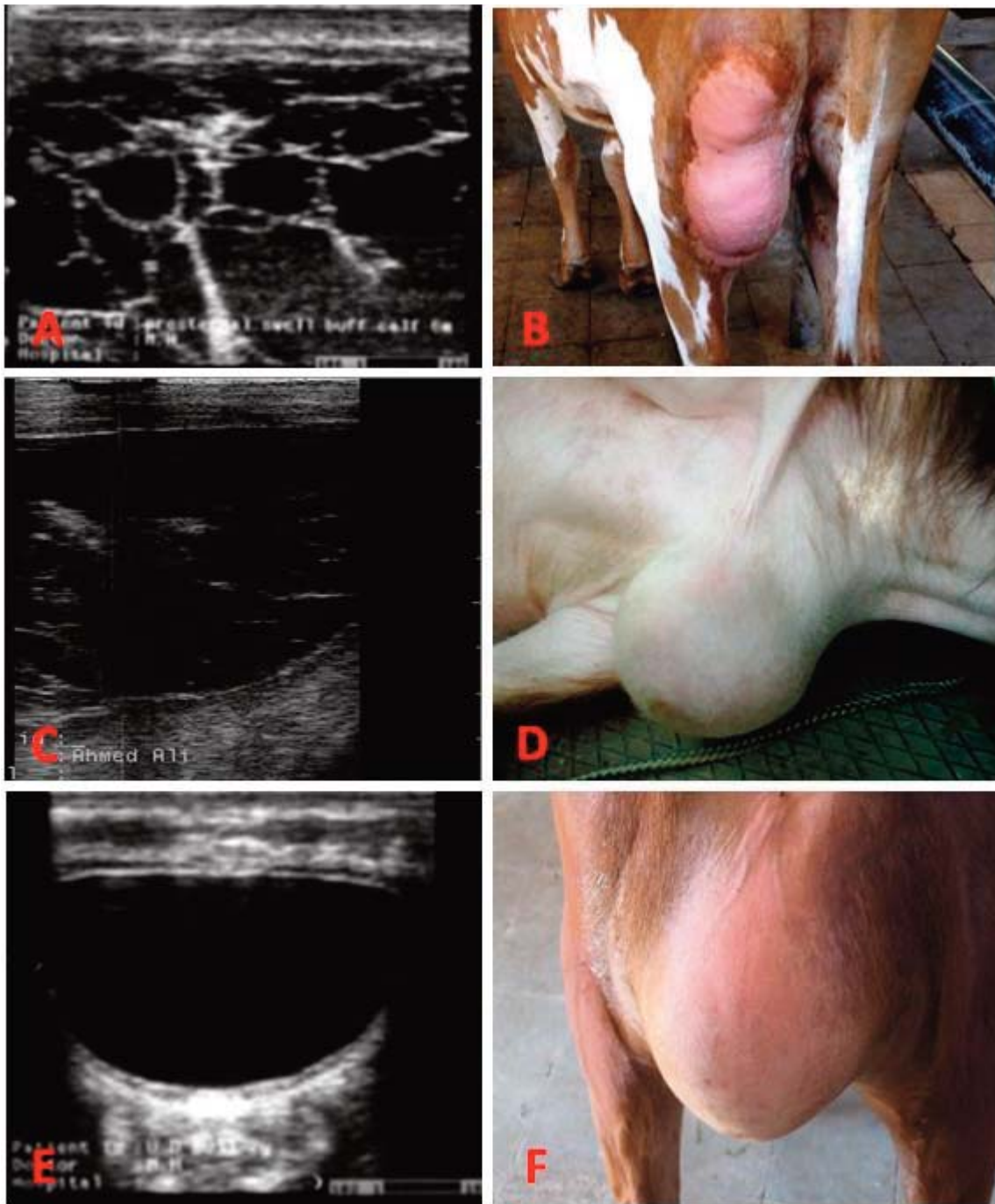


Fig. 3. A): Ultrasonographic view of hematoma (B) appeared as hypoechoic diffuse non demarcated structure due to infiltration of the escaped blood between the muscle fibers. C, D): Cysts appeared as recent hematoma in compartmentalization, note the presence of septa in the cyst were thick and hyperechoic than in the hematoma. E): Ultrasonographic view of the urethral diverticulum showing the variation in the echogenicity with appearance of hyperechoic crystals. F): Urethral diverticulum in a cattle calf.

man, 1996). Needle aspiration or catheter drainage under ultrasonographic guidance allowed safe obtaining of samples from the contents of different forms of swellings and was of value for differential diagnosis (Braun, 1993; Hashefi, 2009).

In our study, variation in echogenicity of abscess varied according to the duration of the abscess and the character of the contents. Recent abscesses diagnosed in sheep and goat were mostly characterized by presence of hyperechoic shadow

and presence of more or less hyperechoic spots. This was specially observed in cases of lymph node abscess. These results were in contrary to Hager *et al.* (1985) who reported that, the contents of recent (acute) abscess are hypoechoic and homogenous creating a moderate degree of acoustic enhancement below the swelling. Old (chronic) abscess diagnosed in this study were hyperechoic with a distinct hyperechoic capsule. Posterior acoustic enhancement (hyperechoic shadow) in addition to



formation of internal septae were usually seen in more chronic cases (Hager *et al.*, 1985; Mohamed and Oikawa, 2007).

In our study, demarcation of the hernial ring and contents were easily performed via ultrasonography. The hernial ring was determined as a discontinuation of the abdominal wall echogenicity which isolated the hernia contents from the surrounding tissues. In cases of traumatic irreducible hernias, the hernia ring appeared thick and extremely hyperechoic in comparison to the surrounding tissues; the presence of more or less hypoechoic inflammatory exudates in these forms of hernias resembled the abscess in the ultrasonographic examination (Corn, 1998; Hashefi, 2009). However the clear appearance of the peristaltic movement of the intestine inside the hernia was diagnosis of value for differential diagnosis; this was in agreement with (Mohamed and Oikawa, 2007).

Ultrasonographic differential diagnosis between recent hematoma and cyst/bursitis was mostly difficult in our study as they appeared mostly the same. This was in agreement with Farrow (1996) and Hashefi (2009). However, the predilection seat for hematoma in the heavy musculature areas as the gluteal, thigh and shoulder region, duration and case history of previous blunt trauma was helpful in dedifferentiation between both lesions. Moreover, the internal septae seen in the cyst/bursitis were thick and hyperechoic than those seen in hematoma with a marked acoustic enhancement in case of the cyst/ bursitis. In the chronic form of bursitis/cyst, the fluid contents decreased while the internal fibrosis increased.

In agreement with Magda (2006), urethral dilatation appeared sonographically in our study as an anechoic to hypoechoic homogenous structure with well demarcated wall and acoustic enhancement. However the variation in the concentration of urine and concurrent diseases of the urinary tract as pyelonephritis or cystitis could result in difference in echogenicity. Obtaining of a sample from the swelling contents under ultrasound visual control is of value for laboratory diagnosis (Braun, 1993).

## Conclusion

Ultrasonography is considered a noninvasive successful technique for differential diagnosis of different types of swellings in farm animals. It is used

as a screening method before the surgical operations and could be successfully follow the progression of different affections in farm animals and expect the prognosis after treatment. The technique does not need any special preparations for the animals as fasting or anesthesia, therefore field application of ultrasonography in differential diagnosis of swellings could allow successful help for field veterinarians.

## Acknowledgement

The author would like to thank the members of Department of Animal Surgery, Faculty of Veterinary Medicine, Assiut University, Assiut, Egypt for their help and support

## References

- Braun, U., 1993. Ultrasonographic examination of the left kidney, the urinary bladder, and the urethra in cows. *Zentralblatt Veterinary Medicine* 40, 1-9.
- Burk, R.L., Ackreman, N., 1996. *Small Animal Radiology and Ultrasonography. A diagnostic Atlas and Text*. Ch. 1, W.B. Saunders Company, Tokyo. pp. 1-22.
- Corn, L. 1998. What is your diagnosis?. *Journal of the American Veterinary Medical Association* 212, 957.
- Farrow, C.S., 1996. Musculoskeletal system. In: *Small Animal Ultrasound*. (Green R.W. Ed). Philadelphia, Lippincott- Raven. pp. 2310-2314.
- Farrow, C.S., 2003. Extremity Injury. In: Charles S. Farrow, C.S., Ed. *Veterinary Diagnostic Imaging: The Dog and Cat*, 1st Edition. Vol. 1, W.B. Saunders Co., Philadelphia. pp. 21-92.
- Hager, D.A., Nyland T.G., Fisher P., 1985. Ultrasound-guided biopsy for the canine liver, kidney and prostate. *Veterinary Radiology* 26, 82.
- Hashefi, M., 2009. Ultrasound in the Diagnosis of Non inflammatory Musculoskeletal Conditions. *Annals of the New York Academy of Sciences* 1154, 171-203.
- Henry, C.J., 1992. What is your diagnosis?. *Journal of the American Veterinary Medical Association* 201, 1773.
- Kofler, J., 2009. Ultrasonography as a Diagnostic Aid in Bovine Musculoskeletal Disorders. *Veterinary Clinics of North America: Food Animal Practice* 25, 687-731.
- Magda, M.A., 2006. Diagnosis of obstructive urolithiasis in cattle and Buffalo by ultrasonography. *Online Journal of Veterinary Research* 10, 26 – 30.
- McAuliff, S.B., 2004. Abdominal Ultrasonography of the Foal. *Clinical Techniques in Equine Practice* 3, 308-316.
- Mohamed, T., Oikawa, S., 2007. Ultrasonographic Characteristics of Abdominal and Thoracic Abscesses in Cattle and Buffaloes. *Journal of the American Veterinary Medical Association* 54, 512-517.
- Reef, V.B., 1998. *Equine Diagnostic Ultrasound* Ch. 11. Ultrasonographic evaluation of small parts, W.B., Saun-

ders Company Tokyo. pp. 480-547.

Scott, P.R., 2012. Applications of diagnostic ultrasonography in small ruminant reproductive management. *Animal Reproduction Science* 130, 184–186.

Streeter, R.N., Step D.L., 2007. Diagnostic Ultrasonography in Ruminants. *Veterinary Clinics of North America: Food Animal Practice* 23, 541–574.