

## Ultrasonographic evaluation of carotid intima-media thickness in hypertensive and normotensive individuals

P Sharma,<sup>1</sup>B Lohani<sup>2</sup> and SP Chataut<sup>3</sup>

Department of Radiology and Imaging, <sup>1</sup>Nepalgunj Medical College Teaching Hospital Kohalpur, Banke, Nepal, <sup>2</sup>TU Teaching Hospital, Kathmandu, Nepal, <sup>3</sup>Norvic-Escorts International Hospital, Kathmandu, Nepal

**Corresponding author:** Dr. Prakash Sharma, Lecturer, Department of Radiology and Imaging, Nepalgunj Medical College Teaching Hospital, Kohalpur, Banke, e-mail: prakashshrm@hotmail.com

### ABSTRACT

This was a case control study designed to evaluate carotid intima-medial thickness (IMT) by high-resolution ultrasound in hypertensive and normotensive individuals. High-resolution carotid ultrasound was done in 203 hypertensive patients (cases) and 101 normotensive individuals (control). Scanning of bilateral common carotid artery (CCA) was performed in anteroposterior projections. To obtain a better image sound wave was adjusted perpendicularly to the arterial surface of the posterior wall of the vessel, yielding two parallel echogenic lines which correspond to lumen-intima and media -adventitia interfaces. Intima-medial thickness was measured in the far wall 1-1.5 cm proximal to the bulb bilaterally. The age of the study population ranged from 35 to 65 years. Mean IMT was significantly high in hypertensive patients compared to the control group,  $p < 0.001$  (in cases, IMT in right side was 0.968 mm and that of left side was 0.969 mm and in control group IMT of right side was 0.551 mm and that of left side was 0.555 mm). A significant difference in IMT of bilateral common carotid arteries was found between the smoker and non-smoker hypertensive patients ( $p < 0.02$ ). IMT was found to increase progressively with age. In conclusion, the study revealed a strong correlation between IMT of common carotid artery and hypertension. Hence, IMT measurement of CCA by high-resolution ultrasound in hypertensive patients is a helpful tool to assess the atherosclerosis and to identify individual at risk of cardiovascular and cerebrovascular complications.

**Keywords:** Hypertension, intima media thickness, smoking.

### INTRODUCTION

Hypertension is a common cardiovascular problem and is a major public health problem in both developed and developing countries. In Nepal the incidence is 6.0<sup>1</sup>-19.7%.<sup>2</sup> More than 95.0% of hypertensive patients in the community are of essential or idiopathic/unknown aetiology<sup>3</sup> whereas only a small percentage has an identifiable cause (secondary hypertension).

Hypertension is a risk factor for the development of atherosclerosis by various mechanisms. Atherosclerosis is a systemic condition primarily affecting elastic arteries (aorta, carotid and iliac arteries) as well as large and medium sized muscular arteries. An atherosclerotic change in the carotid artery is thus a window to the systemic changes that are taking place in the body. Atherosclerotic plaques start developing in the carotids and aorta simultaneously, actually preceding plaque occurrence in the coronary arteries.<sup>4</sup> High-resolution B mode ultrasonography is a non-invasive simple, safe, inexpensive, precise and reproducible method to evaluate and characterize arterial wall thickening and atherosclerotic progression. This technique permits us to accurately quantify the intima media thickness (IMT), which is generally considered as an early marker of

atherosclerosis. In this study B mode ultrasound was used to compare the intima media thickness of hypertensive patients with normotensive healthy volunteers.

### MATERIALS AND METHODS

This case control study was conducted in the Department of radiology and imaging TUTH, Kathmandu Nepal from August 2005 to July 2006. Two hundred and three hypertensive patients between 35 to 65 years who were diagnosed on the basis of WHO /JNC VII report criteria, irrespective of the duration of hypertension and medication were included in the study. Similarly, 101 non smoker healthy volunteers were taken as control.

After taking informed consent and relevant history, high resolution carotid ultrasonographic examination with 7.5 MHz linear probes in SONOACE 8000 live machine was done. Patient was placed in supine position with neck slightly extended; head was placed away from the examination site. IMT was measured at 1- 1.5 cm proximal to the carotid bulb in longitudinal plane. The area had to be free of plaque. Scanning of both side arteries was performed in anteroposterior projections and to obtain a better image sound wave was adjusted

**Table-1:** Mean IMT between case and control groups

		Mean(mm)	P Value
Rt. IMT(mm)	Case	0.96	<0.01
	Control	0.55	
Lt. IMT(mm)	Case	0.96	<0.01
	Control	0.55	

perpendicularly to the arterial surface of the posterior wall of the vessel, yielding two parallel echogenic lines which corresponds to lumen-intima and media-adventitia interfaces. The distance between the lines was taken as the combined thickness of the intima and media (IM complex).

Statistical analysis of the data was done using SPSS software version 10.0 for windows. Chi-square test was used to calculate the p value and p value of < 0.05 was taken as statistically significant.

**RESULTS**

A total of 203 hypertensive patients and 101 healthy volunteers were included in our study. Both the hypertensive patients and control volunteers were in the age group between 35 and 65 years. Most of the hypertensive patients were in the age group of 60-65 years (31.5%). The mean age of the hypertensive patients was 55.30 years and that of the control was 49.12 years. Among hypertensive patients 67.5% were male and 32.5% were female. Among the healthy volunteers 42.6% were male and 57.4% were female. Regarding smoking, 52.20% of hypertensive patients were smokers however none of the control group gave history of smoking. Hypertensive patients irrespective of their

treatment had more systemic blood pressure than healthy volunteers. Mean arterial blood pressure in case and control group was 153.46/89.90 mm of Hg and 118.18/76.16 mm of Hg, respectively.

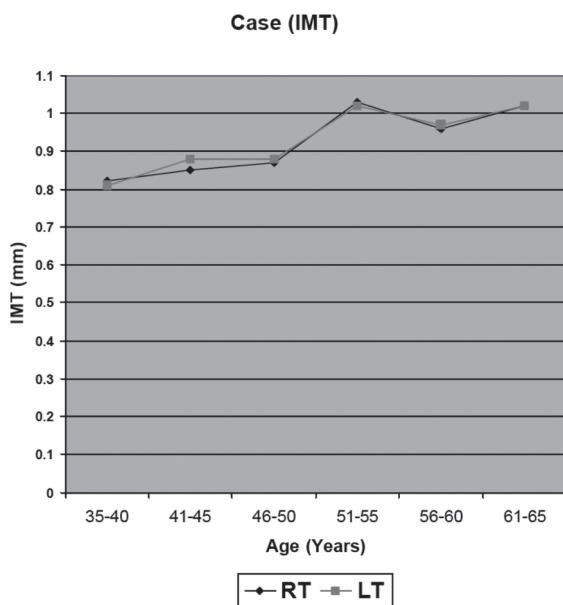
Mean IMT in hypertensive patients was more bilaterally than in normotensive control group, p value <0.001 (Table-1).

IMT was found to be increasing with age both in hypertensive and normotensive patients (Fig. 1 and 2). Hypertensive patients with smoking habit had a significantly higher IMT bilaterally than non smoker hypertensives (Table-2).

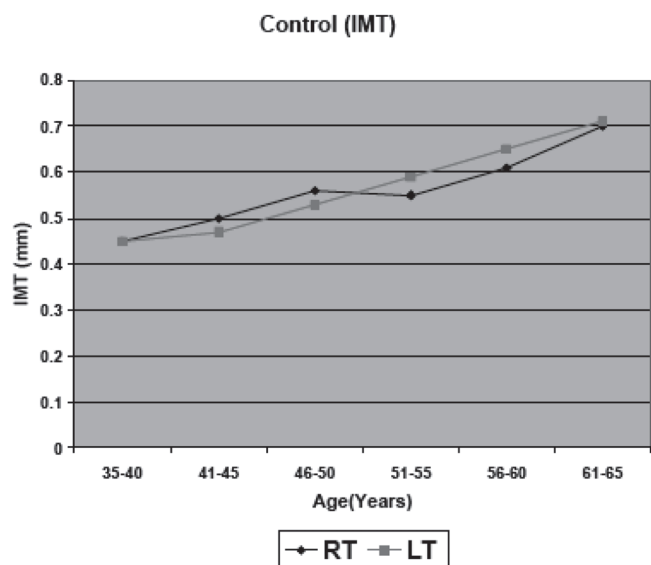
**DISCUSSION**

A total of 203 hypertensive patients and 101 healthy volunteers comprised the study group. The present study showed a positive correlation between the age and the carotid intima media thickness and could reflect the normal aging process of arteries. This finding is closely related to that of other studies. Studies conducted by Adaikkappan *et al*,<sup>5</sup> Ghimire<sup>6</sup> have found significant association between the IMT and age. Plavnik *et al*<sup>7</sup> and Pall *et al*<sup>8</sup> studies have also shown the similar result.

Our study showed a significant association between smoking and IMT of common carotid arteries. Hypertensive patients with history of smoking had thicker intima-media thickness compared to the non-smoker hypertensives. This showed smoker hypertensives are at risk of increased cardiovascular and cerebrovascular complications than non-smoker hypertensives. The exact mechanism causing smoking-related damage to the arterial wall and its relation to the atherosclerotic process is not known. Tell *et al*<sup>9</sup> and



**Fig. 1.** Variation of IMT with age in hypertensive patients



**Fig. 2.** Variation in IMT with age in healthy volunteers

**Table-2:** Mean IMT between non smoker and smoker hypertensive patients

	Hypertensive	Mean(mm)	P Value
Rt. IMT(mm)	Non Smoker	1.10	<0.02
	Smoker	0.84	
Lt. IMT(mm)	Non Smoker	1.09	<0.02
	Smoker	0.85	

Baldassarre *et al*<sup>10</sup> obtained similar result. Both active and passive smoking are associated with increased carotid intima-media thickness.<sup>11</sup> In contrast to this, Plavnik *et al*<sup>7</sup> observed no differences in IMT for carotid artery between smokers and nonsmokers.

The present study revealed a significant increase in IMT of both CCA in hypertensive patients as compared to the control group. Hypertensive patients irrespective of the duration were included in the study. Various studies have shown association between IMT and Hypertension. Adaikkappan *et al*<sup>5</sup> compared the carotid intima media thickness of hypertensive patients with that of normotensives and found similar result. The study conducted by Plavnik *et al*<sup>7</sup> also showed intima media complex (IMC) of common carotid artery to be thicker in hypertensive than in normotensive subjects. Similar results were obtained by Jiang *et al*<sup>12</sup> and Labrova *et al*<sup>13</sup> in their studies. Mechanisms by which hypertension predisposes to atherosclerosis may include endothelial dysfunction, hyperinsulinemia, hemodynamic stress, and multiple metabolic alterations. Impaired production of endothelium-derived relaxing factors and increased activity of endothelium-derived contractile substances have been demonstrated in hypertensive patients, preceding overt atherosclerotic disease.<sup>14</sup>

This study was not free from limitations because of its small sample size, convenient sampling and limited time. Most of the patients included in the study were from Kathmandu valley and there could be some bias in selection of control group as they were taken from the General health Check up clinic and might not represent the general population.

In conclusion, B mode ultrasound is a safe, non invasive method in the evaluation of intima media thickness in hypertensive patients. Intima media thickness assessment could be helpful in the prediction of cardiovascular disease risk so that timely management could prevent from complications. Furthermore, it can also be used in the monitoring of the hypertensive patients.

Large-scale studies in the general population over a longer time period should be done to evaluate the intima-media thickness in hypertensive patients so that the standards for the Nepalese population could be set.

#### REFERENCES

- Pandey MR, Upadhyaya LR, Dhungel S. Prevalence of hypertension in a rural community in Nepal. *Indian Heart J* 1981; 33: 284-9.
- Sharma D, KC MB, Rajbhandari S. Study of Prevalence, awareness, and control of hypertension in a suburban area of Kathmandu, Nepal. *Indian Heart J* 2006; 58: 34-7.
- Boon NA, Fox KAA. Systemic hypertension. In: Edwards CRW, Bouchier AD, Haslett C, Chilvers ER editors. Davidson's Principles and Practice of Medicine. 17th ed. Edinburgh: Churchill Livingstone; 1996, 266-8.
- Strong JP. Atherosclerotic lesions: natural history, risk factors and topography. *Arch Pathol Lab Med* 1992; 116: 1268-75.
- Adaikkappan M, Sampath R, Felix AJW, Sethupathy S. Evaluation of carotid atherosclerosis by B-mode ultrasonographic study in hypertensive patients compared with normotensive patients. *Indian J Radiol Imag* 2002 12: 365-8.
- Ghimire RK, Oli KK, Pradhan S, Agrawal JP. Carotid Intimomedia Complex thickening in patients with stroke: A case control study. *Nepal J Neuroscience* 2005; 2: 117-21.
- Plavnik FL, Ajzen S, Kohlmann OJ *et al*. Intima-media thickness evaluation by B-mode ultrasound: Correlation with blood pressure levels and cardiac structures. *Brazil J Med Biol Res* 2000; 33(1): 55-64.
- Páll D, Settakis G, Katona É *et al*. Increased common carotid artery intima media thickness in adolescent hypertension. *Cerebrovasc Dis* 2003; 15: 167-72.
- Tell GS, Polak JF, Ward BJ, Kittner SJ, Savage PJ, Robbins J. Relation of smoking with carotid artery wall thickness and stenosis in older adults. The Cardiovascular Health Study. The Cardiovascular Health Study (CHS) Collaborative Research Group. *Circulation* 1994; 90: 2905-8.
- Baldassarre D, Castelnuovo S, Frigerio B *et al*. Effects of Timing and Extent of Smoking, Type of Cigarettes, and Concomitant Risk Factors on the Association Between Smoking and Subclinical Atherosclerosis. *Stroke* 2009; 40: 1991-8.
- European carotid Plaque study Group. Carotid artery plaque composition: relationship to clinical presentation and ultrasound B-mode imaging. *Eur J Vasc Surg* 1995; 10: 23-30.
- Jiang YN, Kohara K, Hiwada K. Alteration of carotid circulation in essential hypertensive patients with left ventricular hypertrophy. *J Hum Hypertens* 1998; 12: 173-9.
- Labrova R, Honzikova N, Madirova E *et al*. Age-dependent relationship between the carotid intima-media thickness, baroreflex sensitivity, and the inter-beat interval in normotensive and hypertensive subjects. *Physiol Res* 2005; 54: 593-600.
- Touboul PJ, Elbaz A, Koller C *et al*. Common carotid artery intima-media thickness and brain infarction: the Etude du Profil Génétique de l'Infarctus Cérébral (GENIC) case-control study. The GENIC Investigators. *Circulation* 2000; 102: 313-8.