

## ULTRASONOGRAPHY OF ARM EDEMA AFTER AXILLARY DISSECTION FOR BREAST CANCER: A PRELIMINARY STUDY

A. Balzarini, M. Milella, E. Civelli, C. Sigari, F. De Conno

Department of Rehabilitation and Palliative Care (AB,CS,FDC) and Department of Radiology, National Cancer Institute (MM,EC), Milan, Italy

### ABSTRACT

*This work examined whether ultrasonography (US) provides detailed information about physical characteristics of lymphedema and whether there is agreement between imaging and clinical data. The study population included 46 women with chronic arm edema after axillary dissection for breast cancer. US showed in each patient an increase of subcutaneous tissue thickness compared with the contralateral arm. Fluid accumulation was seen in 16 patients (34.7%), fibrosis in 12 (26.0%), and a mixed picture (fibrosis and fluid) in 18 (39.1%). Correlation with clinical information ("soft," "medium," "hard," and "pitting" edema) demonstrated that US documented interstitial fluid in 68.4% of soft edema, mixed fluid and fibrosis in 64.2% of medium edema, and fibrosis in 76.9% of hard edema. Ultrasonography also showed that in soft and medium edema, fibrosis may already have formed. US is useful to follow progression, composition, and management of arm lymphedema after axillary dissection.*

Diagnosis of lymphedema is usually based on clinical and imaging criteria (1,2). Ultrasonography (US) represents a simple, rapid, repetitive and therefore a useful technique to image edema (3,4). US is also able to give valuable information on cutaneous and subcutaneous connective

tissue, on the extent of edema and/or fibrosis, and it has been suggested as a useful tool to follow the results of lymphedema treatment and its progression over time (5,6). On the other hand, clinical assessment may not consistently and reliably evaluate edema/fibrosis based on physical characteristics alone. Accordingly, we tried to verify the diagnostic capability of US in patients with arm edema after treatment for breast cancer and to correlate the US findings with the clinical impression of "soft," "hard," "medium," or "pitting" edema.

### CLINICAL MATERIAL

The study was carried out on 46 women (age 36-65 years; average 54.7) with chronic arm lymphedema following axillary dissection for breast cancer. Thirty five had undergone a breast quadrantectomy with axillary dissection and radiotherapy and 11 a modified radical mastectomy but without radiotherapy. The interval between operation and onset of lymphedema averaged 32.5 months with a minimum of 3 months and a maximum of 120 months. Each patient had "third stage" chronic arm edema according to Brunner (6). No patient had pain or functional limitation of shoulder motion. Edema was evaluated as slight in 12 (26.0%), moderate in 26 (56.5%), and severe in 8 (17.3%). The edema consistency was "soft" in

**TABLE 1**  
**Relationship Between Ultrasonographic and Clinical Data**

Ultrasonography	Consistency	Pitting				
		(n)	(%)		(n)	(%)
Primary fluid accumulation (19 patients)	Soft	13	(68.4)	Yes	17	(89.4)
	Medium	6	(31.5)	No	2	(10.5)
Mixed picture (fluid & fibrosis) (14 patients)	Soft	3	(21.4)	No	9	(64.2)
	Medium	9	(64.2)	No	5	(35.7)
	Hard	2	(14.2)	—	—	—
Fibrosclerosis (13 patients)	Medium	3	(23.0)	No	13	(100)
	Hard	10	(76.9)	No	13	(100)

**TABLE 2**  
**Tissue Consistency Correlated  
 With Ultrasonography Findings**

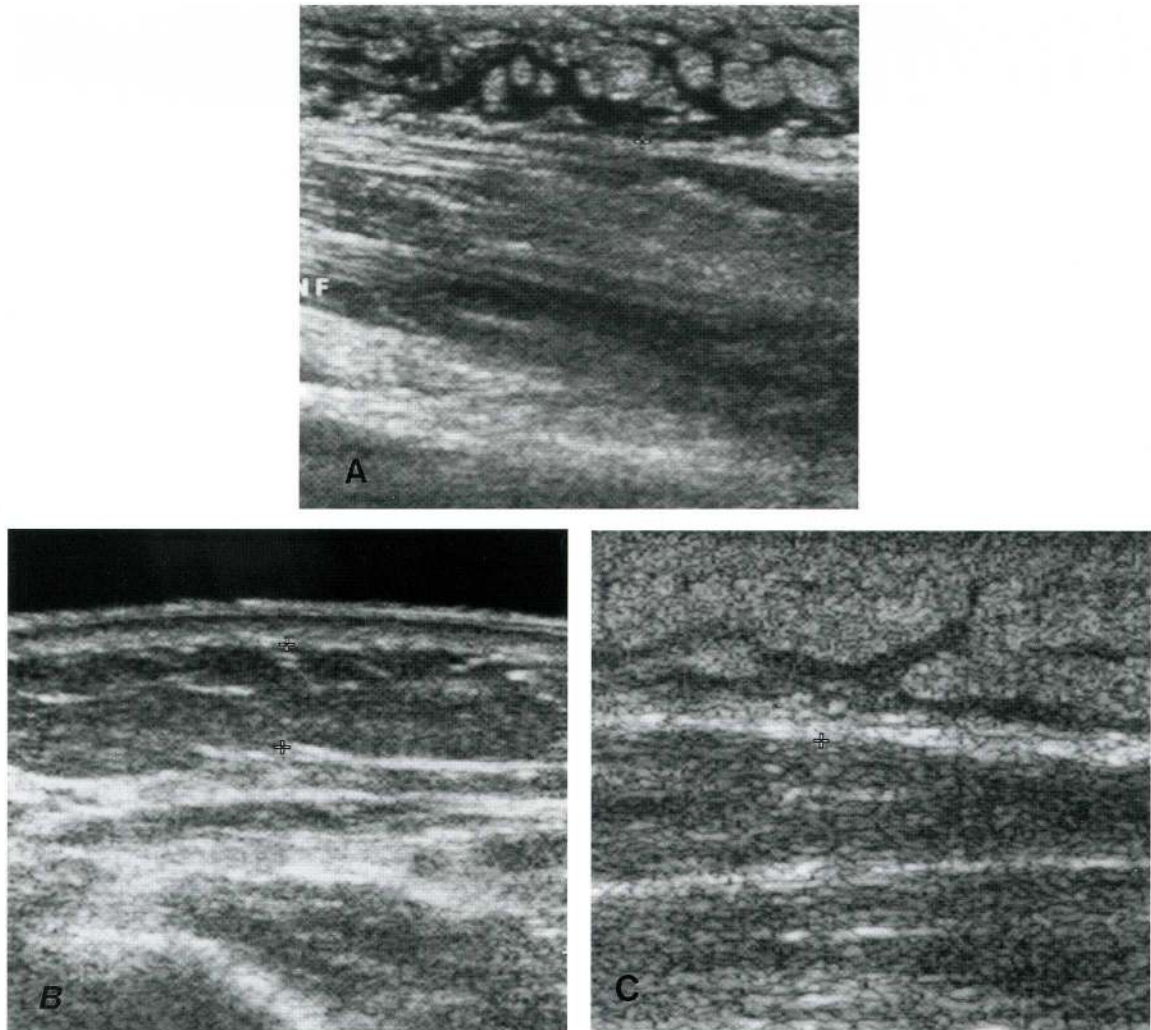
Consistency	n	Ultrasonography
Soft	16	Fluid—13
		Mixed—3
		Fibrosis—0
Medium	18	Fluid—6
		Mixed—9
		Fibrosis—3
Hard	12	Fluid—0
		Mixed—2
		Fibrosis—10

16 patients (34.7%); "medium" in 18 (39.1%); and "hard" in 12 (26.0%). Twenty six patients (56.5%) showed pitting with digital compression (14 with soft and 12 with medium edema). Patients were excluded who had previously undergone manual, mechanical, or pharmacologic treatment. Each patient at the time of clinical examination also underwent comparative circumferential measurement of both arms at 7 standard points.

Ultrasonography was performed using a high frequency transducer (10 MHz) to optimize the quality of imaging and optimize resolution of cutaneous and subcutaneous structures. An US was done on both arms including dorsal and volar aspects of upper arms and forearm and dorsum of the hand. Ultrasounds were analyzed for subcutaneous tissue thickness, distance from skin to superficial fascia, presence, degree and extent of lymphatic lacunae, localization, degree and extent of fibrosclerosis. Imaging and clinical data as to edema quality were correlated with palpable tissue consistency of soft, medium, and hard.

## RESULTS

Ultrasonography was performed at our first consultation, which was unrelated to the time of onset of arm edema. Each patient displayed an increase in subcutaneous tissue thickness compared with the contralateral arm. The thickness calculated as distance from skin to superficial fascia, ranged from 0.3 to 2.3 cm. We chose the maximum edema point at the upper arm and forearm for measurement. US showed the following images: edema fluid primarily in 19 patients



*Fig. 1. Ultrasound images of arm edema showing primarily water accumulation with large lymphatic lacunae (A), diffuse fibrosis (B), and advanced fibrosclerosis and obliteration (attenuated lacunae) (C).*

(41.3%), fibrosclerosis in 13 (28.2%), and a mixed picture in 14 patients (30.4%). No venous varicosities or venous stagnation were observed

US findings compared with clinical data are shown in *Tables 1 and 2*. Of 33 patients with notable interstitial fluid accumulation, "pitting" was present in 26 or 78.7%. US showed primarily fluid accumulation in patients with "soft" edema (68.4%), and in these pitting was present in 17 patients or 89.4%. Furthermore, 7 patients (36.8%) had

detectable fibrosis even though edema appeared less than one year earlier. In patients with a mixed picture on US, 9 or 64.2% had "medium" edema and pitted. In 10 patients or 76.9% with "hard" edema, there was diffuse fibrosclerosis without notable fluid accumulation. No patient of this group showed pitting with digital compression.

Lymphatic lacunae were seen in those patients with primarily fluid accumulation and "mixed" edema: with primarily fluid, US showed good association with lacunae in

89.4%; with mixed, however, US showed association with lacunae in only 28.5%. Analysis of degree and extent of lymphatic lacunae emphasized that with primarily fluid accumulation, lacunae were large and diffuse along the arm and forearm (*Fig. 1A*), whereas in mixed and hard edema, they were less prominent and fibrosis was more striking (*Fig. 1B, C*).

### CONCLUSIONS

Ultrasonography (US) is relatively easy, inexpensive, and rapid compared with other imaging tools such as computer tomography and magnetic resonance (7). We documented a close association between presence of edema and US images. Interstitial water accumulation is characteristic of "soft" edema although in some patients US already detected beginning signs of fibrosclerosis. This finding supports an evolution towards fibrosis with lymphedema, and it can appear independent of intercurrent infection and rehabilitative therapy. Tissue fibrosis, on the other hand, was evident in nearly all patients with "hard" edema and in 2/3 of patients with "medium" edema, if patients with a mixed picture are taken into account (*see Table 2*). Pitting is a reliable sign of fluid accumulation. It is present in "soft" and "medium" edemas, but absent in "hard" edema.

These data suggest that US is useful to follow the evolution with time of lymphedema and to direct rehabilitation programs to optimize therapy.

### ACKNOWLEDGMENTS

We thank Mr. R. Pagani for assisting in English translation.

### REFERENCES

1. Consensus Document of the International Society of Lymphology Executive Committee. The diagnosis and treatment of peripheral lymphedema. *Lymphology* 28 (1995), 113-117.
2. Mortimer, PS: Investigation and management of lymphoedema. *Vasc. Med. Rev.* 1 (1990), 1-20.
3. Franco, A, G N'Guyen Khac: Comment explorer les lymphoedemes des membres: Interet de l'ecographie-Doppler. *Sang. Thrombose Vaisseaux* 2 (1990), 213-216.
4. Valiant, L, F Auriol, A Calliens, et al: High resolution echography in the diagnosis of lymphoedema. XVIIIth Meeting of the European Group of Lymphology. Bruxelles 6-7 May 1994.
5. Michelini, S, A Failla, A Santoro, et al: Valutation avec echographie haute resolution de le effect du drainage lymphatique manuel et mecanique. *Eur. J. Lymph.* 2 (1995), 216.
6. Cavezzi, A, S Michelini: Il flebolinfedema. Dalla diagnosi alla terapia. Bologna, Ed Auxilia, 1997.
7. Dimakakos, PB: MRI and ultrasonographic findings in the investigation of lymphoedema and lipoedema. *Internat. Surg.* 82 (1997), 411-416.

**Augusta Balzarini, MD**  
**Rehabilitation and Palliative Care**  
**Department**  
**National Cancer Institute**  
**Via Venezian 1**  
**20133 Milan, Italy**