

Ultrasound-guided drainage of walled-off pancreatic necrosis. Case report.

Bogdan Popa¹, Madalina Ilie², Oana Plotogea², Ionut Olteanu³, Claudiu Turculeț³, Gabriel Constantinescu²

¹Radiology Department, ²Gastroenterology Department, ³Surgery Department, Clinical Emergency Hospital Bucharest, Romania

Abstract

ERCP (endoscopic retrograde cholangiopancreatography) represents a safe endoscopic procedure and serious complications (perforation, haemorrhage, and acute pancreatitis) are usually uncommon. We present the case of a 38-year-old patient with gallstones in the common biliary duct who developed acute pancreatitis after ERCP. One month later a huge fluid collection with necrotic tissue in the right paracolic gutter was found, the fluid being drained by percutaneous drainage under ultrasonographic guiding. The particularity of the case is the post-ERCP pancreatitis, complicated with walled-off necrosis, resolved without surgical intervention by using percutaneous drainage.

Keywords: ERCP, pancreatitis, walled-off necrosis, percutaneous drainage, ultrasonography

Introduction

Pancreatitis is one of the most common complication of endoscopic retrograde cholangiopancreatography (ERCP), accounting for an incidence of 1.6% to 15.7%, depending on a variety of risk factors [1,2]. Acute severe pancreatitis occurs in 1–5% of cases and can be complicated with pancreatic walled-off necrosis in its late phase (at least 4 weeks after the beginning of the disease) [3]. Percutaneous drainage of pseudocysts or recently formed abscesses can lead to complete recovery or, in other cases, it can delay the time of surgical intervention, until the patient becomes stable [4]. We present the case of a young patient in which ERCP for gallstones in the common biliary duct was complicated with severe pancreatitis and walled-off necrosis.

Case report

A 38-year-old woman presented at the Emergency Department with acute abdominal pain in epigastrium and right hypocondrium and nausea. She had no significant pathological history with the exception of a recent cholecystectomy. The clinical examination on admission revealed painful abdomen palpation. Laboratory findings showed cholestasis (alkaline phosphatase 380U/L, gamma-glutamyl-transferase 467U/L, normal bilirubin), hepatic cytolysis, positive inflammatory tests (leukocytosis 14,500/mm³, C-reactive protein 23mg/l). Abdominal ultrasonography revealed multiple hyperechoic images with posterior acoustic shadow in the common bile duct. The diagnosis of choledocholithiasis was established and ERCP with sphincterotomy was performed. Multiple gallstones were removed without any periprocedural incidents.

After 36 hours, the patient complained of severe abdominal pain radiating to the back. Blood tests revealed increased serum amylase concentration (1700 U/l). CT images showed fluid collections, pancreatic necrosis and important quantities of fluid in the peritoneal recesses. The Balthazar score was grade E and 4 points CT severi-

Received 02.11.2014 Accepted 25.12.2014

Med Ultrason

2015, Vol. 17, No 2, 259-261

Corresponding author: Madalina Ilie

Clinical Emergency Hospital

8 Calea Floreasca, Bucharest,

014461 Bucharest, Romania

E-mail: m_ilie2001@yahoo.com

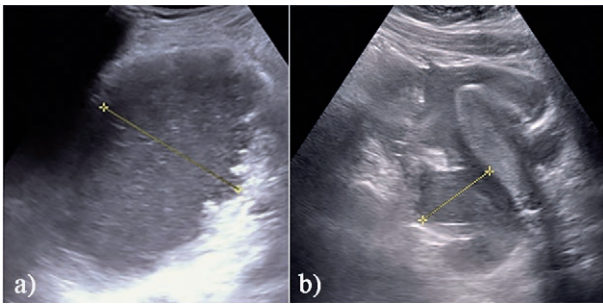


Fig 1. a) Large fluid collection with necrotic tissue in the right paracolic gutter; b) Fluid in Morrison space.

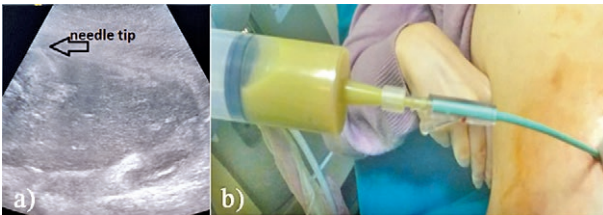


Fig 1. a) Right paracolic walled-off necrosis; b) Percutaneous drainage of the collection.

ty index. The patient's clinical status deteriorated and she was admitted to the intensive therapy unit. Her evolution was slowly favorable under conservative treatment. One month later, abdominal ultrasonography and CT showed a large fluid collection (6.5/6.2/16.3 cm) with necrotic tissue in the right paracolic gutter, in the Morrison space, in the Douglas pouch, and peripancreatic, with an enlarged, hypoechoic pancreas (fig 1).

It was decided to puncture the walled-off pancreatic necrosis under ultrasound guidance in order to drain it and to analyze the fluid, the procedure being a minimally invasive method. Therefore, percutaneously drainage was performed using a pig-tail catheter of 12F inserted by the Seldinger technique under ultrasound guidance, using first boujies on the guidewire (fig 2).

During the next 3 days, 2.5 liters of purulent fluid were evacuated. A sample was sent for bacteriological analysis. The results were positive for *Citrobacter* spp. These gram-negative bacteria are considered to be opportunistic nosocomial pathogens, being more frequently seen in immunocompromised patients during hospitalization. The antibiogram showed high antibiotic resistance. This could be explained by the fact that the infection was probably nosocomial. As indicated, targeted antibiotics (Imipenem) were introduced. The patient was discharged with good clinical status, absent fever, absent abdominal pain and normal blood tests and with maintained percutaneous drainage. After one week, she returned for the drainage removal and the ultrasound showed minimal residual necrosis of 1 cm.

Discussions

Pancreatitis is the most serious complication of all post-ERCP causing prolonged hospitalization, important morbidity, and occasionally death. Although, 75% of the patients develop transient increases in serum pancreatic enzymes, severe acute pancreatitis occurs in only 1-5% cases [3,5]. It can be predicted by several risk factors: female, young age, Oddi dysfunction, Wirsung cannulation, normal size of the bile duct, normal bilirubin, previous pancreatitis [5,6]. In our case, the pancreatitis caused a hospitalization for one month.

According to the Atlanta Classification, acute pancreatitis can be divided into interstitial edematous pancreatitis and necrotizing pancreatitis. Necrotizing pancreatitis most commonly manifests as necrosis involving both the pancreas and peripancreatic tissues. Local complications of the disease are acute peripancreatic fluid collection, acute necrotic collection which develops in the early phase and before demarcation, pseudocyst that develops >4 weeks after onset of interstitial edematous pancreatitis, and walled-off pancreatic necrosis which occurs >4 weeks after onset of necrotizing pancreatitis [4,7]. Our patient developed a walled-off necrosis, 4 weeks after the debut of pancreatitis.

Percutaneous drainage of peripancreatic collections may be considered as the first option treatment. In our case, the patient presented a walled-off necrosis and we used percutaneous drainage as a minimally invasive method. Finally, the procedure solved the case and the patient required no other invasive approaches. There are different sizes of catheters used, depending on the type of the fluid. If there is an infected necrosis, a thicker (14-30F) pig-tail catheter should be chosen. To evaluate the size of the collection, ultrasound is the most suitable examination as it can be performed at the bedside [8,9].

The drain can be removed when there is no pus and the fluid is clear and sterile, or the drainage is less than 10-30 ml/day and the cavity has deflated on imaging examinations [10]. If the cavity does not decrease or the septic status of the patient worsens, surgical treatment is indicated. Our patient's status improved and the catheter was removed when there was no more pus and the drainage decreased.

Studies have mentioned that in some cases of necrotic collections when drainage alone is not effective, a minimally invasive additional method can be very successful used, especially for perigastric localization, for example endoscopic transmural necrosectomy through expandable stents [11,12]. Sometimes these modalities can be combined at the same time or sequentially. Recently, a well-designed study from the Netherlands using a step-

up approach (percutaneous catheter drainage followed by video-assisted retroperitoneal debridement) which demonstrated the superiority of the step-up approach as reflected by lower morbidity and lower costs compared with open surgical necrosectomy [13]. It was reported that 20-50% of the patients recovered without surgery, only by drainage treatment [4,11-14].

Percutaneous drainage assisted by ultrasonography has rare complications. The injury of the surrounding organs and bleeding is seen in less than 2% of the patients. More frequently, the catheter can get clogged and must be replaced. Pancreatic fistulae may develop in relation with the skin or gastrointestinal tract, but most of them close spontaneously [4,12].

There are several particularities of our case that consist of the severity of post-ERCP pancreatitis, the presence of risk factors, and most important the minimally invasive approach of the case. The percutaneous drainage solved, in our case, a walled-off necrosis without any surgery.

In conclusion percutaneous drainage may be the first minimally invasive method for managing the fluid collections in necrotizing acute pancreatitis. Currently, a multidisciplinary consensus favors this method over open surgery for the management of pancreatic necrosis [15].

References

1. Cotton PB, Garrow DA, Gallagher J, Romagnuolo J. Risk factors for complications after ERCP: a multivariate analysis of 11,497 procedures over 12 years. *Gastrointest Endosc* 2009; 70: 80-88.
2. Barthet M, Lesavre N, Desjeux A, et al. Complications of endoscopic sphincterotomy: results from a single tertiary referral center. *Endoscopy* 2002; 34: 991-997.
3. Baillie J. Management of Post-ERCP Pancreatitis. *Gastroenterol Hepatol* 2011; 7: 390-392.
4. Szentkereszty Z, Kotán R, Sápy P. The Role of Percutaneous Drainage in the Treatment of Severe Acute Pancreatitis on the Basis of the Modified Atlanta Classification. *Acute Pancreatitis*. Luis Rodrigo (Ed.). 2012; 279-288.
5. American Society for Gastrointestinal Endoscopy. Complications of ERCP. *Gastrointest Endosc* 2012; 75: 467-473.
6. Donnellan F, Byrne MF. Prevention of Post-ERCP Pancreatitis. *Gastroenterol Res Pract* 2012; 2012: 796751.
7. Banks PA, Bollen TL, Dervenis C, et al. Classification of acute pancreatitis-2012: revision of the Atlanta classification and definitions by international consensus. *Gut* 2013; 62: 102-111.
8. Mortelé KJ, Girshman J, Szejnfeld D, et al. CT-guided percutaneous catheter drainage of acute necrotizing pancreatitis: clinical experience and observations in patients with sterile and infected necrosis. *AJR Am J Roentgenol* 2009; 192: 110-116.
9. Bruennler T, Langgartner J, Lang S, et al. Outcome of patients with acute, necrotizing pancreatitis requiring drainage-does drainage size matter? *World J Gastroenterol* 2008; 14: 725-730.
10. Zerem E, Imamovic G, Omerović S, Imširović B. Randomized controlled trial on sterile fluid collections management in acute pancreatitis: Should they be removed? *Surg Endosc* 2009; 23: 2770-2777.
11. Ross A, Gluck M, Irani S, et al. Combined endoscopic and percutaneous drainage of organized pancreatic necrosis. *Gastrointest Endosc* 2010; 71: 79-84.
12. Stamatakis M, Stefanaki C, Kontzoglou K, Stergiopoulos S, Giannopoulos G, Safioleas M. Walled-off pancreatic necrosis. *World J Gastroenterol* 2010; 14: 1707-1712.
13. Tenner S, Baillie J, DeWitt J, Vege SS; American College of Gastroenterology. American College of Gastroenterology guideline: management of acute pancreatitis. *Am J Gastroenterol* 2013; 108: 1400-1415.
14. Baril NB, Ralls SM, Wren SM, et al. Does infected peripancreatic fluid collection or abscess mandate operation? *Ann Surg* 2000; 231: 361-367.
15. Freeman MF, Werner J, Van Santvoort HC, et al. Interventions for necrotizing pancreatitis: summary of a multidisciplinary consensus conference. *Pancreas* 2012; 8 : 1176-1194.