

Ultrasound of the male genital tract in relation to male reproductive health

Francesco Lotti and Mario Maggi*

Sexual Medicine and Andrology Unit, Department of Experimental and Clinical Biomedical Sciences, University of Florence, Florence, Italy

*Correspondence address. Sexual Medicine and Andrology Unit, Department of Experimental and Clinical Biomedical Sciences, University of Florence, Viale Pieraccini 6, 50139, Florence, Italy. Tel. +39-55-4271415; Fax: +39-55-4271413; E-mail: m.maggi@dfc.unifi.it

Submitted on November 13, 2013; resubmitted on May 27, 2014; accepted on June 18, 2014

TABLE OF CONTENTS

- Introduction
- Methods
- Sonographic anatomy of the male genital tract and color-Doppler ultrasound normal patterns
 - Scrotal region
 - Prostate-vesicular region
- Color-Doppler ultrasound in pathological conditions
 - Testis
 - Varicocele
 - Epididymis and vas deferens
 - Prostate
 - Seminal vesicles
- Diagnostic value of scrotal and transrectal ultrasound and specific applications
 - Sensitivity and specificity of US in predicting azoospermia outcomes
 - Testis color Doppler ultrasound and surgical sperm retrieval in azoospermic subjects
 - Male genital tract US and hormonal treatments
 - Color Doppler ultrasound clinical utility and impact on male reproductive health management
- Conclusions

BACKGROUND: Infertility affects ~7% of all men. Despite much progress, mainly in genetics, its etiology remains obscure in ~50% of cases. To fill this gap, imaging of the male genital tract (MGT) has progressively expanded, providing useful information in the assessment of MGT abnormalities.

METHODS: A critical, systematic review of the available literature was performed using Medline, with no restrictions regarding date of publication (i.e. from inception date until March 2014), along with analysis of previous reports in color Doppler ultrasound (CDUS) atlas textbooks. Normal anatomy and sonographic characteristics of the MGT have also been summarized.

RESULTS: Testicular volume (TV) is tightly associated with both sperm and hormonal parameters. Ultrasound (US) offers a greater accuracy in TV measurement than Prader orchidometer (PO). However US- and PO-derived TV are closely related, making PO-derived TV informative enough in the work-up of the infertile man in everyday clinical practice. US-derived TV might play an independent role in specific clinical conditions (i.e. large hydrocele, inguinal testis, enlarged epididymis). Scrotal US may detect signs of testicular dysgenesis, often related to an impaired spermatogenesis and to a higher risk of malignancy, or testicular lesions suggestive of malignancy. A decreased testis vascularization is characteristic of testicular torsion, whereas hyperemia is often observed in epididymo-orchitis or in some malignant conditions (i.e. lymphoma, leukemia). The impact of varicocele detection and surgical correction on sperm parameters/fatherhood is debated. At present, the clinical management of varicocele is mainly based on physical examination. However, CDUS is useful in assessing venous reflux, when palpation is unreliable and/or in detecting recurrence/persistence after surgery. Epididymis head and/or tail dilation is suggestive of MGT obstruction or inflammation and both are related, along with echo-texture abnormalities, to impaired sperm parameters. Scrotal and transrectal US (TRUS) are useful in detecting

congenital uni- or bilateral absence of vas deferens (CBAVD), which may be associated with epididymis, seminal vesicles (SV) or kidney abnormalities/agenesis. TRUS plays a key role in assessing obstructive azoospermia and detecting distal CBAVD or anomalies related to ejaculatory ducts obstruction, such as ejaculatory duct abnormalities, prostate median cysts or SV enlargement/emptying impairment. TRUS findings lead to operational decision-making, such as testicular sperm extraction in the case of CBAVD, cyst aspiration in the case of a large prostatic median cyst, and surgical treatment if ejaculatory duct abnormalities are observed. TRUS may reveal prostate volume reduction (suggestive of hypogonadism) or enlargement, which can be related to aging or even metabolic abnormalities. Finally, TRUS may reveal prostate and SV echo-texture abnormalities suggestive of inflammation or SV stasis.

CONCLUSIONS: MGT-CDUS is a useful tool in detecting abnormalities related to impaired male reproductive health. However, it suffers from a lack of standardization and often produces subjective/vague diagnoses. To fill this gap, the European Academy of Andrology has promoted an ongoing multicenter study aimed at defining the MGT-CDUS characteristics of healthy, fertile men.

Key words: scrotal and transrectal ultrasound / color-Doppler ultrasound / male genital tract / subfertile/infertile men / azoospermia

Introduction

It has been estimated that almost 7% of men, in their reproductive age, are subfertile or infertile, due to testicular, pre-testicular or post-testicular problems (Krausz, 2011). Genetic abnormalities account for ~15% of all causes of male infertility. Despite many technical advances that have improved diagnostic skills, the etiological factors for male infertility are still obscure, and ~50% of men remain undiagnosed (Tuttelmann and Nieschlag, 2010; Krausz, 2011). To fill this gap, in infertility clinics, the use of imaging of the male genital tract (MGT) has been progressively expanded. With the newer advances in technology, in terms of image quality and resolution, ultrasound (US), which employs high-frequency sound waves to produce images, is now widely used in the assessment of male reproductive problems (Ammar *et al.*, 2012; Raza and Jhaveri, 2012). Gray-scale and color-Doppler US (CDUS) can provide useful information in the assessment of MGT abnormalities not necessarily related to only infertility. In fact, testicular malignancy and male accessory gland infection (MAGI) can be detected (Woodward *et al.*, 2002; La Vignera *et al.*, 2012). Hence, CDUS imaging of the MGT has a relevant impact not only on reproductive health but also on male health in general. Whereas scrotal CDUS has been commonly used in reproductive medicine for several years, only recently transrectal US (TRUS) has assumed a growing importance in the imaging of male infertility, extending the examination to the prostate, seminal vesicles and deferential ampullas (Ammar *et al.*, 2012; Lotti *et al.*, 2012a; Raza and Jhaveri, 2012). Here we systematically review the diagnostic impact of CDUS on the MGT in relation to subfertility/infertility, giving special attention to obstructive and non-obstructive azoospermia. Concepts of normal anatomy and characteristic US findings of the MGT will be critically analyzed, with the aim of identifying abnormalities related to the male infertile state. In line with the data obtained from our review, the clinical utility of CDUS and its impact on male reproductive health management is highlighted, point by point, and finally discussed (Table I).

Methods

An extensive Medline search was performed with no restrictions regarding date of publication (i.e. from inception date until March 2014) including the following words: ('male'[MeSH Terms] OR 'male'[All Fields]) AND ('ultrasonography'[Subheading] OR 'ultrasonography'[All Fields] OR 'ultrasound'[All Fields] OR 'ultrasonography'[MeSH Terms] OR 'ultrasound'[All Fields] OR

'ultrasonics'[MeSH Terms] OR 'ultrasonics'[All Fields]) AND ('infertility, male'[MeSH Terms] OR ('infertility'[All Fields] AND 'male'[All Fields]) OR 'male infertility'[All Fields] OR ('male'[All Fields] AND 'infertility'[All Fields])). The identification of relevant studies in the English language was performed independently by both authors. In addition, a 'pearl growing' strategy was employed, whereby, after obtaining the full text articles, the reference lists of all included studies were reviewed for additional publications that could be used in this review. Analysis of previous reports in CDUS atlas textbooks was also performed.

Sonographic anatomy of the male genital tract and color-Doppler ultrasound normal patterns

Scrotal region

Testicles are normally located in the scrotal sac (Figs 1 and 2). This peculiar position requires the use of a high-spatial resolution transducer dedicated to the study of soft parts (7–15 MHz). Usually the patient lays supine with the penis resting on the suprapubic region and gel applied to the scrotum, supported by a towel placed between the thighs. The testes are examined in transverse, oblique and longitudinal planes, and images are acquired in both gray-scale and color-Doppler modes, to assess testicular blood flow (Ammar *et al.*, 2012; Appelbaum *et al.*, 2013).

Testis

Volume. In clinical practice, testis volume (TV) is assessed by Prader's orchidometer (PO) (Nieschlag and Behre, 2010). However, orchidometry overestimates TV when compared with US (Behre *et al.*, 1989; Lenz *et al.*, 1993; Diamond *et al.*, 2000; Goede *et al.*, 2011; Rastrelli *et al.*, 2013). Clinically the assessed TV varies as a factor of age. Prepubertal boys show a TV ≤ 3 ml, with a size >3 ml representing the first sign of an ongoing puberty (Palmert and Dunkel, 2012). During puberty, the TV increases rapidly (Goede *et al.*, 2011), up to 10-fold between 10 and 15 years (Beres *et al.*, 1989). Reference growth curves for TV measured by PO in boys are available (Goede *et al.*, 2011). In a large cohort of males aged 0–28 years, the maximum TV was attained at 17–18 and 21–22 years among non-gypsies and gypsies, respectively (Beres *et al.*, 1989). Findings of TV declinings as a function of aging are not universal, as some studies report a decrease (Stearns *et al.*, 1974; Baker *et al.*, 1976) and some report a stable size (Harman and Tsitsouras, 1980; Sparrow *et al.*, 1980; Nieschlag *et al.*,

Table I Male genital tract (MGT) color-Doppler ultrasound (CDUS) clinical utility and impact on male reproductive health management.

CDUS parameter	Clinical utility	Comments		Impact on male reproductive health management
		Pros	Cons	
Scrotal CDUS				
Testis localization	F: Low GH: Moderate	<ul style="list-style-type: none">– Useful in localizing inguinal testis	<ul style="list-style-type: none">– Physical examination often informative enough– Useless in localizing intra-abdominal testis	<ul style="list-style-type: none">– Debated utility prior orchipexy planning– No impact on management of nonpalpable testes– Useful in follow-up of cryptorchid testis-related malignancy risk and contralateral testis
Testis volume (TV)	F and GH: Low	<ul style="list-style-type: none">– US useful when Prader orchidometer is unreliable (large hydrocele, inguinal testis, enlarged epididymis)	<ul style="list-style-type: none">– Prader orchidometer-derived TV is strictly related to US-TV; US shows greater accuracy, but Prader orchidometer is informative enough in clinical setting	<ul style="list-style-type: none">– Positive correlation with sperm and hormonal parameters– Poor utility in TESE decision-making– Poor utility in spermatogenic arrest
Testis echo-texture and calcifications	F: Moderate GH: Moderate	<ul style="list-style-type: none">– Inhomogeneity suggests testicular function impairment and abnormal sperm morphology– Severe inhomogeneity warns of malignancy– Microcalcifications warn of malignancy, suggesting US follow-up and eventually biopsy	<ul style="list-style-type: none">– Inhomogeneity may be found in several diseases or exposure to harmful causes , so it is not specific– Associations between microcalcifications and malignancy is recently debated– Poor utility in TESE decision-making	<ul style="list-style-type: none">– US useful in follow-up for malignancy when severe inhomogeneity or microcalcifications are found, especially when other risk factors are present– Biopsy debated in presence of microcalcifications– poor utility in infertility management
Testicular lesions	F: Low GH: Moderate/ High	<ul style="list-style-type: none">– Detection of small and large lesions and their characteristics (extension, vascularization, echo-texture)– Useful in follow-up of cryptorchid testis-related malignancy risk or small lesions	<ul style="list-style-type: none">– Physical examination informative enough to detect large/hard lesions– Poor information on the biological behavior of the lesion; histology required	<ul style="list-style-type: none">– Useful in follow-up of cryptorchid testis-related malignancy risk or small lesions– Moderate utility in large/hard lesions decision-making
Testicular vascularization	F: Low GH: High	<ul style="list-style-type: none">– Useful for torsion, infarction (reduced), orchi-epididymitis or some tumors (enhanced)– A few reports on positive correlation with sperm parameters and retrieval in TESE	<ul style="list-style-type: none">– Not standardized for fertility assessment	<ul style="list-style-type: none">– Useful for torsion, infarction (reduced), orchitis or some tumors (enhanced)– Not standardized for fertility assessment– poor utility for TESE decision-making
Varicocele	F: Moderate GH: Low	US: <ul style="list-style-type: none">– Confirms clinical diagnosis– Useful when physical examination is inconclusive– Detects the type of venous reflux– detects subclinical varicocele with persistent reflux– avoids 'false' varicocele (dilation without reflux)– Detects recurrence/persistence after surgery	<ul style="list-style-type: none">– Physical examination is sufficient for treatment decision– Treatment of subclinical varicocele disputable– Risk of complications	<ul style="list-style-type: none">– Poor utility when varicocele is palpable or visible– Useful when physical examination is unreliable– Useful in detecting recurrence/persistence after surgery

Epididymal diameters	F: Moderate GH: Low	<ul style="list-style-type: none"> – US shows greater accuracy compared with physical examination – Enlarged epididymis suggestive of past or present inflammation or post-testicular obstruction 	<ul style="list-style-type: none"> – Difficult to evaluate after scrotal surgery or in the presence of large varicocele – Primary obstruction may only be suggested, but not proven, by US 	<ul style="list-style-type: none"> – Epididymal enlargement may indicate distal obstruction in subjects with oligo/azoospermia, eventually leading to extent US investigation to the prostate-vesicular region
Epididymal echo-texture	F and GH: Low	<ul style="list-style-type: none"> – Echo-texture abnormalities may associate with past or present inflammation 	<ul style="list-style-type: none"> – Not standardized 	<ul style="list-style-type: none"> – May associate with reduced sperm count and motility
Epididymal vascularization	F: Low GH: Moderate	<ul style="list-style-type: none"> – Hyperaemia indicates inflammation – Follow-up after medical treatment 	<ul style="list-style-type: none"> – Not standardized 	<ul style="list-style-type: none"> – Hyperemia indicates medical treatment (associated with medical history and clinical symptoms/signs)
Epididymal abnormalities	F: Moderate GH: Low	<ul style="list-style-type: none"> – US detects abnormalities or absence of the epididymis 	<ul style="list-style-type: none"> – epididymal cysts have low utility in infertility assessment 	<ul style="list-style-type: none"> – useful in suggesting absence or downstream obstruction
Vas deferens (VD)	F: High GH: Moderate	<ul style="list-style-type: none"> – US detects abnormalities or absence of the proximal or distal VD – VD dilation may indicate distal obstruction – (see 'epididymal diameters') 	<ul style="list-style-type: none"> – The intermediate portion of the VD is not detectable by US 	<ul style="list-style-type: none"> – Useful in defining OA cause – Positive sperm retrieval by TESE – VD absence suggests CFTR gene and kidneys US evaluation
Transrectal CDUS				
Prostate volume	F: Low GH: Moderate	<ul style="list-style-type: none"> – US shows greater accuracy than physical examination – Useful to assess upward growth (bladder) 	<ul style="list-style-type: none"> – Physical examination may reveal normal, reduced or enlarged prostate – TRUS is uncomfortable 	<ul style="list-style-type: none"> – Not very useful in infertile male management – Reduced volume may suggest hypogonadism – Useful in benign prostatic hyperplasia management
Prostate echo-texture	F and GH: Low	<ul style="list-style-type: none"> – Abnormalities suggestive of past or present inflammation (see Table II) 	<ul style="list-style-type: none"> – Abnormal echo-texture: frequent, poorly specific 	<ul style="list-style-type: none"> – Impact on fertility not demonstrated
Prostate vascular parameters	F: Low GH: Moderate	<ul style="list-style-type: none"> – May indicate present inflammation (see Table II) – Correlation with CPPS and PLS (see Table II) 	<ul style="list-style-type: none"> – Few available studies – Not standardized 	<ul style="list-style-type: none"> – Impact on fertility not demonstrated
Prostate median cyst	F: Moderate/ highGH: Low	<ul style="list-style-type: none"> – Large cysts may cause ejaculatory duct obstruction – US used in follow-up after cyst aspiration 	<ul style="list-style-type: none"> – No size cutoff associated with distal obstruction 	<ul style="list-style-type: none"> – Useful in defining OA cause – Aspiration in OA subject may lead to semen parameters improvement
Ejaculatory ducts (ED)	F: Moderate/high GH: Low	<ul style="list-style-type: none"> – TRUS detects abnormalities 		<ul style="list-style-type: none"> – Useful in defining OA cause – ED cyst may indicate CFTR gene evaluation
Seminal vesicles (SV) agenesis	F: Moderate/high GH: Low	<ul style="list-style-type: none"> – TRUS detects uni- or bilateral absence 		<ul style="list-style-type: none"> – SV absence suggests CFTR gene and kidneys US evaluation
Seminal vesicles volume	F: Moderate GH: Low	<ul style="list-style-type: none"> – Dilation after ejaculation may indicate partial ED obstruction 	<ul style="list-style-type: none"> – Dilation or hypoplasia are not standardized 	<ul style="list-style-type: none"> – Dilation suggestive of partial ED obstruction, but no standardization

Continued

Table 1 Continued

CDUS parameter	Clinical utility	Comments	Cons	Impact on male reproductive health management
Seminal vesicles echo-texture	F: Low/moderate GH: Low	Pros <ul style="list-style-type: none">Abnormalities may indicate past or present inflammation or stasis (see Table II)Giant cyst may indicate genitourinary anomalies investigation	Cons <ul style="list-style-type: none">Should be evaluated after ejaculation	<ul style="list-style-type: none">Giant cyst may indicate genitourinary anomalies investigationAbnormalities may indicate inflammation or stasis

The clinical utility of the parameters investigated by CDUS has been arbitrarily classified as low, moderate and high, in relation to fertility (F) or general health (GH). The statements made are extensively discussed in the text. MGT, male genital tract; US, ultrasound; CDUS, color-Doppler ultrasound; TRUS, transrectal ultrasound; TV, testis volume; TESE, Testicular Sperm Extraction (including micro TESE); OA, obstructive azoospermia; ED, ejaculatory duct; SV, seminal vesicles; CFTR, cystic fibrosis transmembrane conductance regulator.

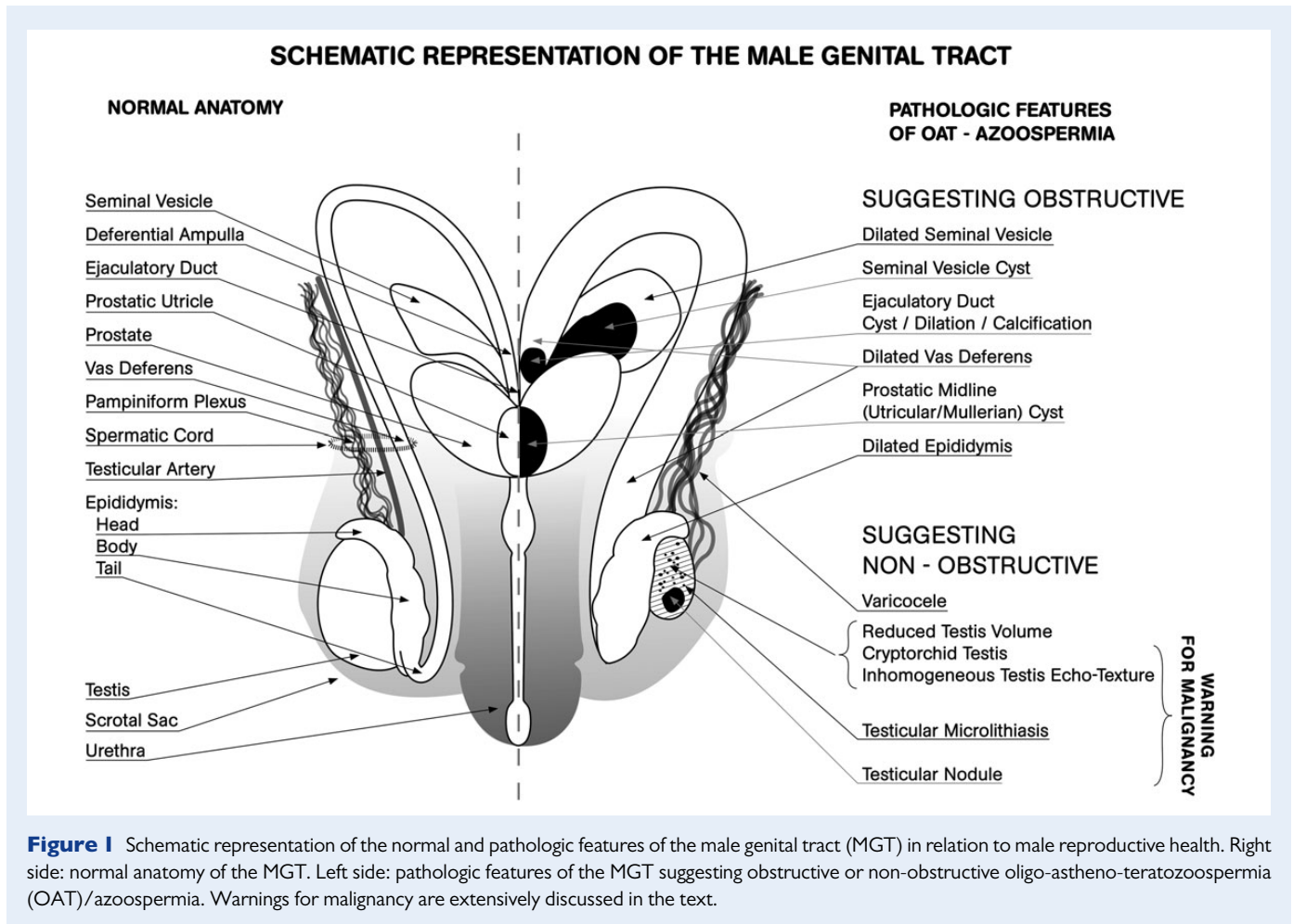
1982). It has also been reported that age, malnutrition and illness exert independent effects on testicular size (Handelsman and Staraj, 1985), with age alone demonstrating a reduction in TV only in the eighth decade of life (Handelsman and Staraj, 1985; Sartorius and Nieschlag, 2010). However, recent studies suggest that a mild TV decline often occurs earlier, starting from the 50–60 s on (Pilatz et al., 2013a; Rastrelli et al., 2013). Although many reports regarding PO-derived TV are available, there are no uniform reference values, due to differences in the nature of the populations studied (geographic area, nourishment, ethnicity and environmental factors) (Diamond, 1986; Takihara et al., 1987; Bahk et al., 2010). The mean PO-based TV reported in the European general population is 20.0 ± 5.0 ml (Jørgensen et al., 2002; Jensen et al., 2004), whereas in infertile patients it is 18.0 ± 5.0 ml (Nieschlag and Behre, 2010).

US offers a greater accuracy in TV measurement than PO (Lenz et al., 1993; Sakamoto et al., 2007a, b). However, PO- and US-derived TV are closely related (Rastrelli et al., 2013), both in boys (Goede et al., 2011) and in adult eugonadal or hypogonadal subjects (Behre et al., 1989; Lenz et al., 1993; Diamond et al., 2000; Rastrelli et al., 2013). Hence, in clinical practice, PO-derived TV may be considered a reliable surrogate of US-measured TV, easier to perform and not costly. Nevertheless, US maintains a role in TV assessment when PO is unreliable, such as in the case of large hydrocele, inguinal testis, epididymal enlargement/fibrosis, thickened scrotal skin (Behre et al., 1989; Sakamoto et al., 2006; Nijs et al., 2007; Behre and Zitzmann, 2010) or a small testis in which the epididymis is large in comparison to the total TV (Goede et al., 2011).

At US, testicles appear as ellipsoid organs of 3–5 cm length, 2–4 cm width and 3 cm anterior-posterior size (Appelbaum et al., 2013) (Fig. 3A). TV is calculated automatically using some ultrasonography softwares, by applying the ellipsoid formula ($\text{length} \times \text{width} \times \text{height} \times 0.52$). However, the use of this mathematical formula is currently debated (Lin et al., 2009; Goede et al., 2011; Pilatz et al., 2013a). The mean TV difference when comparing US and PO is 4–5 ml (Carlsen et al., 2000; Sakamoto et al., 2007a, 2008). Hence, assuming that a normal TV by PO is >14 – 15 ml (Takihara et al., 1987; Forti and Krausz, 1998), the normal US-TV should be >10 – 11 ml (Lotti et al., 2012b). However, so far, testicular hypotrophy by US has been defined as a TV <12 ml (see Condorelli et al. (2013)).

Normative TV values for boys aged 0–6 years (Kuijper et al., 2008) and 6 months–18 years (Goede et al., 2011) are available, based on PO, and only few studies have assessed TV by US in the general adult population. US-assessed TV varies according to the mathematical formula applied; however, the results are similar among different ethnic groups (Lenz et al., 1993; Bahk et al., 2010; Pilatz et al., 2013a; Foresta et al., 2013). A recent study (Pilatz et al., 2013a) reported TVs in the same population according to different mathematical formulas. Using the ellipsoid formula, an average TV of 14 ml was reported in healthy German (Pilatz et al., 2013a), Danish (Lenz et al., 1993) and Italian (Foresta et al., 2013) men. Right TV has been reported to be larger than the left TV by some (Beres et al., 1989; Lenz et al., 1993; Pilatz et al., 2013a), but not all (Bahk et al., 2010), authors. An average US-detected TV in infertile patients ranges from ~ 10 ml (Lenz et al., 1994) to $\sim 13.0 \pm 5.0$ ml (Sakamoto et al., 2007a).

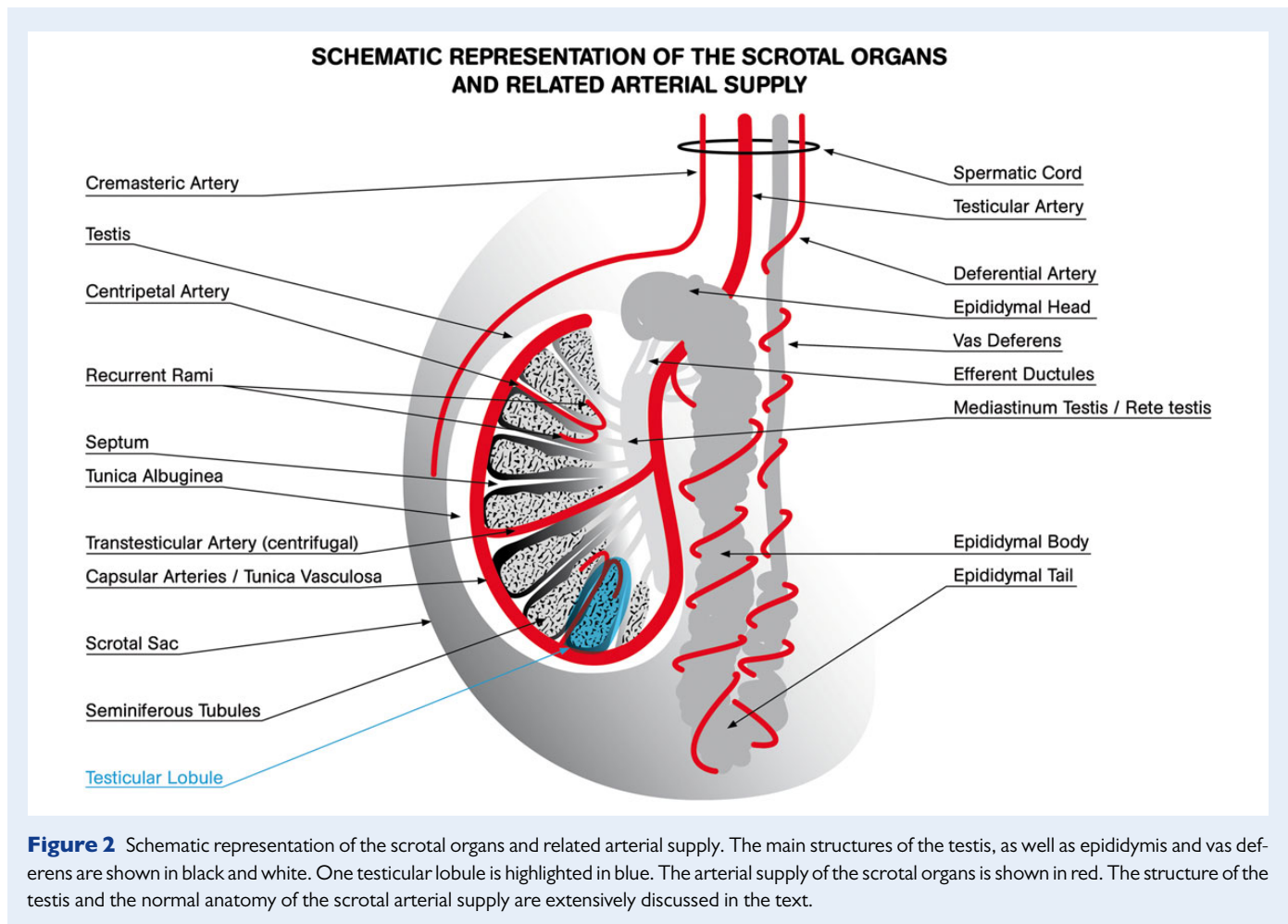
Homogeneity and echogenicity. The normal adult testis has a homogeneous granular echo-texture, composed of uniformly distributed medium level echoes, resembling the echogenicity of the normal thyroid gland (Hamm and Fobbe, 1995; Isidori and Lenzi, 2008)



(Fig. 3A). It is surrounded by an echogenic fibrous capsule, the tunica albuginea, which projects into the interior of the testis with fibrous septa, dividing it into 200–400 lobules (Fig. 2). Each lobule contains interstitial Leydig cells and seminiferous tubules (ST) (Fig. 2), with differentiating germinal cells and somatic Sertoli cells. It is estimated that ST account for ~85% of the entire TV (Takahara *et al.*, 1987; Forti and Krausz, 1998; Kollin *et al.*, 2006). Septa radiating from the tunica albuginea (Fig. 2) may be seen as delicate linear hypoechoic striae, converging to form the mediastinum testis (Fig. 2), which appears in a longitudinal scan as a hyperechoic line, eccentrically located. Whereas the concept of echo-texture homogeneity is a relatively objective finding, the construct of normal echogenicity is more operator-dependent. Homogeneity has been classified on a 5-point scale by Lenz *et al.* (1993) and Westlander *et al.* (2001) (Table II). Echogenicity depends on the ST maturation and germ cell representation. Prepubertal testis, compared with the adult one, is slightly more hypoechoic, since ST have not developed a lumen yet. During puberty, as a function of lumen development, testis echogenicity progressively increases, up to average adult level. A reduction in and/or an increase in interstitium leads to a hypoechoic and/or inhomogeneous echo-texture (Beres *et al.*, 1989; Loberant *et al.*, 2010) (Fig. 4A and B, respectively).

Vascularization. The testes are mainly perfused by the testicular arteries (TA) (Figs 1 and 2), which arise from the aorta, distal to the renal arteries, enter the spermatic cord at the deep inguinal ring and reach

the upper testicular pole (Horstman *et al.*, 1991a) (Figs 2 and 3B). Each TA lies in the spermatic cord with the ipsilateral cremasteric artery (a branch of the inferior epigastric artery) and the deferential artery (a branch of the vesicular artery) (Horstman *et al.*, 1991a) (Fig. 2). Although there are anastomoses between these vessels, the TA primarily supplies the testis, the deferential artery perfuses the epididymis and vas deferens, and the cremasteric artery supplies the peritesticular tissues and the scrotal wall (Horstman *et al.*, 1991a; Isidori and Lenzi, 2008) (Fig. 2). After entering the scrotum, the TA runs along the posterior aspect of the testis and penetrates the tunica albuginea, supplying two sets of arteries, the capsular and the transmediastinal arteries (Fig. 2). The capsular arteries have a superficial course beneath the tunica albuginea, in a layer called the tunica vasculosa, over the surface of seminiferous tubules (Schlegel and Li-Ming, 1997) (Fig. 2). They branch centripetal arteries that enter the testicular parenchyma and flow toward the mediastinum (Horstman *et al.*, 1991a) penetrating between the septa separating the seminiferous tubules (Schlegel and Li-Ming, 1997). As they approach the mediastinum, the centripetal arteries arborize into recurrent rami that branch back in the opposite direction, carrying blood from the mediastinum into the testis (Middleton *et al.*, 1989; Migaleddu *et al.*, 2012) (Fig. 2). In some men, a large branch of the TA, the centrifugal transmediastinal artery, enters at the mediastinum and run across the testicular parenchyma with a straight course, to form capsular branches on the opposite side (Horstman *et al.*, 1991a; Pais *et al.*, 2004) (Fig. 2).



Pampiniform plexus

Normal pampiniform plexus (Fig. 1) is scarcely appreciable by physical examination. It is also poorly detected by gray-scale US, because of the difficulty in differentiating it from the other structures in the spermatic cord (Fig. 3B). Hence, color or power Doppler should be applied and they should not show any venous reflux. In normal conditions, the pampiniform plexus appears as a complex network of small vessels <2 mm in diameter (Dogra *et al.*, 2003; Cina *et al.*, 2006) converging into the spermatic veins. The right spermatic vein enters obliquely into the inferior vena cava, whereas the left one enters perpendicular into the left renal vein, and is therefore burdened by higher blood hydrostatic pressure. When the pressure becomes excessive and/or the venous valvular mechanism is impaired, venous reflux and dilation may occur, leading to varicocele (Gat *et al.*, 2008) (see below).

Epididymis and proximal vas deferens

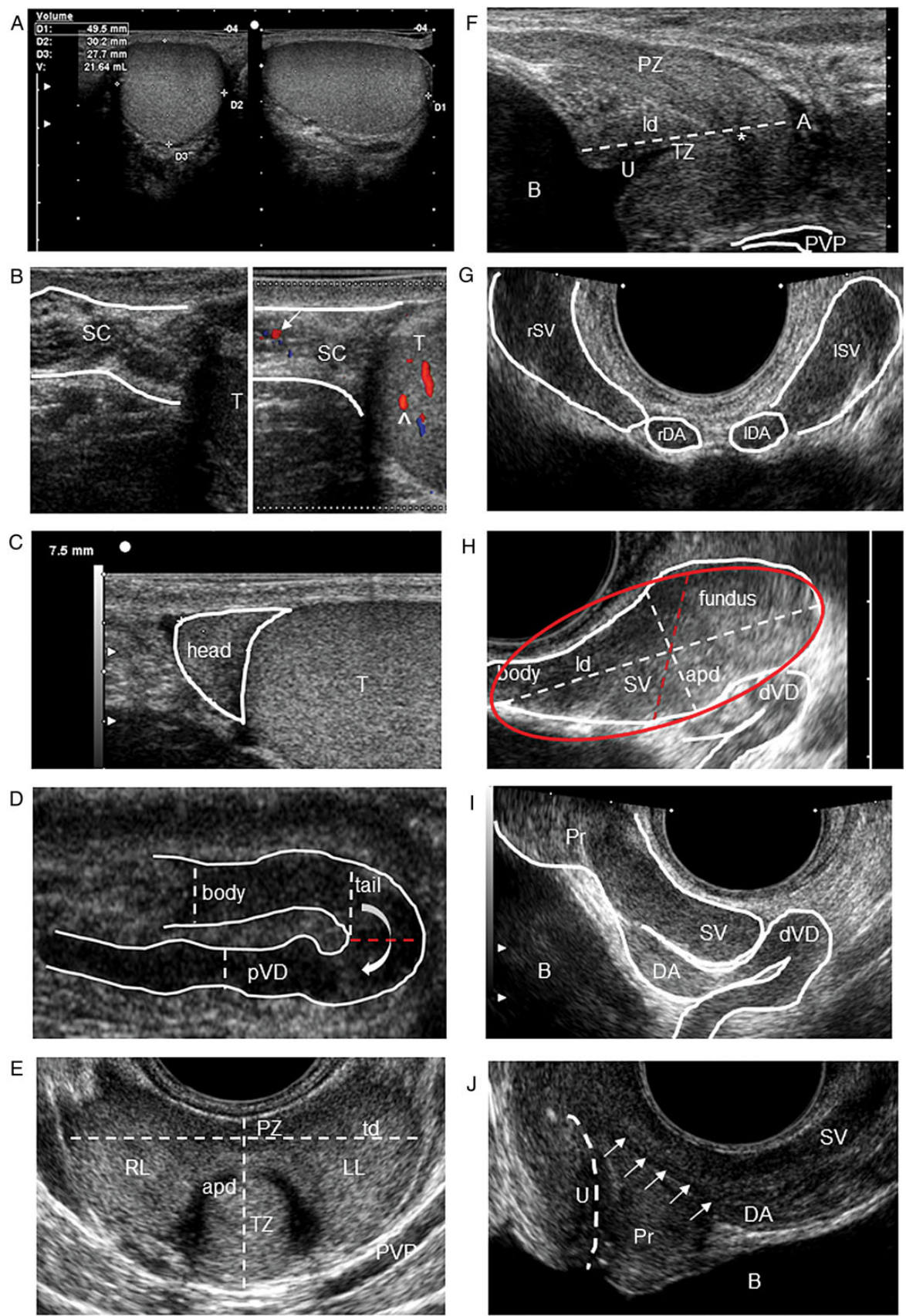
The normal epididymis is a soft organ that lies along the superior margin of the testis and is classically divided into three segments: the head, body and tail (Figs 1 and 2). The head contains 10–15 efferent ductules originating from the rete testis, which converge in a single, convoluted tube in the distal portion (Fig. 2). At US, the epididymis is usually detected posterior-laterally to the testis, with the head and tail at the upper and lower pole of the testis, respectively. The normal head is triangular,

with echogenicity comparable to that of the testis and usually slightly more echogenic than the body and tail (Dogra *et al.*, 2003; Lee *et al.*, 2008) (Fig. 3C). It is usually measured in a longitudinal scan from the top to the base of the triangle (Pezzella *et al.*, 2013; Pilatz *et al.*, 2013a) (Fig. 3C). The body and tail are measured considering the anterior-posterior diameters (Vicari, 1999; Pezzella *et al.*, 2013) (Fig. 3D). A head of 5–12 mm (Behre *et al.*, 1995; Vicari, 1999; Dogra *et al.*, 2003; Lee *et al.*, 2008; Pezzella *et al.*, 2013; Pilatz *et al.*, 2013a), a body of 2–4 mm (Behre *et al.*, 1995; Dogra *et al.*, 2003; Lee *et al.*, 2008) and a tail of 2–6 mm (Vicari, 1999; Dogra *et al.*, 2003; Lee *et al.*, 2008) have been proposed as normal. Blood flow is detectable by CDUS in discrete vascular spots in all tracts of the epididymis (Keener *et al.*, 1997).

The vas deferens (VD) is a straight tense cord which extends along the spermatic cord (Figs 1 and 2). VD absence, with or without epididymal agenesis, is often a difficult palpatory diagnosis, to be confirmed by US. At scrotal US, the proximal VD appears as a straight duct, slightly hypoechoic compared with the epididymis, originating from the epididymal tail (Fig. 3D) and extending, along the spermatic cord, toward the inguinal channel (Isidori and Lenzi, 2008).

Prostate-vesicular region

The prostate-vesicular region is usually assessed at transrectal US (TRUS), using a transrectal biplanar probe (linear and convex transducer,



6.5–7.5 MHz) or an 'end fire' probe (6.5 MHz, field of view 50–200°), through transverse, longitudinal and oblique scans, with patients placed in the left lateral decubitus (Behre et al., 1995; Older and Watson, 1996; Vicari, 1999; Lotti et al., 2011a, b, 2012a, c).

Prostate

The prostate is a tubuloalveolar, exocrine gland surrounding the male urethra (Fig. 1) just below the neck of the bladder, which produces prostatic fluid, an acidic secretion which makes up ~30% of the total ejaculate (Cooper, 2010).

The normal prostate at TRUS appears in young adults as symmetric, triangular or ellipsoid and, in older men, pear- or orange-shaped (Older and Watson, 1996; Raza and Jhaveri, 2012). Its base lies at the bladder neck, at the beginning of the urethra, detectable in a longitudinal scan as a hypoechoic duct curving toward the prostatic apex. TRUS identifies a peripheral zone (PZ), which extends laterally and posteriorly from the apex to the base, and a transitional zone (TZ), centrally located and slightly hypoechoic (Fig. 3E). The PZ and TZ show a 3:1 ratio in young men (Doble and Carter, 1989; Jin et al., 2001). Some authors also report a central zone (Berger et al., 2006; Jin et al., 2001). Prostate volume (PV) is often measured using a planimetric method (Behre et al., 1995; Vicari, 1999; Lotti et al., 2011a, b). It is calculated by measuring three diameters (anterior-posterior and transverse in the transversal scan, longitudinal in the sagittal one; Fig. 3E and F) using the mathematical formula of the ellipsoid (Collins et al., 1995; St Sauver et al., 2006; Lotti et al., 2011a, 2014a). 'TZ volume' is similarly calculated (St Sauver et al., 2006; Lotti et al., 2014a). A PV of 20–25 ml has been proposed as normal in young men (Raza and Jhaveri, 2012). The normal adult prostate shows thin, densely packed and homogeneously deployed echoes. The periprostatic venous plexus (PVP) is detectable as a slightly hypoechoic system of vessels (Fig. 3E and F). Intraprostatic arteries are grouped in central/periurethral and peripheral/capsular arteries, supplying the TZ and PZ, respectively (Older and Watson, 1996).

Seminal vesicles, deferential ampullas and ejaculatory ducts

The seminal vesicles (SV) are paired, saccular and coiled structures, located superior and posterior to the prostate (Fig. 1), between the bladder and the rectum (Ramchandani et al., 1993; Kim and Lipshultz, 1996; Kim et al., 2009). They produce an alkaline fluid contributing 50–80% of the ejaculate volume (Ramchandani et al., 1993; Kim et al., 2009).

SV appear at TRUS as symmetric organs which lie cephalic to the prostate and posterior to the bladder (Ramchandani et al., 1993; Kim and Lipshultz, 1996; Kim et al., 2009; Lotti et al., 2012a). They have a typical 'bow-tie' appearance in transversal scans, and a club or tennis-racket shape in longitudinal scans (Fig. 3G and H, respectively). SV echo-texture is characterized by homogenous fine echoes and it is slightly less echogenic than the prostate (Ramchandani et al., 1993; Kim and Lipshultz, 1996).

SV volume is positively affected by circulating testosterone (Sasagawa et al., 1989, 1990) and prolactin (Lotti et al., 2013a), and increases during a prolonged sexual abstinence (Lotti et al., 2012a). In relatively young subjects, SV volume is negatively associated with age (Lotti et al., 2012a) and tends to shrink after the fifth decade, showing a significant reduction in the eighth compared with the fourth decade (Terasaki et al., 1993).

While most of the available studies have assessed SV diameters, we recently proposed calculating SV volume by measuring the maximum longitudinal and anterior-posterior diameters, using the 'ellipsoid/prolate spheroid' mathematical formula (Lotti et al., 2012a) (Fig. 3H). SV volume varies with ejaculation and is positively related to the ejaculate volume, but not with sperm parameters (Lotti et al., 2012a).

The deferential ampullas (DA) (Fig. 1) appear at TRUS as oval structures medial to the SV in transversal scans, just cephalic to the prostate, or as distal VD enlargements in longitudinal scans (Fig. 3G and I, respectively). They have an echo-texture similar to that of the SV.

The ejaculatory ducts (Fig. 1) appear at TRUS as subtle and hypoechoic, with a normal caliber < 2 mm (Fig. 3J). They are detectable in

Figure 3 Normal color-Doppler ultrasound (CDUS) features of the organs of the male genital tract. **(A)** Testis of normal volume, homogeneity and echogenicity with ellipsoid shape. Longitudinal (right figure) and transversal (left figure) scans of the testis, with length (D1), width (D2) and height (D3) measurements are reported. **(B)** Left figure: B-mode appearance of the spermatic cord (SC) and the upper pole of the testis (T) in a longitudinal scan. Small, non-dilated venous vessels of the pampiniform plexus are difficult to differentiate from the other structures of the SC. Right figure: CDUS detection of the testicular artery (arrow) in the SC and recurrent ramus (^) of an intratesticular centripetal artery. Venous reflux at rest in the venous vessels is not detectable. **(C)** Normal epididymal head with triangular shape in a longitudinal scan, homogeneous, with echogenicity comparable to that of the testis (T). Its length is measured from the top to the base of the triangle. **(D)** Homogeneous epididymal body and tail and proximal vas deferens (pVD) in a longitudinal scan. Their echogenicity is slightly hypoechoic compared with the testis and the epididymal head in (C). Their diameters are reported as dashed lines. The red dashed line indicates the end of the epididymal tail and the beginning of the pVD. The curve arrow indicates the epididymal-deferential handle. **(E)** Prostate of normal volume, homogeneity and echogenicity in a transversal scan. Peripheral and transitional zones (PZ and TZ) show a 3:1 ratio in young men. Right and left lobes (RL and LL, respectively) and periprostatic venous plexus (PVP) are indicated. Anterior-posterior and transverse diameters ('apd' and 'td', respectively) are reported. **(F)** Prostate of normal volume, homogeneity and echogenicity in a sagittal scan. Peripheral and transitional zones (PZ and TZ, respectively) and the apex (A) are indicated, as well as the bladder (B), urethra (U), prostatic utricle (*) and periprostatic venous plexus (PVP). The longitudinal diameter ('ld') is reported. **(G)** Right and left seminal vesicles (rSV and lSV, respectively) with typical 'bow-tie' appearance and, medial to them, right and left deferential ampullas (sDA and lDA, respectively) in a transversal scan. **(H)** Seminal vesicle (SV) assessed by 'end fire' probe in sagittal scan. The fundus and body are reported, as well as the longitudinal and anterior-posterior diameters ('ld' and 'apd' dashed lines, respectively). A schematic model of SV volume calculation is reported, using the 'ellipsoid/prolate spheroid ($d1 > d2 = d3$)' (red ellipse) mathematical formula ($d1 \times d2 \times d3 \times 4/3 \times \pi$), with $d1 = ld$ and $d2 = apd$, and $d3$ assumed = $d2$ (red dashed line) (according to Lotti et al. (2012a)). **(I)** Distal vas deferens (dVD) and deferential ampulla (DA) beside a section of the seminal vesicle (SV) assessed by 'end fire' probe in a sagittal scan. **(J)** Ejaculatory duct (arrows) and prostatic utricle assessed by 'end fire' probe in a sagittal scan. The deferential ampulla (DA), a section of the seminal vesicle (SV), the urethral (U) course (dashed line), bladder (B) and prostate (Pr) are reported.

Table II Color-Doppler ultrasound (CDUS) abnormalities of the organs of the male genital tract, clinical associations and available cutoff discriminating normal and pathologic features.

CDUS echo-pattern abnormalities	Associations	Cutoff
Testis		
Inhomogeneity	– Carcinoma in situ in cryptorchid men (Lenz <i>et al.</i> , 1987)	Abnormal pattern: grade 2–5
Lenz <i>et al.</i> (1993)	– Testis tumor (Lenz, 1991; Woodward <i>et al.</i> , 2002; Isidori and Lenzi, 2008)	
(1) Very uniform pattern	– Several pathological conditions, including hypogonadism, ischemia, orchitis, trauma, torsion, exposure to physical or chemical agents, chemo- and radio-therapy or alcohol abuse (Loberant <i>et al.</i> , 2010; Migaleddu <i>et al.</i> , 2012; Lotti <i>et al.</i> , 2013b)	
(2) Slightly irregular pattern	– Klinefelter's syndrome: inhomogeneous testicles with spread hyper- and hypoechoic foci (Ekerhovd and Westlander, 2002)	
(3) Moderately irregular pattern or small echogenic points throughout any sectional view	– M540 bodies, round anucleated elements, detected by fluocytometry in the semen, markers of apoptosis-related spermatogenesis derangement (Lotti <i>et al.</i> , 2012d)	
(4) Very irregular pattern or bright echogenic spots (at least throughout the testis)	– Metabolic syndrome, a cluster of medical conditions which increases the risk of type 2 diabetes mellitus and cardiovascular diseases, recently recognized as a new risk factor also for fertility (Alberti <i>et al.</i> , 2009; Kasturi <i>et al.</i> , 2008; Lotti <i>et al.</i> , 2013b)	Abnormal pattern: grade 3–5
(5) Tumor suspected due to demarcated area		
Westlander <i>et al.</i> (2001)		
(1) Homogeneous		
(2) Homogeneous with some hyperechogenic foci		
(3) Heterogeneous with spread hyperechogenicity		
(4) Heterogeneous with both hyperechogenic and cystic (hypoechogenic) parenchima		
(5) Post-operative intratesticular lesion		
– Calcifications/Microcalcifications,	– TM and testicular cancer (debated) (Richenberg and Brejt, 2012; Appelbaum <i>et al.</i> , 2013)	– Microcalcifications: 1–3 mm
– Testicular microlithiasis (TM)	– TM and male infertility (Yee <i>et al.</i> , 2011)	– TM, ≥ 5 /US scan (Richenberg and Brejt, 2012)
Epididymis		
Hypoechogenicity	– Acute/subacute inflammation (Woodward <i>et al.</i> , 2003; Isidori and Lenzi, 2008)	Not reported
Hyperaemia	– MAGI, elevated sIL8 (Vicari, 1999; Lotti <i>et al.</i> , 2011a; Lotti and Maggi, 2013)	
Hyperechogenicity	– Chronic inflammation (Woodward <i>et al.</i> , 2003; Isidori and Lenzi, 2008)	
Coarse calcifications	– MAGI, elevated sIL8 (Vicari, 1999; Lotti <i>et al.</i> , 2011a; Lotti and Maggi, 2013)	
Prostate		
Glandular asymmetry	– MAGI (Christiansen and Purvis, 1991; Vicari, 1999), – Fibro-sclerotic MAGI (La Vignera <i>et al.</i> , 2011e)	Not reported; proposed 5 mm
Nonhomogeneity	– MAGI, CP/PPS (Di Trapani <i>et al.</i> , 1988; Christiansen and Purvis, 1991; Behre <i>et al.</i> , 1995; Vicari, 1999) – Elevated sIL8 (Lotti <i>et al.</i> , 2011a; Lotti and Maggi, 2013) – Overweight/obesity (Lotti <i>et al.</i> , 2011b) and MetS (Lotti <i>et al.</i> , 2014a) – PLS (Lotti <i>et al.</i> , 2014b)	Abnormal pattern: grade 1–3: 1, mild; 2, moderate; 3, severe inhomogeneity (Lotti <i>et al.</i> , 2011b, 2014b)

Continued

Table II *Continued*

CDUS echo-pattern abnormalities	Associations	Cutoff
Hypoechoogenicity	<ul style="list-style-type: none"> – Oedema, acute/subacute inflammation (Doble and Carter, 1989; Purvis and Christiansen, 1993), hypertrophic-congestive MAGI (Vicari, 1999; La Vignera <i>et al.</i>, 2011e) – Elevated sIL8 (Lotti <i>et al.</i>, 2011a; Lotti and Maggi, 2013) – PLS (Lotti <i>et al.</i>, 2014b) 	Not reported
Hyperechoogenicity	<ul style="list-style-type: none"> – MAGI, CP/CPPS (Doble and Carter, 1989; Vicari, 1999) – Fibro-sclerotic MAGI (La Vignera, 2011e) 	Not reported
Calcifications	<ul style="list-style-type: none"> – MAGI, CP/CPPS (Doble and Carter, 1989; Purvis and Christiansen, 1993; Vicari, 1999) – Elevated sIL8 (Lotti <i>et al.</i>, 2011a; Lotti and Maggi, 2013) – Overweight/obesity (Lotti <i>et al.</i>, 2012b) and MetS (Lotti <i>et al.</i>, 2014a) – PLS (Lotti <i>et al.</i>, 2014b) – Maintenance of CP, bacterial colonization (Meares, 1974; Shoskes <i>et al.</i>, 2007) – Corpora amylacea (Sfanos <i>et al.</i>, 2009) 	Macro-calcifications: >3 mm (Isidori and Lenzi, 2008)
Hyperemia	<ul style="list-style-type: none"> – Tissue inflammation and clinical activity (Cho <i>et al.</i>, 2000) 	<p>≥ 15 Doppler spots (Cho <i>et al.</i>, 2000)</p> <ul style="list-style-type: none"> – measure before ejaculation to avoid post-ejaculatory vascular flow changes (Keener <i>et al.</i>, 2000)
Arterial prostatic peak systolic velocity	<ul style="list-style-type: none"> – Tissue inflammation and clinical activity (Lotti <i>et al.</i>, 2011a, 2012c, 2014b; Lotti and Maggi, 2013) and PLS (Lotti <i>et al.</i>, 2014b) 	<ul style="list-style-type: none"> – Moderate-severe PLS in young men: 11 cm/s (Lotti <i>et al.</i>, 2014b) – BPH: > 15 cm/s (Berger <i>et al.</i>, 2006)
Resistive index	BPH and LUTS (Berger <i>et al.</i> , 2006; Shinbo <i>et al.</i> , 2010)	Not reported (proposed > 0.725, see Berger <i>et al.</i> , 2006)
Dilation of the prostatic venous plexus	<ul style="list-style-type: none"> – MAGI and CP/CPPS (Di Trapani <i>et al.</i>, 1988; Vicari, 1999; Lotti <i>et al.</i>, 2009) – Varicocele (Lotti <i>et al.</i>, 2009) 	<p>Not well defined/not replicable</p> <ul style="list-style-type: none"> – > 150 mm² (Di Trapani <i>et al.</i>, 1988) – diameter >3 mm (Kamoi, 1996) or >4 mm (La Vignera <i>et al.</i>, 2011e)
Ejaculatory ducts (ED)		
Dilation	<ul style="list-style-type: none"> – ED partial or complete obstruction (Engin <i>et al.</i>, 2000; Fisch <i>et al.</i>, 2002; Lotti <i>et al.</i>, 2012a) 	>2 mm (see Fisch <i>et al.</i> (2002))
Cysts	<ul style="list-style-type: none"> – ED partial or complete obstruction (Engin <i>et al.</i>, 2000; Fisch <i>et al.</i>, 2002; Lotti <i>et al.</i>, 2012a) 	Not reported
Calcifications	<ul style="list-style-type: none"> – ED partial or complete obstruction (Engin <i>et al.</i>, 2000; Fisch <i>et al.</i>, 2002; Lotti <i>et al.</i>, 2012a) – Hemospermia (Litttrup <i>et al.</i>, 1988) and PLS (Lotti <i>et al.</i>, 2014b). 	Not reported
Seminal vesicles		
Enlargement	<ul style="list-style-type: none"> – MAGI (Vicari, 1999; La Vignera <i>et al.</i>, 2008) – Partial ejaculatory duct obstruction (Lotti <i>et al.</i>, 2012a) 	<p>Not well defined. Proposed:</p> <ul style="list-style-type: none"> – APD > 14–15 mm (Jarow, 1993; Vicari, 1999) – Total volume ejaculation >7 ml (extrapolated from Lotti <i>et al.</i>, 2012a)
Reduction	<ul style="list-style-type: none"> – Congenitally small SV (Kim <i>et al.</i>, 2009) – MAGI/fibrosis (Vicari, 1999) – T deficiency (Sasagawa <i>et al.</i>, 1989, 1990) 	<p>Not well defined. Proposed:</p> <ul style="list-style-type: none"> – APD < 7 mm (Vicari, 1999) – LD < 25 mm (Donkol, 2010)

Asymmetry	–	MAGI (Vicari, 1999; La Vignera et al., 2008)	Not reported
	–	MAGI (Kim and Lipshultz, 1996; Vicari, 1999; Kim et al., 2009)	Not reported
	–	Diabetes mellitus (La Vignera et al., 2009; 2011b, c, d)	Persisting after ejaculation (Lotti et al., 2012a)
	–	Emptying impairment (Lotti et al., 2012a)	
Abnormal fundus/body ratio	–	MAGI: low or high; diabetes mellitus: high (La Vignera et al. 2011b)	Low < 1; high > 2.5 (La Vignera et al., 2011b)
	–	MAGI (Vicari, 1999; Lotti et al., 2011a)	Not reported
Calcifications	–	Hemospermia and ejaculatory pain (Littrup et al., 1988; Zhao et al., 2012).	
Areas of endocapsulation	–	MAGI (Colpi et al., 1997; Vicari, 1999; La Vignera et al., 2008; Lotti et al., 2011a)	Not reported
	–	Emptying impairment (Colpi et al., 1997; Lotti et al., 2012a)	Prevalence reduction after ejaculation (Lotti et al., 2012a)
	–	PLS (Lotti et al., 2014b)	
Inhomogeneity	–	Higher PRL (in the normal range) (Lotti et al., 2013a)	Not reported

Regarding male reproductive health, testis inhomogeneity is related to impaired sperm parameters (Lenz et al., 1993; Loberant et al., 2010). Epididymis, prostate, and SV echo-texture abnormalities have been suggested to be related to inflammation, which possible negative impact on semen quality/quantity is debated (La Vignera et al., 2011a; Ruzs et al., 2012). Ejaculatory ducts abnormalities may be associated with distal obstruction and painful ejaculation (Singh et al., 2012). TM, testicular microlithiasis; MAGI, male accessory gland infection; sIL-8, seminal interleukin 8, a surrogate marker of prostate and overall MGT inflammation (Penna et al., 2007; Lotti and Maggi, 2013); CP/CPPS, chronic prostatitis/chronic pelvic pain syndrome; PLS, prostatitis-like symptoms, defined as 'perineal and/or ejaculatory pain or discomfort and a National Institutes of Health-Chronic Prostatitis Symptom Index pain subdomain score ≥ 4 ' (Nickel et al., 2001); MetS, metabolic syndrome; BPH, benign prostatic hyperplasia; LUTS, lower urinary tract symptoms; PRL, prolactin; SV, seminal vesicle.

longitudinal scans crossing the prostate up to the urethra (Kim and Lipshultz, 1996; Raza and Jhaveri, 2012) (Fig. 3J).

Color-Doppler ultrasound in pathological conditions

Testis

Volume

A reduced TV (Fig. 1) at PO is related to poor sperm parameters, including low total sperm count (Handelsman et al., 1984; Bujan et al., 1989; Arai et al., 1998; Jørgensen et al., 2002; Sakamoto et al., 2008), poor sperm motility (Bujan et al., 1989; Arai et al., 1998; Sakamoto et al., 2008) and low levels of normal sperm morphology (Jørgensen et al., 2002). In addition, a reduced TV is associated with hormonal abnormalities, including low testosterone and increased luteinizing hormone (LH) and follicle-stimulating hormone (FSH) levels (Sakamoto et al., 2008; Rastrelli et al., 2013). Finally, TV correlates with fatherhood (Fisher et al., 2012).

As for clinically assessed TV, US-estimated TV is positively related to total sperm count (Lenz et al., 1993, 1994; Sakamoto et al., 2008; Cooper, 2010), sperm motility (Sakamoto et al., 2008), normal sperm morphology (Lenz et al., 1993) and testosterone levels, and negatively to LH and FSH (Sakamoto et al., 2008; Sakamoto and Ogawa, 2009). A negative correlation between US-TV and nonconventional sperm parameters has been also reported (Lotti et al., 2012d; Condorelli et al., 2013).

Abnormally enlarged testes are termed 'macroorchidism' or 'megalo-testes' (Lachiewicz and Dawson, 1994; Meschede et al., 1995). A clear cutoff indicative of enlarged TV in children or adults has not been reported, either at PO or US. Only some authors have defined macroorchidism as a TV greater than the 95th percentile of the standard testicular curves (Lachiewicz and Dawson, 1994). A PO-derived TV ≥ 4 ml has been proposed as indicative of macroorchidism in infants and children up to 8 years old (see Lachiewicz and Dawson (1994)), whereas a TV $> 25-30$ ml has been suggested in adults (Nielsen et al., 1982; Meschede et al., 1995). Available studies have been mainly performed on subjects with fragile X syndrome or mentally retarded males, but there are limited reports also describing macroorchidism in men with different diseases (see Lachiewicz and Dawson (1994)). Slightly enlarged TV may, however, be a normal variant in adult men (Nielsen et al., 1982). In addition, any definition of 'pathologically' large testes should refer to the ethnic group, age and anthropometric parameters considered (Nielsen et al., 1982). Interestingly, a limited number of studies have reported that enlarged testes show normal gonadal function (Cantu et al., 1976; Berkovitz et al. 1986; Meschede et al., 1995).

Echo-pattern abnormalities

Testicular inhomogeneity (TI) (Figs 1 and 4A and B) was originally studied and classified by Lenz et al. (1993) and Westlander et al. (2001) (Table II). It has been associated with testicular function impairment (Lenz et al., 1993; Behre et al., 1995), abnormal sperm morphology (Lenz et al., 1993; Lotti et al., 2013b) and a history of cryptorchidism (Lenz et al., 1993). TI increases as a factor of age (Lenz et al., 1993), although it is also suggestive of atrophy and fibrosis (Loberant et al., 2010). In fact, whereas TI is often observed in the elderly and considered normal, in young subjects it is

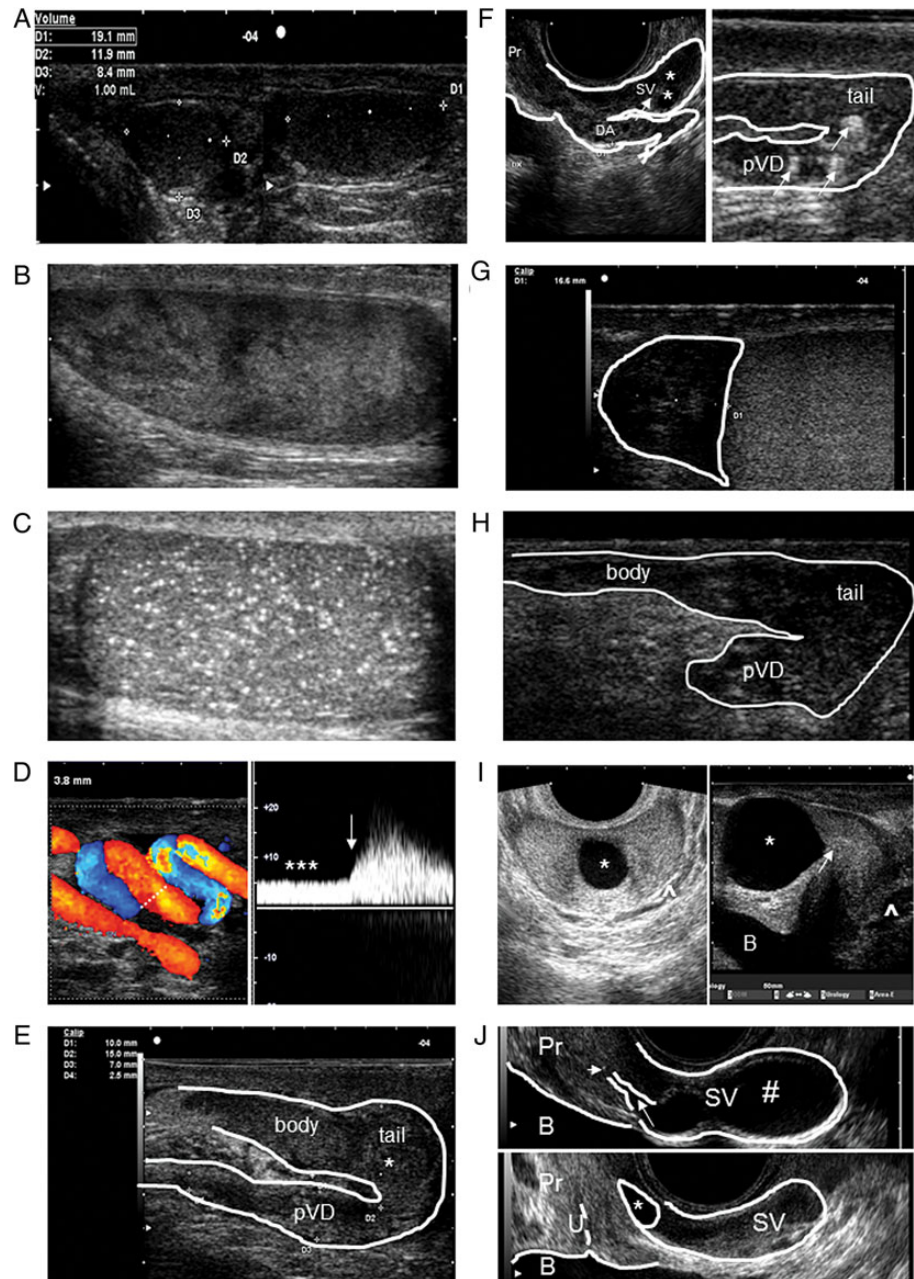


Figure 4 Abnormal color-Doppler ultrasound (CDUS) features of the organs of the male genital tract. **(A)** Testis with echo-texture inhomogeneity in a sagittal scan. **(B)** Testicular microlithiasis with 'starry sky' appearance. **(C)** Testis with low volume, inhomogeneous and hypoechoic echo-texture, detected in a man with a history of cryptorchidism. **(D)** CDUS evaluation of dilated veins of the pampiniform plexus with a colored signal (left), showing continuous reflux at rest (***), increasing with Valsalva (arrow), identifying a severe, sonographic-defined, varicocele, according to different classifications (see Table III). **(E)** dilated and inhomogeneous epididymal body and tail and proximal vas deferens (pVD), with an irregularly shaped mass (*) in the epididymal tail region, detected in a sagittal scan. **(F)** Left figure: dilated, inhomogeneous deferential ampulla (DA) beside a section of a seminal vesicle (SV) with areas of endo-capsulation (*) and thick septa (arrow) detected by 'end fire' probe in a sagittal scan. Right figure: dilated, inhomogeneous epididymal tail and proximal vas deferens (pVD), with coarse calcifications (arrow). **(G)** Dilated (> 12 mm), inhomogeneous, hypoechoic epididymal head. **(H)** Abrupt interruption of the proximal vas deferens (pVD) in a man with congenital bilateral absence of vas deferens. The epididymal body and tail are also visualized in a sagittal scan. **(I)** Midline prostatic cyst (*) in transversal (left) and sagittal (right) scans. The prostatic utricle is indicated with an arrow. The periprostatic venous plexus (^) are also visible. **(J)** Upper figure, ejaculatory duct dilation (arrow) and microcalcification (short arrow), and seminal vesicle cyst (#), assessed by 'end fire' probe in a sagittal scan. Lower figure, ejaculatory duct cyst (*). SV, seminal vesicle; Pr, prostate; U, urethra; B, bladder.

associated with several pathological conditions (see Table II). Seminiferous tubules reduction and interstitial proliferation produce an exaggeration of the normally-unapparent septa, resulting at US in a striated appearance (Loberant *et al.*, 2010) (Fig. 4B).

In our opinion, the association between TI and testis malignancy (see below and Table I) is clinically relevant for male reproductive and general health. In particular, TI was associated with a high risk of carcinoma *in situ* of the testis in subjects with a history of cryptorchidism (Lenz *et al.*, 1987; Lenz, 1991) or with testicular microlithiasis (Elzinga-Tinke *et al.*, 2010). However, at present, a diagnostic testicular biopsy is not recommended when TI is detected. We suggest US follow-up if severe TI is found, especially if additional risk factors for testicular malignancy (see below) are present. In addition, while focal TI lesions may suggest a neoplasm, particularly in young men, diffuse TI may be related to massive tumors or lymphoma, the latter occurring later in life (50–70 years), and usually associated with palpatory hardness and enhanced vascularization (Woodward *et al.*, 2002; Isidori and Lenzi, 2008).

Vascularization

Testis vascularization plays a critical role in the differential diagnosis among testicular torsion (absent), infarction (absent or peripheral), epididymo-orchitis or some malignant conditions (i.e. leukemia, lymphoma) (enhanced), when considered along with other clinical features (Isidori and Lenzi, 2008) (see Table I). This is relevant, because these conditions may even lead to a definitive impaired testicular function (Tekgül *et al.*, 2008; Grabe *et al.*, 2013; Jungwirth *et al.*, 2013; Sharp *et al.*, 2013). In addition, an adequate knowledge of testicular arterial supply (see above and Fig. 2) is mandatory when testis surgery is performed. In fact, centripetal arteries (Fig. 2) are end-arteries. Any injury occurring to these vessels during testicular surgery may devascularize an area of the testis, both by testicular sperm extraction (Schlegel and Li-Ming, 1997; Ron-El *et al.*, 1998) and, rarely, with percutaneous fine needle sperm aspiration (Friedler *et al.*, 1997). Testicular open or percutaneous biopsy may also lead to intratesticular or extratunical hematoma formation (Schlegel and Li-Ming, 1997; Friedler *et al.*, 1997) and to inflammatory changes with disruption of the spermatogenesis (Schlegel and Li-Ming, 1997).

Interestingly, testis-related vascular parameters also represent a new frontier of research in fertility assessment, however with no actual clinical impact (see below).

Testicular findings/lesions

Several abnormal CDUS testicular findings may be related to, or exert a negative impact on, male reproductive health (see Tables I and II).

Calcifications. Calcifications are calcium deposits in the seminiferous tubules (Richenberg and Brejt, 2012). Solitary parenchymal calcifications may be due to a prior trauma, orchitis, infarction, torsion, chemo/radiotherapy, or may be associated with testicular atrophy, maldescended testis, or, rarely, a burnt-out tumor (Mihmanli and Kantarci, 2009; Raza and Jhaveri, 2012; Appelbaum *et al.*, 2013).

Microcalcifications are small (1–3 mm) bright echogenic foci with no acoustic shadowing. Testicular microlithiasis (TM) (Fig. 1) is defined as the presence of ≥ 5 microcalcifications in a single US scan (Raza and Jhaveri, 2012; Richenberg and Brejt, 2012; Appelbaum *et al.*, 2013). They can be limited, 'clusters' or diffuse ('starry sky' appearance; Fig. 4C) (Mihmanli and Kantarci, 2009; Elzinga-Tinke *et al.*, 2010). TM

prevalence ranges from 0.6 to 9% (see Richenberg and Brejt (2012)). However, in a study considering also <5 microcalcifications in a US scan as TM (Elzinga-Tinke *et al.*, 2010), a higher prevalence of TM was reported (43%). In that study, the authors reported detection of carcinoma *in situ* in one out of four patients with TM, particularly when testicular inhomogeneity was present, or when 'clusters' of TM were found (Elzinga-Tinke *et al.*, 2010). Although most of the previous studies have reported an association between TM and testicular malignancy, recent literature raises doubts about this association (see Appelbaum *et al.* (2013)), and a meta-analysis suggested no causal link between TM and testicular cancer (Richenberg and Brejt, 2012). Hence, this issue and its clinical impact is still debated (Table I). According to the European Academy of Urology (EAU) guidelines (Albers *et al.*, 2013), US follow-up of TM is recommended in subjects with additional risk factors for testicular malignancy (see below). Solely, the presence of TM is not considered an indication for regular scrotal US follow-up or biopsy (Albers *et al.*, 2013). Conversely, testicular biopsy should be offered to men with TM who belong to high-risk groups (infertility and bilateral TM, atrophic testes, undescended testes, a history of testicular tumors, or contralateral TM) (Jungwirth *et al.*, 2013).

A TM association with infertility is debated (Aizenstein *et al.*, 1998; Miller and Sidhu, 2002; Yee *et al.*, 2011). In infertile men, asymptomatic TM is not considered a risk factor for the production of antisperm antibodies (Clyne, 2012; Jiang and Zhu, 2013). Recent evidence supports TM as an additional feature of the 'testicular dysgenesis syndrome' (see below and Fig. 1) and there is evidence of a genetic background for TM (Tan and Eng, 2011). At the present time, the impact of TM in the management of male infertility is low (Table I).

Orchitis. The majority of orchitis originate with a previous epididymitis, later on extending to the testis (44–47% of cases) (Horstman *et al.*, 1991b; Pilatz *et al.*, 2013b). In this case, the etiology is mainly bacterial. Conversely, primary orchitis is mainly viral (mumps orchitis), occurring in 20–30% of infected postpubertal men (Grabe *et al.*, 2013). Orchitis usually presents with a painful hemiscrotum and testis enlargement (Grabe *et al.*, 2013). CDUS plays a key role in identifying a diagnostic feature, enhanced testis vascularization (see Table I), along with diffuse enlargement, inhomogeneous, mainly hypoechoic, testicular echo-texture and reactive hydrocele (see in Dogra *et al.* (2003), Isidori and Lenzi (2008), Ammar *et al.* (2012) and Pilatz *et al.* (2013b)). Post-orchitis testis may present with inhomogeneous echo-texture, mainly hypo- or hyper-echoic, with normal or reduced vascularization and micro- or macro-calcifications (Isidori and Lenzi, 2008; Ammar *et al.*, 2012). Although it has been reported that, in the case of testicular involvement, chronic inflammation may result in testicular atrophy (see Grabe *et al.* (2013)), a recent study suggests that, under conservative treatment, no testicular atrophy occurs after acute epididymo-orchitis (Pilatz *et al.*, 2013b). However, orchitis is often associated with sperm abnormalities (Isidori and Lenzi, 2008; Ammar *et al.*, 2012).

Testicular lesions. Testicular lesions (Fig. 1) can be detected by US occasionally, especially during evaluation for infertility, or when the patient complains of a vague discomfort in the scrotum, lump or painless swelling of the testis, dull or heavy pain, the latter being reported by 10–20% of subjects with testicular cancer (Isidori and Lenzi, 2008). Differential diagnosis is difficult, particularly when testis echo-texture is inhomogeneous. Testicular lesions may be small (millimetric) or large. Small hypoechoic

areas, often not vascularized, are possibly related to spermatocetes, cysts, focal Leydig cell hyperplasia, fibrosis and focal inhomogeneity due to previous pathologic conditions (Isidori and Lenzi, 2008). However, they may also indicate small tumors (Isidori and Lenzi, 2008). Hence, they require careful evaluation and follow-up, with periodic US examination (see Table I), especially if additional risk factors for malignancy are present (i.e. infertility, bilateral TM, cryptorchidism, testicular atrophy, inhomogeneous parenchyma, history of testicular tumor, contralateral tumor and age <50 years; van Casteren *et al.*, 2009; Elzinga-Tinke *et al.*, 2010; Albers *et al.*, 2013; Jungwirth *et al.*, 2013). In the case of the growth of the small nodule (Dohle *et al.*, 2012), or of the presence of additional risk factors for malignancy, testicular biopsy/surgery should be considered (Jungwirth *et al.*, 2013). Large nodules, with or without internal vascularization, may be observed by US and may be either benign or malign. Most of them cannot be defined in origin by US, and histology remains the only certain diagnostic tool (Woodward *et al.*, 2002). However, new imaging techniques, such as contrast-enhanced ultrasound (CEUS) and tissue elastography, have improved the characterization of testicular lesions (Huang and Sidhu, 2012). Clinical and CDUS patterns of testicular lesions have been described in detail elsewhere (Woodward *et al.*, 2002; Isidori and Lenzi, 2008). According to the EAU guidelines (Albers *et al.*, 2013), scrotal US serves to confirm the presence of a testicular mass, and to explore the contralateral testis. Its sensitivity in detecting a testicular mass is almost 100% (Kim *et al.*, 2007). US plays an important role in determining whether a mass is intra- or extra-testicular (Kim *et al.*, 2007), its characteristics, and its differential diagnosis among different clinical conditions (i.e. malignancy, inflammation, cysts) (Woodward *et al.*, 2002; Montgomery and David, 2011). US should be performed even in the presence of a testicular tumor that is clinically evident (Shaw, 2008; Albers *et al.*, 2013). According to the EAU guidelines (Albers *et al.*, 2013), every patient with a suspected testicular mass must undergo surgical exploration, with orchiectomy if a malignant tumor is found, or testicular biopsy with histological examination if the diagnosis is not clear. In our opinion, US is useful in the detection and follow-up of small lesions or of the aforementioned risk factors for malignancy, playing an adjuvant role in the management of large/hard lesions (Table I).

Testicular malignancy accounts for 4–6% of all MGT tumors and 1–2% of the male neoplasms and represents the most common malignancy in young men (15–34 years, Woodward *et al.*, 2002). Testicular cancer occurs more frequently with other testicular disorders, such as defective spermatogenesis, male infertility, or cryptorchidism. Various mechanisms may contribute to semen impairment in testicular cancer, such as tumor size and general cancer effects, tumor histological features, disease stage, previous testicular disorders, and orchiectomy (Rives *et al.*, 2012; Trost and Brannigan, 2012). Among samples of oligospermic men cryopreserved for cancer, those from testicular cancer patients show the lowest basal semen quality and the worst recovery after thawing (Degl'Innocenti *et al.*, 2013; Hotaling *et al.*, 2013). With other types of cancers, some studies report motility recovery similar to that of non-cancer-related samples (see Degl'Innocenti *et al.* (2013)). Combined information on sperm concentration, age and contralateral TV may predict the risk of contralateral carcinoma *in situ* in patients with a unilateral testicular germ cell tumor (Rud *et al.*, 2013).

Cryptorchidism. Cryptorchidism is a condition associated with an abnormal testis development and/or a failure of its descent into the scrotum. It

is the most common abnormality in newborn males, affecting 1–6% of full-term neonates and ~0.8% of infants at 1 year of age, with a higher overall incidence for preterm infants (see Christensen and Dogra (2007)). Although most commonly unilateral, it is bilateral in ~10% of patients. Cryptorchidism is associated with an increased risk of infertility and testicular malignancy (Fig. 1). Furthermore, it is often associated with other urinary tract abnormalities, including renal agenesis or ectopias, ureteral duplication, SV agenesis or cysts, and hypospadias (see Christensen and Dogra (2007)). Given the spectrum of associated abnormalities, cryptorchidism is thought to be one manifestation of a primitive generalized defect in genitourinary embryogenesis. In addition, a common origin has been advocated for spermatogenesis impairment, cryptorchidism and testicular germ cell tumors ('testicular dysgenesis syndrome'; Skakkebaek and Jorgensen, 2005). As ~80% of cryptorchid testes are located within the inguinal canal, and 5–16% are intra-abdominal, also a secondary degeneration of the cryptorchid testes has been traditionally advocated, mainly related to increased temperature compared with the scrotal environment. Regarding infertility, germ cell failure seems not to be congenital, but rather acquired, beginning at ~4 months of age and progressively decreasing thereafter, with gonadal atrophy clinically detectable by age 5. Hence, early surgical correction has been advocated to prevent infertility (see Christensen and Dogra (2007)). The risk of a testicular tumor is increased by 3–5%, resulting in a 4–7-fold higher risk than in the healthy population, with higher figures for bilateral undescended testes. Approximately 20% of tumors occur in the contralateral descended testis (see Christensen and Dogra (2007)). Finally, the incidence of testicular torsion is believed to be higher in patients with undescended testes (Schultz and Walker, 1984).

At US, the cryptorchid testis is often hypotrophic, inhomogeneous and hypoechoic (Fig. 4A), with or without macro- or micro-calcifications (Christensen and Dogra, 2007; Ozden *et al.*, 2012). The role of US in the setting of cryptorchidism and preoperative planning before orchiopexy is controversial (Christensen and Dogra, 2007; Ozden *et al.*, 2012). A recent systematic review and meta-analysis reported that US does not reliably localize nonpalpable testes or rule out an intra-abdominal testis (Tasian and Copp, 2011). Hence, performing US does not change the clinical management of nonpalpable testes. However, US can reliably identify a cryptorchid testis lying below the level of the internal inguinal ring (Nijs *et al.*, 2007).

In conclusion, US plays a key role in cancer detection or in the follow-up of the cryptorchid and contralateral testes (see Table I).

Varicocele

Varicocele is an abnormal dilatation of the pampiniform plexus (Figs 1 and 4D), characterized by retrograde venous flow (Forti and Krausz, 1998; Forti *et al.*, 2003; Zini and Bowman, 2009). According to the aforementioned anatomical considerations (see above), varicocele is mainly (90%) detected on the left side (Fig. 1) (Sakamoto and Ogawa, 2008; Zini and Bowman, 2009). The prevalence of varicocele, virtually absent in boys aged <11 years, and increases with age, up to ~15% in the general adult population (Forti *et al.*, 2003; Canales *et al.*, 2005; Cayan and Woodhouse, 2007). Varicocele is clinically classified into three grades: I, palpated during Valsalva maneuver; II, palpated without Valsalva maneuver; and III, visible (Dubin and Amelar, 1970). While clinically assessed grade III varicoceles are easily diagnosed, detection of milder forms depends on the investigator's experience. In fact, palpation may be

disturbed by cremasteric contraction, previous surgery, hydroceles or maldescended testis (see [Liguori et al. \(2012\)](#)). Pathophysiologic mechanisms leading to varicocele formation and its clinical associations have been extensively described elsewhere (see [Gat et al. \(2008\)](#) and [Sakamoto and Ogawa \(2008\)](#)).

Venography of the internal spermatic vein is considered the gold-standard for varicocele detection (see [Geatti et al. \(1991\)](#), [Lee et al. \(2008\)](#) and [Liguori et al. \(2012\)](#)). Its strength is the low susceptibility to technical variation and inter-observer variability (see [Lee et al. \(2008\)](#)). However, venography is time-consuming, invasive and requires use of radiation (see [Liguori et al. \(2012\)](#)). Hence, even if it is the most accurate technique for varicocele detection and often used for comparison with all the other diagnostic approaches in research studies, venography is currently indicated in clinical practice only in select cases (see [Liguori et al. \(2012\)](#)). At present, the American Urology Association/American Society for Reproductive Medicine [American Urological Association/American Society for Reproductive Medicine (AUA/ASRM) see [Practice Committee of American Society for Reproductive Medicine, 2008](#)] and the EAU Guidelines on Male Infertility ([Jungwirth et al., 2013](#)) suggest making the diagnosis of varicocele by clinical examination, because 'only palpable varicocele have been documented as being associated with infertility' (AUA/ASRM, 2008). However, the diagnosis should be confirmed by CDUS (EAU Guidelines on Male Infertility, [Jungwirth et al., 2013](#)), especially when physical examination is inconclusive (AUA/ASRM, 2008). In particular, CDUS has been found to have better diagnostic accuracy than physical examination (see [Lee et al. \(2008\)](#)), and it is essential when physical examination is unreliable ([Liguori et al., 2012](#)) and considered the imaging modality of choice for detection and grading varicocele ([Liguori et al., 2012](#)), offering a more complete stratification of lower grades ([Isidori and Lenzi, 2008](#)). In addition, CDUS may identify those cases with markedly dilated vessels but without venous reflux, considered as 'false' clinical varicocele ([Isidori and Lenzi, 2008](#)), and is useful in detecting post-operative recurrence or persistence ([Lund et al., 2000](#); [Tefekli et al., 2001](#); [Isidori and Lenzi, 2008](#)). Compared with venography, physical examination has a 50–70% sensitivity in varicocele detection, while CDUS has a 93% sensitivity (see [Lee et al. \(2008\)](#) and [Zini and Bowman \(2009\)](#)). Hence, CDUS has become the most widely accepted, as well as most frequently used, modality for evaluating varicocele (see [Lee et al. \(2008\)](#)). In our opinion, although physical examination remains the cornerstone of varicocele management, CDUS has a higher diagnostic accuracy (Table I).

At CDUS, varicocele should be assessed with the patient in both the recumbent and upright position. A palpable varicocele feels like a 'bag of worms' and is significantly reduced when the patient is recumbent. When a suspected varicocele is not clearly palpable, it should be examined while the patient performs a Valsalva maneuver in a standing position (AUA/ASRM, 2008). Some authors suggest evaluating the internal spermatic vein between the upper pole of the testis and the inguinal ligament, in order to assess a straight vein instead of the convoluted vessels below ([Orda et al., 1987](#)). The size and location of the varices, their number, basal intermittent or continuous reflux at CDUS and changes during Valsalva maneuver should be taken into consideration.

The US grey-scale appearance of varicocele consists of multiple (>3), hypoechoic, serpiginous tubular structures of varying size, >2–3 mm, visualized superior and/or lateral to the testis, and, when large, extending posteriorly and inferiorly ([Dogra et al., 2003](#); [Isidori and Lenzi, 2008](#); [Lee](#)

[et al., 2008](#); [Raheem, 2013](#)). Many CDUS classifications of varicocele severity are available (Table III). In most of them severe, sonographic-defined, varicocele is characterized by a continuous venous reflux at rest, increasing or not during a Valsalva maneuver (Fig. 4D).

The vast majority of studies report reduced mean or ipsilateral TV in subjects with varicocele, along with normal or slightly increased LH and FSH levels ([Zini and Bowman, 2009](#); [Raheem, 2013](#)). Conversely, the effect of varicocele on testosterone levels is more debatable ([Tanrikut et al., 2011](#)). A recent meta-analysis showed that surgical treatment significantly increases testosterone production ([Li et al., 2012](#)). Most studies, but not all, report worse sperm parameters in subjects with varicocele. However, these studies have been conducted in infertile populations, whereas data in fertile subjects are contrasting. In addition, 75% of subjects with varicocele have normal semen parameters (see [Zini and Bowman \(2009\)](#)). Most studies reported no difference in paternity comparing men with or without varicocele (see [Zini and Bowman \(2009\)](#)). The possibility of reverting infertility through varicocele treatment is under debate. According to the AUA/ASRM (2008), 'when the male partner of a couple attempting to conceive has a varicocele, its treatment should be considered when all of the following conditions are met: (i) varicocele is palpable on physical examination of the scrotum; (ii) the couple has known infertility; (iii) the female partner has normal fertility or a potentially treatable cause of infertility; (iv) the male partner has abnormal semen parameters or abnormal results from sperm function tests. Varicocele treatment for infertility is not indicated in patients with either normal semen quality or a subclinical varicocele'. A recent meta-analysis reported that varicolectomy improves sperm parameters (count, total and progressive motility), reduces sperm DNA damage and seminal oxidative stress, and improves sperm ultra-morphology ([Baazeem et al., 2011](#)). Although there is no conclusive evidence that varicocele repair improves spontaneous pregnancy rates, a recent updated Cochrane review concluded that surgical or radiological treatment in subfertile men, with a clinically manifest varicocele and poor semen quality, may be of benefit, reporting one additional pregnancy for every seven men treated ([Kroese et al., 2013](#)). In addition, some men with scrotal pain, low testosterone, non-obstructive azoospermia, or at risk for testicular dysfunction may benefit from varicolectomy ([Schlegel and Goldstein, 2011](#)).

Regarding subclinical varicocele, defined as venous reflux detected by CDUS but not clinically evident, a recent Cochrane review considers its treatment disputable, the number needed to treat to benefit being 17 ([Kroese et al., 2012](#)). In addition, varicocele treatment may be associated with complications, such as hydrocele, inadvertent arterial ligation, testicular atrophy, vas deference occlusion and epididymitis ([Isidori and Lenzi, 2008](#); [Iaccarino and Venetucci, 2012](#)), making the decision to treat subclinical varicocele even more disputed. However, treatment of subclinical varicocele with grade 3 reflux according to [Cornud et al. \(1999\)](#), defined as permanent reflux, regardless of the size of the veins, resulted in changes similar to those seen after repair of palpable varicocele ([Cornud et al., 1999](#); [Lee et al., 2008](#)). In addition, grade 3 reflux according to [Cornud et al. \(1999\)](#) was found to be palpable in 60% of cases ([Cornud et al., 1999](#); [Lee et al., 2008](#)). Hence, detection of 'permanent reflux' by CDUS (see Table III) could be an indication for treating varicocele when physical examination is negative. However, to date, this is not evidence-based.

Finally, varicocele has also been suggested as a potential cause of intra-pelvic venous congestion, prostate inflammation and, eventually,

Table III Proposed classification of varicocele according to clinical and increasing sonographic severity, by different authors.

First author of classification	Varicocele clinical grade				
Dubin and Amelar (1970)	[1] Detectable only during Valsalva		[2] Palpable		[3] visible
	Varicocele CDUS grade				
Hirsh <i>et al.</i> (1980)	[1] No spontaneous reflux, inducible with Valsalva	[2] Intermittent spontaneous reflux		[3] Continuous spontaneous reflux	
Dhabuwala <i>et al.</i> (1989)	[1] Reflux <2 s	[2] Reflux >2 s		[3] Spontaneous reflux increasing with Valsalva	
Sarteschi <i>et al.</i> (1993) and Liguori <i>et al.</i> (2004)	[1] Inguinal reflux only during Valsalva in not enlarged vessels	[2] Supra-testicular reflux only during Valsalva in small posterior varicosities	[3] Peri-testicular reflux only during Valsalva in enlarged vessels. Visible but not dilated vessels when supine, enlarged when standing.	[4] Enlarged vessels in supine and standing position, with increasing caliber with Valsalva. Reflux at rest, increasing during Valsalva. Common testicular hypotrophy.	[5] Enlarged vessels in supine and standing position, with caliber not increasing with Valsalva. Reflux at rest, not increasing during Valsalva. Intratesticular varices and/or testicular hypotrophy.
Hoekstra and Witt (1995)	[1] Dilated veins <2.5 mm without flow reversal after Valsalva	[2] Dilated veins 2.5–3.5 mm and flow reversal after Valsalva		[3] Dilated veins >3.5 mm and flow reversal after Valsalva	
Cornud <i>et al.</i> (1999)	[1] Brief reflux: <1 s [2] Intermediate reflux <2 s, decreasing during and stopping prior to the end of Valsalva			[3] Permanent reflux: >2 s and with a plateau aspect throughout the abdominal strain.	
Oyen (2002) <i>B-mode Reflux-Doppler</i>	[1] Slight reflux (<2 s) during Valsalva	[2] Reflux (>2 s) during Valsalva, not continuous		Diameter of the veins > 3 mm increasing during Valsalva and/or in the upright position [3] Reflux at rest or during the entire Valsalva	
Isidori and Lenzi (2008) <i>B-mode</i>	[1] Dilated vessels (>2.5 mm) in inguinal region	[2] Supra-testicular vessel dilation (> 3 mm)	[3] Supra- and peri-testicular vessel dilation (>3 mm)	Supra[2]- and peri [3]-testicular vessel dilation, [4] increasing with Valsalva. Testicular hypotrophy.	[5] Peri-testicular vessel dilation not increasing with Valsalva, or intratesticular vessels and testicular hypotrophy
<i>Reflux Doppler</i>	[1] Inguinal reflux only during Valsalva (2–3 s)	[2] Supra-testicular reflux only during Valsalva (>3 s)		Peri-testicular reflux at rest increasing [3] or not [4] during Valsalva	[5] Peritesticular reflux at rest which increases minimally with Valsalva or dilated intratesticular veins which refill with Valsalva
Pauroso <i>et al.</i> (2011)	[1] Reflux in the inguinal channel only during Valsalva	[2] Small varicosities with reflux only during Valsalva		[3] Enlarged vessels dilating during Valsalva	[4] Enlarged vessels with venous reflux at rest not increasing during Valsalva
Iosa and Lazzarini (2013)	[1] Reflux >1 s only during Valsalva	Spontaneous, discontinuous reflux not increased [2] or increased [3] by Valsalva		[4B] Spontaneous, continuous reflux not increased by Valsalva	[4A] Spontaneous, continuous reflux not increased by Valsalva

The grade severity of each classification is reported in brackets. Since the different classifications have not used the same parameter to categorize severity, a strict comparison is not applicable. Extension, size and number of dilated veins, affected side, duration of retrograde flow during Valsalva, presence of spontaneous retrograde flow in the upright position, volume and echo-texture of the affected testis and comparison with the contralateral should be reported when varicocele evaluation is performed.

prostatitis-related premature ejaculation (Lotti *et al.*, 2009). Accordingly, it has been recently reported that varicocelectomy is related to improvement of premature ejaculation (Ahmed *et al.*, 2014).

Epididymis and vas deferens

CDUS abnormalities

At clinical evaluation, tense-elastic spherical formations within the epididymis, mainly located in the head, may represent cysts or spermatoceles. Epididymal cysts and spermatoceles are detectable in one out of four men and appear at US as anechoic avascular and slightly hypoechoic inhomogeneous formations, respectively (Leung *et al.*, 1984). Their clinical significance and association with male infertility has not been yet defined, since their involvement in complete epididymal obstruction and obstructive azoospermia has never been proven (see Singh *et al.* (2012)). Hence, their detection by US has no impact on infertility decision-making (Table I). Conversely, epididymal injury secondary to excision surgery, mainly performed for large and painful lesions, may lead to epididymal obstruction (see Singh *et al.* (2012)). Hence, epididymal cyst surgery is not suggested for restoring fertility (Table I).

Epididymal US echo-texture abnormalities have been associated with acute or chronic inflammation (see Table II; Woodward *et al.*, 2003; Isidori and Lenzi, 2008; Lotti *et al.*, 2011a; Lotti and Maggi, 2013). Acute epididymitis usually presents with a painful hemiscrotum, epididymal swelling and fever (Grabe *et al.*, 2013; Pilatz *et al.*, 2013b). CDUS plays a key role in identifying diagnostic features, revealing mild to severe hyperemia and epididymal enlargement (see Table I), mainly of the tail or both the tail and head (Pilatz *et al.*, 2013b), along with inhomogeneous echo-texture, often hypoechoic with scattered hyperechoic foci, and reactive hydrocele with skin thickening (Horstman *et al.*, 1991b; Woodward *et al.*, 2003; Isidori and Lenzi, 2008; Pilatz *et al.*, 2013b). Concomitant orchitis, revealed in almost half of all the cases, is associated with hydrocele, testicular enlargement, hyper-perfusion and pain (Pilatz *et al.*, 2013b). Under conservative treatment, epididymal CDUS parameters normalize (Pilatz *et al.*, 2013b). Hence, along with clinical characteristics, CDUS may play a role in the follow-up of acute epididymitis (Table I). Chronic epididymitis often involves the tail, with coarse calcifications in a variably enlarged hypo- or hyperechoic epididymis (Fig. 4E and F). The organ has an irregular profile, inhomogeneous, sometimes with hard irregularly shaped masses (Fig. 4E) or indenting the testicular parenchyma, mimicking a primary testicular mass (Woodward *et al.*, 2003). Hydrocele and tunica albuginea thickening are commonly associated, and the latter are sometimes so severe as to be called 'fibrous pseudotumor' (Isidori and Lenzi, 2008). Epididymitis impact on male reproductive function seems to be more relevant than inflammation/infection of the prostate and/or SV (Haidl *et al.*, 2008; see below). Acute infection may lead to transient impairment of semen quality. However, persistent detrimental effects are common (see Rusz *et al.* (2012)). Chronic epididymitis may result in reduced sperm count and motility (Haidl *et al.*, 2008).

Regarding the vas deferens, chronic inflammation and diabetes may cause luminal or parietal calcifications, respectively (Kim *et al.*, 2009) (Fig. 4F). A dilated, inhomogeneous proximal VD may be seen in patients with chronic inflammation (Fig. 4E), distal VD or ED obstruction (often showing deferential ampulla and SV dilation/echo-texture abnormalities, Fig. 4F) or vasectomy (see below). Hence, according to medical

history, epididymal and VD dilation is indicative of a distal obstruction (Fig. 1), suggesting the extension of the US examination to the prostate-vesicular region by transrectal ultrasound (TRUS) (Table I).

Obstruction-related findings

There is no clear evidence that MAGI results in complete epididymal or VD obstruction, with the exception of genital tuberculosis (Dohle *et al.*, 2003), which may present at US with enlarged hypoechoic epididymis with an irregular profile, calcifications and firm granulomatous masses (Isidori and Lenzi, 2008). Obstruction of the distal epididymal tail or of proximal VD has been demonstrated in blocked seminal tracts in subjects treated by epididymovasostomy (Matsuda *et al.*, 1994). Primary obstruction may only be suggested, but not proven, by US (Table I). An epididymal tail >6 mm (Vicari, 1999) and head >11 (Pezzella *et al.*, 2013) or >12 mm (Vicari, 1999) have been proposed as indicative of obstruction (Fig. 4E and G). After vasectomy, an epididymal head >15 mm in vasectomized patients (Reddy *et al.*, 2004) and an increment of 2 cm in epididymal head, with a higher prevalence of inhomogeneity and cysts, have been reported (Jarvis and Dubbins, 1989; Cho *et al.*, 2011) (Fig. 4G). Abrupt tapering, tubular ectasia, enlargement (Fig. 1), with or without calcifications, or mass-like lesions, together with a normal VD caliber, all suggest a partial or even complete epididymal obstruction (Moon *et al.*, 2006). Similar secondary changes of the proximal VD have been reported (Donkol, 2010).

Agensis

Congenital uni- or bilateral vas deferens (VD) agenesis (Fig. 4H) may be partial or complete, depending on the level of the Wolffian duct abnormality. Since VD, seminal vesicles (SV), ejaculatory ducts and epididymis embryologically originate from the Wolffian duct, VD agenesis may be associated with agenesis/abnormalities of these structures. Hence, if VD agenesis is detected at scrotal US, the examination should be extended to the prostate-vesicular region by TRUS (Table I). Interestingly, when complete VD and epididymis agenesis occurs, the epididymal head persists and is detectable by US (Sadler, 2012; Singh *et al.*, 2012).

Congenital bilateral absence of vas deference (CBAVD) accounts for 1–2% of infertile men, 4–17% of azoospermic men and up to 25% of those with obstructive azoospermia (see Singh *et al.* (2012)). CBAVD may be isolated or associated with cystic fibrosis. Almost all men with cystic fibrosis also have CBAVD. Cystic fibrosis is common in Caucasian populations, but very rare in others (see Yu *et al.*, 2012). A recent meta-analysis reported that 78% of CBAVD subjects have at least one CFTR mutation (Yu *et al.*, 2012). The most common heterozygous F508del/5T and F508del/R117H mutations are observed in 17 and 4% of CBAVD, respectively (Yu *et al.*, 2012). CFTR mutations in CBAVD patients exhibit ethnic differences, Caucasian patients showing higher F508del, but lower 5T frequency, than non-Caucasians (Yu *et al.*, 2012). CBAVD is associated with bilateral SV agenesis in about half of the patients, and usually presents with normal kidneys, renal agenesis occurring in 1 out of 10 patients (Schlegel *et al.*, 1996). Almost ~20% of cases of CBAVD, ~20% of cases of unilateral SV agenesis and two-thirds of cases of unilateral SV cyst may present with kidney agenesis and are usually not related to CFTR gene mutations. Conversely, when kidney agenesis occurs, CFTR gene mutations are rarely involved (Singh *et al.*, 2012). In subjects with CBAVD, testes are usually normal in volume and function (Silber *et al.*, 1990). Hence, CBAVD investigation by US is essential in the diagnosis of obstructive azoospermia and in its

clinical decision-making, since surgical sperm retrieval is virtually always positive (see Table I).

Approximately 1% of men have congenital unilateral absence of vas deference (CUAVD). CUAVD is associated with ipsilateral and contralateral SV agenesis in 90 and 20% of patients, respectively, and with renal agenesis in 79% of cases (Singh et al., 2012). Subjects with CUAVD are usually fertile, but at high risk of infertility, having a single patent VD. In addition, those with CUAVD and contralateral SV agenesis may have contralateral deferential ampulla atresia. Therefore, a subset of men with CUAVD may have abnormal semen parameters or azoospermia (Singh et al., 2012). Similar problems may be present in subjects with CUAVD and contralateral testis damage.

Prostate

Volume

Detection of prostate volume (PV) by TRUS has a low impact in the clinical management of male infertility (Table I). A reduced PV suggests hypogonadism, because of the important role of testosterone in prostate growth (Behre et al., 1995; Jin et al., 2001). An increased PV is related to benign prostatic enlargement (BPE), with a PV >30 ml indicating initial gland enlargement (Older and Watson, 1996) and a PV >60 ml indicating a severe form (Gacci et al., 2013). BPE has a continuum spectrum of TRUS abnormalities ranging from larger transitional zone to a well-defined adenoma. The typical TRUS characteristics of BPE are echotexture inhomogeneity, occasional cysts, well- and poorly-defined nodules and calcifications, especially at the 'surgical capsule' (Older and Watson, 1996). Interestingly, BPE has been recently associated with overweight/obesity (Lotti et al., 2011b) and metabolic syndrome (Lotti et al., 2014a).

CDUS abnormalities

A possible negative impact of prostatitis on semen quality is debatable (La Vignera et al., 2011a; Rusz et al., 2012; Lotti et al., 2014b). Accordingly, the relationship between prostate inflammation, CDUS-related abnormalities and sperm parameters is controversial. Hence, the assessment of CDUS prostate abnormalities by TRUS has a low impact on male infertility clinical management (Table I). We report several TRUS features that have been considered suggestive of prostate inflammation (see Table II).

Ejaculatory ducts obstruction/abnormalities

Ejaculatory ducts obstruction (EDO) affects 1–5% of infertile men, and may be congenital or acquired (Singh et al., 2012). Congenital causes include ED atresia/stenosis, midline prostatic cysts or ED congenital cysts (Fig. 1). Acquired causes may be secondary to infection/inflammation, calcifications or iatrogenic (Fisch et al., 2002). Detection of bilateral EDO by TRUS is useful in defining the diagnosis of obstructive azoospermia and its clinical management, considering surgical treatments if specific abnormalities are found (see below and Table I). Patients with congenital or noninfectious causes of EDO, or with partial EDO, have better improvements in semen parameters after treatment than those with infectious causes or complete EDO (see Fisch et al. (2002) and El-Assmy et al. (2012)).

TRUS findings in suspected EDO include midline prostate cysts and ED dilation, calcifications or cysts (Fig. 4I and J). Dilated SV (anterior-posterior diameter >15 mm) and enlarged deferential ampulla

(diameter >6 mm) have also been previously suggested as EDO-related findings (Fig. 1) (Jarow, 1993; Engin et al., 2000; Engin, 2012; Jungwirth et al., 2013). We recently proposed a new parameter related to the SV emptying capacity, 'SV ejection fraction', reporting a cutoff suggestive for complete or partial EDO (Lotti et al., 2012a). However, further studies are needed to assess the clinical relevance of this parameter.

Intraprostatic cysts can be classified as congenital or acquired, or, based on their position within the prostate, as midline, paramedian and lateral cysts (Nghiem et al., 1990; Singh et al., 2012; Shebel et al., 2013). Midline cysts (Fig. 1) affect 1–5% of men, with a greater prevalence in infertile men. They may cause partial or complete EDO, with reduced sperm count or obstructive azoospermia, respectively, often associated with SV obstruction/dilation, reduced ejaculate volume and pH (see Singh et al. (2012)). At TRUS, they appear as roundish or pear/oval-shaped anechoic formations in transversal or longitudinal scans, respectively (Fig. 4I). According to previous studies (see Nghiem et al. (1990), Singh et al. (2012) and Shebel et al. (2013)), two main different cystic entities have been recognized. The first, mullerian cyst, is thought to arise from a regression failure of the mullerian ducts, causing a focal saccular dilation. This cystic entity is located at midline or slightly lateral to midline, is large and may extend above the base of the prostate, does not communicate with the urethra or contain spermatozoa, and may be associated with various genitourinary abnormalities (see Nghiem et al. (1990), Singh et al. (2012) and Shebel et al. (2013)). However, it eventually may erode the ED and affect sperm (Mc Dermott et al., 1995). The second cystic entity, utricular cyst, is thought to derive from dilation of the prostatic utricle, is strictly midline, smaller than the former, and confined to the prostate; it communicates with the urethra and usually contains spermatozoa. Both midline cysts may cause EDO by deviating or compressing the ED (see Nghiem et al. (1990), Singh et al. (2012) and Shebel et al. (2013)). However, even if detection of a midline cyst suggests EDO, conclusions concerning its functional significance cannot be drawn, and size cutoffs for complete EDO have not been reported (Table I). Midline cyst-related EDO may be diagnosed only after TRUS-guided aspiration (Donkol, 2010), which will allow cyst reduction and restore semen expulsion. This is of clinical relevance, since aspiration of large cysts in subjects with obstructive azoospermia may lead to semen parameter improvement (Table I). However, after this procedure, midline cysts may enlarge and lead to EDO and azoospermia again, after variable times. In this case, TRUS should be considered to evaluate cyst recurrence (Table I). Various complications may be associated with prostate cysts, besides infertility, such as urinary tract infection, pain, recurrent epididymitis or prostatitis, and hemospermia (Singh et al., 2012).

Ejaculatory duct (paramedian) cysts (Figs 1 and 3J) may be congenital, originating from wolffian ducts, or acquired, and may be related or not to cystic fibrosis (Singh et al., 2012). Uni- or bilateral, they may lead to obstructive azoospermia. In this case, cysts detection by TRUS is useful in clinical management (Table I), and their surgical treatment often restores semen expulsion (Engin, 2012).

Ejaculatory duct dilation (Figs 1 and 4J) has been defined as a diameter of ED >2 mm (Engin et al., 2000; Fisch et al., 2002; Engin, 2012) and may be related to inflammatory distal stenosis, which is often difficult to detect (Cornud et al., 1997).

Ejaculatory duct calcifications (Figs 1 and 4J) may be associated with EDO, but are not a reliable indicator of it (Jarow, 1993; Fisch et al., 2002; Engin, 2012). They have also been associated with hemospermia

(Littrup *et al.*, 1988) and prostatitis-like symptoms (Lotti *et al.*, 2014b) (Table II). Accordingly, EDO may be associated with hemospermia, prostatitis and painful ejaculation.

In select cases, transurethral resection of ED results in marked improvement in semen parameters, and pregnancies have been achieved (Fisch *et al.*, 2002; Donkol, 2010; Engin, 2012).

Seminal vesicles

Volume

SV volume abnormalities include dilation and hypoplasia.

SV dilation (Fig. 1) has been defined, based on SV diameters, as a SV anterior-posterior diameter > 14 (Vicari, 1999) or 15 mm (Jarow, 1993; Engin *et al.*, 2000; Engin, 2012; Fisch *et al.*, 2002; Jungwirth *et al.*, 2013), suggestive of EDO (Jungwirth *et al.*, 2013). Recently, we proposed an algorithm calculating SV volume (Lotti *et al.*, 2012a; see above). So far, a volumetric cutoff for SV dilation is lacking. However, a higher post-ejaculatory SV volume has been associated with a higher prevalence of SV abnormalities (see below), a higher prostate volume and detection of a prostatic midline cyst, supposed to cause partial or complete EDO, as well as signs suggestive of upstream MGT dilation, such as higher deferential and epididymal tail diameters (Lotti *et al.*, 2012a) (Fig. 1).

A decreased SV volume is defined as hypoplasia, and mainly refers to congenitally small SV (Kim *et al.*, 2009), although an acquired form may be associated with testosterone deficiency (Sasagawa *et al.*, 1989, 1990). It has been defined by some authors as a SV anterior-posterior diameter < 5 (Raviv *et al.*, 2006) or < 7 mm (Vicari, 1999), while others have considered the longitudinal diameter, suggesting a normal SV when > 25 mm in length, hypoplastic when 16–25 mm and atrophic when < 16 mm (Donkol, 2010). So far, a SV volume cutoff is lacking.

Echo-pattern abnormalities

Several US features are suggestive of SV abnormalities and have been associated with inflammation or stasis (see Table II). Their possible negative impact on semen quality/quantity is debatable (La Vignera *et al.*, 2011a; Ruzs *et al.*, 2012). In particular, 'SV areas of endocapsulation', that should be assessed after ejaculation (Lotti *et al.*, 2012a and Table II), is considered a feature suggestive of EDO (Colpi *et al.*, 1997; Jungwirth *et al.*, 2013), however with a low impact on clinical decision-making (Table I).

Obstruction-related findings

An enlarged SV anterior-posterior diameter has been related to partial EDO (Littrup *et al.*, 1988; Kim and Lipshultz, 1996; Colpi *et al.*, 1997) as well as 'SV areas of endocapsulation' (see above). Diagrams showing the partial EDO percentage probability as a function of SV anterior-posterior diameter variation have been reported (Colpi *et al.*, 1997). Reduced 'SV ejection fraction' (see above) is suggestive of impaired SV emptying and partial EDO, and is associated with a higher frequency of SV giant cysts and ED abnormalities (dilation, calcifications or cysts) (Lotti *et al.*, 2012a) (Fig. 1).

Reduced or absent contraction of SV during ejaculation without a clear obstructive cause has been defined as 'functional SV atony' (La Vignera *et al.*, 2011b, c, d). Signs suggestive of SV atony have been described in

patients with type 2 diabetes mellitus (T2DM) with or without diabetic neuropathy (La Vignera *et al.*, 2009, 2011b, c, d).

SV agenesis, hypoplasia and cysts

SV congenital abnormalities include defects in number (agenesis, fusion), maturation (hypoplasia) and canalization (cysts) of the glands (Vohra and Morgentaler, 1997). Their detection is clinically relevant, because they are often associated with abnormal development of other mesonephric/metanephric derivatives, such as the VD, ureter and kidney (Patel *et al.*, 2002), which should be evaluated by US (Table I).

Unilateral SV agenesis arises if an insult occurs before the 7th week of gestation, when the ureteric bud arises from the mesonephric duct (Kim *et al.*, 2009). It is often associated with ipsilateral renal agenesis (79%) or other renal abnormalities (12%) (Kim *et al.*, 2009).

Bilateral SV agenesis is associated with mutations in the CFTR gene in 64–73% of cases, with CBAVD in half of the cases and with normal kidneys (Kim *et al.*, 2009). SV abnormalities are observed in 50% of children and 90% of adults with cystic fibrosis, with the latter showing bilateral agenesis in half of cases, supporting the hypothesis of a progression of the cystic fibrosis-related abnormalities (Carter *et al.*, 1989; Cornud *et al.*, 1997; Rathaus *et al.*, 2006).

Congenital SV hypoplasia may be isolated or associated with other congenital genitourinary anomalies (Kim *et al.*, 2009).

SV cysts (Figs 1 and 4) are rare and may be congenital or acquired. A congenital SV cyst may be isolated or, more often, associated with other genitourinary anomalies. They are mainly secondary to EDO caused by maldevelopment of the distal portion of the mesonephric duct (Patel *et al.*, 2002). They are associated with ipsilateral renal agenesis (Zinner syndrome) or dysgenesis in two-thirds of cases (King *et al.*, 1989). Ectopic ureteral insertion into the SV, ED, VD, or prostatic urethra or VD agenesis may also be present (Kim *et al.*, 2009). Bilateral SV cysts have been reported to occur in 44–60% of patients with autosomal dominant polycystic kidney disease (Danaci *et al.*, 1998). Hence, detection of SV cysts by TRUS is clinically relevant, leading to a careful evaluation of the urinary tract by US (Table I). Acquired cysts are usually unilateral and associated with inflammation-related EDO (Patel *et al.*, 2002). Cystic SV dilatation has been associated with perineal pain (Littrup *et al.*, 1988).

Diagnostic value of scrotal and transrectal ultrasound and specific applications

Sensitivity and specificity of US in predicting azoospermia outcomes

It has been reported that the combination of scrotal and transrectal US, detecting TV and seminal tract obstruction-related findings, respectively, discriminates obstructive and non-obstructive azoospermia (OA and NOA, respectively) with 95% sensitivity and 97% specificity and may be of help in assessing OA etiology (Du *et al.*, 2010). More recently, Abdulwahed *et al.* (2013) found that scrotal US is more sensitive for OA and specific for NOA detection, while TRUS showed the opposite trend. Both imaging examinations had greater specificity than sensitivity for OA, indicating that US is better able to exclude, more than to

diagnose, OA. However, US is still unlikely to replace testicular biopsy (Abdulwahed *et al.*, 2013).

Testis color Doppler ultrasound and surgical sperm retrieval in azoospermic subjects

Surgical sperm retrieval from the testes occurs in 50–60% of men with NOA and in almost all with OA (Dohle *et al.*, 2012). Among the different parameters investigated as predictors of successful sperm retrieval by testicular biopsy in azoospermic subjects, evidence for testis CDUS characteristics, including testis volume (TV) and vascularization, has emerged in the last few years, although it is still debated and has limited clinical utility (see below).

Azoospermic subjects with normal FSH and positive sperm retrieval have higher a TV compared with those with a negative harvesting (Mitchell *et al.*, 2011). TV in OA has been reported as higher than in NOA subjects (Moon *et al.*, 2006; Du *et al.*, 2010). In subjects with CBAVD-related OA, testes are usually normal (Silber *et al.*, 1990; Singh *et al.*, 2012) and sperm retrieval by testicular biopsy virtually always occurs. In NOA subjects, most (Ziaee *et al.*, 2006; Ravizzini *et al.*, 2008; Turunc *et al.*, 2010; Boitrelle *et al.*, 2011), but not all (Tournaye *et al.*, 1997; Dohle *et al.*, 2012), studies have reported higher TVs in subjects with a positive sperm retrieval. TV has been reported as an independent parameter related to testicular biopsy outcome (Boitrelle *et al.*, 2011). A total TV of 16 ml (Boitrelle *et al.*, 2011) and a mean TV of 9.5 ml (Ziaee *et al.*, 2006) have been proposed as cutoffs for positive sperm retrieval. However, TV is considered by other authors as inconclusive in sperm retrieval prediction (Tournaye *et al.*, 1997; Dohle *et al.*, 2012). In fact, surgical sperm retrieval may be positive even in men with very small testis, with Klinefelter's syndrome representing a paradigmatic example (Dabaja and Schlegel, 2013; Bryson *et al.*, 2014). On the other hand, in spermatogenic arrest, surgical outlook is often poor, despite the fact that TV and serum FSH can approach normal values (Hung *et al.*, 2007). Hence, we conclude that, even if US has some prognostic value in surgical sperm retrieval outcomes, it is limited, and ultimately makes little impact on clinical management (Table I).

Interestingly, some testis vascular parameters have been associated with sperm quality (Herwig *et al.*, 2007; Hillelsohn *et al.*, 2013), suggested to be useful in discriminating OA and NOA (Foresta *et al.*, 1998; Battaglia *et al.*, 2001; Biagiotti *et al.*, 2002; Schurich *et al.*, 2009) or residual spermatogenic areas in NOA (Foresta *et al.*, 1998). However, at present, they have been evaluated only for research purposes, with no impact on the clinical management of the azoospermic men (Table I).

Male genital tract US and hormonal treatments

Evaluation of testis and prostate-vesicular US characteristics before the beginning and/or during hormonal treatment represents a valid tool in investigating the response of target organs and in early detection of suspicious findings. Baseline US-assessed TV represents one of the main determinants of gonadotrophin responsiveness in subjects with hypogonadotropic hypogonadism (HH). In fact, a better response in terms of sperm output and ongoing pregnancy has been observed for a basal TV >4 ml (Liu *et al.*, 2002). In addition, US has been performed by some authors to evaluate TV increments during hormonal treatment. GnRH (Canale *et al.*, 1990) or gonadotrophin (Main *et al.*, 2002;

Miyagawa *et al.*, 2005) treatment in HH subjects has been associated with a TV increase up to 170%. A 12 week-treatment with FSH in men with idiopathic infertility demonstrated a TV increase of 5 ml compared with baseline (Kamischke *et al.*, 1998). Considering that among infertile (Jacobsen *et al.*, 2000; Walsh *et al.*, 2009) and azoospermic (Eisenberg *et al.*, 2013) men the risk of testicular malignancy is higher, scrotal US should be performed for prevention purposes in azoospermic and/or HH subjects unresponsive to hormonal treatment. However, at present, no agreement on US testis surveillance in these subjects is available.

TRUS is a useful tool in evaluating prostate response to hormonal treatment in HH subjects under gonadotrophin, GnRH or T treatment (Canale *et al.*, 1990; Behre *et al.*, 1995), monitoring not only their biological efficacy (growth) but also for cancer screening, along with palpation and PSA measurements (Behre *et al.*, 1995). Also the SV volume shows changes at US during hormonal supplementation of hypogonadal men with (Sasagawa *et al.*, 1989) or without (Sasagawa *et al.*, 1990) Klinefelter's syndrome.

Color Doppler ultrasound clinical utility and impact on male reproductive health management

Table I summarizes our view on the clinical utility of MGT-CDUS evaluation in clinical decision-making (ranking from mild to high relevance) in male infertility according to the different sites and types of abnormalities. In many circumstances, clinical, hormonal and semen parameters are informative enough for the management of infertile men (Krausz, 2011; Lotti *et al.*, 2012b). However, MGT-CDUS shows a critical role in specific conditions. MGT-CDUS, particularly TRUS, shows a key role in obstructive azoospermia (Du *et al.*, 2010; Abdulwahed *et al.*, 2013), leading to operational decision-making, such as TRUS-guided cyst aspiration if a large prostatic cyst is found, surgical treatment if ejaculatory duct abnormalities are observed, or surgical sperm extraction if CBAVD is detected (Fisch *et al.*, 2002; Donkol, 2010; Engin, 2012).

In particular, EAU Guidelines on Male Infertility (Jungwirth *et al.*, 2013) consider TRUS essential to assess distal obstruction. SV enlargement (anterior-posterior diameter >15 mm) and SV round, anechoic areas are TRUS anomalies often associated with ejaculatory duct obstruction, especially when the semen volume is <1.5 ml (Jungwirth *et al.*, 2013). Prostate midline and ejaculatory duct cysts or calcifications are anomalies often associated with obstructive azoospermia (Jungwirth *et al.*, 2013). In addition, scrotal US is helpful in finding other signs of obstruction (e.g. dilatation of rete testis, enlarged epididymis) (Jungwirth *et al.*, 2013).

Transrectal and scrotal US are useful in detecting CBAVD or CUAVD (EAU Guidelines on Male Infertility, Jungwirth *et al.*, 2013), suggesting more specific examinations (CFTR gene evaluation, urinary tract evaluation by US and surgical sperm extraction) (see Forti and Krausz, 1998 and Lotti *et al.*, 2012b). TRUS may detect SV cysts, usually associated with other genitor-urinary abnormalities (Patel *et al.*, 2002), and should prompt other investigations.

Scrotal US offers a greater accuracy in TV measurement than PO (Lenz *et al.*, 1993; Sakamoto *et al.*, 2007a, b), but PO- and US-derived TV are closely related (Goede *et al.*, 2011; Rastrelli *et al.*, 2013), hence PO-measured TV is sufficient for the management of infertile men in everyday clinical practice. Furthermore, scrotal US is useful in evaluating

Table IV Schematic summary of seminal, ultrasound and hormonal abnormalities in different etiological causes of male infertility.

	Primary hypogonadism*	Secondary hypogonadism*	Complete bilateral EDO	CBAVD [§]	Proximal bilateral (sub)obstruction	Maturation arrest and SCOS
Semen parameters						
Sperm concentration	Oligo/azoospermia	Oligo/azoospermia	Azoospermia	Azoospermia	Oligo/azoospermia	Azoospermia
Ejaculate volume [^]	~Reduced	~Reduced	Low	Normal. Reduced if SV abnormalities.	Normal	Normal
pH [^]	Normal/ reduced	Normal/ reduced	Low	Normal. Reduced if SV abnormalities.	Normal	Normal
Ultrasound						
Testis [°]	Highly reduced volume, abnormal echo-texture	Slightly reduced volume; abnormal echo-texture	Normal volume and echo-texture	Normal volume and echo-texture	Normal volume and echo-texture	Maturation arrest: normal volume and echo-texture SCOS: normal/reduced volume and slight inhomogeneity
Epididymal head [°]	Normal length	Normal length	Normal/increased	Normal/increased	Normal/increased	Normal length
Epididymal tail [°]	Normal width	Normal width	Normal/increased	Normal/increased	Normal/increased	Normal width
Proximal vas deferens [°]	Normal width	Normal width	Normal/increased	Normal/increased	Normal	Normal width
Deferential ampulla [°]	Normal width	Normal width	Normal/increased	Normal/increased	Normal	Normal width
Prostate volume [°]	Reduced	Reduced	Normal	Normal	Normal	Normal
Ejaculatory ducts [°]	Normal	Normal	Dilated and/or cysts and/or calcifications	Possible abnormalities	Normal	Normal
SV [°]	Reduced (?)	Reduced (?)	Dilated. No modification with ejaculation [#]	Possible abnormalities	Normal	Normal
Kidneys	Present	Present	Present	Usually present	Present	Present
Hormones						
T [♂]	Low	Low	Normal	Normal	Normal	Normal
FSH [♂]	Elevated	Normal/low	Normal	Normal	Normal	– Maturation arrest: normal; – SCOS: normal/high
LH [♂]	Elevated	Normal/low	Normal	Normal	Normal	Normal

The seminal, ultrasound and hormonal parameters related to the different categories of azoospermia are defined according to Fisch et al. (2002), Isidori and Lenzi (2008), Cooper (2010), Simoni and Nieschlag (2010) and Singh et al. (2012). EDO, ejaculatory duct obstruction; CBAVD, congenital bilateral absence of vas deferens; SCOS, Sertoli-cells-only syndrome; SV, seminal vesicles; SVEF, seminal vesicles ejection fraction; LH, luteinizing hormone; FSH, follicle-stimulating hormone; T, testosterone.

*Hypogonadism is defined as impaired testis production of spermatozoa and/or testosterone.

[§]Abnormalities of CBAVD may be found in congenital unilateral absence of vas deferens (CUAVD) with contralateral EDO or testis impairment. CUAVD is frequently associated with ipsilateral abnormalities/absence of epididymis, SV and kidney.

[^]Normal ejaculate volume and pH are defined ≥ 1.5 ml and 7.2, respectively (WHO, 2010).

[°]Normal and abnormal US definition. Normal US-testicular volume is defined $> 10-11$ ml (see the text). Dilated epididymal head and tail are defined when > 12 and 6 mm, respectively (Vicari, 1999; Pezzella et al., 2013). Normal prostate volume is considered $20-25$ ml (Raza and Jhaveri, 2012); initial enlargement > 30 ml (Older and Watson, 1996); low volume is defined < 15 ml (extrapolated from Canale et al. (1990) and Sasagawa et al. (1989, 1990). Dilated deferential ampulla, > 6 mm; dilated ejaculatory duct, > 2 mm; dilated SV: anterior-posterior diameter after ejaculation > 14 (Vicari, 1999) or 15 mm (Jarow, 1993; Engin et al., 2000, Engin, 2012; Fisch et al., 2002; Jungwirth et al., 2013), or total SV volume after ejaculation > 7 ml (extrapolated from Lotti et al., 2012a). SV hypoplasia: anterior-posterior diameter < 5 (Raviv et al., 2006) or 7 mm (Vicari, 1999), or longitudinal diameter < 25 mm (Donkol, 2010).

[#]Suggestive of impaired SV emptying: 'SV ejection fraction' $< 21.6\%$ (Lotti et al., 2012a).

[♂]Biochemical hypogonadism is defined for total testosterone levels < 12 nmol/l or calculated free testosterone < 225 pmol/l (Wang et al., 2009). Normal or elevated FSH is defined for FSH levels < 8 or ≥ 8 U/l (Anderson et al., 2004). Secondary or primary hypogonadism are defined for LH ≤ 9.4 or > 9.4 U/l, respectively (Tajar et al., 2010). Very low LH and FSH levels are defined as $< 1-2$ U/l (Silveira and Latronico, 2013).

testicular characteristics when physical examination is unreliable (Behre *et al.*, 1989; Sakamoto *et al.*, 2006; Behre and Zitzmann, 2010).

Scrotal US may indicate characteristics suggestive of testicular damage in non-obstructive azoospermia (Abdulwahed *et al.*, 2013); however, it is not predictive of sperm retrieval in spermatogenic arrest-associated non-obstructive azoospermia (Hung *et al.*, 2007).

Scrotal US is useful in assessing or monitoring signs of testicular dysgenesis (i.e. nonhomogeneous testicular architecture, microcalcifications, cryptorchid testis and suspected small lesions) (Christensen and Dogra, 2007; Dohle *et al.*, 2012; Jungwirth *et al.*, 2013) or testicular abnormalities suspected of malignancy (Isidori and Lenzi, 2008; Albers *et al.*, 2013).

CDUS is useful in localizing inguinal (Nijs *et al.*, 2007) but not intra-abdominal testes (Tasian and Copp, 2011) and its role is debated in preoperative planning (Christensen and Dogra, 2007; Ozden *et al.*, 2012).

MGT-CDUS shows poor utility in surgical sperm extraction decision-making, since the latter is performed even when small testes or karyotype abnormalities are found (Dabaja and Schlegel, 2013; Bryson *et al.*, 2014).

Physical examination may be considered sufficient for diagnosis and decision-making in varicocele treatment (AUA/ASRM, 2008); however, EAU Guidelines on Male Infertility (Jungwirth *et al.*, 2013) report that 'the diagnosis of varicocele should be confirmed by CDUS'. In particular, scrotal CDUS plays a role when physical examination is unreliable, exploring persistent reflux in clinical and subclinical varicocele, and is useful in evaluating venous reflux recurrence/persistence after surgery (see Lee *et al.* (2008)).

Conclusions

Even if medical care for men suffering childlessness is growing, in andrology, diagnostic and therapeutic measures have not yet reached a critical mass to ensure a reasonable understanding of the underlying problem and the consequent evidence-based treatment. Nowadays, scrotal and transrectal imaging of the male genital tract (MGT) has greatly helped in the deciphering anatomy, physiology and pathology of male infertility. Table IV offers a provisional summary of seminal, US and hormonal correlates of some recognized causes of male infertility. However, sonographic imaging of MGT still suffers from a lack of standardization and often tends to produce subjective and vague diagnoses. This is the main reason why the European Academy of Andrology has promoted an ongoing multicenter study (see at <http://www.andrologyacademy.net/studies.php>) aimed at defining the anatomic and functional characteristic of healthy, fertile men, i.e. those who are fathering or have fathered in the past year. Defining US parameters of male fertility will be of great help in establishing criteria for their pathological counterparts in subfertility/infertility.

Acknowledgement

We thank Anna Maggi, illustration designer, for graphical support for Figures 1 and 2.

Authors' roles

F.L. and M.M. made substantial contributions to the conception of the manuscript, the identification of relevant studies (by extensive Medline

searches and analysis of previous reports in color-Doppler ultrasound atlas textbooks), the drafting of the article, the adjustments after the review by other authors, and the critical review of the article. Both authors gave final approval of the submitted version of the manuscript.

Funding

No funding was obtained for this study.

Conflict of interest

F.L. and M.M. have nothing to declare.

References

- Abdulwahed SR, Mohamed EE, Taha EA, Saleh MA, Abdelsalam YM, ElGanainy EO. Sensitivity and specificity of ultrasonography in predicting etiology of azoospermia. *Urology* 2013;**81**:967–971.
- Ahmed AF, Abdel-Aziz AS, Maarouf AM, Ali M, Emara AA, Gomaa A. Impact of varicolectomy on premature ejaculation in varicocele patients. *Andrologia* 2014 Mar 10 (epub ahead of print).
- Aizenstein RI, DiDomenico D, Wilbur AC, O'Neil HK. Testicular microlithiasis: association with male infertility. *J Clin Ultrasound* 1998;**26**:195–198.
- Albers P, Albrecht W, Algaba F, Bokemeyer C, Cohn-Cedermark G, Fizazi K, Horwich A, Laguna MP. *Guidelines on Testicular Cancer. European Association of Urology Guidelines*. Arnhem, The Netherlands: EAU Guidelines Office, 2013.
- Alberti KG, Eckel RH, Grundy SM, Zimmet PZ, Cleeman JI, Donato KA, Fruchart JC, James WP, Loria CM, Smith SC Jr; International Diabetes Federation Task Force on Epidemiology and Prevention; National Heart, Lung, and Blood Institute; American Heart Association; World Heart Federation; International Atherosclerosis Society; International Association for the Study of Obesity. Harmonizing the metabolic syndrome: a joint interim statement of the International Diabetes Federation Task Force on Epidemiology and Prevention; National Heart, Lung, and Blood Institute; American Heart Association; World Heart Federation; International Atherosclerosis Society; and International Association for the Study of Obesity. *Circulation* 2009;**120**:1640–1645.
- Ammar T, Sidhu PS, Wilkins CJ. Male infertility: the role of imaging in diagnosis and management. *Br J Radiol* 2012;**85**:S59–S68.
- Andersson AM, Petersen JH, Jørgensen N, Jensen TK, Skakkebaek NE. Serum inhibin B and follicle-stimulating hormone levels as tools in the evaluation of infertile men: significance of adequate reference values from proven fertile men. *J Clin Endocrinol Metab* 2004;**89**:2873–2879.
- Appelbaum L, Gaitini D, Dogra VS. Scrotal ultrasound in adults. *Semin Ultrasound CT MR* 2013;**34**:257–273.
- Arai T, Kitahara S, Horiuchi S, Sumi S, Yoshida K. Relationship of testicular volume to semen profiles and serum hormone concentrations in infertile Japanese males. *Int J Fertil Womens Med* 1998;**43**:40–47.
- Baazeem A, Belzile E, Ciampi A, Dohle G, Jarvi K, Salonia A, Weidner W, Zini A. Varicocele and male factor infertility treatment: a new meta-analysis and review of the role of varicocele repair. *Eur Urol* 2011;**60**:796–808.
- Bahk JY, Jung JH, Jin LM, Min SK. Cut-off value of testes volume in young adults and correlation among testes volume, body mass index, hormonal level, and seminal profiles. *Urology* 2010;**75**:1318–1323.
- Baker HWG, Burger HG, de Kretser DM, Hudson B, O'Connor S, Wang C, Mirovics A, Court J, Dunlop M, Rennie GC. Changes in the pituitary-testicular system with age. *Clin Endocrinol (Oxf)* 1976;**5**:349–372.
- Battaglia C, Giulini S, Regnani G, Madgar I, Facchinetti F, Volpe A. Intratesticular Doppler flow, seminal plasma nitrites/nitrates, and nonobstructive sperm extraction from patients with obstructive and nonobstructive azoospermia. *Fertil Steril* 2001;**75**:1088–1094.
- Behre HM, Zitzmann M. Imaging diagnostics. In: Nieschlag E, Behre HM, Nieschlag S (eds). *Andrology. Male Reproductive Health and Dysfunction*, 3rd edn. Chapter 6. Berlin: Springer, 2010, 101–107.

- Behre HM, Nashan D, Nieschlag E. Objective measurement of testicular volume by ultrasonography: evaluation of the technique and comparison with orchidometer estimates. *Int J Androl* 1989;**12**:395–403.
- Behre HM, Kliesch S, Schädel F, Nieschlag E. Clinical relevance of scrotal and transrectal ultrasonography in andrological patients. *Int J Androl* 1995;**18**:27–31.
- Béres J, Papp G, Pazonyi I, Czeizel E. Testicular volume variations from 0 to 28 years of age. *Int Urol Nephrol* 1989;**21**:159–167.
- Berger AP, Horninger W, Bektic J, Pelzer A, Spranger R, Bartsch G, Frauscher F. Vascular resistance in the prostate evaluated by colour Doppler ultrasonography: is benign prostatic hyperplasia a vascular disease? *BJU Int* 2006;**98**:587–590.
- Berkovitz GD, Wilson DP, Carpenter NJ, Brown TR, Migeon CJ. Gonadal function in men with the Martin-Bell (fragile-X) syndrome. *Am J Med Genet* 1986;**23**:227–239.
- Biagiotti G, Cavallini G, Modenini F, Vitali G, Gianaroli L. Spermatogenesis and spectral echo-colour Doppler traces from the main testicular artery. *BJU Int* 2002;**90**:903–908.
- Boitrelle F, Robin G, Marcelli F, Albert M, Leroy-Martin B, Dewailly D, Rigot JM, Mitchell V. A predictive score for testicular sperm extraction quality and surgical ICSI outcome in non-obstructive azoospermia: a retrospective study. *Hum Reprod* 2011;**26**:3215–3221.
- Bryson CF, Ramasamy R, Sheehan M, Palermo GD, Rosenwaks Z, Schlegel PN. Severe testicular atrophy does not affect the success of microdissection testicular sperm extraction. *J Urol* 2014;**191**:175–178.
- Bujan L, Mieuisset R, Mansat A, Moatti JP, Mondinat C, Pontonnier F. Testicular size in infertile men: relationship to semen characteristics and hormonal blood levels. *Br J Urol* 1989;**64**:632–637.
- Canale D, Mais V, Turchi P, Andreini F, Melis GB, Menchini-Fabris GF. Ultrasound monitoring of testis and prostate maturation in hypogonadotropic hypogonadic males during gonadotropin-releasing hormone treatment. *Fertil Steril* 1990;**53**:537–540.
- Canales BK, Zapzalka DM, Ercole CJ, Carey P, Haus E, Aeppli D, Pryor JL. Prevalence and effect of varicoceles in an elderly population. *Urology* 2005;**66**:627–631.
- Cantu JM, Scaglia HE, Medina M, Gonzalez-Diddi M, Moranto T, Moreno ME, Perez-Palacios G. Inherited congenital normofunctional testicular hyperplasia and mental deficiency. *Hum Genet* 1976;**33**:23–33.
- Carlsen E, Andersen AG, Buchreitz L, Jørgensen N, Magnus O, Matulevicius V, Nermoen I, Petersen JH, Punab M, Suominen J *et al.* Inter-observer variation in the results of the clinical andrological examination including estimation of testicular size. *Int J Androl* 2000;**23**:248–253.
- Carter SS, Shinohara K, Lipshultz LI. Transrectal ultrasonography in disorders of the seminal vesicles and ejaculatory ducts. *Urol Clin North Am* 1989;**16**:773–790.
- Cayan S, Woodhouse CR. The treatment of adolescents presenting with a varicocele. *BJU Int* 2007;**100**:744–747.
- Cho IR, Keener TS, Nghiem HV, Winter T, Krieger JN. Prostate blood flow characteristics in the chronic prostatitis/pelvic pain syndrome. *J Urol* 2000;**163**:1130–1133.
- Cho SH, Min SK, Lee ST. Associations of ultrasonographic features with scrotal pain after vasectomy. *Korean J Urol* 2011;**52**:782–786.
- Christensen JD, Dogra VS. The undescended testis. *Semin Ultrasound CT MR* 2007;**28**:307–316.
- Christiansen E, Purvis K. Diagnosis of chronic abacterial prostatitis-vesiculitis by rectal ultrasonography in relation to symptoms and findings. *Br J Urol* 1991;**67**:173–176.
- Cina A, Minnetti M, Pirroni T, Vittoria Spampinato M, Canadè A, Oliva G, Ribatti D, Bonomo L. Sonographic quantitative evaluation of scrotal veins in healthy subjects: normative values and implications for the diagnosis of varicocele. *Eur Urol* 2006;**50**:345–350.
- Clyne M. Male factor infertility: asymptomatic testicular microlithiasis does not increase antisperm antibody production in infertile men. *Nat Rev Urol* 2012 Sep 18. doi: 10.1038/nrurol.2012.179 (epub ahead of print).
- Collins GN, Raab GM, Hehir M, King B, Garraway WM. Reproducibility and observer variability of transrectal ultrasound measurements of prostatic volume. *Ultrasound Med Biol* 1995;**21**:1101–1105.
- Colpi GM, Negri L, Nappi RE, Chinea B. Is transrectal ultrasonography a reliable diagnostic approach in ejaculatory duct sub-obstruction? *Hum Reprod* 1997;**12**:2186–2191.
- Condorelli R, Calogero AE, La Vignera S. Relationship between testicular volume and conventional or nonconventional sperm parameters. *Int J Endocrinol* 2013;**2013**:145792. doi: 10.1155/2013/145792. Epub 2013 Sep 5.
- Cooper TG. Semen analysis. In: Nieschlag E, Behre HM, Nieschlag S (eds). *Andrology. Male Reproductive Health and Dysfunction*, 3rd edn. Berlin: Springer, 2010, 125–138.
- Cornud F, Belin X, Delafontaine D, Amar T, Hélénon O, Moreau JF. Imaging of obstructive azoospermia. *Eur Radiol* 1997;**7**:1079–1085.
- Cornud F, Belin X, Amar E, Delafontaine D, Hélénon O, Moreau JF. Varicocele: strategies in diagnosis and treatment. *Eur Radiol* 1999;**9**:536–545.
- Dabaja AA, Schlegel PN. Microdissection testicular sperm extraction: an update. *Asian J Androl* 2013;**15**:35–39.
- Danaci M, Akpolat T, Baştemir M, Sarikaya S, Akan H, Selçuk MB, Cengiz K. The prevalence of seminal vesicle cysts in autosomal dominant polycystic kidney disease. *Nephrol Dial Transplant* 1998;**13**:2825–2828.
- Deg'Innocenti S, Filimberti E, Magini A, Krausz C, Lombardi G, Fino MG, Rastrelli G, Maggi M, Baldi E. Semen cryopreservation for men banking for oligospermia, cancers, and other pathologies: prediction of post-thaw outcome using basal semen quality. *Fertil Steril* 2013;**100**:1555–1563.e1–3.
- Dhabuwala CB, Kumar AB, Kerkar PD, Bhutawala A, Pierce J. Patterns of Doppler recordings and its relationship to varicocele in infertile men. *Int J Androl* 1989;**12**:430–438.
- Diamond JM. Ethnic differences. Variation in human testis size. *Nature* 1986;**320**:488–489.
- Diamond DA, Paltiel HJ, DiCanzio J, Zurakowski D, Bauer SB, Atala A, Ephraim PL, Grant R, Retik AB. Comparative assessment of pediatric testicular volume: orchidometer versus ultrasound. *J Urol* 2000;**164**:1111–1114.
- Di Trapani D, Pavone C, Serretta V, Cavallo N, Costa G, Pavone-Macaluso M. Chronic prostatitis and prostatodynia: ultrasonographic alterations of the prostate, bladder neck, seminal vesicles and periprostatic venous plexus. *Eur Urol* 1988;**15**:230–234.
- Doble A, Carter SS. Ultrasonographic findings in prostatitis. *Urol Clin North Am* 1989;**16**:763–772.
- Dogra VS, Gottlieb RH, Oka M, Rubens DJ. Sonography of the scrotum. *Radiology* 2003;**227**:18–36.
- Dohle GR, Elzanaty S, van Casteren NJ. Testicular biopsy: clinical practice and interpretation. *Asian J Androl* 2012;**14**:88–93.
- Donkol RH. Imaging in male-factor obstructive infertility. *World J Radiol* 2010;**2**:172–179.
- Du J, Li FH, Guo YF, Yang LM, Zheng JF, Chen B, Zhu JS, Liu Q. Differential diagnosis of azoospermia and etiologic classification of obstructive azoospermia: role of scrotal and transrectal US. *Radiology* 2010;**256**:493–503.
- Dubin L, Amelar RD. Varicocele size and results of varicolectomy in selected subfertile men with varicocele. *Fertil Steril* 1970;**21**:606–609.
- Eisenberg ML, Betts P, Herder D, Lamb DJ, Lipshultz LI. Increased risk of cancer among azoospermic men. *Fertil Steril* 2013;**100**:681–685.
- Ekerhovd E, Westlander G. Testicular sonography in men with Klinefelter syndrome shows irregular echogenicity and blood flow of high resistance. *J Assist Reprod Genet* 2002;**19**:517–522.
- El-Assmy A, El-Tholoth H, Abouelkheir RT, Abou-El-Ghar ME. Transurethral resection of ejaculatory duct in infertile men: outcome and predictors of success. *Int Urol Nephrol* 2012;**44**:1623–1630.
- Elzinga-Tinke JE, Sirre ME, Looijenga LH, van Casteren N, Wildhagen MF, Dohle GR. The predictive value of testicular ultrasound abnormalities for carcinoma in situ of the testis in men at risk for testicular cancer. *Int J Androl* 2010;**33**:597–603.
- Engin G. Transrectal US-guided seminal vesicle aspiration in the diagnosis of partial ejaculatory duct obstruction. *Diagn Interv Radiol* 2012;**18**:488–495.
- Engin G, Kadioğlu A, Orhan I, Akdöl S, Rozanes I. Transrectal US and endorectal MR imaging in partial and complete obstruction of the seminal duct system. A comparative study. *Acta Radiol* 2000;**41**:288–295.
- Fisch H, Kang YM, Johnson CW, Goluboff ET. Ejaculatory duct obstruction. *Curr Opin Urol* 2002;**12**:509–515.
- Fisher AD, Rastrelli G, Bandini E, Corona G, Balzi D, Melani C, Monami M, Matta V, Mannucci E, Maggi M. Metabolic and cardiovascular outcomes of fatherhood: results from a cohort of study in subjects with sexual dysfunction. *J Sex Med* 2012;**9**:2785–2794.
- Foresta C, Garolla A, Bettella A, Ferlin A, Rossato M, Candiani F. Doppler ultrasound of the testis in azoospermic subjects as a parameter of testicular function. *Hum Reprod* 1998;**13**:3090–3093.
- Foresta C, Garolla A, Frigo AC, Carraro U, Isidori AM, Lenzi A, Ferlin A. Anthropometric, penile and testis measures in post-pubertal Italian males. *J Endocrinol Invest* 2013;**36**:287–292.

- Forti G, Krausz C. Clinical review 100: Evaluation and treatment of the infertile couple. *J Clin Endocrinol Metab* 1998;**83**:4177–4188.
- Forti G, Krausz C, Cilotti A, Maggi M. Varicocele and infertility. *J Endocrinol Invest* 2003;**26**:564–569.
- Friedler S, Raziell A, Strassburger D, Soffer Y, Komarovskiy D, Ron-El R. Testicular sperm retrieval by percutaneous fine needle sperm aspiration compared with testicular sperm extraction by open biopsy in men with non-obstructive azoospermia. *Hum Reprod* 1997;**12**:1448–1493.
- Gacci M, Vignozzi L, Sebastianelli A, Salvi M, Giannessi C, De Nunzio C, Tubaro A, Corona G, Rastrelli G, Santi R et al. Metabolic syndrome and lower urinary tract symptoms: the role of inflammation. *Prostate Cancer Prostatic Dis* 2013;**16**:101–106.
- Gat Y, Gornish M, Heiblum M, Joshua S. Reversal of benign prostate hyperplasia by selective occlusion of impaired venous drainage in the male reproductive system: novel mechanism, new treatment. *Andrologia* 2008;**40**:273–281.
- Geatti O, Gasparini D, Shapiro B. A comparison of scintigraphy, thermography, ultrasound and phlebography in grading of clinical varicocele. *J Nucl Med* 1991;**32**:2092–2097.
- Goede J, Hack WW, Sijstermans K, van der Voort-Doedens LM, Van der Ploeg T, Meij-de Vries A, Delemarre-van de Waal HA. Normative values for testicular volume measured by ultrasonography in a normal population from infancy to adolescence. *Horm Res Paediatr* 2011;**76**:56–64.
- Grabe M, Bjerklund-Johansen TE, Botto H, Çek M, Naber KG, Pickard RS, Tenke P, Wagenlehner F, Wulft B. *Guidelines on Urological Infections, European Association of Urology Guidelines*. Arnhem, The Netherlands: EAU Guidelines Office, 2013.
- Haidl G, Allam JP, Schuppe HC. Chronic epididymitis: impact on semen parameters and therapeutic options. *Andrologia* 2008;**40**:92–96.
- Hamm B, Fobbe F. Maturation of the testis: ultrasound evaluation. *Ultrasound Med Biol* 1995;**21**:143–147.
- Handelsman DJ, Staraj S. Testicular size: the effects of aging, malnutrition, and illness. *J Androl* 1985;**6**:144–151.
- Handelsman DJ, Conway AJ, Boylan LM, Turtle JR. Testicular function in potential sperm donors: normal ranges and the effects of smoking and varicocele. *Int J Androl* 1984;**7**:369–382.
- Harman SM, Tsitsouras PD. Reproductive hormones in aging men: I. Measurement of sex steroids, basal luteinizing hormone and Leydig cell response to human chorionic gonadotropin. *J Clin Endocrinol Metab* 1980;**51**:35–40.
- Herwig R, Tosun K, Schuster A, Rehder P, Glodny B, Wildt L, Illmensee K, Pinggera GM. Tissue perfusion-controlled guided biopsies are essential for the outcome of testicular sperm extraction. *Fertil Steril* 2007;**87**:1071–1076.
- Hillelsohn JH, Chuang KW, Goldenberg E, Gilbert BR. Spectral Doppler sonography: a noninvasive method for predicting dyspermia. *J Ultrasound Med* 2013;**32**:1427–1432.
- Hirsh AV, Cameron KM, Tyler JP, Simpson J, Pryor JP. The Doppler assessment of varicoceles and internal spermatic vein reflux in infertile men. *Br J Urol* 1980;**52**:50–56.
- Hoekstra T, Witt MA. The correlation of internal spermatic vein palpability with ultrasonographic diameter and reversal of venous flow. *J Urol* 1995;**153**:82–84.
- Horstman WG, Middleton WD, Melson GL, Siegel BA. Color Doppler US of the Scrotum. *Radiographics* 1991a;**11**:941–957.
- Horstman WG, Middleton WD, Melson GL. Scrotal inflammatory disease: color Doppler US findings. *Radiology* 1991b;**179**:55–59.
- Hotaling JM, Lopushnyan NA, Davenport M, Christensen H, Pagel ER, Muller CH, Walsh TJ. Raw and test-thaw semen parameters after cryopreservation among men with newly diagnosed cancer. *Fertil Steril* 2013;**99**:464–469.
- Huang DY, Sidhu PS. Focal testicular lesions: colour Doppler ultrasound, contrast-enhanced ultrasound and tissue elastography as adjuvants to the diagnosis. *Br J Radiol* 2012;**85**:S41–S53.
- Hung AJ, King P, Schlegel PN. Uniform testicular maturation arrest: a unique subset of men with nonobstructive azoospermia. *J Urol* 2007;**178**:608–612.
- Iaccarino V, Venetucci P. Interventional radiology of male varicocele: current status. *Cardiovasc Intervent Radiol* 2012;**35**:1263–1280.
- Iosa G, Lazzarini D. Hemodynamic classification of varicoceles in men: our experience. *J Ultrasound* 2013;**16**:57–63.
- Isidori AM, Lenzi A. *Scrotal CDU: Morphological and Functional Atlas*. Genova: Forum Service Editore s.r.l., 2008.
- Jacobsen R, Bostofte E, Engholm G, Hansen J, Olsen JH, Skakkebaek NE, Møller H. Risk of testicular cancer in men with abnormal semen characteristics: cohort study. *BMJ* 2000;**321**:789–792.
- Jarow JP. Transrectal ultrasonography of infertile men. *Fertil Steril* 1993;**60**:1035–1039.
- Jarvis LJ, Dubbins PA. Changes in the epididymis after vasectomy: sonographic findings. *AJR Am J Roentgenol* 1989;**152**:531–534.
- Jensen TK, Jørgensen N, Punab M, Haugen TB, Suominen J, Zilaitiene B, Horte A, Andersen AG, Carlsen E, Magnus Ø et al. Association of in utero exposure to maternal smoking with reduced semen quality and testis size in adulthood: a cross-sectional study of 1,770 young men from the general population in five European countries. *Am J Epidemiol* 2004;**159**:49–58.
- Jiang H, Zhu WJ. Testicular microlithiasis is not a risk factor for the production of antisperm antibody in infertile males. *Andrologia* 2013;**45**:305–309.
- Jin B, Conway AJ, Handelsman DJ. Effects of androgen deficiency and replacement on prostate zonal volumes. *Clin Endocrinol (Oxf)* 2001;**54**:437–445.
- Jørgensen N, Carlsen E, Nermoen I, Punab M, Suominen J, Andersen AG, Andersson AM, Haugen TB, Horte A, Jensen TK et al. East-West gradient in semen quality in the Nordic-Baltic area: a study of men from the general population in Denmark, Norway, Estonia and Finland. *Hum Reprod* 2002;**17**:2199–2208.
- Jungwirth A, Diemer T, Dohle GR, Giwercman A, Kopa Z, Tournaye H, Krausz C. *Guidelines on Male Infertility, European Association of Urology Guidelines*. Arnhem, The Netherlands: EAU Guidelines Office, 2013.
- Kamischke A, Behre HM, Bergmann M, Simoni M, Schäfer T, Nieschlag E. Recombinant human follicle stimulating hormone for treatment of male idiopathic infertility: a randomized, double-blind, placebo-controlled, clinical trial. *Hum Reprod* 1998;**13**:596–603.
- Kamoi K. [Clinical usefulness of transrectal sonography and transperineal color Doppler flow imaging in the diagnosis of intrapelvic venous congestion syndrome]. *Nihon Hinyokika Gakkai Zasshi* 1996;**87**:1009–1017 [Article in Japanese].
- Kasturi SS, Tannir J, Brannigan RE. The metabolic syndrome and male infertility. *J Androl* 2008;**29**:251–259.
- Keener TS, Winter TC, Nghiem HV, Schmiedl UP. Normal adult epididymis: evaluation with color Doppler US. *Radiology* 1997;**202**:712–714.
- Keener TS, Winter TC, Berger R, Krieger JN, Nodell C, Rothman I, Nghiem HV. Prostate vascular flow: the effect of ejaculation as revealed on transrectal power Doppler sonography. *AJR Am J Roentgenol* 2000;**175**:1169–1172.
- Kim ED, Lipshultz LI. Role of ultrasound in the assessment of male infertility. *J Clin Ultrasound* 1996;**24**:437–453.
- Kim W, Rosen MA, Langer JE, Banner MP, Siegelman ES, Ramchandani P. US-MR Imaging correlation in pathologic conditions of the scrotum. *Radiographics* 2007;**27**:1239–1253.
- Kim B, Kawashima A, Ryu JA, Takahashi N, Hartman RP, King BF Jr. Imaging of the seminal vesicle and vas deferens. *Radiographics* 2009;**29**:1105–1121.
- King BF, Hattery RR, Lieber MM, Williamson BJ, Hartman GW, Berquist TH. Seminal vesicle imaging. *Radiographics* 1989;**9**:653–676.
- Kollin C, Hesser U, Ritzen EM, Karpe B. Testicular growth from birth to two years of age, and the effect of orchidopexy at age nine months: a randomized, controlled study. *Acta Paediatr* 2006;**95**:318–324.
- Krausz C. Male infertility: pathogenesis and clinical diagnosis. *Best Pract Res Clin Endocrinol Metab* 2011;**25**:271–285.
- Kroese AC, de Lange NM, Collins J, Evers JL. Surgery or embolization for varicoceles in subfertile men. *Cochrane Database Syst Rev* 2012;**10**:CD000479.
- Kroese AC, de Lange NM, Collins JA, Evers JL. Varicocele surgery, new evidence. *Hum Reprod Update* 2013;**19**:317.
- Kuijper EA, van Kooten J, Verbeke JI, van Rooijen M, Lambalk CB. Ultrasonographically measured testicular volumes in 0- to 6-year-old boys. *Hum Reprod* 2008;**23**:792–796.
- Lachiewicz AM, Dawson DV. Do young boys with fragile X syndrome have macroorchidism? *Pediatrics* 1994;**93**:992–995.
- La Vignera S, Calogero AE, Arancio A, Castiglione R, De Grande G, Vicari E. Transrectal ultrasonography in infertile patients with persistently elevated bacteriospermia. *Asian J Androl* 2008;**10**:731–740.
- La Vignera S, Lanzafame F, Di Mauro M, Condorelli R, Vicari E. Spermatic and ultrasound characterization of young diabetic patients. *Arch Ital Urol Androl* 2009;**81**:245–247.
- La Vignera S, Vicari E, Condorelli RA, D'Agata R, Calogero AE. Male accessory gland infection and sperm parameters (review). *Int J Androl* 2011a;**34**:e330–e347.
- La Vignera S, Vicari E, Condorelli R, D'Agata R, Calogero AE. Ultrasound characterization of the seminal vesicles in infertile patients with type 2 diabetes mellitus. *Eur J Radiol* 2011b;**80**:e64–e67.
- La Vignera S, Condorelli RA, Di Mauro M, D'Agata R, Vicari E, Calogero AE. Seminal vesicles and diabetic neuropathy: ultrasound evaluation. *J Androl* 2011c;**32**:478–483.

- La Vignera S, Condorelli RA, Vicari E, D'Agata R, Calogero AE. Seminal vesicles and diabetic neuropathy: ultrasound evaluation in patients with couple infertility and different levels of glycaemic control. *Asian J Androl* 2011d; **13**:872–876.
- La Vignera S, Vicari E, Condorelli R, D'Agata R, Calogero AE. Hypertrophic-congestive and fibro-sclerotic ultrasound variants of male accessory gland infection have different sperm output. *J Endocrinol Invest* 2011e; **34**:e330–e335.
- La Vignera S, Calogero AE, Condorelli RA, Vicari LO, Catanusio M, D'Agata R, Vicari E. Ultrasonographic evaluation of patients with male accessory gland infection. *Andrologia* 2012; **44**:26–31.
- La Vignera S, Condorelli RA, Vicari E, Lotti F, Favilla V, Morgia G, Maggi M, Calogero AE. Seminal vesicles and diabetic neuropathy: ultrasound evaluation after prolonged treatment with a selective phosphodiesterase-5 inhibitor. *Andrology* 2013; **1**:245–250.
- Lee JC, Bhatt S, Dogra VS. Imaging of the epididymis. *Ultrasound Q* 2008; **24**:3–16.
- Lenz S. Cancer of the testicle diagnosed by ultrasound and the ultrasonic appearance of the contralateral testicle. *Scand J Urol Nephrol Suppl* 1991; **137**:135–138.
- Lenz S, Giwercman A, Skakkebaek NE, Bruun E, Frimodt-Møller C. Ultrasound in detection of early neoplasia of the testis. *Int J Androl* 1987; **10**:187–190.
- Lenz S, Giwercman A, Elsborg A, Cohr KH, Jønes JE, Carlsen E, Skakkebaek NE. Ultrasonic testicular texture and size in 444 men from the general population: correlation to semen quality. *Eur Urol* 1993; **24**:231–238.
- Lenz S, Thomsen JK, Giwercman A, Hertel NT, Hertz J, Skakkebaek NE. Ultrasonic texture and volume of testicles in infertile men. *Hum Reprod* 1994; **9**:878–881.
- Leung ML, Gooding GA, Williams RD. High-resolution sonography of scrotal contents in asymptomatic subjects. *AJR Am J Roentgenol* 1984; **143**:161–164.
- Li F, Yue H, Yamaguchi K, Okada K, Matsushita K, Ando M, Chiba K, Fujisawa M. Effect of surgical repair on testosterone production in infertile men with varicocele: a meta-analysis. *Int J Urol* 2012; **19**:149–154.
- Liguori G, Trombetta C, Garaffa G, Bucci S, Gattuccio I, Salamè L, Belgrano E. Color Doppler ultrasound investigation of varicocele. *World J Urol* 2004; **22**:378–381.
- Liguori G, Bucci S, Trombetta C, Brkijacic Boris, Bertolotto M. Imaging the infertile male- I: varicocele. In: Bertolotto M, Trombetta C (eds). *Scrotal Pathology. Medical Radiology. Diagnostic Imaging*. Berlin: Springer, 2012, 261–274.
- Lin CC, Huang WJ, Chen KK. Measurement of testicular volume in smaller testes: how accurate is the conventional orchidometer? *J Androl* 2009; **30**:685–689.
- Littrup PJ, Lee F, McLeary RD, Wu D, Lee A, Kumasaka GH. Transrectal US of the seminal vesicles and ejaculatory ducts: clinical correlation. *Radiology* 1988; **168**:625–628.
- Liu PY, Gebiski VJ, Turner L, Conway AJ, Wishart SM, Handelsman DJ. Predicting pregnancy and spermatogenesis by survival analysis during gonadotrophin treatment of gonadotrophin-deficient infertile men. *Hum Reprod* 2002; **17**:625–633.
- Loberant N, Bhatt S, McLennan GT, Dogra VS. Striated Appearance of the Testes. *Ultrasound Q* 2010; **26**:37–44.
- Lotti F, Maggi M. Interleukin 8 and the male genital tract. *J Reprod Immunol* 2013; **100**:54–65.
- Lotti F, Corona G, Mancini M, Biagini C, Colpi GM, Innocenti SD, Filimberti E, Gacci M, Krausz C, Sforza A, Forti G, Mannucci E, Maggi M. The association between varicocele, premature ejaculation and prostatitis symptoms: possible mechanisms. *J Sex Med* 2009; **6**:2878–2887.
- Lotti F, Corona G, Mancini M, Filimberti E, Degli Innocenti S, Colpi GM, Baldi E, Noci I, Forti G, Adorini L et al. Ultrasonographic and clinical correlates of seminal plasma interleukin-8 levels in patients attending an andrology clinic for infertility. *Int J Androl* 2011a; **34**:600–613.
- Lotti F, Corona G, Colpi GM, Filimberti E, Degli Innocenti S, Mancini M, Baldi E, Noci I, Forti G, Adorini L et al. Elevated body mass index correlates with higher seminal plasma interleukin 8 levels and ultrasonographic abnormalities of the prostate in men attending an andrology clinic for infertility. *J Endocrinol Invest* 2011b; **34**:e336–e342.
- Lotti F, Corona G, Colpi GM, Filimberti E, Innocenti SD, Mancini M, Baldi E, Noci I, Forti G, Maggi M. Seminal vesicles ultrasound features in a cohort of infertility patients. *Hum Reprod* 2012a; **27**:974–982.
- Lotti F, Corona G, Krausz C, Forti G, Maggi M. The infertile male-3: endocrinological evaluation. In: Bertolotto M, Trombetta C (eds). *Scrotal Pathology. Medical Radiology. Diagnostic Imaging*. Springer, 2012b, 223–240.
- Lotti F, Corona G, Rastrelli G, Forti G, Jannini EA, Maggi M. Clinical correlates of erectile dysfunction and premature ejaculation in men with couple infertility. *J Sex Med* 2012c; **9**:2698–2707.
- Lotti F, Tamburrino L, Marchiani S, Muratori M, Corona G, Fino MG, Degli Innocenti S, Forti G, Maggi M, Baldi E. Semen apoptotic M540 body levels correlate with testis abnormalities: a study in a cohort of infertile subjects. *Hum Reprod* 2012d; **27**:3393–3402.
- Lotti F, Corona G, Maseroli E, Rossi M, Silverii A, Degli Innocenti S, Rastrelli G, Forti G, Maggi M. Clinical implications of measuring prolactin levels in males of infertile couples. *Andrology* 2013a; **1**:764–771.
- Lotti F, Corona G, Degli Innocenti S, Filimberti E, Scognamiglio V, Vignozzi L, Forti G, Maggi M. Seminal, ultrasound and psychobiological parameters correlate with metabolic syndrome in male members of infertile couples. *Andrology* 2013b; **1**:229–239.
- Lotti F, Corona G, Vignozzi V, Rossi M, Maseroli E, Cipriani S, Gacci M, Forti G, Maggi M. Metabolic syndrome and prostate abnormalities in male subjects of infertile couples. *Asian J Androl* 2014a; **16**:295–304.
- Lotti F, Corona G, Mondaini N, Maseroli E, Rossi M, Filimberti E, Noci I, Forti G, Maggi M. Seminal, clinical and colour-Doppler ultrasound correlations of prostatitis-like symptoms in males of infertile couples. *Andrology* 2014b; **2**:30–41.
- Lund L, Roebuck DJ, Lee KH, Sørensen HT, Yeung CK. Clinical assessment after varicocelelectomy. *Scand J Urol Nephrol* 2000; **34**:119–122.
- Main KM, Schmidt IM, Toppari J, Skakkebaek NE. Early postnatal treatment of hypogonadotropic hypogonadism with recombinant human FSH and LH. *Eur J Endocrinol* 2002; **146**:75–79.
- Matsuda T, Horii Y, Yoshida O. Obstructive azoospermia of unknown origin: sites of obstruction and surgical outcomes. *J Urol* 1994; **151**:1543–1546.
- McDermott VG, Meakem TJ 3rd, Stolpen AH, Schnall MD. Prostatic and periprostatic cysts: findings on MR imaging. *Am J Roentgenol* 1995; **164**:123–127.
- Mearns EM Jr. Infection stones of prostate gland. Laboratory diagnosis and clinical management. *Urology* 1974; **4**:560–566.
- Meschede D, Behre HM, Nieschlag E. Endocrine and spermatological characteristics of 135 patients with bilateral megalotestis. *Andrologia* 1995; **27**:207–212.
- Middleton WD, Thorne DA, Melson GL. Color Doppler ultrasound of the normal testis. *AJR Am J Roentgenol* 1989; **152**:293–297.
- Migaleddu V, Virgilio G, Del Prato A, Bertolotto M. Sonographic scrotal anatomy. In: Bertolotto M, Trombetta C (eds). *Scrotal Pathology. Medical Radiology. Diagnostic Imaging*. Springer, 2012, 41–54.
- Mihmanli I, Kantarci F. Sonography of scrotal abnormalities in adults: an update. *Diagn Interv Radiol* 2009; **15**:64–73.
- Miller FN, Sidhu PS. Does testicular microlithiasis matter? A review. *Clin Radiol* 2002; **57**:883–890.
- Mitchell V, Robin G, Boitrelle F, Massart P, Marchetti C, Marcelli F, Rigot JM. Correlation between testicular sperm extraction outcomes and clinical, endocrine and testicular histology parameters in 120 azoospermic men with normal serum FSH levels. *Int J Androl* 2011; **34**:299–305.
- Miyagawa Y, Tsujimura A, Matsumiya K, Takao T, Tohda A, Koga M, Takeyama M, Fujioka H, Takada S, Koide T et al. Outcome of gonadotropin therapy for male hypogonadotropic hypogonadism at university affiliated male infertility centers: a 30-year retrospective study. *J Urol* 2005; **173**:2072–2075.
- Moon MH, Kim SH, Cho JY, Seo JT, Chun YK. Scrotal US for evaluation of infertile men with azoospermia. *Radiology* 2006; **239**:168–173.
- Nghiem HT, Kellman GM, Sandberg SA, Craig BM. Cystic lesions of the prostate. *Radiographics* 1990; **10**:635–650.
- Nickel JC, Downey J, Hunter D, Clark J. Prevalence of PLS in a population based study using the National Institutes of Health chronic prostatitis symptom index. *J Urol* 2001; **165**:842–845.
- Nielsen KB, Tommerup N, Dyggve HV, Schou C. Macroorchidism and fragile X in mentally retarded males. Clinical, cytogenetic, and some hormonal investigations in mentally retarded males, including two with the fragile site at Xq28, fra(X)(q28). *Hum Genet* 1982; **61**:113–117.
- Nieschlag E, Behre HM. Anamnesis and physical examination. In: Nieschlag E, Behre HM, Nieschlag S (eds). *Andrology. Male Reproductive Health and Dysfunction*, 3rd edn. Chapter 5. Berlin: Springer, 2010, 93–100.
- Nieschlag E, Lammers U, Freischem CW, Langer K, Wickings EJ. Reproductive functions in young fathers and grandfathers. *Clin Endocrinol Metab* 1982; **55**:676–681.
- Nijs SM, Eijssbouts SW, Madern GC, Leyman PM, Lequin MH, Hazebroek FW. Nonpalpable testes: is there a relationship between ultrasonographic and operative findings? *Pediatr Radiol* 2007; **37**:374–379.
- Older RA, Watson LR. Ultrasound anatomy of the normal male reproductive tract. *J Clin Ultrasound* 1996; **24**:389–404.
- Orda R, Sayfan J, Manor H, Witz E, Sofer Y. Diagnosis of varicocele and postoperative evaluation using inguinal ultrasonography. *Ann Surg* 1987; **206**:99–101.
- Oyen RH. Scrotal ultrasound. *Eur Radiol* 2002; **12**:19–34.

- Ozden E, Turgut AR, Dogra VS. Imaging the undescended testis. In: Bertolotto M, Trombetta C (eds). *Scrotal Pathology, Medical Radiology, Diagnostic Imaging*. Springer, 2012, 301–312.
- Pais D, Fontoura P, Esperança-Pina JA. The transmediastinal arteries of the human testis: an anatomical study. *Surg Radiol Anat* 2004;**26**:379–383.
- Palmert MR, Dunkel L. Clinical practice. Delayed puberty. *N Engl J Med* 2012; **366**:443–453.
- Patel B, Gujral S, Jefferson K, Evans S, Persad R. Seminal vesicle cysts and associated anomalies. *BJU Int* 2002;**90**:265–271.
- Pauroso S, Di Leo N, Fulle I, Di Segni M, Alessi S, Maggini E. Varicocele: Ultrasonographic assessment in daily clinical practice. *J Ultrasound* 2011; **14**:199–204.
- Penna G, Mondaini N, Amuchastegui S, Degli Innocenti S, Carini M, Giubilei G, Fibbi B, Colli E, Maggi M, Adorini L. Seminal plasma cytokines and chemokines in prostate inflammation: interleukin 8 as a predictive biomarker in chronic prostatitis/chronic pelvic pain syndrome and benign prostatic hyperplasia. *Eur Urol* 2007; **51**:524–33.
- Pezzella A, Barbonetti A, Micillo A, D'Andrea S, Necozone S, Gandini L, Lenzi A, Francavilla F, Francavilla S. Ultrasonographic determination of caput epididymis diameter is strongly predictive of obstruction in the genital tract in azoospermic men with normal serum FSH. *Andrology* 2013;**1**:133–138.
- Pilatz A, Ruzs A, Wagenlehner F, Weidner W, Altinkilic B. Reference values for testicular volume, epididymal head size and peak systolic velocity of the testicular artery in adult males measured by ultrasonography. *Ultraschall Med* 2013a;**34**:349–354.
- Pilatz A, Wagenlehner F, Bschleipfer T, Schuppe HC, Diemer T, Linn T, Weidner W, Altinkilic B. Acute epididymitis in ultrasound: Results of a prospective study with baseline and follow-up investigations in 134 patients. *Eur J Radiol* 2013b;**82**:e762–768.
- Practice Committee of American Society for Reproductive Medicine. Report on varicocele and infertility. *Fertil Steril* 2008;**90**:S247–249.
- Purvis K, Christiansen E. Infection in the male reproductive tract. Impact, diagnosis and treatment in relation to male infertility. *Int J Androl* 1993;**16**:1–13.
- Raheem OA. Surgical management of adolescent varicocele: Systematic review of the world literature. *Urol Ann* 2013;**5**:133–139.
- Ramchandani P, Banner MP, Pollack HM. Imaging of the seminal vesicles. *Semin Roentgenol* 1993;**28**:83–91.
- Rastrelli G, Corona G, Lotti F, Boddi V, Mannucci E, Maggi M. Relationship of testis size and LH levels with incidence of major adverse cardiovascular events in older men with sexual dysfunction. *J Sex Med* 2013;**10**:2761–2773.
- Rathaus V, Werner M, Freud E, Mei-Zahav M, Mussaffi H, Blau H. Sonographic findings of the genital tract in boys with cystic fibrosis. *Pediatr Radiol* 2006;**36**:162–166.
- Raviv G, Mor Y, Levron J, Shefi S, Zilberman D, Ramon J, Madgar I. Role of transrectal ultrasonography in the evaluation of azoospermic men with low-volume ejaculate. *J Ultrasound Med* 2006;**25**:825–829.
- Ravizzini P, Carizza C, Abdelmassih V, Abdelmassih S, Azevedo M, Abdelmassih R. Microdissection testicular sperm extraction and IVF-ICSI outcome in nonobstructive azoospermia. *Andrologia* 2008;**40**:219–226.
- Raza SA, Jhaveri KS. Imaging in male infertility. *Radiol Clin North Am* 2012;**50**:1183–1200.
- Reddy NM, Gerscovich EO, Jain KA, Le-Petross HT, Brock JM. Vasectomy-related changes on sonographic examination of the scrotum. *J Clin Ultrasound* 2004;**32**:394–398.
- Richenberg J, Brejt N. Testicular microlithiasis: is there a need for surveillance in the absence of other risk factors? *Eur Radiol* 2012;**22**:2540–2546.
- Rives N, Perdrix A, Hennebicq S, Saias-Magnan J, Melin MC, Berthaut I, Barthélémy C, Daudin M, Szyman E, Bresson JL et al. The semen quality of 1158 men with testicular cancer at the time of cryopreservation: results of the French National CECOS Network. *J Androl* 2012;**33**:1394–1401.
- Ron-El R, Strauss S, Friedler S, Strassburger D, Komarovskiy D, Raziel A. Serial sonography and colour flow Doppler imaging following testicular and epididymal sperm extraction. *Hum Reprod* 1998;**13**:3390–3393.
- Rud CN, Dagaard G, Rajpert-De Meyts E, Skakkebaek NE, Petersen JH, Jørgensen N. Sperm concentration, testicular volume and age predict risk of carcinoma *in situ* in contralateral testis of men with testicular germ cell cancer. *J Urol* 2013; **190**:2074–2080.
- Ruzs A, Pilatz A, Wagenlehner F, Linn T, Diemer T, Schuppe HC, Lohmeyer J, Hossain H, Weidner W. Influence of urogenital infections and inflammation on semen quality and male fertility. *World J Urol* 2012;**30**:23–30.
- Sadler TW. *Langman's Medical Embryology*. 12th edn. Philadelphia:Wolters Kluwer Health/Lippincott Williams & Wilkins, 2012.
- Sakamoto H, Ogawa Y. Is varicocele associated with underlying venous abnormalities? Varicocele and the prostatic venous plexus. *J Urol* 2008;**180**:1427–1431.
- Sakamoto H, Ogawa Y. Does a clinical varicocele influence the relationship between testicular volume by ultrasound and testicular function in patients with infertility? *Fertil Steril* 2009;**92**:1632–1637.
- Sakamoto H, Saito K, Shichizyo T, Ishikawa K, Igarashi A, Yoshida H. Color Doppler ultrasonography as a routine clinical examination in male infertility. *Int J Urol* 2006; **13**:1073–1078.
- Sakamoto H, Saito K, Ogawa Y, Yoshida H. Testicular volume measurements using Prader orchidometer versus ultrasonography in patients with infertility. *Urology* 2007a;**69**:158–162.
- Sakamoto H, Saito K, Oohta M, Inoue K, Ogawa Y, Yoshida H. Testicular volume measurement: comparison of ultrasonography, orchidometry, and water displacement. *Urology* 2007b;**69**:152–157.
- Sakamoto H, Ogawa Y, Yoshida H. Relationship between testicular volume and testicular function: comparison of the Prader orchidometric and ultrasonographic measurements in patients with infertility. *Asian J Androl* 2008;**10**:319–324.
- Sarteschi LM, Paoli R, Bianchini M, Menchini Fabris GF. Lo studio del varicocele con eco-color Doppler. *G Ital Ultrasonologia* 1993;**4**:43–49.
- Sartorius GA, Nieschlag E. Paternal age and reproduction. *Hum Reprod Update* 2010; **16**:65–79.
- Sasagawa I, Nakada T, Kazama T, Terada T, Katayama T. Testosterone replacement therapy and prostate/seminal vesicle volume in Klinefelter's syndrome. *Arch Androl* 1989;**22**:245–249.
- Sasagawa I, Nakada T, Kazama T, Satomi S, Terada T, Katayama T. Volume change of the prostate and seminal vesicles in male hypogonadism after androgen replacement therapy. *Int Urol Nephrol* 1990;**22**:279–284.
- Schlegel PN, Goldstein M. Alternate indications for varicocele repair: non-obstructive azoospermia, pain, androgen deficiency and progressive testicular dysfunction. *Fertil Steril* 2011;**96**:1288–1293.
- Schlegel PN, Li-Ming S. Physiological consequences of testicular sperm extraction. *Hum Reprod* 1997;**12**:1688–1692.
- Schlegel PN, Shin D, Goldstein M. Urogenital anomalies in men with congenital absence of the vas deferens. *J Urol* 1996;**155**:1644–1648.
- Schultz KE, Walker J. Testicular torsion in undescended testes. *Ann Emerg Med* 1984; **13**:567–569.
- Schurich M, Aigner F, Frauscher F, Pallwein L. The role of ultrasound in assessment of male fertility. *Eur J Obstet Gynecol Reprod Biol* 2009;**144**:S192–S198.
- Sfanos KS, Wilson BA, De Marzo AM, Isaacs WB. Acute inflammatory proteins constitute the organic matrix of prostatic corpora amyacea and calculi in men with prostate cancer. *Proc Natl Acad Sci USA* 2009;**106**:3443–3448.
- Sharp VJ, Kieran K, Arlen AM. Testicular torsion: diagnosis, evaluation, and management. *Am Fam Physician* 2013;**88**:835–840.
- Shaw J. Diagnosis and treatment of testicular cancer. *Am Fam Physician* 2008; **77**:469–474.
- Shebel HM, Farg HM, Kolokythas O, El-Diasty T. Cysts of the lower male genitourinary tract: embryologic and anatomic considerations and differential diagnosis. *Radiographics* 2013; **33**:1125–1143.
- Shoskes DA, Lee CT, Murphy D, Kefer J, Wood HM. Incidence and significance of prostatic stones in men with chronic prostatitis/chronic pelvic pain syndrome. *Urology* 2007;**70**:235–238.
- Shinbo H, Kurita Y, Takada S, Imanishi T, Otsuka A, Furuse H, Nakanishi T, Mugiya S, Ozono S. Resistive index as risk factor for acute urinary retention in patients with benign prostatic hyperplasia. *Urology* 2010;**76**:1440–1445.
- Silber SJ, Patrizio P, Asch RH. Quantitative evaluation of spermatogenesis by testicular histology in men with congenital absence of the vas deferens undergoing epididymal sperm aspiration. *Hum Reprod* 1990;**5**:89–93.
- Silveira LF, Latronico AC. Approach to the patient with hypogonadotropic hypogonadism. *J Clin Endocrinol Metab* 2013;**98**:1781–1788.
- Simoni M, Nieschlag E. Endocrine laboratory diagnosis. In: Nieschlag E, Behre HM, Nieschlag S (eds). *Andrology. Male Reproductive Health and Dysfunction*, 3rd edn. Berlin: Springer, 2010, 109–118.
- Singh R, Hamada AJ, Bukavina L, Agarwal A. Physical deformities relevant to male infertility. *Nat Rev Urol* 2012;**9**:156–174.
- Skakkebaek NE, Jørgensen N. Testicular dysgenesis and fertility. *Andrologia* 2005; **37**:217–218.
- Sparrow D, Bosse R, Rowe JW. The influence of age, alcohol consumption, and body build on gonadal function in men. *Clin Endocrinol Metab* 1980;**51**:508–512.

- Stearns EL, MacDonnell JA, Kaufman BJ, Padua R, Lucman TS, Winter JSD, Faiman C. Declining testicular function with age. *Am J Med* 1974;**57**:761–766.
- St Sauver JL, Jacobson DJ, Girman CJ, McGree ME, Lieber MM *et al.* Correlations between longitudinal changes in transitional zone volume and measures of benign prostatic hyperplasia in a population-based cohort. *Eur Urol* 2006;**50**:105–111.
- Tajar A, Forti G, O'Neill TW, Lee DM, Silman AJ, Finn JD, Bartfai G, Boonen S, Casanueva FF, Giwercman A *et al.* Characteristics of secondary, primary, and compensated hypogonadism in aging men: evidence from the European Male Ageing Study. *J Clin Endocrinol Metab* 2010;**95**:1810–1818.
- Takahara H, Cosentino MJ, Sakatoku J, Cockett AT. Significance of testicular size measurement in andrology. II. Correlation of testicular size with testicular function. *J Urol* 1987;**137**:416–419.
- Tan MH, Eng C. Testicular microlithiasis: recent advances in understanding and management. *Nat Rev Urol* 2011;**8**:153–163.
- Tanrikut C, McQuaid JW, Goldstein M. The impact of varicocele and varicocele repair on serum testosterone. *Curr Opin Obstet Gynecol* 2011;**23**:227–231.
- Tasian GE, Copp HL. Diagnostic performance of ultrasound in nonpalpable cryptorchidism: a systematic review and meta-analysis. *Pediatrics* 2011;**127**:119–128.
- Tefekli A, Cayan S, Uluocak N, Poyanli A, Alp T, Kadioğlu A. Is selective internal spermatic venography necessary in detecting recurrent varicocele after surgical repair? *Eur Urol* 2001;**40**:404–408.
- Tekgül S, Riedmiller H, Dogan HS, Hoebeke P, Kocvara R, Nijman R, Radmayr Chr, Stein R. *Guidelines on Paediatric Urology, European Association of Urology Guidelines*. Arnhem, The Netherlands: EAU Guidelines Office, 2008.
- Terasaki T, Watanabe H, Kamoi K, Naya Y. Seminal vesicle parameters at 10-year intervals measured by transrectal ultrasonography. *J Urol* 1993;**150**:914–916.
- Tournaye H, Verheyen G, Nagy P, Ubaldi F, Goossens A, Silber S, Van Steirteghem AC, Devroey P. Are there any predictive factors for successful testicular sperm recovery in azoospermic patients? *Hum Reprod* 1997;**12**:80–86.
- Trost LW, Brannigan RE. Oncofertility and the male cancer patient. *Curr Treat Options Oncol* 2012;**13**:146–160.
- Turunc T, Gul U, Haydardedeoglu B, Bal N, Kuzgunbay B, Peskircioglu L, Ozkardes H. Conventional testicular sperm extraction combined with the microdissection technique in nonobstructive azoospermic patients: a prospective comparative study. *Fertil Steril* 2010;**94**:2157–2160.
- Tuttelmann F, Nieschlag E. Classification of Andrological disorders. In: Nieschlag E, Behre HM, Nieschlag S (eds). *Andrology. Male Reproductive Health and Dysfunction*, 3rd edn. Berlin: Springer, 2010, 87–92.
- van Casteren NJ, Looijenga LH, Dohle GR. Testicular microlithiasis and carcinoma in situ overview and proposed clinical guideline. *Int J Androl* 2009;**32**:279–287.
- Vicari E. Seminal leukocyte concentration and related specific reactive oxygen species production in patients with male accessory gland infections. *Hum Reprod* 1999;**14**:2025–2030.
- Vohra S, Morgentaler A. Congenital anomalies of the vas deferens, epididymis, and seminal vesicles. *Urology* 1997;**49**:313–321.
- Walsh TJ, Croughan MS, Schembri M, Chan JM, Turek PJ. Increased risk of testicular germ cell cancer among infertile men. *Arch Int Med* 2009;**169**:351–356.
- Wang C, Nieschlag E, Swerdloff R, Behre HM, Hellstrom WJ, Gooren LJ, Kaufman JM, Legros JJ, Lunenfeld B, Morales A *et al.* (2009) ISA, ISSAM, EAU, EAA and ASA recommendations: investigation, treatment and monitoring of late-onset hypogonadism in males. *Int J Impot Res* 2009;**21**:1–8.
- Westlander G, Ekerhovd E, Granberg S, Lycke N, Nilsson L, Werner C, Bergh C. Serial ultrasonography, hormonal profile and antisperm antibody response after testicular sperm aspiration. *Hum Reprod* 2001;**16**:2621–2627.
- Woodward PJ, Sohaey R, O'Donoghue MJ, Green DE. From the archives of the AFIP: tumors and tumorlike lesions of the testis: radiologic-pathologic correlation. *Radiographics* 2002;**22**:189–216.
- Woodward PJ, Schwab CM, Sesterhenn IA. From the archives of the AFIP: extratesticular scrotal masses: radiologic-pathologic correlation. *Radiographics* 2003;**23**:215–240.
- World Health Organization. *WHO Laboratory Manual for the Examination and Processing of Human Semen*, 5th edn. Geneva, Switzerland: WHO press, 2010.
- Yee WS, Kim YS, Kim SJ, Choi JB, Kim SI, Ahn HS. Testicular microlithiasis: prevalence and clinical significance in a population referred for scrotal ultrasonography. *Korean J Urol* 2011;**52**:172–177.
- Yu J, Chen Z, Ni Y, Li Z. CFTR mutations in men with congenital bilateral absence of the vas deferens (CBAVD): a systemic review and meta-analysis. *Hum Reprod* 2012;**27**:25–35.
- Zhao H, Luo J, Wang D, Lu J, Zhong W, Wei J, Chen W. The value of transrectal ultrasound in the diagnosis of hematospermia in a large cohort of patients. *J Androl* 2012;**33**:897–903.
- Ziaee SA, Ezzatnegad M, Nowroozi M, Jamshidian H, Abdi H, Hosseini Moghaddam SM. Prediction of successful sperm retrieval in patients with nonobstructive azoospermia. *Urol J* 2006 Spring;**3**:92–96.
- Zini A, Boman JM. Varicocele: red flag or red herring? *Semin Reprod Med* 2009;**27**:171–178.