

# ULTRASOUND STUDY OF EMPHATICS, UVULARS, PHARYNGEALS AND LARYNGEALS IN THREE ARABIC DIALECTS

Majed AL-SOLAMI

Department of Linguistics, University of Toronto, Toronto, Ontario

## Résumé

Différentes études présentent des mécanismes différents et, dans une certaine mesure, inconsistants en ce qui a trait aux sons uvulaires, pharyngés et laryngés, c'est-à-dire les sons dits gutturaux et emphatiques. Les études les plus récentes font usage d'imagerie ultrasonore de la langue afin d'observer les articulations jouant un rôle dans la prononciation des phonèmes gutturaux et emphatiques de trois dialectes arabes, soit l'égyptien, le saoudien et le palestinien. Ces études ont pour but de répondre à la question suivante : quelles formes prend la langue lorsqu'elle produit des sons /ʕ, ħ, ʁ, ʁ, q/ à rétraction intrinsèque et des sons /ðʕ, sʕ, tʕ, dʕ/ à rétraction secondaire? Les résultats articulatoires indiquent que ces sons sont produits à l'aide des différentes racines de la langue et des mécanismes de rétraction de la partie postérieure de la langue. Les consonnes pharyngales sont articulées en rétractant les racines de la langue et n'impliquent aucune rétraction marquée des racines de la langue. Les sons uvulaires et emphatiques présentent une rétraction de la partie postérieure de la langue et une rétraction inconsistante des racines de la langue. Les sons laryngés ne présentent aucune rétraction marquante de la langue.

**Mots clefs :** ultrasonore, dialectes arabes, emphatiques, uvulaires, pharyngés, laryngés

## Abstract

Different studies show different and to some extent inconsistent mechanisms for the articulation of Arabic uvular, pharyngeal and laryngeal sounds, i.e. gutturals, and emphatic sounds. The current study uses ultrasound imaging of the tongue to examine the articulations involved in guttural and emphatic sounds in three Arabic dialects, Egyptian, Saudi and Palestinian. This investigation attempts to answer the question: what are the tongue shapes during the production of both inherently retracted /ʕ, ħ, ʁ, q/ and secondarily retracted /ðʕ, sʕ, tʕ, dʕ/ sounds. Articulatory results indicate that these sounds are produced with different tongue root and tongue dorsum retraction mechanisms. Pharyngeals are articulated with tongue root retraction and statistically do not involve significant tongue dorsum retraction. Uvulars and emphatics show tongue root and tongue dorsum retraction with inconsistent tongue root retraction. Laryngeals do not show any significant tongue retraction.

**Keywords:** ultrasound, Arabic dialects, emphatics, uvulars, pharyngeals, laryngeals

## 1 Introduction

Arabic has a number of sounds that involve post-velar retraction. This retraction is inherent in some sounds, pharyngeals and uvulars and secondary in others, emphatics<sup>1</sup>, as shown in Table 1. Analyses of the secondary articulation vary from one study to another. It is accepted, however, that the secondary articulation is a result of the retraction of the tongue body.

**Table 1:** Arabic gutturals and emphatics phonemes

	Dental	Alveolar	Uvular	Pharyngeal	Glottal
Plosives		tʕ dʕ	q		ʔ
Fricatives	ðʕ	sʕ	ʁ ʁ	ħ ʕ	h

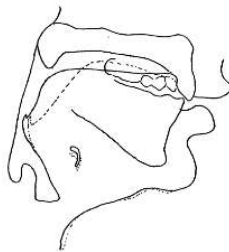
Arabic emphatics are articulatorily similar to their non-emphatic counterparts in their primary coronal constriction. Emphatics differ from plain coronals in their secondary articulation. Despite the advancement in the methods used

in investigating these sounds, the secondary articulation in emphatics is difficult to pinpoint. This is due partly to cross-dialectal variation and partly to different methodologies used in the investigation. It is possible, however, that there is no consistent single articulatory exponent of emphasis. Rather, speakers have different articulatory strategies to produce emphatics, which are influenced by dialect, gender, phonological context and social variables (Khattab et al. 2006).

Modern studies show that, beside their primary coronal articulation, all Arabic emphatics have a secondary articulation involving the back of the tongue. Ghazeli (1977) pointed that the tongue body is pulled backwards into the upper oropharynx during the articulation of [tʕ] and the tongue body is depressed during the emphatic consonant but not during the plain coronal as can be seen in Figure 1. In their cinefluorographic study of Iraqi Arabic, Ali & Daniloff (1972) found emphatics to be articulated with simultaneous depression of the tongue and a rearward movement of the tongue dorsum towards the posterior wall of the pharynx. They found that the difference between emphatics and non-

<sup>1</sup> Emphatics are assumed to be pharyngealized at this point

emphatics is that the former class involves a retraction of the tongue dorsum causing a narrowing in the upper pharynx. They also reported that the posterior wall of the pharynx and the velum were not significantly implicated in the articulation of emphatics. The tongue dorsum depression in emphatics was first reported by Ibn Sina (1037 A.D) where he suggested that emphatics are articulated with a depressed tongue surface behind the main articulation point (Semaan 1963). This point is confirmed in other studies (Ali & Daniloff (1972) in Iraqi Arabic; Ghazeli (1977) in Tunisian Arabic; Al-Tamimi & Heselwood (2011) in Jordanian Arabic.



Solid line represents the articulation of /tˤ/  
Dotted line represents the articulation of /t/

**Figure 1:** Articulations of emphatic /tˤ/ and /t/, from Ghazeli (1977) page 69

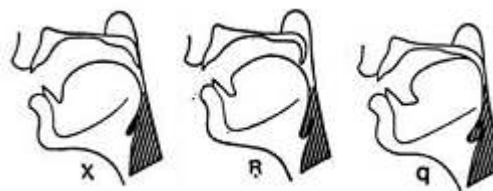
The precise location of the secondary constriction in Arabic emphatics does not seem to be an area of agreement among articulatory studies in Arabic. Ghazeli (1972) found that the tongue back retraction into the upper pharynx takes place at the level of the second cervical vertebra while Giannini & Pettorino (1982) reported that the constriction takes place at the level of the third vertebra.

Another point of disagreement is the implication of tongue root and epiglottis in the production of Arabic emphatics. Due to this controversial point, researchers have posited that emphatics are uvularized in Jordanian Arabic (Zawaydeh 1999), velarized in Lebanese Arabic (Obrecht 1968) and pharyngealized in Iraqi Arabic (Ali & Daniloff 1972; Gianni & Pettorino 1982). During the articulation of emphatics Ali & Daniloff (1972) and Ghazeli (1977) reported a constriction in the upper pharynx achieved by a retraction of the tongue body while little to no adjustments take place in the lower pharynx. Ghazeli (1977) reported that there is an accompanying backward movement of the epiglottis but no adjustments in the laryngopharynx. Giannini & Pettorino (1982) indicated that the aryepiglottic muscle, which moves the epiglottis backwards, is not implicated in the articulation of Arabic emphatics. Laufer & Baer (1988) suggested that the pharyngeal constriction is less extreme and less consistent in emphatics compared to pharyngeals. Shar (2012) in his MRI study of Saudi Arabic showed that emphatics are produced with dorsal retraction of the tongue, which causes consistent narrowing of the upper part of the pharyngeal cavity; however, the tongue root is not involved in this narrowing gesture. In their video-fluoroscopic study of emphatics in Jordanian Arabic, Al-

Tamimi & Heselwood (2011) found that during the articulation of emphatics, the tongue root is seen to press against the anterior surface of the epiglottis, pushing the epiglottis towards the back of the pharynx. However, they suggested that the larynx is raised in emphatics, which means that the pharyngeal volume is reduced. Consequently, it is difficult to judge in the already reduced pharynx whether the tongue root/epiglottis movement is independent or a result of the tongue dorsum retraction. Accordingly, tongue root retraction in emphatics appears to be a mechanical consequence of tongue dorsum retraction.

The coarticulatory effect of emphatics on neighboring vowels was examined in many studies. The most frequently observed effect is a lowered F2 value. Al-Ani (1970) found a considerable F2 onset drop in vowels following emphatic consonants compared to plain coronals. Ghazeli (1977) reported that all vowels have a lower F2 after emphatics as opposed to non-emphatics. Similar results are reported in other studies (Obrecht 1968; Giannini & Pettorino 1982; Khattab et al. 2006; Bin-Muqbil 2006; Shar 2012). A raised F1 is also noticed but not in all studies. Al-Ani (1970) and Hassan (1981) indicated that F1 is raised in vowels after emphatic consonants. However, Bin-Muqbil (2006) found that F1 values after emphatic consonants were not significantly higher than those after non-emphatic coronals in all vowel contexts. He found that while F1 values of vowel [i] after emphatics were significantly higher than non-emphatic coronals, they showed no significance in vowel [a] and showed some variation in vowel [u].

Delattre (1971) described the production of Arabic uvulars [χ, ʁ, q] using X-ray frames of one speaker of Lebanese Arabic. He reported that during the articulation of uvulars, the tongue slides backwards then moves upwards to create a constriction in the upper pharynx, as seen in Figure 2.



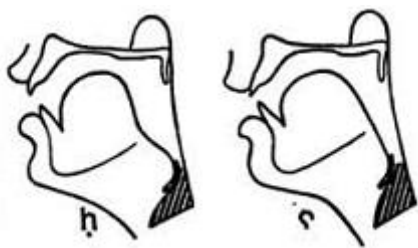
**Figure 2:** Tracings of the articulation of Arabic uvulars [χ], [ʁ] and [q], from Delattre (1971) page 130

Ghazeli (1977) reported that the anterior wall of the pharynx as well as the epiglottis are pulled backwards towards the posterior wall of the pharynx during [χ] and [q], but not [ʁ]. The tongue is backed the most during [q]. Accordingly, the pharyngeal volume above the epiglottis is smaller during [q] than during [ʁ] or [χ]. This is due to the manner of articulation of [q] which entails a complete closure to fulfill the occlusive nature of the consonant.

Uvulars have similar coarticulatory effects to emphatics in which they lower F2 values in adjacent vowels. However, the size of the effects in uvulars is less than in emphatics. Compared to plain coronals, Al-Ani (1970) found that Arabic uvulars [χ, ʁ, q] have lower F2 values in adjacent

vowels with [q] showing the strongest effect. He did not report the effects on F1 values. Ghazeli (1977) suggested that emphatics caused lower F2 values in following vowels [i] and [a] while uvulars caused lower F2 values in following vowel [u]. Similar results were reported in (Ghazeli 1977; Obrecht 1968; Bin-Muqbil 2006; Shar 2012). Bin-Muqbil (2006) reported that uvulars have higher F1 values when compared to plain coronals. However, F1 values were not always significant. F1 values of the vowel [i] were significantly higher after [q] and [ʁ] compared to plain consonants, however, after [χ] F1 value of vowel [i] was not significantly different from plain consonants. Also, F1 values of vowel [a] after [q] and [ʁ] were not significantly different than plain consonants while F1 values of vowel [u] showed no significant difference after all uvulars.

Delattre (1971) indicated that Arabic pharyngeals are articulated by retracting the tongue root towards the posterior wall of the pharynx, as shown in Figure 3. Ghazeli (1977) reported similar results. He added that the constriction during the voiceless pharyngeal [h] is narrower than for [ʕ]. This is expected since the voiceless pharyngeal fricative requires a narrow constriction to produce enough friction.



**Figure 3:** Tracings of the articulation of Arabic pharyngeals, [h] & [ʕ] from Delattre (1971) page 130

The nature of the active articulator of pharyngeals is controversial. While Laufer & Condax (1979) suggested that the epiglottis retracts independently from the rest of the tongue, including the tongue root, Boff-Dkhissi (1983) and Laufer & Baer (1988) challenged this claim and showed that the tongue root and the epiglottis covary with each other.

The most frequently observed effect of pharyngeals on neighboring vowels is a rise in F1 (Al-Ani 1970; Ghazeli 1977; Butcher & Ahmad 1987; Zawaydeh 1999; Bin-Muqbil 2006; Shar 2012). Bin-Muqbil (2006) suggested that F2 values in vowels [i], [a] and [u] after pharyngeals are not significantly different than those after plain consonants in almost all cases. Other studies indicated some variation in F2 values after pharyngeals (Al-Ani 1970; Ghazeli 1977; Butcher & Ahmad 1987; Zawaydeh 1999).

The two Arabic laryngeals are articulated at the larynx with a fully open glottis in [h] or fully constricted glottis in [ʔ]. Laufer & Condax (1979) found no evidence of any constriction in the pharynx during the articulation of the two laryngeals in bilingual speakers of Palestinian Arabic and Hebrew. Zawaydeh (1999) concluded in her fiberoptic study of Jordanian Arabic that laryngeals [h, ʔ] show no constriction in the pharynx. She suggested that the pharynx

during Arabic laryngeals is as wide as it is during the production of plain coronal sounds. Using laryngoscopy to examine Jaffa dialect spoken in Northern Palestine, Shahin (2011) found that the two laryngeals were produced with no aryepiglottic constriction and no retraction of the tongue root or epiglottis. The [h] of the speaker in her study was like the [ʔ] except with a triangular opening between the vocal folds.

Al-Ani (1970) found that laryngeals have no coarticulatory effect on following vowels. Similarly, Bin-Muqbil (2006) found that next to [a], laryngeals showed high F1; however, no such effect is reported next to vowels [i] or [u]. Zawaydeh (1999) suggested that laryngeals in Jordanian Arabic have higher F1 values compared to plain coronals, however, no such conclusion was reported in any other study.

The additional parameter of larynx height contributes significantly to pharyngeal volume and sound quality in Arabic gutturals and emphatics. Raising the larynx reduces the volume of the pharyngeal cavity. Such action would result in converging F1 and F2 frequencies. Lowering the larynx, on the other hand, would elongate the vocal tract and lowers all formants. Larynx height is reported differently in different studies for different sounds. The larynx is suggested to be raised in emphatics in Jordanian Arabic by about 4-7 mm (Al-Tamimi & Heselwood 2011), similar results were reported by Al-Tamimi et al. (2009). Hassan & Esling (2011) reported that the larynx is lowered in Iraqi Arabic, which is different from the findings of Al-Tamimi & Heselwood (2011). However, the methodology of Hassan & Esling (2011), a laryngoscopic study, is not optimal in assessing vertical changes in the larynx. They relied on auditory examination of the tokens to reach the conclusion that the larynx is lowered during emphatics in Iraqi Arabic. During the production of pharyngeals the larynx was observed to ascend by approximately 9 mm relative to the rest position (Ghazeli, 1977). Similar results were reported in (Bucher & Ahmad 1987; Elgendy 2001; Heselwood 2007).

Thus far, it has been suggested that the articulation of Arabic emphatics and uvulars involve retracting the tongue dorsum. Tongue root retraction in these sounds is questioned. It has been indicated that the tongue root does not actively retract in these sounds; rather it retracts as a result of the retraction of the tongue dorsum. Emphatics and uvulars differ, however, in the direction of tongue dorsum retraction and in tongue depression behind the point of main articulation in emphatics. Furthermore, it has been suggested that pharyngeals are articulated with a retracted tongue root while laryngeals do not involve tongue retraction in their articulation. A summary of hypotheses regarding Arabic emphatics and gutturals articulation is presented in Table 2.

**Table 2:** Summary of Arabic emphatics and gutturals articulation hypotheses

1	Arabic emphatics and uvulars share a physical property of tongue dorsum retraction.
2	Emphatics are articulated with a depressed tongue surface behind the main articulation while uvulars lack such a gesture.
3	Emphatics and uvulars retract tongue root as a consequence of tongue dorsum retraction; therefore, tongue root retraction in these sounds is not consistent.
4	Pharyngeals are articulated with a retracted tongue root.
5	Laryngeals do not show any form of tongue retraction.

To test these hypotheses, this study will focus on examining tongue root (TR), tongue dorsum (TD) and tongue body (TB) retraction in laryngeals, pharyngeals, uvulars and emphatics. To achieve this point, this study implements ultrasound technology. All modern descriptions of Arabic emphatic sounds used methodologies that are good for investigating movements in the pharynx. However, it is impossible to see using endoscopy whether the tongue back/dorsum is raised or lowered during the articulation (Hassan & Esling 2011). Ultrasound technology, on the other hand, is optimal for viewing the posterior and anterior parts of the tongue. For the purpose of this paper, it is hypothesized that tongue retraction is the main articulatory component of these sounds and they differ in the degree and direction of retraction. It is expected that these sounds will have different mechanisms of tongue retraction.

The use of ultrasound is limited and still at early stages in Arabic literature. Among the recent studies is an EMA, endoscopic and ultrasound study performed by (Zeroual *et al.* 2011). They provided data from Moroccan Arabic, MA, speakers in order to answer a number of questions. The relevant point is the question related to the nature of secondary articulation in MA emphatics. They compared the properties of MA emphatic coronals /tʰ, dʰ, sʰ/ with their plain counterparts /t, d, s/, uvulars and pharyngeals. For the ultrasound study they recruited two MA speakers. They used words and nonsense words containing emphatic sounds. Their aim was to observe the tongue, and the epiglottis. (Zeroual *et al.* 2011) found that the articulation of emphatics is more similar to uvulars than pharyngeals. Also, emphatic sounds involved a backward movement of the tongue towards the posterior pharyngeal wall while pharyngeals involved backward movement of the tongue and the epiglottis. They suggest that ultrasound technology is not capable of detecting movements of tongue root in pharyngeals. This point is discussed further in the results.

## 2 Method

### 2.1 Participants

Three participants were included in this experiment, one Egyptian Arabic speaker, EA, one Saudi Arabic speaker, SA, and one Palestinian Arabic speaker, PA. All participants spoke their respective dialect natively and reported no speech or hearing impairment.

### 2.2 Stimuli

The stimuli in this experiment consisted of fifteen nonsense words with the form ʔaCCa in which the geminate consonants belonged to the sounds under examination, as shown in Table 3. Geminate consonants were chosen because the rate of ultrasound system used only gives 15 frames per second, thus geminating the segments gives a longer duration of the consonants so the frames can be extracted more easily. The target consonants were preceded and followed by a low vowel [a]. These words were chosen to represent plain coronals, emphatics, uvulars, pharyngeals and laryngeals.

**Table 3:** Ultrasound experiment stimuli

Emphatics	ʔaðˤðˤa	ʔasˤsˤa	ʔatˤtˤa	ʔadˤdˤa
Plain coronals	ʔaðða	ʔassa	ʔatta	ʔadda
Uvulars	ʔaxxa	ʔaxxa		
	ʔaqqa			
Pharyngeals	ʔaʕʕa	ʔahha		
Laryngeals	ʔahha	ʔaʔʔa		

### 2.3 Equipment and procedure

The data were collected using a PI 7.5 MHz *SeeMore* ultrasound probe by *Interson*, connected through a USB port to a computer and recorded on DVD recorder. The depth was set to 10 cm to provide the best visual information and temporal resolution. A non-toxic water based gel was applied to the probe to prevent air from intervening between the surface of the probe and the skin (Stone 1997). The audio signal was recorded using an *AT831b* lavalier microphone via an XLR cable connected to a *SOUND DEVICES USBPre2* pre-amplifier and transferred to the DVD recorder for synchronization with the video. Figure 4 shows the equipment used in the experiment.



**Figure 4:** Ultrasound equipment (1: Ultrasound probe, 2: PC-TV converter, 3: DVD recorder, 4: SOUND DEVICES USBPre2 pre-amplifier)

Ultrasound probe movements were restricted as much as possible. Tongue measurements can be improved by limiting unwanted movements (Gick *et al.* 2005). To maintain transducer stability, the ultrasound transducer was attached a long microphone boom arm. To attain transducer stability further, participants were asked to rest their head

against a wall behind them and to look at a marked dot in front of them, as shown in Figure 5.



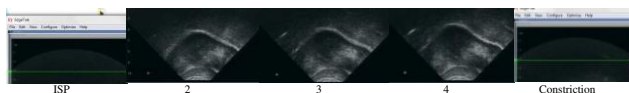
**Figure 5:** Probe setting with non-participant human model

Recording for the participants took place in a quiet booth at the Department of Linguistics Phonetics Lab at the University of Toronto. Prior to the recording session, the participant read the stimuli to ensure correct reading of the words. Because the focus of this study is to investigate the articulations made in the posterior region of the vocal tract, the probe of the ultrasound was adjusted to capture the best angle of the tongue root, dorsum and body. When the participant was seated in the manner explained previously, a trial of the stimuli was carried out, this helped in getting the needed image of the tongue in the ultrasound screen. Once the needed angle was specified, the participant read the list of the words shown on an iPad screen.

## 2.4 Data preparation and analysis

For data analysis purposes, using MPEG Streamclip freeware program, with a rate of 30 frames per second, still frames from each repetition of the 15 words for each participant were extracted. Also, a frame was extracted from every pause between repetitions. This pause was used to extract inter-speech rest position of the tongue, ISP. For each token, the frame corresponding to the maximum constriction for the relevant gesture was identified as the highest position or the lowest position of the tongue. The highest position and lowest position is systematically selected as the frame that occurs in mid gemination.

ISP frames are used to assess the degree and direction of tongue retraction of a particular consonant. For this study, ISP frame is the frame that occurs in inter-utterance speech rest position. This frame is identified by Gick et al. (2004) as the speech posture to which articulators return between utterances. This frame occurs 4 to 5 frames before the constriction frame. Figure 6 shows a set of sample frames for the emphatic [s<sup>ɛ</sup>] in token [ʔas<sup>ɛ</sup>s<sup>ɛ</sup>a].



**Figure 6:** Frames extracted from ultrasound video for a sample emphatic [s<sup>ɛ</sup>] in token [ʔas<sup>ɛ</sup>s<sup>ɛ</sup>a]. The tongue tip is on the right.

The freeware EdgeTrak (Stone 2005; Li, Kambhamettu & Stone 2005) was used to trace tongue contours for each frame. Then .con files (a text file that contains a set of xy coordinate points for each contour) were saved and converted into Excel files and reformatted for R text. The analysis was done using Smoothing Spline ANOVA

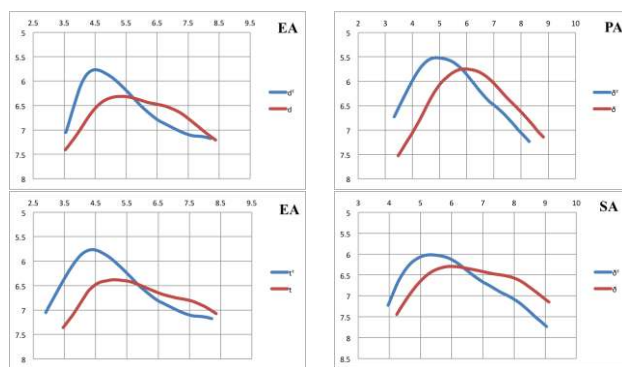
(SS-ANOVA) in R (R Development Core Team 2013) (cf. Davidson 2006).

## 3 Results

In this section the results of the ultrasound experiment are presented. In order to show how these sounds differ in tongue retraction mechanisms, the following subsections discuss the results of comparing emphatics [ð<sup>ɛ</sup>, s<sup>ɛ</sup>, t<sup>ɛ</sup>, d<sup>ɛ</sup>] with plain coronals [ð, s, t, d], uvulars [χ, ʁ, q] with ISP, uvulars with emphatics, pharyngeals [ħ, ʕ] with ISP, laryngeals [h, ʔ] with ISP and finally examining tongue root retraction in emphatics and uvulars compared to pharyngeals. This is motivated partly by hypotheses given in Table 2 and partly by providing explanations for the coarticulatory effects of these sounds on adjacent vowels in terms of tongue shapes. It should be noted that in all the figures the tongue tip is at the right and units are in mm. For simplicity purposes, in each subsection only selected figures from each speaker are discussed and all relevant figures are given in the appendices section<sup>2</sup>.

### 3.1 Emphatics

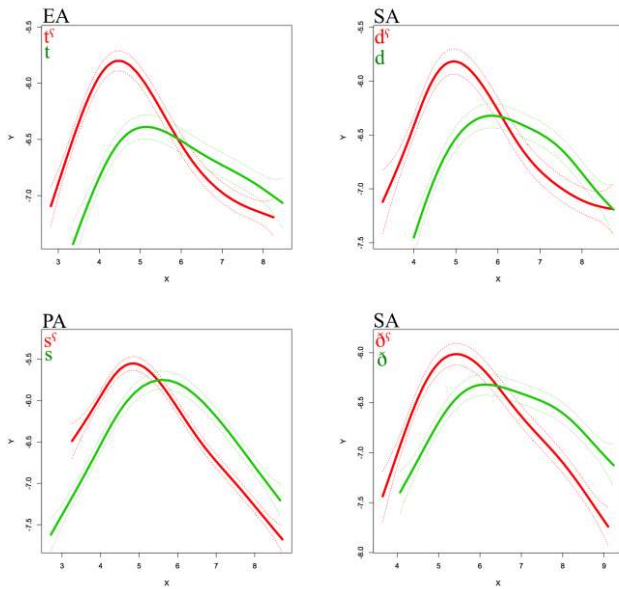
Comparing emphatic consonants [ð<sup>ɛ</sup>, s<sup>ɛ</sup>, t<sup>ɛ</sup>, d<sup>ɛ</sup>] with their plain coronal counterparts [ð, s, t, d] the tongue dorsum is more raised and retracted as shown in Figure 7. Complete comparisons are given in Appendix A. Also, despite some articulatory variability, the tongue blade behind the point of main constriction is depressed during emphatics. This point is illustrated further in SS-ANOVA graphs in Figure 8, where the significant difference between two tongue contours is plotted as the area where the dotted lines, which indicate the 95% confidence interval, do not overlap (Davidson 2006). Complete SS-ANOVA comparisons between emphatics [ð<sup>ɛ</sup>, s<sup>ɛ</sup>, t<sup>ɛ</sup>, d<sup>ɛ</sup>] and plain coronals [ð, s, t, d] are given in Appendix B.



**Figure 7:** Average tracings of emphatics [ð<sup>ɛ</sup>, s<sup>ɛ</sup>, t<sup>ɛ</sup>, d<sup>ɛ</sup>] and plain coronals [ð, s, t, d]

<sup>2</sup> All appendices can be found on this website <http://msolami.kau.edu.sa/> under publications





**Figure 8:** SS-ANOVA tongue-contour graphs of emphatics [δʰ, sʰ, tʰ, dʰ] and plain coronals [δ, s, t, d]

### 3.2 Uvulars and ISP

The posterior part of the tongue in uvular consonants [χ, ʁ, q] compared to ISP is more raised and relatively more backed as shown in Figure 9. The constriction location is more posterior for [ʁ] than for [χ] in Egyptian and Palestinian Arabic speakers and the constriction point is more posterior for [χ] than for [ʁ] in Saudi speaker. The uvular stop [q] in Egyptian and Palestinian Arabic speakers has a more raised tongue dorsum compared to the other two uvulars [χ, ʁ].

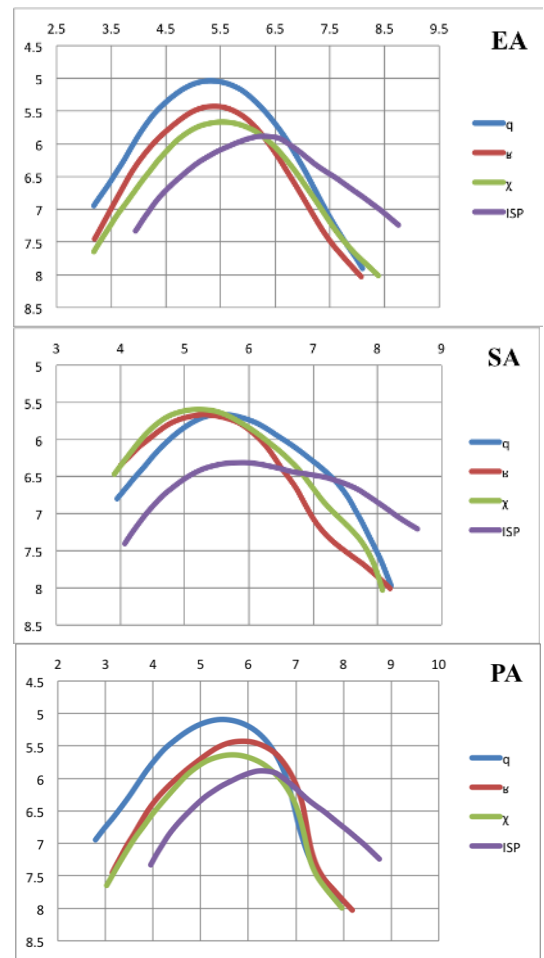
### 3.3 Uvulars and emphatics

Comparing uvulars to emphatics, as illustrated in Figure 10, it can be seen that the anterior part of the tongue in uvular consonants is not depressed compared to emphatics. Also, the back of the tongue is generally moved vertically towards the uvula area during uvulars but horizontally slid backwards during emphatics. This is consistent for all uvular-emphatic comparisons, which are given in Appendix C.

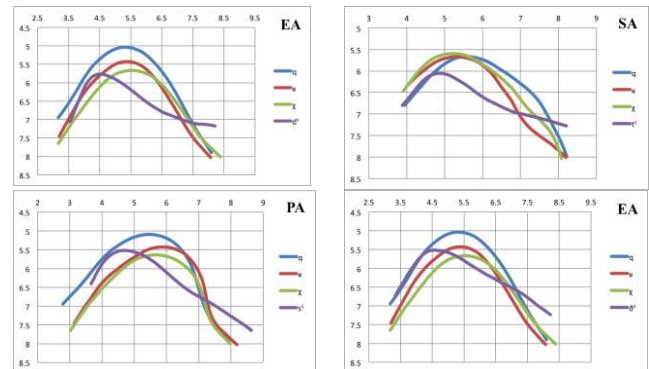
### 3.4 Pharyngeals and ISP

In pharyngeals [ħ, ʕ] the tongue root shows more retraction compared to ISP, as given in Figure 11. Tongue dorsum and the anterior part of the tongue are very similar in voiceless pharyngeal [ħ] and ISP. During the articulation of voiced pharyngeal [ʕ], the tongue blade assumes a curved pyramidal shape almost like an inverted “V”, especially in the Egyptian Arabic speaker and the Saudi Arabic speaker, as shown in Figure 12 where pharyngeal [ʕ] is compared to ISP.

As shown in Figure 13, tongue contours of laryngeals [h, ʔ] do not show noticeable differences compared to their ISP.



**Figure 9:** Average tracings of uvulars [χ, ʁ, q] and ISP



**Figure 10:** Average tracings of uvulars [χ, ʁ, q] and emphatics [δʰ, sʰ, tʰ, dʰ]

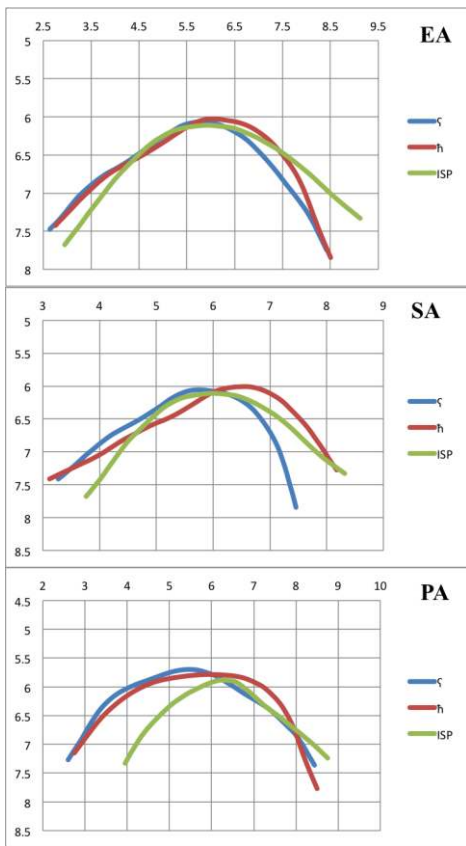


Figure 11: Average tracings of pharyngeals [h, ʕ] and ISP

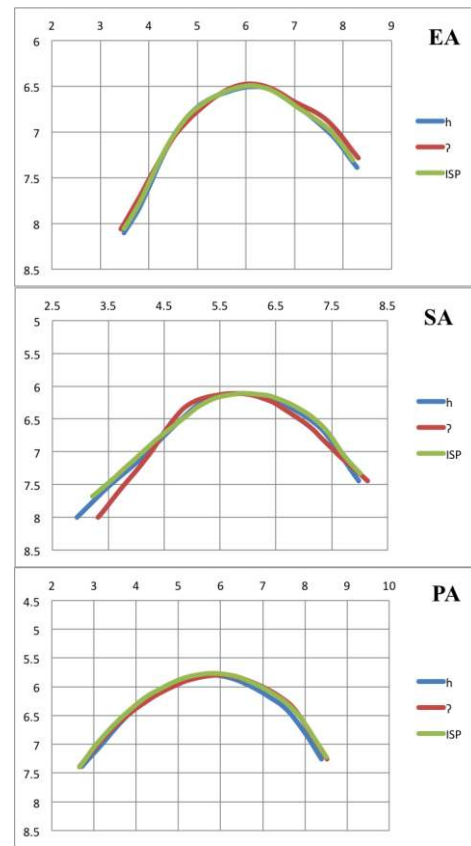


Figure 13: Average tracings of laryngeals [h, ʔ] and ISP

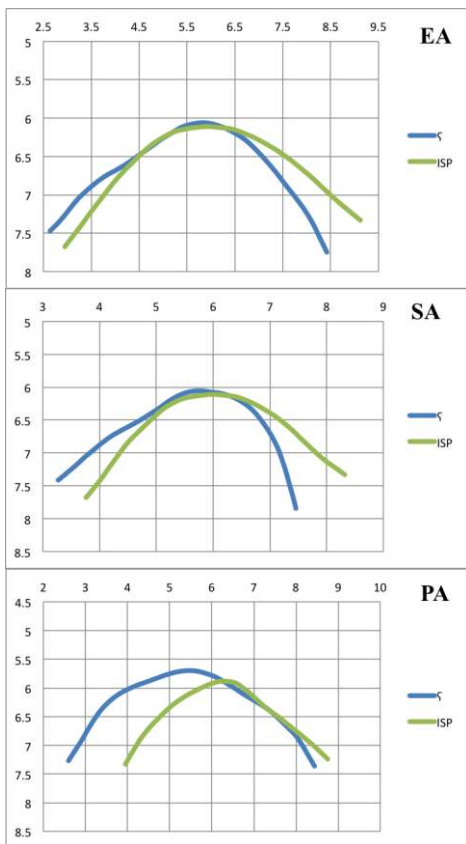
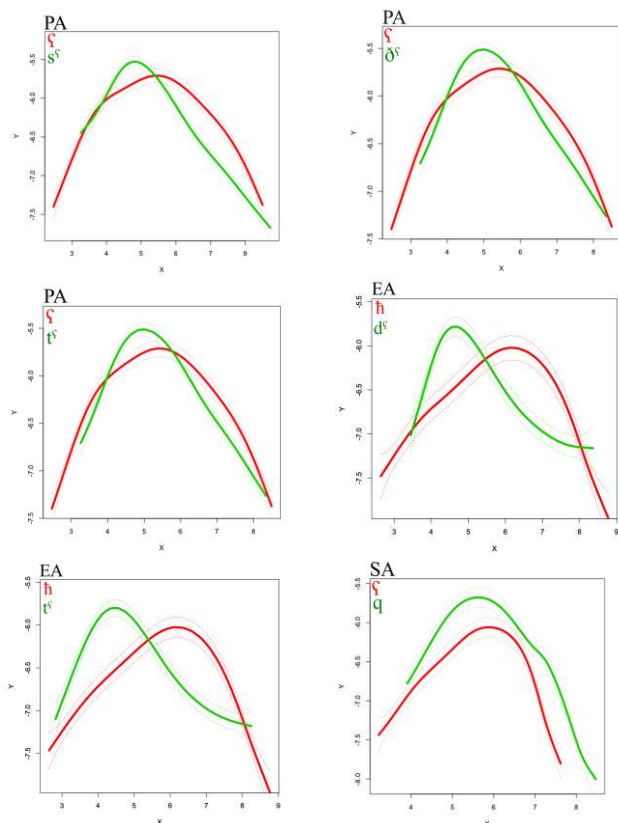


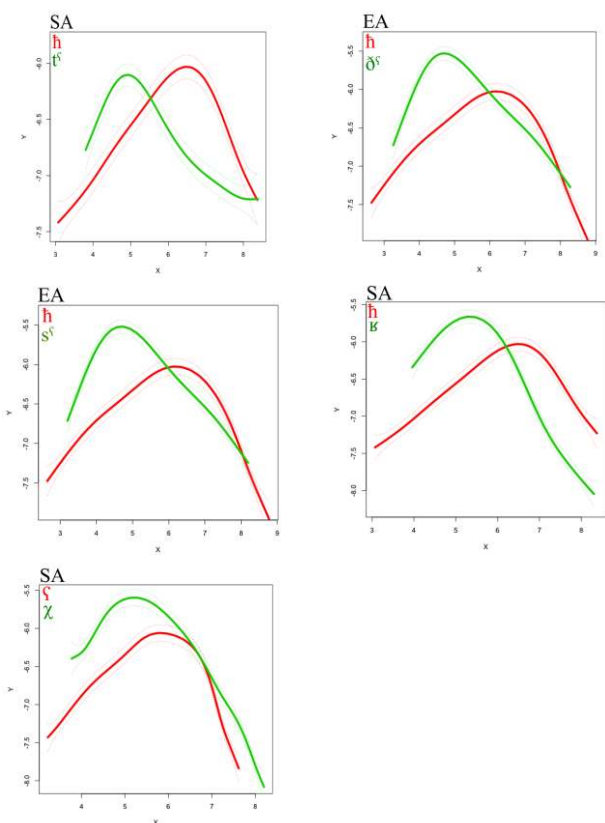
Figure 12: Average tracings of pharyngeal [ʕ] and ISP

### 3.5 Tongue root comparisons between emphatics and uvulars and pharyngeals

Despite the fact that ultrasound system does not show the entire tongue root area due to the obstruction of the hyoid bone, when comparing tongue root movement in images obtained from the ultrasound experiment we can get a general idea about the degree of tongue root retraction. Generally speaking, tongue contours show some differences in the degree of tongue root retraction among pharyngeals and emphatics and uvulars. In Figures 14 & 15, SS-ANOVA is used to compare the tongue root retraction in pharyngeals with that in emphatics and uvulars. In Figure 14 the tongue root is similarly retracted for emphatics, uvulars and pharyngeals, while in Figure 15 tongue root retraction degree is different in the three classes of sound. This suggests that tongue root retraction mechanism in these sounds is different. For the complete emphatic-uvular-pharyngeal comparisons see Appendix D.



**Figure 14:** SS-ANOVA tongue-contour graphs of pharyngeals, emphatics and uvulars



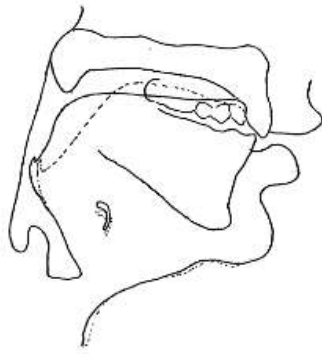
**Figure 15:** SS-ANOVA tongue-contour graphs of pharyngeals, emphatics and uvulars

## 4 Discussion

As previously mentioned in Table 2, it is hypothesized that Arabic emphatics and uvulars share a physical property of tongue dorsum retraction. In the results of the ultrasound experiment, as shown in Figures 6 & 7, the tongue dorsum in emphatics is more raised and retracted compared to their coronal counterparts. This is expected since the secondary articulation in emphatics involves pulling the tongue into the upper oropharynx area (Ali & Daniloff 1972; Ghazeli 1977). Comparing uvular consonants [χ, ʁ, q] to their ISP, Figure 8 illustrates that the tongue in uvulars is more raised and relatively more backed. This shape of the tongue in uvulars is a result of moving the rear-most portion of the tongue surface towards the posterior soft palate and the uvula (Catford 1977). Figure 8 also indicates that the constriction location is more posterior for [ʁ] than for [χ] in the Egyptian Arabic speaker and Palestinian Arabic speaker while the constriction point is more posterior for [χ] than for [ʁ] in Saudi Arabic speaker. This difference was also given in Ghazeli (1977) who reported that the constriction point is more posterior for [ʁ] than for [χ], whereas Delattre (1971) found the opposite. However, the tongue position in emphatics and uvulars is different as suggested by Figure 9. While the back of the tongue is generally moved vertically towards the uvula area during uvulars, it moves horizontally during emphatics. This suggests that the articulation mechanisms in these two subsets of sounds are different. The vertical movement in uvulars is due to the constriction between tongue dorsum and the soft palate. Catford (1977) terms the articulation of uvulars as *dorso-uvular*. For emphatics, on the other hand, the tongue moves horizontally to achieve a constriction at the oropharynx area. It is for this tongue movement that Al-Ani (1970) favored pharyngealization over velarization as the proper description for the secondary emphatic articulation. Zeroual et al. (2011) reported based on endoscopic pictures that the back of the tongue moves towards a higher position during [q] and intermediate during [ʕ] which provides a further support for the difference between the two sound categories.

Furthermore, it is hypothesized that emphatics are articulated with a depressed tongue surface behind the main articulation point while uvulars lack such a gesture. The results in Figures 6, 7 & 9 show that behind the point of main constriction the tongue is depressed during the articulation of emphatics, which was reported by Ibn Sina (Avicenna), (d. 1037 A.D) (Semaan 1963); Ali & Daniloff (1972) in Iraqi Arabic; Ghazeli (1977) in Tunisian Arabic; Al-Tamimi and Heselwood (2011) in Jordanian Arabic. Figure 1, repeated in Figure 16 below, from Ghazeli (1977) clearly shows the depression of the tongue during emphatic [ʕ]. Uvulars, on the other hand, do not show similar tongue shape, as illustrated in Figures 9 & 10.





Solid line represents the articulation of /tʕ/  
Dotted line represents the articulation of /t/

**Figure 16:** Articulations of emphatic /tʕ/ and /t/ in Tunisian Arabic, from Ghazeli (1977) page 69

As expected, the tongue root region in pharyngeals [h, ʕ] shows more retraction degree compared to ISP, as given in Figure 11. Also, the tongue assumes a pyramidal shape during the articulation of pharyngeal [ʕ], as shown in Figure 12. This is reported by Delattre (1971); Ghazeli (1977) and Elgendi (2001). However, these studies did not explain why the tongue assumes such a shape in the voiced pharyngeal [ʕ] only and whether such a gesture would have any coarticulatory effects.

As given in Table 2, it is hypothesized that tongue contours of laryngeals [h, ʔ] do not show noticeable differences compared to their ISP, as illustrated in Figure 12. Zawaydeh (1999) reported that the pharyngeal area during the articulation of the two Arabic laryngeals is as wide as it is during the articulation of plain oral sounds. Zeroual et al. (2011) concluded that compared to laryngeal [h] the back of the tongue is more posterior during [tʕ, ʕ, q, h].

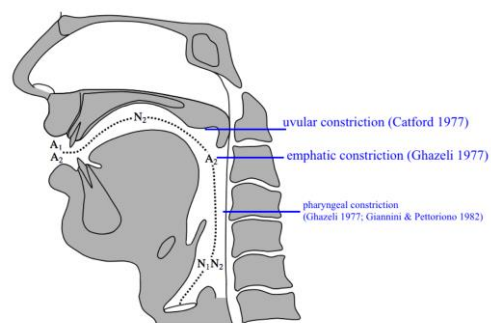
It was suggested in Table 2 that emphatics and uvulars retract tongue root as a consequence of tongue dorsum retraction; therefore, tongue root retraction in these sounds is not consistent. Figures 14 & 15 show that the tongue root retraction degree is similar in pharyngeals, emphatics and uvulars in some instances and significantly different in others. The articulation of pharyngeals [h, ʕ] is characterized by a retraction of tongue root and slight forward displacement of the posterior wall of the pharynx, resulting in a place of articulation at the level of the epiglottis (Ghazeli 1977). As far as the pharynx and tongue root are concerned, they do not play an active part in the production of emphatics (Norlin 1987). Instead, it is the tongue dorsum, which by a backing movement causes the constriction. It seems that the tongue root retraction in emphatics is a by-product of the general retraction of the tongue dorsum and not an independent gesture. The variation in tongue root retraction in uvulars is reported by Ghazeli (1977) in which he indicated that the tongue root and the epiglottis are pulled backward towards the posterior wall of the pharynx during [χ] and [q], but not during [ʁ].

Therefore, the variation in tongue root retraction degree given in Figures 14 & 15 might be a result of tongue root inconsistent retraction in emphatics and uvulars. This is also supported by the acoustic properties of these sounds.

According to resonance models, F1 correlates with the amount of constriction in the oropharyngeal area of the vocal tract (Kent & Read 1992; Pickett 1999). Therefore, the greater the constriction in the front oral portion of the vocal tract, achieved by raising the tongue body which reduces the oral space and expands the pharyngeal space, then the lower F1 will become. Accordingly, F1 values will increase when the tongue body is lowered, which lessens the pharyngeal cavity. In other words, the more the pharyngeal area is, the lower F1 will become. Tongue body height also impacts the pharyngeal cavity of the vocal tract. According to Pickett (1999), lowering the tongue body would force the tongue volume towards the pharyngeal wall, which results in tongue root retraction, both of which will raise F1. For that reason, F1 is affected by tongue body height and tongue root retraction.

F2 is correlated with constriction in the oropharyngeal region of the vocal tract. The location of the constriction and the resultant length of the oral cavity in front of the constriction affect F2 (Pickett 1999). A constriction in the front area of the oral cavity shortens the cavity in front of the constriction and lengthens the pharyngeal cavity, which results in a rise in F2. A constriction further back in the oral cavity lengthens the cavity anterior to the constriction and shortens the pharyngeal cavity, which lowers F2. In other words, the shorter oral cavity with the forward tongue position resonates at a higher F2 frequency and the longer the oral cavity becomes as the tongue is retracted, the lower the frequency that will be resonated. Therefore, F2 is correlated with the location of the tongue body in the front-back dimension.

According to the perturbation theory of Chiba and Kajiyama (1958), a constriction at or near the antinode of a certain formant lowers the formant and a constriction near the formant node causes that formant to be raised. Widening nodes and antinodes have the opposite effect. Therefore, widening a point near an antinode of a formant causes the formant to be increased, while widening a point near a node of a formant causes the formant to be lowered. Points of the nodes and antinodes for F1 and F2 are illustrated in Figure 17.



**Figure 17:** Locations of nodes & antinodes for F1 & F2, adapted from (Bin-Muqbil 2006) page 11

The acoustic studies mentioned in the introduction show that the coarticulatory acoustic effects of emphatics on neighboring vowels distinguish them from their non-emphatic coronals. The main acoustic effect of emphatics on adjacent vowels is a drop in F2 transitions compared to plain coronals. Uvulars, like emphatics, also lower F2 transitions in adjacent vowels. However, the size of F2 drop next to uvulars is not as low as that next to emphatics.

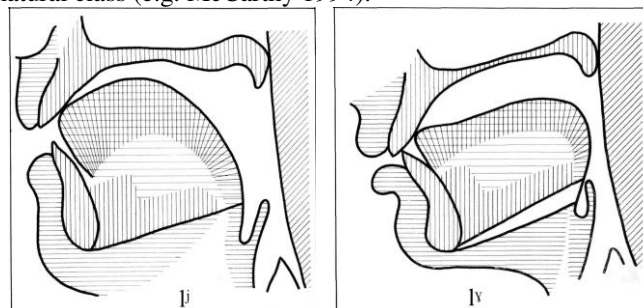
A low F2 value next to emphatics and uvulars is due to constricting an area that coincides with F2 antinode, as shown in Figure 17. Emphatics are associated with lower F2 transition values than uvulars because the point of constriction in emphatics is further back compared to uvulars. As indicated by Figure 7, the point of constriction in emphatics requires further backing of the tongue dorsum towards the upper pharynx, which results in more constriction near F2 antinode. Furthermore, the depression of tongue blade area associated with emphatics, as shown in Figures 7 & 8, coincides with F2 node. The widening of formant node, as suggested by perturbation theory, causes the formant values of the vowel to decrease. Another physiological parameter that lowers F2 in emphatics is lowering the larynx, which is suggested by Hassan & Esling (2011), which elongates the vocal tract. No such adjustment in the larynx was reported for uvulars. These findings support the hypotheses that Arabic emphatics and uvulars both trigger low F2 values in adjacent vowels and that emphatics have lower F2 values in adjacent vowels compared to uvulars.

Pharyngeals are associated with higher F1 values in all adjacent vowels compared to plain coronals. These sounds are articulated with a narrow constriction at the lower part of the pharynx which corresponds to the node of F1 explaining the high values of that formant, as can be seen in Figure 17. Furthermore, raising the larynx during pharyngeals, as reported by (Ghazeli 1977; Bucher & Ahmad 1987; Elgendy 2001; Heselwood 2007), reduces the volume of the pharyngeal cavity, which further increases F1 frequencies.

Laryngeals show no coarticulatory effects on F1 or F2. This outcome in laryngeals is expected since laryngeals do not have any supraglottal adjustments (Zawaydeh 1999; Shar 2012).

The nature of the secondary articulation in Arabic emphatics is a point of disagreement in Arabic literature. This is reflected in different descriptions of Arabic emphatics in different studies. Emphatic consonants have been described differently in different dialects. Emphatics have been termed uvularized in Jordanian Arabic, velarized in Lebanese Arabic and pharyngealized in Iraqi Arabic. Based on the findings of this study, pharyngealization is not an accurate characterization of the secondary articulation in emphatics. Emphatics do not share acoustic correlates or articulatory properties with pharyngeals. Emphatics are associated with low F2 while pharyngeals are associated with high F1 in adjacent vowels. Furthermore, the point of constriction is achieved by tongue root in the lower pharynx in pharyngeals while emphatics are articulated with tongue dorsum retraction to the upper oropharynx. Uvularization,

on the other hand, is possible. However, in addition to the fact that no other language is reported to have uvularized consonants besides Arabic, the use of the term uvularization to describe emphatics is problematic since the tongue dorsum retraction in emphatics is different than that in uvulars, as suggested by Figure 10 and reported in many studies such as Al-Ani (1970) and Ghazeli (1977). Velarization is characterized with lowering F2 and F1 is generally not affected (Ladefoged & Maddieson 1996). For the lack of a better term, velarization seems to be relatively the least problematic term compared to pharyngealization and uvularization because velarized consonants in other languages, such as Russian, are phonetically similar to Arabic emphatics. Figure 18 shows X-ray tracings of Russian velarized [ɮ] with its palatalized counterpart [ɮʲ] (Bolla 1981). Russian velarized [ɮ], which Bolla (1981) refers to as ‘pharyngealized’, retracts tongue dorsum to the upper pharynx, which is very similar tongue retraction mechanism to Arabic emphatics. This mechanism is accompanied with a decrease in F2 values in adjacent vowels (Ladefoged & Maddieson 1996). As a result, the secondary articulation in Arabic emphatics should be referred to as velarization instead of pharyngealization or uvularization. Perhaps a more suitable term is a one that indicates that Arabic emphatics are retracted to the oropharynx area. Such term would exclude emphatics from being associated with uvulars or pharyngeals, which has bearings on Arabic phonology in which many studies suggest that emphatics are not a subclass of Arabic guttural natural class (e.g. McCarthy 1994).



**Figure 18:** Tongue configurations during [ɮʲ] & [ɮ], Bolla (1981), pages 78 & 80

## 5 Conclusion

The experiment focuses on tongue movements during the articulations of Arabic emphatic and guttural sounds. The use of ultrasound provides good images for the tongue dorsum movement, which is important in distinguishing emphatic from uvular consonants. Results indicate that tongue dorsum retraction is different in these two sound categories. While in uvulars the tongue dorsum moves vertically towards the uvula, it moves horizontally in emphatics towards the oropharynx region. Furthermore, emphatics showed tongue depression behind the main articulation point, which is absent in uvulars. Also, ultrasound technology captures enough of the tongue root to indicate the similarities and differences between pharyngeal consonants and emphatic and uvular consonants in terms of

tongue root retraction that can provide further evidence for the variation in tongue root retraction in emphatics and uvulars compared to pharyngeals.

Besides including more participants in future work on Arabic emphatics and gutturals, Arabic sounds can be examined using an ultrasound machine that gives better frame rate. The ultrasound probe used in this study provided reliable images, however, 15 frames per second rate is slower than North American standard, which is 30 fps. To overcome this limitation, geminated consonants are used in the ultrasound stimuli. Another point that warrants more investigation is the effect of gender on emphasis in Arabic as reported in Wahba (1993) for Egyptian Arabic as well as in Khattab et al. (2006) for Jordanian Arabic. A point of uncertainty in this paper is the involvement of the epiglottis in the articulation of Arabic retracted consonants. It is impossible to see the epiglottis, and difficult to see the part of the tongue root that is obscured by the hyoid bone shadow. This could be avoided by including an additional suitable method of examining the lower part of the pharynx such as endoscopy. The study had not included palate images, which will make the exact point of passive articulators more accurate to measure. Finally, a cross-linguistic articulatory comparison of post-velar sounds is needed in order to gain solid understanding of Arabic emphatics and gutturals.

## References

- [1] Al-Ani, S. (1970). "Arabic phonology; an acoustical and physiological investigation". The Hague: Mouton.
- [2] Ali, L.H., Daniloff, R.E. (1972). "A contrastive cinefluorographic investigation of the articulation of emphatic-non-emphatic cognate consonants". *Studia Linguistica* 26, 81-105.
- [3] Al-Nassir, A. (1993) "Sibawayh the Phonologist" London and New York: Keegan Paul International.
- [4] Alwan, A. (1989). "Perceptual cues for place of articulation for the voiced pharyngeal and uvular consonants". *Journal of the Acoustical Society of America*, 86, 549-556.
- [5] Bin-Muqbil, M. (2006). "Phonetic and phonological aspects of Arabic emphatics and gutturals". PhD dissertation, University of Wisconsin-Madison.
- [6] Catford, J.C. (1977). "Fundamental Problems in Phonetics." Edinburgh University Press.
- [7] Chiba, T. & Kajiyama, M. (1941). "The vowel: its nature and structure". Tokyo-Kaiseikan.
- [8] Delattre, P. (1971). "Pharyngeal features in the consonants of Arabic, German, Spanish, French, and American English." *Phonetica*, 23, 129-155.
- [9] Ghazeli, S. (1977). "Back Consonants and Backing Coarticulation in Arabic". PhD, Univ. Texas at Austin.
- [10] Giannini, A., Pettorino, M. (1982). "The emphatic consonants in Arabic". Speech Laboratory Report IV, Istituto Universitario Orientale di Napoli.
- [11] Gick, B. I. Wilson, K. Koch, and C. Cook. (2004). "Language-specific articulatory settings: Evidence from inter-utterance rest position." *Phonetica*, 61 (4): 220-233.
- [12] Gouda, A. (1988). "Quraanic Recitation: Phonological Analysis". Ph.D. dissertation. Georgetown University.
- [13] Hamid, A. (1984). "The phonology of Sudanese Arabic". Urbana: University of Illinois Ph.D. dissertation.
- [14] Hassan, Z M and Esling, J (2008) "Investigating the Emphatic Feature in Iraqi Arabic: Acoustic and Articulatory Evidence of Co-articulation" Forthcoming in *Instrumental Studies in Arabic Phonetics*. Hassan & Heselwood. Editors. John Benjamin.
- [15] Jakobson, R. (1957). "Mufaxxama – the emphatic phonemes in Arabic: synchronic and diachronic aspects". In: Pulgram, E. (ed), *Studies Presented to Joshua Whatmough*. The Hague: Mouton, 105-115.
- [16] Johnson, Keith (2004). "Acoustic and Auditory Phonetics" 2nd ed. Oxford: Blackwell.
- [17] Kent, R. D., Read, C., & Kent, R. D. (1992). "The acoustic analysis of speech" (Vol. 58). San Diego: Singular Publishing Group.
- [18] Ladefoged, Peter. (2001). "A Course in Phonetics", 4 edition. U.S.A.: Thomson Wadsworth.
- [19] Ladefoged, P, and Maddieson, I. (1996). "The sounds of the world's languages". Oxford: Blackwell.
- [20] Laradi, Widad (1983) "Pharyngealization in Libyan (Tripoli) Arabic" PhD, dissertation, University of Edinburgh
- [21] Laufer, A., Baer, T. (1988). The emphatic and pharyngeal sounds in Hebrew and Arabic. *Lang. & Speech* 24, 39-61.
- [22] McCarthy, J. (1994). "The phonetics and phonology of Semitic pharyngeals". In P. Keating (ed.), *Phonological Structure and Phonetic Form: Papers in Laboratory Phonology III*. Cambridge: Cambridge University Press.
- [23] Namdaran, N. (2006). "Retraction in St'at'imcets: An Ultrasound Investigation." University of British Columbia, MA Thesis
- [24] Ohala, J. J. (1990). "There is no interface between phonetics and phonology. A personal view." *Journal of Phonetics*. 18. 153-171. Trubetskoï, N. (1969). *Principles of phonology*. Berkeley: University of California Press.
- [25] Pickett, J. M. (1999). "The acoustics of speech communication: Fundamentals, speech perception theory, and technology". Allyn & Bacon.
- [26] Stone, M. (1997). "Laboratory techniques for investigating speech articulation". In *Handbook of Phonetic Sciences*. eds. William Hardcastle and John Laver, 11-32. Oxford: Blackwell Publishers.
- [27] Zawaydeh, B. (1997). "An acoustic analysis of uvularization spread in Ammani-Jordanian Arabic". *Studies in the Linguistic Sciences*, 27, 185-200.
- [28] Zawaydeh, B. (1998). "Gradient uvularisation spread in Ammani-Jordanian Arabic". In: Benmamoun, A., Eid, M., Haeri, N. (eds), *Perspectives on Arabic Linguistics 11*. Amsterdam: John Benjamins, 117-141.
- [29] Zawaydeh, B. (1999). "The phonetics and phonology of gutturals in Arabic", Ph.D. Dissertation, Indiana University.
- [30] Zeroual, C., Esling, J.H., and Hoole, P. (2011). "EMA, endoscopic, ultrasound and acoustic study of two secondary articulations in Moroccan Arabic: labial-velarization vs. emphasis." In Zeki Majeed Hassan and Barry Heselwood (eds.), *Instrumental Studies in Arabic Phonetics*, pp. 277-297. John Benjamins

## VIBRATION MONITORING TERMINAL – TYPE 3680

# GOOD VIBRATIONS



Reliably take real-time measurements with our new Vibration Monitoring Terminal. The robust device enables you to:

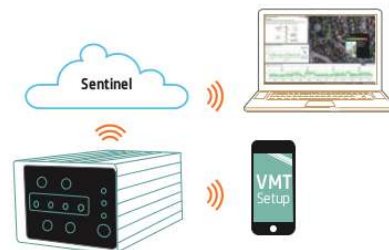- Protect against structural damage risks in construction and mining
- Assess human response to road and rail traffic vibration
- Monitor background vibration to avoid sensitive machinery disturbance

The Vibration Monitoring Terminal includes metrics for a wide range of applications. The system provides continuous, uninterrupted, real-time monitoring 24/7. Alerts are based on level and time of day. It contains a single tri-axial geophone for full coverage of vibration levels, and built-in remote access so you don't need to visit a site to retrieve data.

Use the unit with our Sentinel environmental monitoring service or as a stand-alone device.

See more at [www.bksv.com/VMT](http://www.bksv.com/VMT)

**Brüel & Kjær**   
BEYOND MEASURE



**Brüel & Kjær North America Inc.**  
3079 Premiere Parkway, Suite 120  
Duluth, GA 30097  
Tel: 770 209 6907

[bkinfo@bksv.com](mailto:bkinfo@bksv.com)

[www.bksv.com/VMT](http://www.bksv.com/VMT)

BN 1914 - 12