




REPORTS OF MORPHOLOGY

Official Journal of the Scientific Society of Anatomists,
Histologists, Embryologists and Topographic Anatomists
of Ukraine

journal homepage: <https://morphology-journal.com>



Ultrastructural reorganization of the constituent components of the rat periodontium under conditions of chronic opioid exposure

Fik V. B.¹, Podoliyk M. V.¹, Matkivska R. M.²

¹Danylo Halytsky Lviv National Medical University, Lviv, Ukraine

²O.O. Bogomolets National Medical University, Kyiv, Ukraine

ARTICLE INFO

Received: 21 June 2022

Accepted: 20 July 2022

UDC:

616.311.2+616.314.17):615.212.7]-
019-076.4

CORRESPONDING AUTHOR

e-mail: fikvolodymyr@ukr.net

Fik V. B.

CONFLICT OF INTEREST

The authors have no conflicts of interest to declare.

FUNDING

Not applicable.

Opioid addiction has acquired the characteristics of an epidemic in recent years and is a serious problem in modern medicine. In users of narcotic substances, a significant prevalence of diseases of the oral cavity and periodontal tissues is noted in comparison with the general population. The aim of the work was to investigate the ultrastructural organization of the periodontal tissues of rats at the end of the fourteenth week of the experimental opioid effect. The animals were administered intramuscularly, daily, once, the opioid analgesic nalbuphine (pharmacotherapeutic group: analgesics, opioids, morphinan derivatives) in increasing doses for 14 weeks: 1-2 weeks - 0.212 mg/kg, 3-4 weeks - 0.225 mg/kg, 5-6 weeks - 0.252 mg/kg, 7-8 weeks - 0.260 mg/kg, 9-10 weeks - 0.283 mg/kg; 11-12 - 0.300 mg/kg, 13-14 weeks - 0.450 mg/kg. At the end of the fourteenth week of opioid exposure, ultrastructural changes in the epithelium of the mucous membrane of the gums, periodontium, and hemomicrovessels with the development of decompensation and pronounced dystrophic-destructive changes were established. With the long-term effect of an opioid analgesic, signs of karyorrhexis, segregation of nucleoli, spongiosis, apoptosis, violation of the integrity of intercellular contacts, as well as vacuole-like formations, which were a manifestation of focal necrosis of epitheliocytes, were revealed. The development of necrotic changes was caused by significant damage and destruction of organelles, as well as fragmentation or lysis of bundles of tonofilaments. The intercellular spaces were mostly expanded and uneven, which was caused by edematous phenomena. Fragmentation and destruction of periodontal collagen fibers, destructive changes in fibrocytes and fibroblasts were found in the periodontium. The translucency of the amorphous component of the intercellular substance of the connective tissue was determined. The ultrastructural reorganization of the cellular components of the periodontium was caused by vascular disorders of a systemic nature, which were manifested by the phenomena of dilatation, hemoptysis, sludge phenomenon, dystrophic changes in the endotheliocytes of hemocapillaries and venules, and the progression of sclerotic changes, which significantly disturbed the trophism of the periodontal tissues of rats.

Key words: opioid influence, rats, periodontium, ultrastructural study.

Introduction

Opioid addiction has acquired the characteristics of an epidemic in recent years and is a serious problem in modern medicine [6, 18, 19]. Chronic use of narcotic substances leads to addiction, when there is a need for higher doses, after all, the constant and long-term use of opioids in 23 % of people leads to the development of opioid addiction [1, 19]. In view of this, experimental models for the purpose of studying the action of opioids, namely, the study of their analgesic potential, side effects, behavioral reactions, as well as their effects on various organs and

systems, are of increasing interest recently [7, 8, 12, 17].

It should be noted that among users of narcotic substances, a significant prevalence of diseases of the oral cavity is noted, in comparison with the general population [9, 11, 20]. Taking into account the fact that the constituent components of the periodontium react quite distinctly to the action of various factors and homeostasis disturbances, the study of pathological changes in the oral cavity of addicted persons is relevant [21, 23]. The researchers note that comprehensive knowledge about

the condition of the organs and tissues of the oral cavity in opioid-dependent persons can ensure the effectiveness of diagnostic and therapeutic measures [5, 10, 22].

Analysis of modern scientific data shows that the problem of the pathogenesis of inflammatory and dystrophic periodontal diseases remains unsolved [4, 14, 15]. The reflection of the pathomorphological picture in the periodontal tissues is a rather complex process, and changes occur after a certain period of time with the involvement of various mechanisms of pathogenesis [2, 3, 13, 16]. In this regard, the study of pathomorphological changes at the ultrastructural level in the organs of the oral cavity, periodontal tissues, which develop against the background of the long-term effect of opioid agents, is undoubtedly an urgent problem today.

The aim of the study was to find out the peculiarities of the submicroscopic organization of the tissues of the periodontal complex at the end of the fourteenth week of the experimental action of the opioid analgesic nalbuphine.

Materials and methods

The study was conducted on 17 white outbred male rats of reproductive age, body weight 160 - 270 g. In the experiment, the animals were divided into two groups. The I group - control rats (5), which were injected with physiological solution during the experiment. In the II group of animals (12), the opioid analgesic nalbuphine (pharmaceutical group: analgesics, opioids, morphine derivatives) was administered intramuscularly, daily, once, at the same time interval (10-11 a.m.) in increasing doses for 14 weeks: 1-2 weeks - 0.212 mg/kg, 3-4 weeks - 0.225 mg/kg, 5-6 weeks - 0.252 mg/kg, 7-8 weeks - 0.260 mg/kg, 9-10 weeks - 0.283 mg/kg; 11-12 - 0.300 mg/kg, 13-14 weeks - 0.450 mg/kg [11].

All animals were kept in a vivarium and work on keeping, care, labeling and all the other manipulations were carried out in compliance with the provisions of the European Convention for the Protection of Vertebrate Animals used for experimental and other scientific purposes (Strasbourg, 1985). The Commission on Bioethics of Danylo Halytskyi Lviv National Medical University has stated that the study meets ethical requirements in accordance with the order of the Ministry of Health of Ukraine No. 231 of 01.11.2000 (Protocol No. 10 of 24.05.2021).

For electron microscopic examination, pieces of periodontal soft tissue in the area of the gingival margin of the jaws were used, which were immediately immersed in a large drop of 2.5 % glutaraldehyde solution diluted in 0.1 M phosphate buffer (pH 7.36) with sucrose. Pieces were cut from the strips, tissue blocks were transferred to tubes with a fixing solution of the same composition. Subsequently, tissue blocks were fixed with a 2 % solution of osmium tetroxide in 0.1 M phosphate buffer (pH 7.36) with the addition of sucrose. For dehydration and preparation for impregnation with water-insoluble resins, fabric blocks washed from the remains of fixatives were passed through alcohols of

increasing concentration. Fabric blocks were immersed in epon-araldite by passing through solutions of increasing resin concentration. Ultrathin sections were prepared on a YMTT-3M ultramicrotome using glass knives. For the study, sections of silver or gently lemon color were selected and contrasted in a 2 % solution of uranyl acetate, and then lead citrate. Studying and photographing the material was carried out with the help of an electronic microscope ПЕМ-100-01 (Ukraine) at magnifications of 1500x - 20000x on the microscope screen.

Results

Electron microscopic examination of rats of the I (control) group revealed layer-by-layer arrangement of gingival epithelium cells, clear and even contours of nuclei, and a low density of organelles in the cytoplasm were established. Ordered bundles of collagen fibers, intercellular substance and cells of the fibroblastic series are visualized in the periodontium. In the hemomicrovessels, a clear organization of endothelial cells, intercellular contacts, and small perivascular spaces containing constituent components of connective tissue has been established.

At the ultrastructural level, after 14 weeks of opioid exposure, significant changes were found in the studied periodontal components of laboratory animals. In the epitheliocytes of the basal layer of the free part of the gums, uneven contours of the nuclei are determined, the karyolemma forms rather deep intussusceptions, and karyorrhexis phenomena are observed in some places. The perinuclear space is of uneven width, in some places significantly expanded. Nucleoli are not detected in the electron light karyoplasm. In some areas, the contours of the plasmalemma are vaguely traced. Violation of the integrity of intercellular contacts, their significant reduction in individual areas was revealed. In places, intercellular contacts are visualized in the form of osmiophilic clusters. The intercellular spaces are mostly expanded and uneven, which is caused by edematous phenomena due to excessive fluid accumulation. In the karyolemma of the spinous layer of cells of the epithelium of the free part of the gums, deep intussusceptions were found, in the karyoplasm there are segregated components of nucleoli (Fig. 1). Vacuole-like formations are observed in structureless illuminated areas of the cytoplasm, which is a sign of the development of partial focal cell necrosis. Organelles in the cytoplasm are mostly damaged, destroyed cristae and a lighted matrix are found in swollen mitochondria. Bundles of tonofilaments have vague contours, mostly thickened. Electron-dense inclusions of keratohyalin of various sizes are visualized in the cytoplasm of the granular layer of epitheliocytes of the free part of the gums.

The contours of the nuclei of the epithelium of the gingival sulcus are uneven, the karyolemma forms multiple intussusceptions. Nucleoli are not detected in the illuminated karyoplasm. Organelles in the cytoplasm of epitheliocytes of the basal layer are destructively changed. In most of the

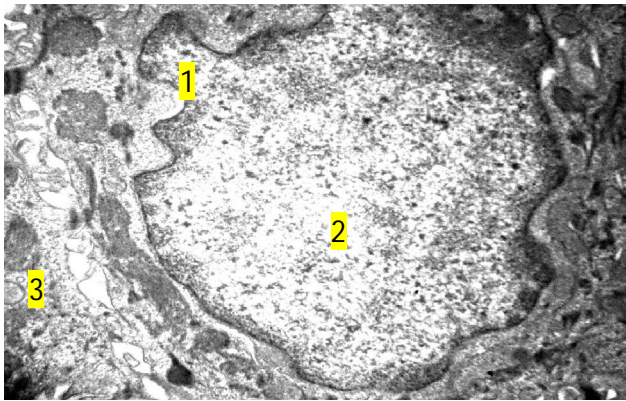


Fig. 1. Ultrastructural changes in the epithelium of the free part of the gingiva of a rat under conditions of 14-week opioid exposure. Intussusceptions of the karyolemma of the epitheliocyte of the spinous layer (1), segregation of the nucleolus (2), vacuole-like formations (3). x9000.

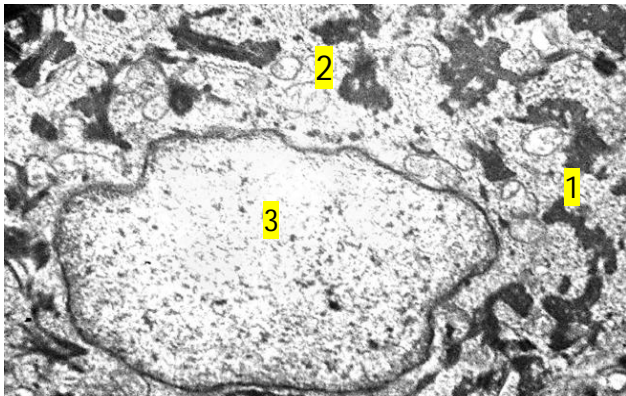


Fig. 2. Ultrastructural changes in the epithelium of the gingival sulcus of the rat under conditions of 14-week opioid exposure. Structureless osmiophilic inclusions in the cytoplasm of the epitheliocyte of the basal layer (1), vacuolization of mitochondria (2), clarification of the karyoplasm (3). x12000.

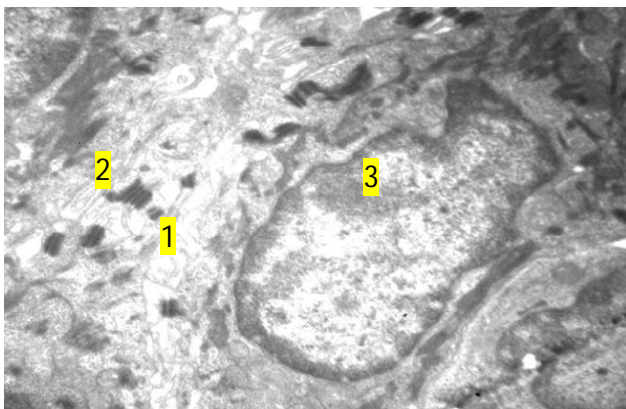


Fig. 3. Ultrastructural changes in the epithelium of the attached part of the rat's gingiva under conditions of 14-week opioid exposure. Necrotic areas of the cytoplasm of the epitheliocyte of the spinous layer (1), osmiophilic inclusions (2), heterochromatin cells in the karyoplasm (3). x12000.

mitochondria, lightening of their matrix and damaged cristae were found, vacuolization of mitochondria was observed in

some places (Fig. 2). Destructive changes of tonofilaments are determined, where signs of their fragmentation are revealed, in some places they are lysed. In significant areas, intercellular contacts are not clearly visualized, most are reduced, which indicates the phenomenon of acantholysis. Intercellular spaces are mostly uneven and significantly expanded. In the cytoplasm of cells of the spinous layer, osmiophilic inclusions are observed, which is caused by increased keratinization of the epithelial plate in the area of the gingival sulcus of white rats.

In the epithelial cells of the attached part of the gums, apoptotic phenomena are observed, as well as structureless, illuminated areas of the cytoplasm, lysosomes, and osmiophilic inclusions (Fig. 3). The development of necrotic changes is caused by significant damage and destruction of organelles, as well as fragmentation or lysis of bundles of tonofilaments. Small pyknotic nuclei with uneven contours and heterochromatin in the karyoplasm are found in some of the epitheliocytes of the attached part of the gums. The karyolemma is mainly osmiophilic, the phenomena of karyorrhexis, in some places - karyolysis, as well as signs of destruction of karyoplasm are observed. Violation of intercellular contacts, their indistinctness and uneven expansion of intercellular spaces were revealed.

Ultrastructural studies demonstrated pronounced changes in periodontal components. Disruption of the orderly arrangement of collagen fibers and destructive changes, in particular, their fragmentation, destruction of fibers in places, were found in the bundles. The illumination of the amorphous component of the intercellular substance of the connective tissue is determined (Fig. 4).

Submicroscopic organization of fibroblasts and fibrocytes changes significantly, macrophages are activated. In fibroblasts, altered nuclei and damaged organelles in the cytoplasm are identified. Signs of karyopyknosis in fibrocytes, karyorrhexis phenomena in places. There is an expansion of the perinuclear space, indistinct contours of

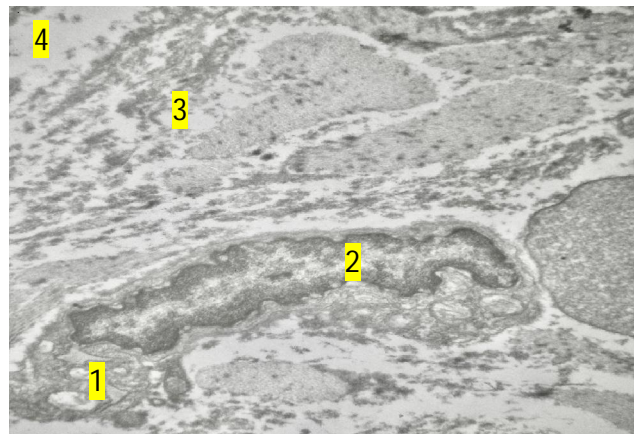


Fig. 4. Ultrastructural changes in the rat periodontium under conditions of 14-week opioid exposure. Vacuole-like formations in the cytoplasm of a fibrocyte (1), karyopyknosis (2), fragmented collagen fibers (3), swollen connective tissue (4). x12000.

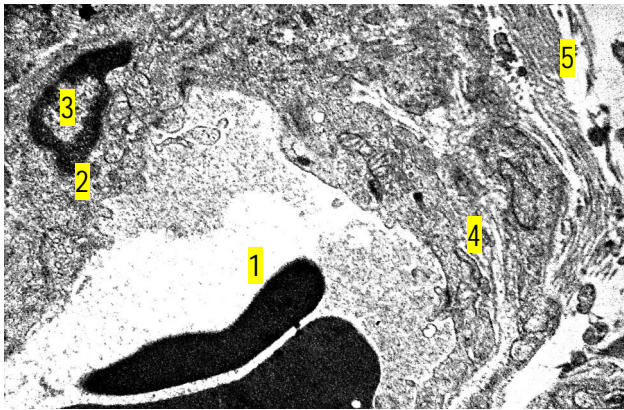


Fig. 5. Ultrastructural changes in the hemocapillary of the mucous membrane of the gingiva of the rat under conditions of 14-week opioid exposure. Hemocapillary lumen with formed blood elements (1), endotheliocyte cytoplasm (2), karyopyknosis (3), swelling of the basement membrane (4), swelling and delamination of collagen fibers in the perivascular space (5). x12000.

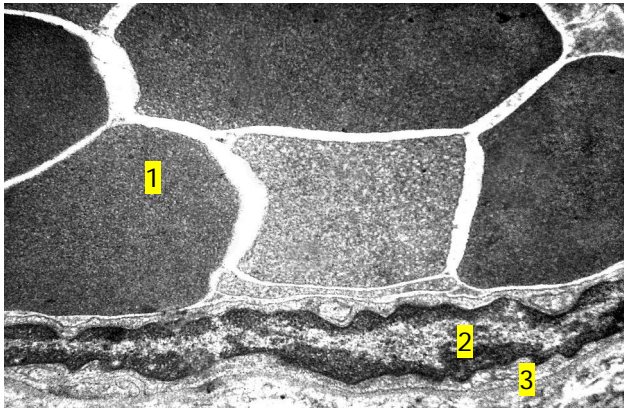


Fig. 6. Ultrastructural changes of the venules of the gingival mucosa of the rat under conditions of 14-week opioid exposure. Formed blood elements in the venule lumen (1), destruction of the endotheliocyte nucleus (2), basement membrane (3). x9000.

the karyolemma, where deep intussusceptions are revealed. Heterochromatin is determined on a significant area of osmiophilic karyoplasm. In the cytoplasm, organelles are mostly destructively changed, lysosomes, vacuole-like formations, expanded and fragmented tubules of the granular endoplasmic reticulum, and unevenly thickened cisterns of the Golgi complex are observed. Swollen mitochondria with destroyed cristae and lightened matrix were found (see Fig. 4).

Submicroscopically, significant changes were found in the links of the hemomicrocirculatory channel of the mucous membrane of the gums. In the wide lumens of the hemocapillaries, the formed elements of the blood, mostly erythrocytes, are determined. The phenomenon of "sludge phenomenon" is observed. Endotheliocyte nuclei are destructively altered, with signs of karyopyknosis and karyorrhexis. Numerous deep intussusceptions of the karyolemma and dense accumulations of heterochromatin in the karyoplasm were revealed. Destroyed organelles

and few pinocytotic vesicles can be found in the cytoplasm. In some areas, vacuole-like structures are visualized. The basal membrane is vaguely contoured, in some places it is significantly thickened. Perivascular spaces are expanded, where thickened bundles of collagen fibers are determined, which is caused by the development and progression of sclerotic changes (Fig. 5).

In the venules, the signs of dilatation, hemoptysis and "sludge phenomenon" predominate. In the lumen of the venules, erythrocytes are identified, places where platelets accumulate. In the nuclei of endotheliocytes, osmiophilic karyoplasm with accumulation of heterochromatin, karyopyknosis and uneven contours of karyolemma are visualized (Fig. 6). The perinuclear space is expanded. Brightened areas, electron-dense inclusions, vacuoles, as well as damaged organelles and vacuolated mitochondria are observed in the cytoplasm, which is a sign of cytolysis. The adluminal surface of endotheliocytes is focally exfoliated in some areas and protrudes into the lumen of venules. The basal membrane thickens significantly, its contours are indistinct in places. Collagen fibers were found in significantly expanded perivascular spaces.

Discussion

The results obtained by us of the electron microscopic study of the constituent components of the periodontium against the background of chronic opioid exposure are compared with the data of the ultrastructural study in patients with periodontopathies. In particular, with generalized periodontitis, researchers submicroscopically detected destroyed contacts between epitheliocytes and signs of spongiosis in the layers of the gingival epithelium, the formation of which was caused by the penetration of serous fluid into the intercellular spaces, which had a significant volume [2, 13, 16]. The destruction of mitochondrial cristae and vacuolization of their matrix, the phenomena of apoptosis, cell nuclei acquired an irregular shape and lost nucleoli and chromatin were also noted [3]. In individual cells of the basal layer of the gingival epithelium, the researchers identified foci of destruction of the cell membrane [2, 16].

In our studies, we also observed fragmented or lysed bundles of tonofilaments, significant damage and destruction of organelles, phenomena of karyorrhexis and vacuole-like formations in illuminated areas of the cytoplasm, which is a sign of the development of partial focal necrosis. According to the researchers, in patients with generalized periodontitis, the lumen of hemocapillaries was filled with erythrocytes and platelets. The basal membrane is loose, in the cytoplasm of endotheliocytes, areas of lightening, mitochondria with disorganized cristae were determined. Nuclei of irregularly shaped endotheliocytes with karyolemma intussusception, destructive nucleoli were present, which indicated damage to the hemomicrocirculatory channel of the periodontium, causing ischemia of the gingival mucosa [3].

In patients with generalized periodontitis with accompanying cardiovascular pathology, obturation of the lumen of vessels of the gingival mucosa, desquamation of the endothelium, apoptosis of endotheliocytes, and obturation of blood vessels with formed blood elements were noted, which indicated the development of local endothelial dysfunction [13]. The given data in patients with periodontitis are compared with the results obtained by us of the study of microvessels under the experimental action of opioid, where submicroscopically in the lumen of the hemocapillaries of animals, the phenomenon of "sludge phenomenon", destructively changed nuclei of endotheliocytes, with signs of karyopyknosis, and damaged organelles and vacuole-like structures were found in the cytoplasm, which indicated the progression of hypoxia.

Conclusions

1. At the end of the fourteenth week of opioid exposure, ultrastructural changes in the epithelium of the mucous

membrane of the gums, periodontium, and hemomicrovessels with the development of decompensation and pronounced dystrophic-destructive changes were established.

2. With the long-term effect of an opioid analgesic, signs of karyorrhexis, segregation of nucleoli, spongiosis, acantholysis, apoptosis, as well as vacuole-like formations, which are a manifestation of focal necrosis of epitheliocytes, were revealed. Fragmentation and destruction of periodontal collagen fibers, destructive changes in fibrocytes and fibroblasts were found in the periodontium.

3. Ultrastructural reorganization of the cellular components of the periodontium is caused by vascular disorders of a systemic nature, which are manifested by the phenomena of dilatation, hemoptysis, sludge phenomenon, dystrophic changes in the endotheliocytes of hemocapillaries and venules, and the progression of sclerotic changes, which significantly disrupts the trophism of rat periodontal tissues.

References

- [1] Algera, M.H., Olofsen, E., Moss, L., Dobbins, R.L., Niesters, M., van Velzen, M., ... Dahan, A. (2021). Tolerance to Opioid-Induced Respiratory Depression in Chronic High-Dose Opioid Users: A Model-Based Comparison with Opioid-Na?ve Individuals. *Clin Pharmacol Ther.*, 109(3), 637-645. doi: 10.1002/cpt.2027
- [2] Babai, O. M. (2016). Методика та досвід оцінки ефективності лікування пацієнтів з генералізованим пародонтитом за даними ультраструктурного аналізу епітелію ясен [Methodology and experience of evaluating the effectiveness of treatment of patients with generalized periodontitis based on ultrastructural analysis of the gingival epithelium]. *Український журнал екстремальної медицини ім. Г.О. Можаява - Ukrainian Journal of Extreme Medicine named after G.O. Mozaeva*, 17(2), 5-10.
- [3] Buchkovska, A. Yu., Nakonechna, O. V., Petryshyn, O. A., & Strus, Kh. I. (2018). Ультраструктурне дослідження слизової оболонки ясен при генералізованому пародонтиті [Ultrastructural study of the gingival mucosa in generalized periodontitis]. *Світ медицини та біології - World of Medicine and Biology*, 4(66), 145-148. doi: 10.26724/2079-8334-2018-4-66-145-148
- [4] Dahlen, G., Fejerskov, O., & Mangi, F. (2020). Current concepts and an alternative perspective on periodontal disease. *MC Oral Health*, 20(1), 1-9. doi: 10.1186/s12903-020-01221-4
- [5] Dana, R., Azarpazhooh, A., Laghapour, N., Suda, K.J., Okunseri, C. (2018). Role of dentists in prescribing opioid analgesics and antibiotics: an overview. *Dent Clin. North Am.*, 62, 279-294. doi: 10.1016/j.cden.2017.11.007
- [6] Erim, D., Obadan-Udoh, E., & Agaku, I. (2021). Cost savings from averted prescription opioid-attributable dental diseases in the United States between 2013 and 2019. *Popul. Med.*, 3, 1-13. doi: <https://doi.org/10.18332/popmed/136488>
- [7] Ferreira, R. C. M., Almeida-Santos, A. F., Duarte, I. D. G., & Aguiar, D. C. (2017). Peripheral antinociception induced by aripiprazole is mediated by the opioid system. *BioMed Research International*, 2017, 8109205. doi: 10.1155/2017/8109205
- [8] Fik, V.B., Paltov, E.V., & Kryvko, Y.Y. (2018). Morphofunctional peculiarities of the periodontal tissue under conditions of simulated eight-week opioid effect. *Deutscher Wissenschaftsberichter. German Science Herald*, (1), 14-17. doi: 10.19221/201814
- [9] Fitkalo, O.S., Ohonovskyi, R.Z., Pohranychna, K.R., Nahirnyi, Y.P., & Netlyukh, A.V. (2021). Clinical features of toxic jaw bone osteomyelitis in drug addicts. *Wiadomoscie Lekarskie*, 74(2), 263-267. doi: 10.36740/WLek202102116
- [10] Hartnett, K.P., Jackson, K.A., Felsen, C., McDonald, R., Bardossy, A.C., Gokhale, R.H. ... Dumyati, G. (2019). Bacterial and Fungal Infections in Persons Who Inject Drugs - Western New York, 2017. *Morbidity and Mortality Weekly Report*, 68(26), 583-586. doi: 10.15585/mmwr.mm6826a2
- [11] Hegazi, F., Alhazmi, H., Abdullah, A., Alamer, N., Nelson, J., Aldosari, M. ... Vardavas, C. (2021). Prevalence of Oral Conditions Among Methamphetamine Users: NHANES 2009-2014. *J. Public Health Dent.*, 81(1), 21-28. doi: 10.1111/jphd.12389
- [12] Jirkof, P. (2017). Side effects of pain and analgesia in animal experimentation. *Laboratory Animal*, 46(4), 123-128. doi: 10.1038/labana.1216
- [13] Kopchak, O. V., Biloklytska, G. F., Stechenko, L. O., & Kryvosheeva, O. I. (2017). Ультраструктурна організація тканин ясен хворих на генералізований пародонтит при кардіоваскулярній патології [Ultrastructural organization of gingival tissues in patients with generalized periodontitis with cardiovascular pathology]. *Світ медицини та біології - World of Medicine and Biology*, 59(1), 121-126.
- [14] Manji, F., Dahlen, G., & Fejerskov, O. (2018). Caries and periodontitis: contesting the conventional wisdom on their aetiology. *Caries Reports*, 52(6), 548-564. doi: 10.1159/000488948
- [15] Martinez-Garcia, M., & Hernandez-Lemus, E. (2021). Periodontal Inflammation and Systemic Diseases: An Overview. *Front Physiol.*, 12:709438. doi: 10.3389/fphys.2021.709438
- [16] Matviyuk, T. I. (2017). Ультраструктурні зміни епітелію ясен хворих на генералізований пародонтит в динаміці терапії [Ultrastructural changes of the gingival epithelium of patients with generalized periodontitis in the dynamics of therapy]. *Хірургія Донбасу - Surgery of Donbass*, 6(2), 40-44.
- [17] Paltov, E. V., Kovalyshyn, O. A., Fik, V. B., Kryvko, Y. Ya.,

- Podoliuk, M. V., & Holeyko, M. V. (2019). Pathomorphological changes in rats retinal layers at the end of the twelfth week of experimental opioid influence. *International Academy Journal Web of Scholar*, 4(34), 19-22. doi: 10.31435/rsglobal_wos/30042019/6444
- [18] Pergolizzi, J. V. Jr., Raffa, R. B., & Rosenblatt, M. H. (2020). Opioid withdrawal symptoms, a consequence of chronic opioid use and opioid use disorder: Current understanding and approaches to management. *J. Clin. Pharm. Ther.*, 45(5), 892-903. doi: 10.1111/jcpt.13114
- [19] Taqi, M. M., Faisal, M., & Zaman, H. (2019). OPRM1 A118G Polymorphisms and Its Role in Opioid Addiction: Implication on Severity and Treatment Approaches. *Pharmacogenomics and Personalized Medicine*, (12), 361-368. doi: 10.2147/PGPM.S198654
- [20] Valadas, L. A. R., Fernandes, M. L., Silva, M. I. G., Cito, M. do C. de O., Oliveira I.C.M., Dias, M. L. ... Sousa, F. C. F. (2020). Oral Manifestations of Drug Abuse: A Review of Literature. *Journal of Young Pharmacists*, 12(1), 11-14. doi: 10.5530/jyp.2020.12.3
- [22] Zhao-Fleming, H., Hand, A., Zhang, K., Polak, R., Northcut, A., Jacob, D. ... Rumbaugh, K. P. (2018). Effect of non-steroidal anti-inflammatory drugs on post-surgical complications against the backdrop of the opioid crisis. *Burns Trauma*, 6(1), 25. doi: 10.1186/s41038-018-0128-x
- [23] Zubachyk, V. M., & Fedun, I. R. (2017). Біохімічні показники ротової рідини у наркозалежних хворих на хронічний генералізований пародонтит [Biochemical indicators of oral fluid in drug-dependent patients with chronic generalized periodontitis]. *Клінічна стоматологія - Clinical Dentistry*, (2), 9-14. doi: 10.11603/2311-9624.2017.2.7741

УЛЬТРАСТРУКТУРНА РЕОРГАНІЗАЦІЯ СКЛАДОВИХ КОМПОНЕНТІВ ПАРОДОНТА ЩУРІВ ЗА УМОВ ХРОНІЧНОГО ОПІОЇДНОГО ВПЛИВУ

Фік В. Б., Подолюк М. В., Матківська Р. М.

Опіоїдна залежність за останні роки набула ознак епідемії та становить серйозну проблему у сучасній медицині. У споживачів наркотичних речовин відмічають значну поширеність захворювань ротової порожнини, тканин пародонта в порівнянні із загальною популяцією населення. Метою роботи було дослідити ультраструктурну організацію тканин пародонта щурів наприкінці чотирнадцятого тижня експериментальної дії опіоїда. Тваринам вводили внутрішньом'язово, щоденно, одноразово опіоїдний анальгетик налбуфін (фармакотерапевтична група: анальгетики, опіоїди, похідні морфіну) у зростаючих дозах упродовж 14 тижнів: 1-2 тижні - 0,212 мг/кг, 3-4 тижні - 0,225 мг/кг, 5-6 тижні - 0,252 мг/кг, 7-8 тижні - 0,260 мг/кг, 9-10 тижні - 0,283 мг/кг; 11-12 - 0,300 мг/кг, 13-14 тижні - 0,450 мг/кг. Наприкінці чотирнадцятого тижня опіоїдного впливу встановлено ультраструктурні зміни епітелію слизової оболонки ясен, пародонта та гемомікросудин з розвитком декомпенсації та виражених дистрофічно-деструктивних змін. При довготривалій дії опіоїдного анальгетика було виявлено ознаки каріорексису, сегрегації ядерець, спонгіозу, апоптозу, порушення цілісності міжклітинних контактів, а також вакуолеподібні утворення, що було проявом фокального некрозу епітеліоцитів. Розвиток некротичних змін зумовлювався значним ушкодженням і руйнуванням органел, а також фрагментацією чи лізисом пучків тонофіламентів. Міжклітинні простори переважно були розширеними та нерівномірними, що зумовлювалося набряковими явищами. У пародонті було виявлено фрагментацію та руйнування колагенових волокон пародонта, деструктивні зміни фіброцитів і фібробластів. Визначали просвітлення аморфного компоненту міжклітинної речовини сполучної тканини. Ультраструктурна реорганізація клітинних компонентів пародонта зумовлювалася судинними розладами системного характеру, які проявлялися явищами дилатації, повнокров'я, складж-феномену, дистрофічними змінами ендотеліоцитів гемокапілярів і венул та прогресуванням склеротичних змін, що суттєво порушувало трофіку тканин пародонта щурів.

Ключові слова: опіоїдний вплив, щури, пародонт, ультраструктурне дослідження.