

UNCEMENTED POROUS-COATED ANATOMIC TOTAL HIP REPLACEMENT

RESULTS AT SIX YEARS IN A CONSECUTIVE SERIES

YOUNG-HOO KIM, VANA E. M. KIM

From Yonsei University College of Medicine, Seoul, Korea

We studied 108 patients (116 hips) who were followed for a minimum of six years (73 to 89 months) after primary total hip arthroplasty using an uncemented porous-coated anatomic hip. The average age of the patients at operation was 48.4 years, and the diagnosis was avascular necrosis of the femoral head in 46 hips, neglected femoral neck fracture in 27, osteoarthritis secondary to childhood pyogenic arthritis in 24 and to childhood tuberculous arthritis in five, and miscellaneous in 14. The average preoperative Harris hip score was 55, which improved to 91 at latest follow-up.

All patients with loose femoral components or disabling thigh pain had received prostheses which were undersized in the coronal or the sagittal plane, or in both. No patient with a satisfactory fit in both coronal and sagittal planes had loosening of the femoral component or disabling thigh pain. Three acetabular components showed aseptic loosening and 20 showed excessive wear (5 to 11 mm) of the polyethylene liner. Excessive wear was related to young age, but not to body-weight, gender, primary diagnosis, hip score, or range of hip movement. There was a high incidence of osteolysis (38 of 116 hips, 33%).

We recommend careful preoperative planning, with the use of a contemporary cemented technique when a satisfactory fit cannot be obtained. The high incidence of excessive wear and of osteolysis needs further investigation.

*J Bone Joint Surg [Br] 1993;75-B:6-14.
Received 19 March 1992; Accepted 11 June 1992*

Y.-H. Kim, MD, Orthopaedic Surgeon
V. E. M. Kim, Ed D, Consultant
5569 North County Road 29, Loveland, Colorado 80538, USA.

Correspondence should be sent to Dr Y.-H. Kim.

©1993 British Editorial Society of Bone and Joint Surgery
0301-620X/93/1491 \$2.00

Encouraging short-term clinical results have been reported after uncemented porous-coated total hip arthroplasties using various types of prosthesis (Cameron 1982; Engh 1983; Engh and Bobyn 1985; Hedley et al 1987; Callaghan, Dysart and Savory 1988). More long-term studies, however, are needed to establish the merits of these prostheses relative to those which employ contemporary cementing methods (Harris 1969; Harris, McCarthy and O'Neill 1982; Russotti, Coventry and Stauffer 1988).

We present the results of a prospective study of a consecutive series of patients followed for a minimum of six years after primary arthroplasty with an uncemented porous-coated anatomic hip (PCA; Howmedica, Rutherford, New Jersey).

PATIENTS AND METHODS

Primary total hip arthroplasties were performed in Korea by Y-HK on 119 patients using an uncemented PCA prosthesis. Eleven patients were lost to follow-up: one was lost before one year, another five by two years, two more by three years, two by four years, and one at between four and six years. This left 108 patients (116 hips) followed for six years or more. The average follow-up was 76 months (73 to 89).

The right hip was operated on in 60 patients, and the left in 40, while eight had bilateral replacements. There were 51 men and 57 women; the average age was 48.4 years (19 to 85). Twenty patients were under 30 years of age, 65 were between 30 and 64, and 23 were 65 or more. The diagnosis was avascular necrosis of the femoral head in 46 hips (40%); neglected femoral neck fracture in 27 (23%); osteoarthritis secondary to childhood pyogenic arthritis in 24 (21%); osteoarthritis secondary to childhood tuberculous arthritis in five (4%); post-traumatic arthritis in five (4%); rheumatoid arthritis in four (3.5%); arthrodesed hip in four (3.5%); and giant-cell tumour of the femoral head in one (1%).

A modified Gibson approach was used in 97 hips and a Moore approach in 19; no trochanteric osteotomies were performed. Allograft was used in one patient to reconstruct a deficiency of the acetabulum. The numbers of each size of implanted components are shown in Table I.

A prophylactic antibiotic (cephalosporin 6 g daily) was started immediately after the induction of anaesthesia and continued for two days after the operation. Postoperatively, the operated leg was suspended in a Thomas splint with a Pearson knee attachment; all dressings and splints were removed at 48 hours. Standing was allowed on the third postoperative day and walking with crutches and partial weight-bearing shortly thereafter. Full weight-bearing was not allowed before three months.

Clinical ratings (Harris 1969) were determined preoperatively and postoperatively at three and six months and then annually. An attempt was made to correlate these hip ratings with a number of factors including the underlying disease, the patient's activity, unilateral or bilateral involvement, time since arthroplasty, and the patient's weight and age group.

There is an anecdotal view that oriental patients have a considerably lower prevalence of deep-vein

thrombosis after total hip replacement. We therefore documented its prevalence in our patients, using venography at 10 or 11 days and perfusion lung scanning at 10 or 11 days in all cases. If the perfusion lung scan was positive we proceeded with ventilation lung-scanning and pulmonary angiography (Kim and Suh 1988).

Anteroposterior, frog-lateral, and cross-table lateral radiographs were taken by a standard method on each operated hip before and immediately after the operation and at two weeks (on discharge from hospital), three months, six months and then annually.

The follow-up radiographs were compared with the postoperative films for evidence of new radiolucent lines at the bone-implant interface. Radiolucent lines were measured in the femur at 14 zones, seven in the coronal plane and seven in the sagittal plane (Gruen, McNeice and Amstutz 1979), and at three zones on the acetabular interface (DeLee and Charnley 1976).

From the postoperative radiographs we recorded the position of the femoral component within the intramedullary canal (valgus, neutral or varus), and the ratio of the width of the femoral component to that of the femoral canal in the coronal and sagittal planes at three levels. We used these measurements to assess the adequacy of the fill achieved by the femoral component at each level. The first level was at the upper border of the lesser trochanter. At this level, in the coronal plane, the presence of the greater trochanter makes it difficult to measure the medullary canal. We therefore drew a line along the lateral margin of the lateral cortex of the femur extending it through the greater trochanter, and measured the width between this line and the medial cortex (Fig. 1). In the sagittal plane, the posterior cortex of the femur can be located through the superimposed greater trochanter. The stem-canal ratio at this first level gives an

Table I. Components used in 116 PCA total hip arthroplasties

Femoral stem		Acetabular component*	
Size	Number	Size (mm)	Number
1	6	46	24
2	7	49	25
3	26	52	31
4	21	55	25
5	26	58	11
6	24		
7	6		

* inner diameter 32 mm in all

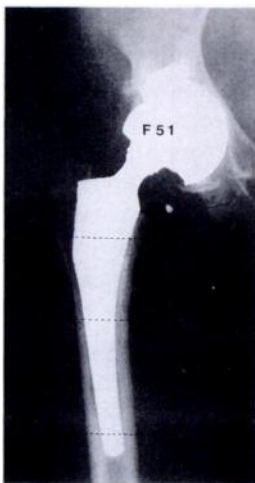


Fig. 1a

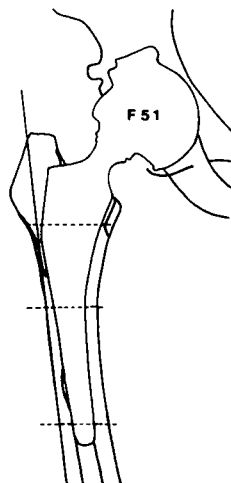


Fig. 1b

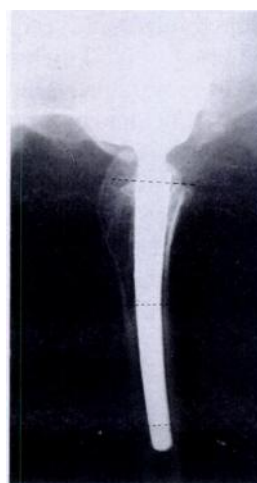

Fig. 1c

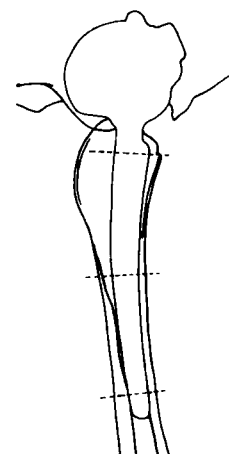


Fig. 1d

Postoperative radiographs of the right hip of a 51-year-old woman who had osteoarthritis secondary to childhood pyogenic arthritis. The diagrams showing a satisfactory stem fill in both planes. Figures 1a and 1b - The stem is in good position and has a satisfactory fill at all three levels (over 80%). At the proximal level, it is difficult to measure the canal because of the greater trochanter, and a line is therefore drawn along the lateral margin of the lateral cortex and extended, then used as the basis for measurement. Figures 1c and 1d - The lateral view also shows a satisfactory fill at all three levels (over 70%).

indication of metaphyseal fill. The second level was at mid-stem, and the third level 1 cm proximal to the tip of the prosthesis. We studied the relationship between bone ingrowth into the surface of the stem at the level of the greater trochanter and the stability of the prosthesis and also the remodelling of the proximal femoral bone. We assessed bone ingrowth by the presence of horizontal, feathery cancellous striations growing into the porous surface of the stem at this level.

On the postoperative films we assessed the acetabular component for lateral opening angle and for coverage both superiorly and laterally. Migration of the acetabular component was measured vertically between the inferior margin of the cup and the inferior margin of the ipsilateral tear drop, and horizontally between Köhler's line and the centre of the outer shell of the acetabular cup (Callaghan et al 1988).

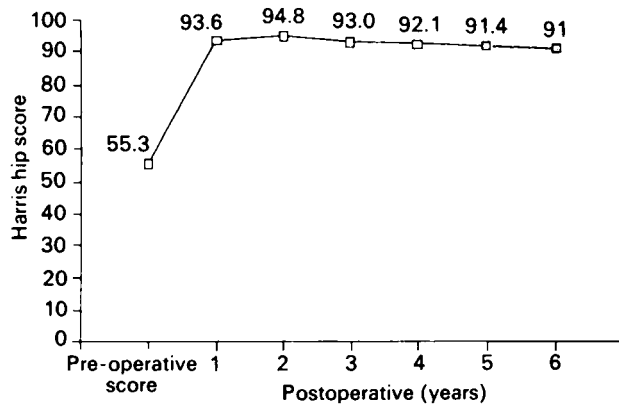


Fig. 2

Mean preoperative and postoperative Harris hip scores. There is progressive improvement for two years and then a steady decrease.

Wear of the polyethylene liner was assessed by measuring its thickness on the immediate postoperative anteroposterior and lateral radiographs, and on all available intermediate and final radiographs. Thickness was measured from the centre of the femoral head to the acetabular metal shell. Where it was difficult to be certain exactly where the centre of the femoral head was located, because it was covered by the metal-backed acetabular component, we measured the distance between the inferior margin of the femoral head and the acetabular component. All measurements were corrected for magnification of the radiographs, using the diameter of the head of the femoral component.

The bone in the proximal femur was evaluated for osteolysis, medial neck round-off, medial neck cortico-cancellisation and cancellous hypertrophy in the medial and lateral metaphysis. The distal femoral bone was evaluated for cortical hypertrophy, endosteal osteolysis and endosteal consolidation, and the number of loose beads around each component was recorded. Heterotopic ossification, if present, was graded according to the classification of Brooker et al (1973).

Loosening of the femoral component was diagnosed if there was progressive varus shift or progressive axial subsidence of more than 5 mm. Loosening of the acetabular component was diagnosed where there was a change in position or a continuous radiolucent line wider than 2 mm.

At the final follow-up, all patients had scintigraphic scanning using ^{99m}Tc phosphate to compare the degree and the pattern of radionuclide uptake in the stable hips with those with component loosening. Static images in anterior, posterior, and lateral projections were obtained four hours after the injection.

RESULTS

The average Harris hip score preoperatively was 55.3 points (12 to 74) and at latest follow-up was 91 (55 to 100) (Fig. 2). For the 46 patients with avascular necrosis the average score rose from 63 to 93 points; for femoral neck fracture ($n = 27$) from 29 to 92; for pyogenic arthritis ($n = 24$) from 51 to 90; for tuberculous arthritis ($n = 5$) from 49 to 88; for post-traumatic arthritis ($n = 5$) from 72 to 92; for rheumatoid arthritis ($n = 4$) from 58 to 88; for an arthrodesed hip ($n = 4$) from 58 to 94; and for the one case of giant-cell tumour of the femoral head from 57 to 92. The improvement in hip score was slightly less in patients with pyogenic, tuberculous or rheumatoid arthritis in comparison with those who had avascular necrosis or femoral neck fracture, but this difference was not statistically significant by analysis of variance ($p = 0.78$). The mean follow-up score was 89 points for men and 93 points for women.

For the 20 patients aged under 30 years, the average score rose from 62 to 90; for those from 30 to 64 years ($n = 65$) from 66 to 92; and for those of 65 years or more ($n = 23$), from 37 to 92. These age-group scores are very similar, although the youngest group had marginally lower average scores at follow-up.

A hip with an excellent result scored 90 to 100 points; a good result, 80 to 89; a fair result, 70 to 79; and a poor result, below 70. The scores at two-year follow-up were excellent in 87 hips (75%), good in 22 (19%), and fair in seven (6%). At six years, 84 hips (72%) were excellent, 19 (16%) were good, two (2%) were fair and 11 (10%) were poor. The fall in number of excellent and good results at six years was not statistically significant (chi-squared test, $p = 0.28$), but it should be noted that no hip had a poor result at two years, while at six years there were 11 (10%).

Postoperatively, all patients had less pain in the operated hip, but there was a 25% prevalence of thigh pain. Of the 98 patients (106 hips) with a satisfactory stem fit, 17 (17%) had occasional, non-disabling and activity-related thigh pain at each follow-up. None of these patients took analgesics and none had component loosening.

Nine patients (9%) had persistent and disabling

thigh pain at six years and seven of these (nine hips) had evidence of femoral loosening; all seven had an undersized femoral component in one or both planes. One patient (one hip) had a radiologically loose femoral component but no clinical symptoms.

Dependence on walking aids had decreased substantially. Before the operation, 26 patients used no support for walking, 26 used a cane for long distances, and 56 used crutches. At six years, 97 patients used no support and 11 used crutches, comprising seven with femoral loosening, three with acetabular loosening and one with excessive wear in the acetabular liner. Two patients with disabling thigh pain did not use crutches because they were self-conscious about their appearance.

Before arthroplasty, every patient had a limp; in 59 it was mild, in 22 moderate, and in 27 severe. At latest follow-up, 49 patients had no detectable limp, in 33 it was mild, in 16 moderate, primarily due to leg-length discrepancy, and in ten severe due to component loosening. The patients with a limp due to leg-length discrepancy all had normal hip muscle power and good hip motion, allowing their limp to be completely resolved by a shoe lift.

The range of hip motion was improved: average flexion contracture decreased from 5° to 0°, flexion increased from 84° to 112°, internal rotation from 15° to 34°, external rotation from 28° to 40°, abduction from 30° to 50°, and adduction from 21° to 37°. Leg-length discrepancy was measured with a tape measure and on a scanogram. It ranged from 0 to 5 cm before arthroplasty (average 1.7 cm); postoperatively, it ranged from 0 to 3 cm (average 0.3 cm).

On postoperative radiographs, 111 (96%) of the 116 femoral stems were in a neutral position, four (3%) were in varus and one (1%) in valgus. The adequacy of the intramedullary fill was recorded as satisfactory when the stem filled the proximal canal by more than 80% in the

coronal plane and more than 70% in the sagittal plane. The component was considered as undersized if filling was less than this in either or both planes. In the 106 of the 116 stems which were satisfactory, the average filling of the medullary canal by the stem in the coronal plane was 84% at the metaphysis, 87% at mid-length, and 86% distally. In the sagittal plane, these percentages were 70, 72 and 67 respectively.

Of the other ten stems, six had a satisfactory fill in the coronal plane (average 83%) but not in the sagittal plane (under 70%). Three of these six stems had component loosening (Fig. 3), and another two had no evidence of radiographic loosening and some bone ingrowth, but the patients suffered disabling thigh pain. The remaining patient had subsidence of the stem of 13 mm but no clinical symptoms. In the other four unsatisfactory stems, the component was undersized in both planes and all four showed loosening. These differences in fit and loosening were statistically significant (chi-squared test, 2df, $p < 0.001$).

The seven hips with confirmed loosening of the femoral component had subsidence ranging from 13 to 20 mm. The diagnosis was childhood pyogenic arthritis in four hips and avascular necrosis of the femoral head in three. As mentioned above, one hip with radiographic loosening and 13 mm subsidence had no symptoms. Laboratory tests, including hip aspiration, showed no evidence of infection in any hip with loosening of the femoral component.

Four stems were in a varus position. One showed progressive varus shift at two years but was stable in varus position with bone ingrowth at the latest follow-up. Another had osteolysis of the medial neck without clinical symptoms. The other two were well-fixed in varus position with no abnormal bone remodelling.

Two other femoral stems had a radiolucent line wider than 2 mm in zones 1 and 7 in both coronal and

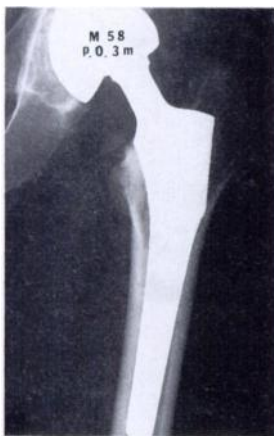

Fig. 3a

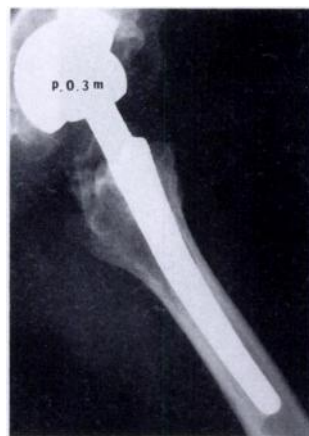

Fig. 3b

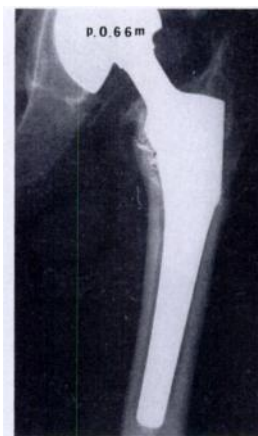

Fig. 3c

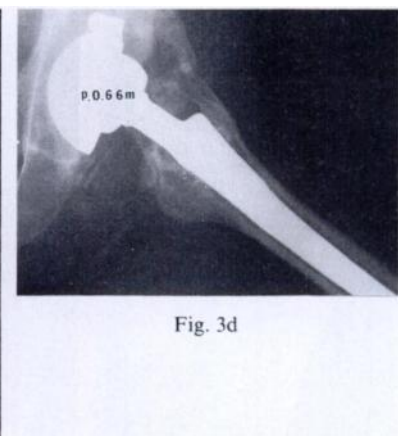


Fig. 3d

Postoperative radiographs of the left hip of a 58-year-old man who had avascular necrosis of the femoral head. Figures 3a and 3b - At three months there is a satisfactory stem fill in the coronal plane, but not in the sagittal plane. Figures 3c and 3d - At 66 months there is a subsidence of about 13 mm with loose beads in zones 1 and 7 on the anteroposterior view, and on the lateral view an undersized stem, continuous radiolucent lines wider than 2 mm in all zones, and loose beads in zones 1 and 7.

sagittal planes, but there was no subsidence or symptoms at latest follow-up.

Of the 116 hips, 90 (78%) with bone ingrowth in the area of the greater trochanteric surface all had a stable stem. Eighteen hips (16%) with bone ingrowth but with some osteolysis of the greater trochanter also had stable stems. The remaining eight hips (7%) had loosening with subsidence and showed no bone ingrowth in the area of the greater trochanter.

Of the 116 acetabular components, 97 showed a radiodense line with no radiolucency, two had a complete radiolucent line narrower than 1 mm, and four had an

incomplete radiolucent line narrower than 1 mm. Three acetabular components were loose. Ten hips had osteolysis in the acetabulum; three in zone I, two in zones I and II; three in zones II and III; one in zones I and III; and one in zone III only. One patient had severe osteolysis of the entire superior pubic rami. The diameter of the area of osteolysis was between 1.0 and 7.5 cm.

The average lateral opening of the acetabular components was 47° (range 32° to 71°). Two sockets had excessive lateral opening (68° and 71°); the socket in 68° abduction resulted in late dislocation of the hip 49 months after the operation.

Table II. Comparison of patients with and without wear of polyethylene liner

	Wear group	Non-wear group	Statistical analysis	
	(n = 19)	(n = 89)		
Age (yr)	33.5 (19 to 59)	52.4 (22 to 85)	Student's <i>t</i> -test (two-tailed)	
29 or under (number of patients, <i>per cent</i>)	8 (42)	12 (14)	$p < 0.001$; $df = 106$	
30 to 39	4 (21)	12 (14)		
40 to 49	5 (26)	15 (16)		
50 to 59	2 (11)	18 (20)		
60 to 69	-	18 (20)		
70 to 79	-	12 (14)		
80 to 89	-	2 (2)		
Under 50	17 (90)	39 (44)		
Weight (kg)	57.9 (45 to 75)	57.2 (31 to 76)	Student's <i>t</i> -test (two-tailed)	
			$p = 0.61$; $df = 106$	
Sex (M:F)	12:17	39:50	Chi-squared test 2×2	
			$p = 0.15$; $df = 1$	
Hip score (points)				
Preoperative	64 (53 to 75)	59 (49 to 73)	Student's <i>t</i> -test (two-tailed)	
Postoperative	91.9 (55 to 100)	91.2 (70 to 100)	$p = 0.82$; $df = 114$	
Diagnosis (number of hips, <i>per cent</i>)	(n = 20)	(n = 96)		
AVN*	9 (45)	37 (39)	} Chi-squared test 2×2	
OA 2 secondary to septic arthritis	5 (25)	19 (20)		$p = 0.41$; $df = 4$
OA 2 secondary to TB arthritis	2 (10)	3 (3)		
Miscellaneous	4 (20)	10 (10)		
Fracture of femur neck	0 (0)	27 (28)		
Range of motion (degrees)†	298.3 (280 to 315)	300.5 (205 to 350)	Student's <i>t</i> -test (two-tailed)	
			$p = 0.74$; $df = 114$	

* avascular necrosis

† total of flexion, abduction, adduction, external and internal rotation

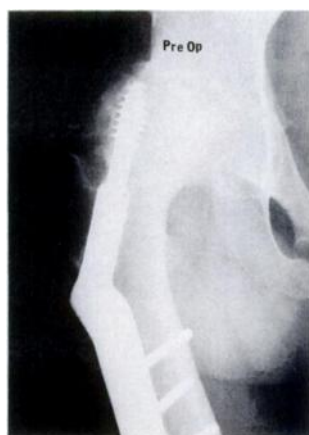

Fig. 4a

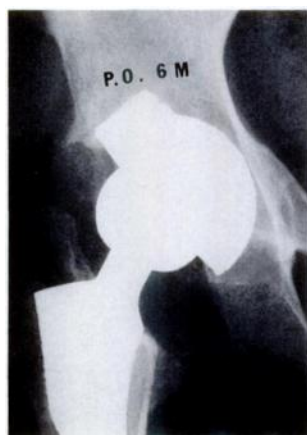


Fig. 4b

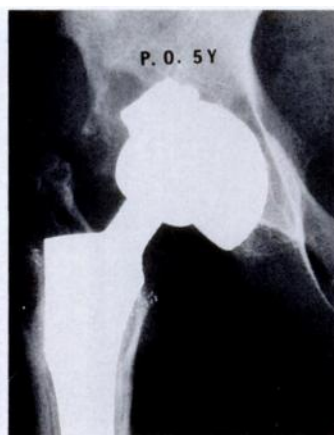


Fig. 4c

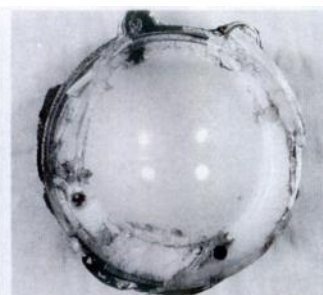


Fig. 4d

The right hip of a 23-year-old woman who had avascular necrosis of the femoral head secondary to femoral neck fracture. Figure 4a - The preoperative radiograph showing complete collapse of the femoral head. Figure 4b - At six months the femoral head is central in the acetabular component. Figure 4c - At five years the femoral head has migrated superiorly due to wear of the polyethylene liner. There are loose femoral beads. Figure 4d - The retrieved acetabular component shows wear of the polyethylene liner from the original thickness of 9 mm to 2 mm.

Twenty of the 116 hips (17%) showed definite wear and had loss of thickness of the polyethylene liner of on average 7.4 mm (SD 0.99, range 5 to 11) at an average of 67.9 months (60 to 73). The average wear rate in these cases was 1.3 mm/year (0.88 to 1.93). The incidence of severe wear was similar in unilateral (17%) and bilateral arthroplasties (19%).

One hip was revised because of excessive wear (Fig. 4). The direction of the wear was always upwards and forwards. We found a statistically significant relationship to the age of the patient, but not to diagnosis, weight, gender, hip score or range of motion (Table II).

Twenty-eight hips had areas of osteolysis of from 0.5 to 6 cm in the femur: eight in zones 1 and 7; four in zone 7; three in zones 3 and 7; three in zones 3 and 4; two in zones 1 and 2; two in zones 1 and 3; three in zones 1, 3 and 5; and three in zones 1, 2, 3, 6 and 7. No revision was performed only for osteolysis.

There were loose femoral beads in seven hips and loose acetabular beads in three. All had appeared later than three months after the operation, and all were associated with component loosening.

The degree and the pattern of radionuclide uptake were comparable in intact hips and in those with component loosening, with an increased uptake of radionuclide localised to zones 1, 4 and 7 of the femoral stem in all cases, both intact and loosened. In both groups, there was normal uptake in the remaining zones. A radiodense line around the components did not correspond to increased uptake, and radionuclide uptake did not provide useful criteria for differentiating the stable from the loose prostheses (Fig. 5).

Complications. Seven femoral components came loose:

four were revised and three await revision. One patient had subsidence of a stem of 13 mm but did not have clinical symptoms. Two acetabular components were revised for loosening and one for excessive wear of the liner. One patient with a loose acetabular component is awaiting revision.

Three patients had dislocations in the immediate postoperative period, which were reduced by manipulation, without recurrence. One patient had late recurrent dislocation at 49 months because of excessive abduction of the acetabular component.

Two patients had intraoperative fractures of the femoral shaft around the tip of the prosthesis. Both were treated by open reduction and internal fixation, giving a good result.

We used no prophylaxis against thromboembolism, and only 12 patients (10%) had evidence of silent deep-vein thrombi in the operated limb. None was treated, and none had a pulmonary embolism. One patient had a cardiac arrest due to postoperative hypovolaemia, but was resuscitated successfully.

Two patients had a sciatic neuropathy; in one it resolved completely and in the other incompletely, leaving a residual drop foot. One patient had a urinary tract infection postoperatively, which was cured with antibiotics.

DISCUSSION

The PCA stem is designed to follow the natural curve of the proximal femur to optimise contact between the prosthesis and the metaphyseal bone. It is known that the dimensions of the proximal femur do not change

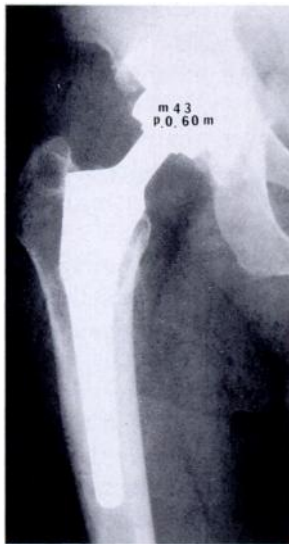

Fig. 5a

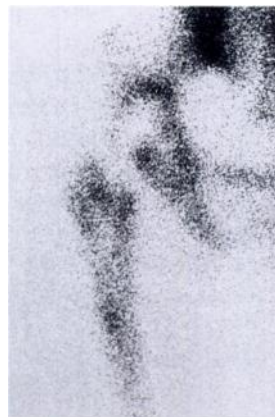

Fig. 5b

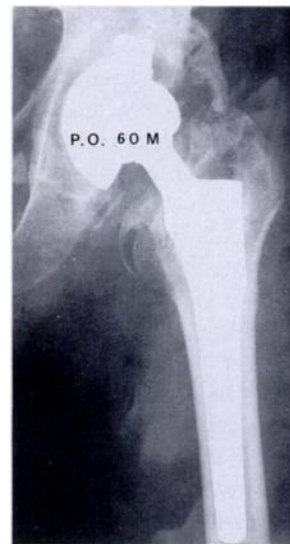

Fig. 5c

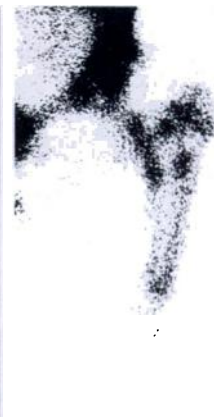

Fig. 5d

Radiographs and bone scans of a satisfactory hip and one with definite femoral loosening. Figure 5a – The radiograph of a 43-year-old man who had avascular necrosis of the femoral head. Sixty months postoperatively the prosthesis is in a good position. Figure 5b – A bone scan of the same hip shows increased uptake in zones 1, 4 and 7 around the femoral stem. Figure 5c – The radiograph of a 56-year-old man who had avascular necrosis of the femoral head. Sixty months postoperatively, there was evidence of a loose femoral component. Figure 5d – A bone scan of the same hip also shows increased uptake in zones 1, 4 and 7 in the left femoral stem.

markedly with age (Smith and Walker 1964; Ruff and Hayes 1982). The shape of the stem is intended to provide axial as well as rotational stability, the distal stem acting as a keel to counteract bending moments. The porous-surfaced, hemispherical acetabular component has two pegs on its outer surface and a prefixed high-density polyethylene liner. Both components have to be revised when the polyethylene liner is worn even if the metallic shell still has good fixation.

The Korean patient population requiring hip arthroplasty is very different from that in the West, particularly regarding the age of the patients and their diagnoses. In the current series, 52% of the patients were under 50 years of age. In the 496 hip arthroplasties (158 with cement, 338 without cement) performed by the senior author (YHK) in Korea, the diagnosis was avascular necrosis of the femoral head in 35%, femoral neck fracture in 22%, and osteoarthritis secondary to childhood pyogenic arthritis in 21% and to childhood tuberculous arthritis in 5%. Primary osteoarthritis was the diagnosis in only 3%, rheumatoid arthritis in 3%, and miscellaneous in the remaining 11%.

A high prevalence of thigh pain has been reported after uncemented total hip replacement (Hedley et al 1987; Callaghan et al 1988). Our study suggests that there are two types of thigh pain associated with uncemented replacement. Occasional, non-disabling, and activity-related thigh pain may be caused by stress concentration between the proximal femur which is stiffened by the prosthesis and the more flexible bone at the tip of the stem (Hedley et al 1987). All our patients with persistent and disabling thigh pain had either component loosening or a prosthesis which was too small in one or both planes; we therefore believe that this more severe thigh pain is probably due to axial and/or rotational movement of a loose or poorly fitting prosthesis.

Prolonged postoperative limping has been reported to result from the use of the direct lateral approach with elevation of the abductor muscles. Callaghan et al (1988) reported that their patients had much less limping after they changed from the direct lateral approach to the posterolateral approach. We used a modified Gibson or a Moore approach without elevation of the abductor muscles for all patients, and none had a moderate or severe limp due to abductor weakness.

Our results support the general contention that good filling in the sagittal plane is as important as that in the coronal plane. If the prosthesis cannot be fitted satisfactorily in both planes, we recommend that it be cemented using the latest techniques, or that a custom-made uncemented prosthesis be obtained and used.

Bone ingrowth at the greater trochanteric surface of the PCA stem appears to be important: it provides prosthetic stability and may improve load transfer to the proximal femur, thus reducing stress shielding and bone resorption. Bone ingrowth is believed to occur predominantly in areas affected by compression, and the ingrowth

at the greater trochanteric surface of the stem is an indication that there may be a compression force at the interface at zone I.

The fixation of the PCA acetabular component was encouraging: an adequate press-fit was achieved, and the two outrigger pegs provided sufficient rigidity to give successful anchorage. In only one hip was there a change in position of the component, and in this an allograft had been required to reconstruct a deficiency of acetabular bone stock. When grafting is required the two pegs may not be enough to provide initial stability. However, the high incidence of osteolysis is a problem.

Wear of the polyethylene acetabulum caused anxiety in the earlier days of hip replacement, but aseptic loosening seemed to occur before this wear produced clinical failure (Charnley and Cupic 1973). In the more durable arthroplasties, however, using modern techniques, wear may of itself cause clinical failure. The average long-term wear rate of Charnley acetabular cups has been reported as 0.07 to 0.15 mm/yr (Charnley and Halley 1975; Griffith et al 1978; Cupic 1979; Bartel, Wright and Edwards 1983; Eyerer and Ke 1984; Wroblewski 1985; McCoy et al 1988).

In our series, we noted excessive wear (over 5 mm) in the polyethylene liner in 17% of 116 hips within six years of implantation. The average wear rate in this group was 1.3 mm (0.88 to 1.93) per year. The reason for this excessive wear during the short period of six years was not certain. Several factors may have contributed: young age, third-body-wear from loose beads, imperfect conformity of the articulating surfaces, and the physical properties and thickness of the polyethylene liner. Younger patients are reported to have an increased prevalence of wear (Griffith et al 1978; Charnley 1979; Rimnac et al 1988), and in our series, the average age of those with excessive wear was 33.5 years and of those without wear 52.4 years. This difference is statistically significant ($p < 0.001$).

We also found, however, that wear could not be related to body-weight, primary diagnosis, hip score, or range of motion of the hip, thus supporting observations made by others (Griffith et al 1978; Charnley 1979; Rimnac et al 1988). It has been reported that male patients are more at risk of wear (Griffith et al 1978; Charnley 1979), but we found that gender was not a relevant factor.

There was a strikingly high incidence of osteolysis in our series (38 of 116 hips: 33%), and this correlated with the youth of the patient and the amount of polyethylene wear, which were themselves related. Gender and weight of the patient did not correlate with osteolysis. In all four patients who had revision for loose stems, we found particulate polyethylene debris. This suggests that polyethylene wear is associated with osteolysis.

Callaghan et al (1988) reported that technetium scans showed stabilisation of tracer activity around the

acetabular component in all patients at one year, but that scans remained active at the tip of the femoral prosthesis in 95% at two years. White, Johnson and Cook (1988) studying uncemented hip replacements, concluded that activity after the initial resolution may be associated with clinical symptoms or fixation problems. Amstutz et al (1984) also reported that patients with an increased uptake of radionuclide in the hip at two years may be at risk of loosening, sepsis or other yet undefined complications, such as ion accumulation.

We found that technetium scans showed stabilisation of tracer activity around the acetabular component in all patients by six years, but that scans remained active in zones 1, 4 and 7 in all femoral stems at this interval whether the hips were intact or loose. This suggests that the diagnosis of loosening cannot be made by bone scanning alone.

The failure rate in our series, from loosening and/or disabling thigh pain, was 12.1%; ten hips (8.6%) have been revised or are awaiting revision. These rates are substantially higher than those reported for cemented total hip arthroplasty using the latest techniques (Harris et al 1982; Harris and McGann 1986; Russotti et al 1988). This appears to be related to unsatisfactory fixation of the femoral stem in the femoral canal in both coronal and sagittal planes. We therefore recommend careful preoperative planning, using templates and CT scanning when necessary to obtain a satisfactory stem fill in both planes of the canal. If a good fit cannot be obtained, then either a custom-made uncemented prosthesis or a cemented prosthesis should be considered.

Excessive wear in the polyethylene liner and the high incidence of osteolysis in even stable hips remain as challenging problems.

The authors wish to thank Doctors H-S. Choi, D-Y. Han, H-S. Lee, and S-H. Oh for referring patients.

No benefits in any form have been received or will be received from a commercial party related directly or indirectly to the subject of this article.

REFERENCES

- Amstutz HC, Kilgus DJ, Thomas BJ, Weber MM. Evaluation of bony ingrowth by technetium diphosphonate and sulfur colloid scanning in porous hip surfacing. In: *The Hip*. Proc 11th meeting of the Hip Society. St Louis, etc: CV Mosby, 1984:257-70.
- Bartel DL, Wright TM, Edwards D. The effect of metal backing on stresses in polyethylene acetabular components. In: Hungerford DS, ed. *The Hip*. Proc 11th meeting of the Hip Society. St Louis, etc: CV Mosby Co, 1983:229-39.
- Brooker AF, Bowerman JW, Robinson RA, Riley LH Jr. Ectopic ossification following total hip replacement. *J Bone Joint Surg [Am]* 1973; 55-A:1629-32.
- Callaghan JJ, Nostrand DV, Dysart SH, Savory CG, Hopkinson WJ. A prospective evaluation of serial combined bone technetium diphosphonate and indium: III WBC scanning in uncemented primary total hip arthroplasty. Paper presented at the 55th meeting AAOS, 1988.
- Callaghan JJ, Dysart SH, Savory CG. The uncemented porous-coated anatomic total hip prosthesis: two-year result of a prospective consecutive series. *J Bone Joint Surg [Am]* 1988; 70-A:337-46.
- Cameron HU. The results of early clinical trials with a microporous coated metal hip prosthesis. *Clin Orthop* 1982; 165:188-90.
- Charnley J. *Low friction arthroplasty of the hip: theory and practice*. Berlin, etc: Springer-Verlag, 1979.
- Charnley J, Cupic Z. The nine and ten year results of the low-friction arthroplasty of the hip. *Clin Orthop* 1973; 95:9-25.
- Charnley J, Halley DK. Rate of wear in total hip replacement. *Clin Orthop* 1975; 112:170-9.
- Cupic Z. Long-term follow-up of Charnley arthroplasty of the hip. *Clin Orthop* 1979; 141:28-43.
- DeLee JG, Charnley J. Radiological demarcation of cemented sockets in total hip replacement. *Clin Orthop* 1976; 121:20-32.
- Engh CA. Hip arthroplasty with a Moore prosthesis with porous coating: a five-year study. *Clin Orthop* 1983; 176:52-66.
- Engh CA, Bobyn JD. *Biological fixation in total hip arthroplasty*. New Jersey: Slack Inc, 1985.
- Eyerer P, Ke YC. Property changes of UHMW polyethylene hip cup endoprostheses during implantation. *J Biomed Mater Res* 1984; 18:1137-51.
- Griffith MJ, Seidenstein MK, Williams D, Charnley J. Socket wear in Charnley low friction arthroplasty of the hip. *Clin Orthop* 1978; 137:37-47.
- Gruen TA, McNeice GM, Amstutz HC. "Modes of failure" of cemented stem-type femoral components: a radiographic analysis of loosening. *Clin Orthop* 1979; 141:17-27.
- Harris WH. Traumatic arthritis of the hip after dislocation and acetabular fractures: treatment by mold arthroplasty. *J Bone Joint Surg [Am]* 1969; 51-A:737-55.
- Harris WH, McGann WA. Loosening of the femoral component after use of the medullary-plug cementing technique: follow-up note with a minimum five-year follow-up. *J Bone Joint Surg [Am]* 1986; 68-A:1064-6.
- Harris WH, McCarthy JC Jr, O'Neill DA. Femoral component loosening using contemporary techniques of femoral cement fixation. *J Bone Joint Surg [Am]* 1982; 64-A:1063-7.
- Hedley AK, Gruen TA, Borden LS, et al. Two-year follow-up of the PCA noncemented total hip replacement. In: *The Hip*. Proc of the 14th meeting of the Hip Society. St Louis, etc: CV Mosby, 1987: 225-50.
- Kim Y-H, Suh J-S. Low incidence of deep vein thrombosis after cementless total hip replacement. *J Bone Joint Surg [Am]* 1988; 70-A:878-82.
- McCoy TH, Salvati EA, Ranawat CS, Wilson PD Jr. A fifteen-year follow-up study of one hundred Charnley low-friction arthroplasties. *Orthop Clin North Am* 1988; 19:467-76.
- Rinnac CM, Wilson PD Jr, Fuchs MD, Wright TM. Acetabular cup wear in total hip arthroplasty. *Orthop Clin North Am* 1988; 19: 631-6.
- Ruff CB, Hayes WC. Subperiosteal expansion and cortical remodeling of the human femur and tibia with aging. *Science* 1982; 217:945-8.
- Russotti GM, Coventry MB, Stauffer RN. Cemented total hip arthroplasty with contemporary techniques: a five-year minimum follow-up study. *Clin Orthop* 1988; 235:141-7.
- Smith RW, Walker RR. Femoral expansion in aging women: implications for osteoporosis and fractures. *Science* 1964; 145: 156-7.
- White RE Jr, Johnson RA, Cook G. Evaluation of cementless total hip replacement by methylene diphosphonate bone imaging. Paper presented at the 55th Annual Meeting of the American Academy of Orthopaedic Surgeons, February 9, 1988.
- Wroblewski BM. Direction and rate of socket wear in Charnley low-friction arthroplasty. *J Bone Joint Surg [Br]* 1985; 67-B:757-61.