



## Images in Pathology

## Undiagnosed intracranial lipoma associated with sudden death

Carlos Durão<sup>a,b,\*</sup>, Frederico Pedrosa<sup>a</sup><sup>a</sup> National Institute of Legal Medicine and Forensic Sciences, Gabinete Medico Legal de Torres Vedras, Portugal<sup>b</sup> Hospital Vila Franca de Xira, Lisbon, Portugal

## ARTICLE INFO

## Article history:

Received 13 April 2016

Received in revised form 29 May 2016

Accepted 3 June 2016

Available online xxx

## Keywords:

Intracranial lipoma

Brain lipoma

Sudden death

## ABSTRACT

Intracranial lipomas represent less than 0.1% of all intracranial tumors. They are usually located in the callus area and often asymptomatic. This paper presents a sudden death case after an episode of convulsions on a 39 years old woman with a history of migraines and seizures since adolescence. The autopsy revealed the presence of an undiagnosed massive brain lipoma (60 × 35 mm) associated with atrophy of the corpus callosum. Although very rare and seldom malignant these may be associated with seizures and sudden death.

© 2016 The Authors. Published by Elsevier Inc. This is an open access article under the CC BY-NC-ND license (<http://creativecommons.org/licenses/by-nc-nd/4.0/>).

## 1. Introduction

Intracranial lipomas (IL) represent less than 0.1% of all cerebral tumors [1–3]. They are considered congenital malformation caused by abnormal differentiation and persistence of the primitive meninx with transformation to adipose tissue during subarachnoid space development [4]. Most of IL are asymptomatic [5]. Seizures are the most common symptom [4–6].

## 1.1. Case report

We report the case of a 39 years old woman, obese, with an history of seizures during adolescence, no regular medication, alcohol abuse or cognitive impairment. Sudden death occurred after a seizure episode. The autopsy revealed the presence of a voluminous cerebral lipoma (60 × 35 mm) associated to corpus callosum (CC) atrophy (Fig. 1) and pulmonary edema. There were no relevant findings except the expected bite marks in the tongue and some bruising on the upper limbs compatible with seizures. The histological examination confirmed the diagnosis of lipoma showing that this mass was composed by fatty tissue. Toxicological testing was negative to alcohol, drugs and pharmaceutical drugs.

## 2. Discussion

Lipomas are benign tumors composed of fat tissue and are the most common soft tissue neoplasms of adult population. They are usually

painless and macroscopically soft and mobile. First described in 1856 by Von Rokitansky as an autopsy finding [7] their location in the central nervous system (CNS) is extremely rare. In the CNS they are most commonly located in the CC [5,6].

Several theories were proposed to explain IL origin. It is believed that defects in the reabsorption process of primitive meninx when forming the subarachnoid space and cisterns may result in meningeal tissue implantation as the source of IL cellular components. This theory explains the location of IL in the subarachnoid space and cisterns correlating the higher incidence of CC lipomas when compared to other CNS locations [8,9].

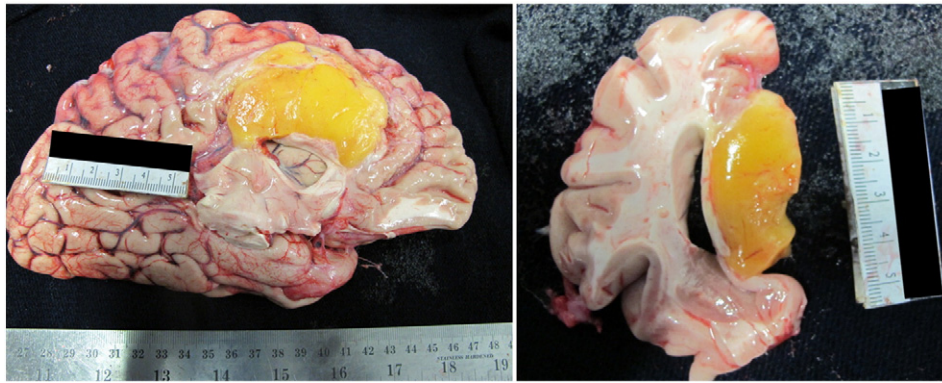
Macroscopically IL can vary from infracentimetric to large masses. They have a collagenous capsule adherent to the cerebral parenchyma. Vascularization is dependent on the anterior cerebral arteries or branches traversing the tumor. Eventually, a single large vessel can be found, divided in two, the pericallosal and the calloso marginal branches [8,9].

Microscopically IL is composed of typical adipose tissue and a capsule with variable quantity of collagen fibers which can penetrate the cerebral parenchyma in association with blood vessels. Calcifications can occur within the lipoma, its capsule and adjacent cerebral tissue. Due to these characteristics surgical removal is often unfeasible and conservative treatment assumes a major role controlling seizures [10].

## 3. Conclusion

IL is rare, generally asymptomatic and usually a radiological or autopsy find. They can be associated with seizures and a variety of clinical manifestations depending on their size and location. This case-report is

\* Corresponding author at: Orthopaedic Surgeon and Forensic Expert, Hospital Vila Franca Xira, Estrada Nacional n°1, Povos, 2600-009 Vila Franca de Xira, Lisboa, Portugal.  
E-mail address: [drcarlosduro@hotmail.com](mailto:drcarlosduro@hotmail.com) (C. Durão).



**Fig. 1.** A voluminous cerebral lipoma.

an example of a non-diagnosed voluminous lipoma as the cause of a fatal convulsive seizure.

### References

- [1] G. Jabot, S. Stoquart-Elsankari, G. Saliou, P. Toussaint, H. Deramond, P. Lehmann, Intracranial lipomas: clinical appearances on neuroimaging and clinical significance, *J. Neurol.* 256 (6) (2009) 851–855.
- [2] D.F. Silva, M.M. Lima, C.O. Oliveira, W.N. Oliveira, R. Anghinah, J.G. Lima, Agenesis and lipoma of corpus callosum. Case report, *Arq. Neuropsiquiatr.* 53 (1995) 667–670.
- [3] P. Bailey, *Intracranial Tumors*, Charles C Thomas Publisher, Springfield III, 1933 354.
- [4] A.C. Sarioglu, M.Y. Kaynar, M. Hanci, M. Uzan, Sylvian fissure lipomas: case reports and review of the literature, *Br. J. Neurosurg.* 13 (4) (1999) 386–388.
- [5] H. Regis, J.L. Gastaut, E. Yermenos, M.D. Low, Lipomas of the corpus callosum and epilepsy, *Neurology* 30 (1980) 132–138.
- [6] H. Gastaut, H. Regis, J.L. Gastaut, E. Yermenos, M.D. Low, Lipomas of the corpus callosum and epilepsy, *Neurology* 30 (1980) 132–138.
- [7] C. Rokitansky, *Lehrbuch der pathologischen anatomie*, Braumuller, Vienna, 1856.
- [8] D. Wallace, Lipoma of the corpus callosum, *J. Neurol. Neurosurg. Psychiatry* 39 (1976) 1179–1185.
- [9] R.P. Tart, R.G. Quisling, Curvilinear and tubulonodular varieties of lipoma of the corpus callosum: an MR and CT study, *J. Comput. Assist. Tomogr.* 15 (1991) 805–810.
- [10] F. Tankéré, E. Vitte, N. Martin-Duverneuil, J. Soudant, Cerebellopontine angle lipomas: report of four cases and review of the literature, *Neurosurgery* 50 (3) (2002) 626–631.