

# Unusual Palatal Presentation of Oral Psoriasis

(Manifestation palatale inhabituelle du psoriasis buccal)

- Lisa J. Richardson, DDS •
- F. James Kratochvil, DDS •
- Monica B. Zieper, DMD, MS •

## S o m m a i r e

*Les lésions buccales du psoriasis sont rarement observées à l'examen clinique. D'après des rapports bien documentés sur le psoriasis buccal, les lésions varient. Elles se manifestent sous forme de plaques rouges ou blanches, ou d'ulcères. Dans le présent article, on décrit une manifestation palatale inhabituelle du psoriasis buccal sous forme d'arcs concentriques serpigneux. Le diagnostic du psoriasis intra-buccal s'appuie sur des découvertes cliniques et microscopiques.*

**Mots clés MeSH :** case report; mouth mucosa/pathology; psoriasis/pathology

© J Can Dent Assoc 2000; 66:80-2

Le présent article a fait l'objet d'une révision par des pairs.

Psoriasis is a common dermatologic disease. It can occur at any age but usually first develops during young adult life and may persist throughout a person's lifetime with periods of exacerbation and remission.<sup>1</sup> The exact etiology of psoriasis is unknown, but it appears to be a multifactorial disease with both genetic and psychosomatic factors.<sup>2</sup> Various triggers, such as trauma, infection and stress, may cause new episodes. The epidermal changes that occur in psoriasis seem to be related to a defect in keratinocyte proliferation. The hyperproliferative state of the affected epidermis produces a turnover rate that is up to eight times greater than normal.<sup>1</sup>

Clinically, skin lesions appear as papules and plaques covered by silvery scales. When the scales are removed, small pinpoint bleeding is seen (Auspitz sign).<sup>1</sup> Skin lesions are predominantly found on the individual's extremities and scalp.<sup>3</sup>

The microscopic appearance of psoriasis varies with lesion age and activity. The early lesion shows parakeratosis and acanthosis with budding at the tips of the rete ridges and thinning of the suprapapillary plate. Polymorphonuclear leukocytes migrate through the epithelium with the formation of intraepithelial microabscesses.<sup>1,3,4</sup> Although the formation of microabscesses (Munro abscesses) is characteristic of psoriasis, it is not specific to the disease nor are the microabscesses always present.<sup>3</sup> Within the connective tissue papilla, engorgement of the capillaries occurs and a mixed inflammatory cell infiltrate is commonly seen.<sup>1,4</sup> In the oral cavity, this microscopic presentation, known as psoriasisiform mucositis, is shared by psoriasis, Reiter's syndrome (a disease

of unknown origin characterized by the triad of urethritis, arthritis and conjunctivitis), benign migratory glossitis (also known as geographic tongue) and erythema migrans (lesions that are clinically and histologically similar to geographic tongue but involve oral mucosa other than the dorsum of the tongue).<sup>5</sup>

Oral lesions of psoriasis are rare clinical observations. Early reports of intraoral psoriasis lacked microscopic confirmation of the clinical findings. As a result, the number of cases reported and the incidence of intraoral psoriasis cannot be accurately determined from the literature. Reports of oral psoriasis that are well documented show no consistent lesion pattern. Patterns range from raised, white, scaling lesions predominantly on the palate or buccal mucosa to well-demarcated, flattened, erythematous lesions with a slightly raised, white, annular or serpiginous border.<sup>5</sup> These latter lesions closely resemble geographic tongue. Oral lesions may disappear quickly or they may undergo exacerbations or remissions concomitantly with skin lesions.<sup>5</sup> Diagnosis of oral psoriasis is best made when the clinical course of the oral lesion parallels that of the skin disease and is supported by microscopic findings.<sup>5</sup>

This report presents an unusual palatal presentation of oral psoriasis. The diagnosis of intraoral psoriasis is supported by clinical and histopathologic findings.

## Case Report

A 51-year-old male presented to the graduate periodontology clinic for a complete periodontal evaluation. The patient's medical

history was evaluated by questionnaire and interview. The patient had been diagnosed with a bipolar disorder in the early 1980s and with psoriasis in the mid 1980s. There was no family history of dermatologic problems. At the time of examination and treatment, the patient was on gabapentin (Neurontin) 300 mg 3X/day for treatment of the bipolar disorder.

Extraorally, the patient presented with psoriatic lesions on the scalp and elbows (Figs. 1 and 2). No oral lesions were noted at the time of initial presentation; however, at the second visit three weeks later, asymptomatic red serpiginous linear lesions on the posterior half of the hard palate were noted (Fig. 3). A diagnosis of erythema migrans or intraoral psoriasis was made. After informed consent was obtained, a confirmatory incisional biopsy was taken using a 6-mm-diameter biopsy punch.

Microscopic examination (Fig. 4) revealed sections of mucosa surfaced with hyperparakeratotic stratified squamous epithelium with moderately developed rete pegs. Central portions of the specimen exhibited mild psoriasiform mucositis consisting of "test tube" rete pegs, thinning of the suprapapillary plate and engorgement of capillaries in the connective tissue papilla. There was mild exocytosis of inflammatory cells into the epithelium. The lamina

propria contained a mild chronic inflammatory cell infiltrate. Periodic acid-Schiff (PAS) stain for fungal elements was negative.

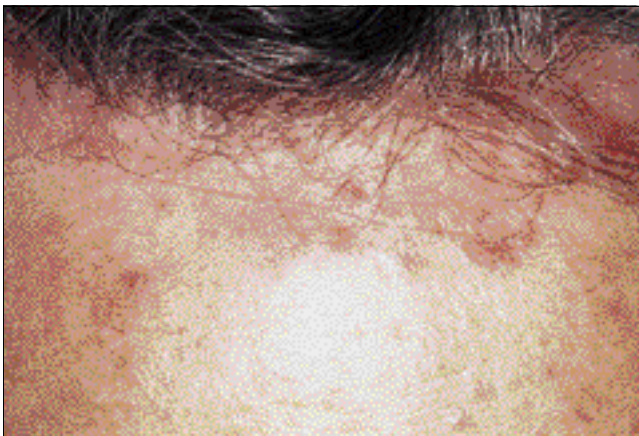The lesion resolved on its own and had disappeared completely one month after the biopsy was taken.

The clinical and microscopic features of the palatal lesion were consistent with psoriasiform mucositis, and the patient's pre-existing cutaneous psoriasis supports the diagnosis of intraoral psoriasis.

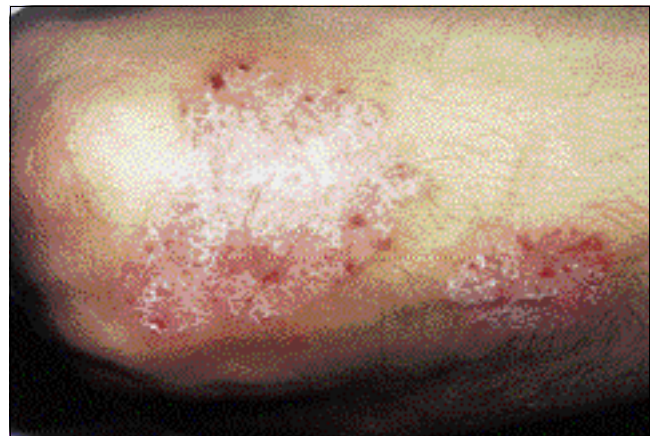### Discussion

A biopsy was taken in this case to confirm the clinical impression of intraoral psoriasis. When more common causes of red lesions are eliminated (fungal infection, denture irritation), a biopsy enables the clinician to recognize and rule out more serious causes. The diagnosis then directs the clinician to the most suitable treatment for the patient's condition. In this case, the lesion was diagnosed as intraoral psoriasis and was asymptomatic; therefore, no treatment was provided. Symptomatic presentations of intraoral psoriasis have been treated with topical or local injections of corticosteroids.<sup>6-8</sup> Treating oral psoriasis is unnecessary unless the patient's symptoms require attention.

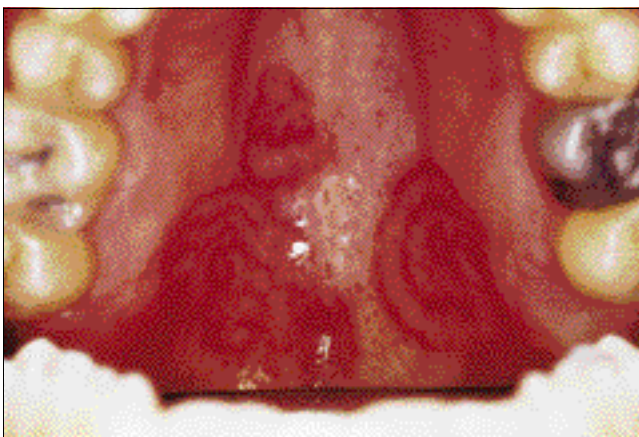
In 1997, Younai and Phelan<sup>8</sup> reviewed the literature and presented a case of oral mucositis with features of psoriasis. Their



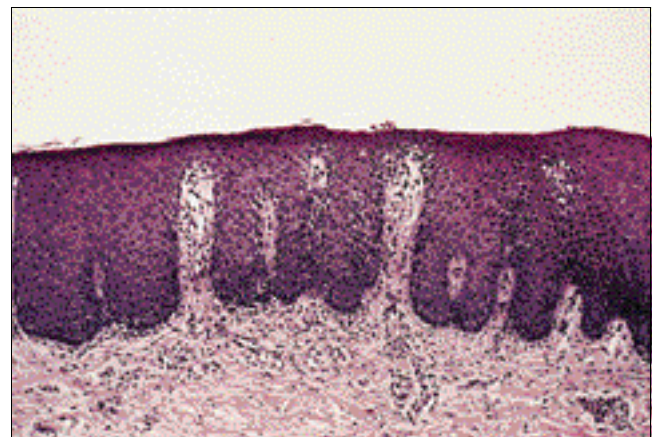
**Figure 1:** Psoriatic lesions on the patient's scalp. The patient's cutaneous lesions presented as silvery scales.



**Figure 2:** Psoriatic lesions on the patient's elbow.



**Figure 3:** Clinical presentation of the patient's palate. The intraoral psoriasis presented as red serpiginous linear lesions on the posterior half of the hard palate.



**Figure 4:** Haematoxylin-and-eosin-stained section of tissue biopsied from the patient (medium magnification). The specimen exhibits elongation of the rete ridges into test-tube shapes, thinning of the suprapapillary plate and engorgement of the capillaries in the connective tissue papilla.

review of the English-language and European literature identified 57 reported cases of oral psoriasis. This review excluded cases of geographic tongue seen in patients with cutaneous psoriasis, resulting in a lower number than identified in the 1990 review by Sklavounou and Laskaris.<sup>7</sup> Younai and Phelan found that the 46 lesions reported in the English literature could be divided into two large categories (20 white lesions and 11 erythematous lesions) and five smaller categories (6 lesions with a mixed white and red appearance, 5 ulcerative lesions, 2 vesicular lesions, 1 pustular lesion and 1 indurated lesion). The oral lesions presented on various surfaces within the oral cavity, including the lip, the buccal mucosa, the tongue, the gingiva, the palate and the floor of the mouth. The cases of psoriasis on the palate had the appearance of erythematous patches with or without ulcerations.<sup>5,9-13</sup> The present case is therefore unique with its red serpiginous concentric arcs.

Weathers' article<sup>5</sup> on psoriasiform lesions discussed several pathologic conditions that can involve the oral cavity. Psoriasis, Reiter's syndrome, benign migratory glossitis and erythema migrans have similar clinical and histologic findings.<sup>5</sup> Therefore, when microscopic examination reveals a psoriasiform lesion, it is important to consider the clinical presentation of the patient. In the current case, the presence of skin lesions, the clinical location of the oral lesion, the microscopic presentation and the absence of the triad of symptoms known to characterize Reiter's syndrome support the diagnosis of oral psoriasis. ♦

---

Le Dr Richardson est diplômée du Département de parodontologie à la Faculté de médecine dentaire de l'Université des sciences de la santé de l'Orégon.

Le Dr Kratochvil est professeur agrégé et directeur du Département de pathologie buccale à la Faculté de médecine dentaire de l'Université des sciences de la santé de l'Orégon.

Le Dr Zieper est professeure adjointe au Département de pathologie buccale à la Faculté de médecine dentaire de l'Université des sciences de la santé de l'Orégon.

Écrire au : Dr Lisa J. Richardson, Oregon Health Sciences University, School of Dentistry, Department of Graduate Periodontology, 611 SW Campus Dr., Portland, OR 97201 USA

Les auteurs n'ont aucun intérêt financier déclaré.

---

## Références

1. Regezi JA, Sciubba JJ, editors. *Oral pathology: clinical-pathologic correlations*. Philadelphia: WB Saunders; 1989. p. 134-41.
2. Watson W, Cann HM, Faber EM, Nall ML. The genetics of psoriasis. *Arch Dermatol* 1972; 105:197-207.
3. Montgomery H. *Dermatopathology*. New York: Harper & Row; 1967. p. 309-52.
4. Lever WF. *Histopathology of skin*, 4th ed. Philadelphia: J.B. Lippincott Company; 1967. p. 141-4.
5. Weathers DR, Baker G, Archard HO, Burkes EJ Jr. Psoriasiform lesions of the oral mucosa (with emphasis on "ectopic geographic tongue"). *Oral Surg Oral Med Oral Pathol* 1974; 37:872-88.
6. Ulmanky M, Michelle R, Azaz B. Oral psoriasis: report of six new cases. *J Oral Pathol Med* 1995; 24:42-5.
7. Sklavounou A, Laskaris G. Oral psoriasis: report of a case and review of the literature. *Dermatologica* 1990; 180:157-9.
8. Younai FS, Phelan JA. Oral mucositis with features of psoriasis: report of a case and review of the literature. *Oral Surg Oral Med Oral Pathol Oral Radiol Endod* 1997; 84:61-7.
9. Levin HL. Psoriasis of the hard palate. *Oral Surg Oral Med Oral Pathol* 1954; 7:280-6.
10. Norins A, Yaffee H. Psoriasis of the hard palate. *AMA Arch Dermatol* 1957; 76:357-8.

11. Baker H, Ryan TJ. General pustular psoriasis. A clinical and epidemiological study of 104 cases. *Br J Dermatol* 1968; 80:771-93.
12. White DK, Leis HJ, Miller AS. Intraoral psoriasis associated with widespread dermal psoriasis. *Oral Surg Oral Med Oral Pathol* 1976; 41:174-81.
13. Eastman JR, Goldblatt LI. Psoriasis. Palatal manifestations and physiologic considerations. *J Periodontol* 1983; 54:736-9.

---

## CENTRE DE DOCUMENTATION DE L'ADC

---

### Dossier de documentation, février 2000

Le dossier de ce mois-ci renferme toute une documentation sur les soins dentaires offerts aux personnes atteintes d'une maladie débilante. Les membres de l'ADC peuvent se le procurer pour la somme de 10 \$, taxes applicables en sus.

Pour obtenir une liste complète des dossiers de documentation, veuillez composer le 1-800-267-6354 ou consulter le site Web de l'ADC à [www.cda-adc.ca](http://www.cda-adc.ca). Une fois sur le site, cliquez sur Membres ADC, puis sur Centre de documentation pour obtenir la liste des dossiers.

### Nouvelles acquisitions

Buchanan, L.S. *Shaping root canals*, vol. I and II. [2 videos] Dental Education Laboratories, 1999.

Curzon, M.E.J. *Handbook of dental trauma: a practical guide to the treatment of trauma to the teeth*. Wright [Butterworth] 1999.

Ord, R.A. and Blanchaert, R.H. *Oral cancer: the dentist's role in diagnosis, management, rehabilitation, and prevention*. Quintessence Books, 2000.

Feinmann, C. *The mouth, the face and the mind*. Oxford, 1999.

Ranalli, D.N. *Advances in sports dentistry*. Dental Clinics of North America, January 2000.

### Index annuel

Vous pouvez consulter l'index annuel de 1999 sur le site Web de l'ADC en accédant à l'eJADC. Les membres de l'ADC qui désirent obtenir une copie imprimée de l'index sont priés de communiquer avec le Centre de documentation de l'ADC.