






## Updates in mechanical thrombectomy

Kevin Pierre<sup>1\*</sup>, Carlos Perez-Vega<sup>2</sup>, Anna Fusco<sup>3</sup>, Bankole Olowofela<sup>3</sup>, Rami Hatem<sup>3</sup>, Mohammed Elyazeed<sup>4</sup>, Mohammed Azab<sup>5</sup>, Brandon Lucke-Wold<sup>4</sup>

<sup>1</sup>Department of Radiology, University of Florida, Gainesville, FL 32608, USA

<sup>2</sup>Department of Neurosurgery, Mayo Clinic, Jacksonville, FL 32224, USA

<sup>3</sup>College of Medicine, University of Florida, Gainesville, FL 32610, USA

<sup>4</sup>Department of Neurosurgery, University of Florida, Gainesville, FL 32608, USA

<sup>5</sup>Biomolecular Sciences Graduate Program, Boise State University, Boise, ID 83725, USA

**\*Correspondence:** Kevin Pierre, Department of Radiology, University of Florida, 1600 SW Archer Rd, Gainesville, FL 32608, USA. [kpierre150@gmail.com](mailto:kpierre150@gmail.com)

**Academic Editor:** Dirk M. Hermann, University of Duisburg-Essen, Germany

**Received:** August 29, 2022 **Accepted:** September 26, 2022 **Published:** December 30, 2022

**Cite this article:** Pierre K, Perez-Vega C, Fusco A, Olowofela B, Hatem R, Elyazeed M, et al. Updates in mechanical thrombectomy. *Explor Neurosci.* 2022;1:83–99. <https://doi.org/10.37349/en.2022.00007>

### Abstract

Stroke is a leading cause of morbidity and mortality. The advent of mechanical thrombectomy has largely improved patient outcomes. This article reviews the features and outcomes associated with aspiration, stent retrievers, and combination catheters used in current practice. There is also a discussion on clinical considerations based on anatomical features and clot composition. The reperfusion grading scale and outcome metrics commonly used following thrombectomy when a patient is still in the hospital are reviewed. Lastly, there are proposed discharge and outpatient follow-up goals in caring for patients hospitalized for a stroke.

### Keywords

Stroke, ischemic infarct, mechanical thrombectomy, catheters, aspiration, stent retrievers

### Introduction

Strokes are the 5th leading cause of death in the United States, accounting for over 160,000 deaths in the nearly 800,000 annually affected individuals and resulting in significant long-term disability in many survivors [1, 2]. Though the incidence of stroke has decreased, increased longevity has resulted in elevated lifetime risk (24.9% in 2016 vs. 22.8% in 1990) [3]. As 87% of strokes are ischemic, intravenous (IV) thrombolysis using tissue plasminogen activator (tPA) can be used for patients presenting with stroke within 4.5 h [1]. However, mechanical thrombectomy (MT) is now the new standard of care in ischemic stroke in appropriate candidates [1, 4–7]. It has been proven more effective than thrombolysis alone in several randomized control trials [8, 9].

MT is used for stroke caused by large anterior circulation artery occlusions. Patients may be treated within 24 h of symptom onset regardless of prior tPA administration [10]. With modern techniques and technology, there is often recanalization of over 80% of the lumen diameter [11]. While MT may be used to treat patients with posterior circulation (PC) strokes, the benefits are not as well-established [10].

© The Author(s) 2022. This is an Open Access article licensed under a Creative Commons Attribution 4.0 International License (<https://creativecommons.org/licenses/by/4.0/>), which permits unrestricted use, sharing, adaptation, distribution and reproduction in any medium or format, for any purpose, even commercially, as long as you give appropriate credit to the original author(s) and the source, provide a link to the Creative Commons license, and indicate if changes were made.



In MT, obstructed arteries are accessed via microcatheters, through which a thrombectomy device is passed [12]. Categories of MT devices include coil retrievers, stentriever, aspiration catheters, and mechanical clot disruption apparatuses [12]. Coil retrievers are delivered to the clot via a microcatheter and deployed at a destination across the clot. Once the coil engages the clot, revascularization is achieved by pulling the coil-clot complex back into the catheter [13]. Like the coil retriever, the stentriever is delivered via a microcatheter. The self-expanding stent is positioned inside the thrombus, allowing its appendages to intertwine with the thrombus, and is subsequently drawn back into the catheter used for delivery [13]. Aspiration devices use vacuum suction to remove clots from occluded arteries [12, 13]. The addition of a separator wire with a bulbous tip that can be pushed and pulled to detach a clot from the lumen addresses aspiration device tip clogging or congestion [12]. There has also been an increasing use of combination catheters that employ the use of aspiration catheters with coil retrievers and stentriever.

The type of MT device used to treat a patient with stroke is determined by the clinical scenario and judgment of the operating neuro-interventionalist.

Complications, such as hemorrhage and successive embolization by thrombus fragmentation, may be seen in MT with all devices. Complications appear to be more frequent with the use of coil retrieval and aspiration (10%) when compared to stentriever (2–4%) [13].

Patient factors also influence response to MT therapy. Area of ischemia may influence patient recovery following stroke as treatment of white matter infarcts shows better recovery than that of gray matter infarcts [14]. Good collateral circulation has also been associated with improved outcomes and decreased rates of complication following stroke [15]. In addition, hyperglycemia and the amount of time between the onset of symptoms and achievement of reperfusion have been shown to have a significant impact of patient outcome [16, 17].

## Stent retrievers

Detachable stents are widely used to assist the revascularization of vascular stenosis or to support the coiling of intracranial aneurysms. Non-detachable stents showed promising *in vitro* and *in vivo* outcomes for clot and foreign body removal and introduced a second generation of clot retrievers for patients with acute ischemic stroke [18, 19]. Non-detachable stents (stent retrievers) are temporarily placed in the cerebral vasculature and restore blood flow by the expansion of the stent within the occluded vessel. The stent retriever mesh then embeds into the clot and allows for clot retrieval when removing the stent [20]. This type of device improved previous MT techniques by providing immediate blood flow restoration and more effective target thrombus retrieval. Stent retrievers are often combined with a balloon guide catheter (BGC) that may be inflated to arrest anterograde flow and allow aspiration [21]. Based on the SWIFT randomized trial, the first stent retriever approved by the Food and Drug Administration (FDA) in 2012 was the Solitaire FR [22]. A number of different devices have also surfaced in the last few years including Trevo XP, Merci, EmboTrap, Versi, Embolus Retriever with Interlinked Cages (ERIC), Tigertriever, among others. An overview of the different stent retrievers currently available in the market can be found in Table 1.

**Table 1.** Stent retrievers

Stent retriever	Company	FDA approval	Design/Shape	Study	Outcomes
Solitaire FR	Medtronic	2012	Self-expanding stent cut into a nitinol plate with a honeycomb pattern	SWIFT-PRIME [19] SWIFT-DIRECT [23] REVASCAT [24] EXTEND-IA [25] ESCAPE [26]	Successful revascularization achieved in 91% (thrombectomy alone; up to 96% with alteplase)
Trevo XP	Stryker	2012	Self-expanding stent with a unique distal shaped section for clot retrieval; its platinum marker allows fluoroscopic control of the distal portion	DAWN [27] TREVO 2 [28]	Successful revascularization achieved in 86%

**Table 1.** Stent retrievers (*continued*)

Stent retriever	Company	FDA approval	Design/Shape	Study	Outcomes
Merci	UCLA Health	2004	Stent formed of nitinol with a characteristic helical shape that traps the clot once deployed. Often combined with BGC to prevent antegrade flow	MERCI [29] SWIFT [22] TREVO 2 [28]	Successful revascularization achieved in 60%; 19% device-related subarachnoid hemorrhage
EmboTrap	Johnson and Johnson	2018	Dual-layer construct to improve clot engagement and distal mesh to reduce emboli	ARISE [30]	Successful revascularization achieved in 80.2%; 67% with functional independence at 90 days
Versi	NeuroVasc		Stent formed with nitinol that has three articulated stent segments that facilitate opening during retrieval	Sakai et al. [31]	Successful revascularization achieved in 100% (11 patients); 72.7% favorable functional outcomes (mRS 0–2) at 90 days
ERIC	MicroVention Terumo		Three to five interlinked cages preventing the clot from shearing off during retraction	ETIS [32]	Successful revascularization achieved in 82%; 40% favorable outcome (mRS ≤ 2)
Tigertriever	Rapid Medical		Device with handle that allows physician to expand or contract the mesh	Kara et al. [33]	Successful revascularization achieved in 75.4%; 27.9% with favorable clinical outcomes

mRS: modified Rankin scale; UCLA: University of California, Los Angeles

Although these stent retrievers operate by the same principle of retrieving a clot and restoring blood flow, differences in design and shape have resulted in variable revascularization rates. The Solitaire FR stent retriever is the most widely studied device with multiple clinical trials already completed; it is a self-expanding stent cut into a nitinol plate with a honeycomb pattern, showing a 91% reperfusion rate in the recent SWIFT-DIRECT study [23], supporting the use of alteplase before thrombectomy in eligible patients (96% reperfusion). Trevo XP is another widely used self-expanding stent retriever with a unique distal shaped section for clot retrieval; its platinum marker allows fluoroscopic control of the distal portion. In the TREVO 2 trial, this stent retriever showed 86% successful revascularization, which was significantly higher when compared to the Merci stent retriever (60%) [28]; the latter is also formed of nitinol but has a characteristic helical shape that traps the clot once deployed [34]. Other stent retrievers including EmboTrap (dual-layer construct to improve clot engagement and distal mesh to reduce emboli) [35], Versi (three articulated stent segments that facilitate opening during retrieval) [31], ERIC (three to five interlinked cages preventing the clot from shearing off during retraction) [36], and Tigertriever (a device with handle that allows physician to expand or contract the mesh) [33] have been studied less extensively. The SWIFT-DIRECT study demonstrated increased revascularization in patients administered IV thrombolytics prior to MT using the Solitaire FR stent retriever [23], while stent retrievers other than Solitaire FR are often combined with thrombolytic therapy or administered following unsuccessful thrombolysis with tPA, the literature is relatively limited, suggesting the need for further research in this area.

Multiple studies have analyzed and compared stent retrievers for revascularization rate differences and potential complications. Solitaire FR is often analyzed against Trevo XP. Though many studies report non-significant differences in revascularization and complication rates [37, 38], Trevo XP usually has shorter procedural time, decreased number of stent passages, and higher successful recanalization than Solitaire FR in studies showing statistically significant differences [39, 40].

## Aspiration devices

Intermediate or distal access catheters are used for direct contact aspiration using negative pressure with an aspiration pump or syringe to dislodge the clot [41]. In addition to aspiration ability, the performance of

these catheters is often judged by the ease of navigation, a feature of malleability depending on the catheter components. The device liner is made from a malleable substance such as polytetrafluoroethylene that ensures proper advancement through tortuous vasculature [42]. The aspiration capacity of the catheter is directly proportional to the inner diameter and the negative pressure magnitude [43]. It is proposed that higher catheter to vessel diameters achieve better perfusion because of increased force acting on the clot [44].

The Penumbra aspiration device was FDA-approved in 2008 [29]. This device allows the operator to perform clot fragmentation and aspiration by moving the catheter in and out [45]. The penumbra pivotal stroke trial demonstrated safe use up to 8 h from stroke onset and an 82% recanalization rate in 125 patients [45]. This aspiration device shows similar clinical outcomes to the Solitaire FR stent retriever in a retrospective review of 76 patients [46]. However, it demonstrated higher rates of complete recanalization with lower device passage count, shorter procedure times, and shorter recanalization times [46–50].

Other catheters are less well-studied. Those that are studied generally prove to be safe and effective [43, 51–54]. For example, REACT catheters achieved recanalization in 89–96% of cases and resulted in a rate of 24–36% of functional independence in 299 patients across three studies [43, 51, 55, 56]. Selected catheters currently available on the market are listed (Table 2) [53, 57–61].

**Table 2.** Aspiration devices

Company	Catheters
Penumbra [57]	RED 72, RED 68, RED 62 Penumbra JET 7, Penumbra JET D ACE68, ACE60 3MAX, 4MAX, 5MAX
Medtronic [58]	REACT 68, REACT 71
Stryker [59]	AXS Vecta 71, AXS Vecta 74
MIVI Neuroscience [60]	Super Q 3F, Super Q 4F, Super Q 5F, Super Q 6F
MicroVention Terumo [61]	SOFIA 6F

## Combination techniques

It is important to note that various combined techniques with stent retrievers, distal aspiration catheters, and BGCs are used in many centers with good outcomes [62]. A recent meta-analysis demonstrated that the combined use of the aspiration catheter and stent retriever result in a superior first pass effect (40.8%) compared to stent retrievers alone (32.6%;  $P < 0.0001$ ). However, they did not result in statistically significant improvements in functional independence and reperfusion [63]. Examples of combination techniques include the BALloon guide with large bore Distal access catheter with Dual Aspiration with Stent retriever as Standard approach (BADDASS) technique [64], the REACT catheter combined with a stent retriever [56], aspiration-retriever technique for stroke (ARTS) [65], a stent retrieving into an aspiration catheter with proximal balloon (ASAP) technique [66], the stent retriever-assisted vacuum-locked extraction (SAVE) approach [67], and PROximal balloon Occlusion TogetHER with direCt Thrombus aspiration during stent retriever thrombectomy (PROTECT<sup>PLUS</sup>) [68]. Clinical experience with these techniques suggests they are safe and effective [64, 65, 67–69].

## Clinical considerations

PC strokes are ischemic infarcts occurring in the vertebrobasilar arterial system [70]. They constitute approximately one-fifth of ischemic strokes and are managed differently from anterior circulation strokes [71].

Anatomical PC variants are relatively common in the PC and must be taken into account by the treating physician [70]. Roughly half the population has an incomplete circle of Willis. Another variation is the fetal posterior cerebral artery (FPCA), representing a posterior cerebral artery (PCA) arising from the internal carotid artery (ICA). Most are unilateral. When bilateral, they are often associated with a small caliber basilar

artery. It is important to note that these FPCAs do not carry increased stroke risk [72, 73]. However, patients with hypoplastic vertebral arteries have increased PC stroke risk [74].

Thrombi at the terminal ICA, middle cerebral artery bifurcation, or trifurcations often prove difficult in attempting recanalization. In such cases, contact aspiration is often beneficial when recanalization with stent retrievers proves unsuccessful [75, 76]. Combination aspiration and stent retriever methods may also be beneficial in such situations [65, 77].

Like tPA administration, MT shows better outcomes when done in the first 3 h to 4.5 h following the initial stroke [78]. It is considered safe to recanalize PC 24 h prior to the ischemic event [76, 79, 80].

## Implications of thrombus composition

The histopathological clot composition determines recanalization difficulty. Clots are generally either rich in red blood cells (RBCs) or fibrin [81]. RBC-rich thrombi are generally more malleable and therefore more engageable. However, fibrin-rich thrombi are stiffer and therefore are less likely to fragment and theoretically should have lower embolization rates [82, 83]. Fibrin-rich thrombi generally require more recanalization attempts compared to thrombi rich with RBCs [83].

Studies suggest that computed tomography angiography (CTA) and magnetic resonance imaging (MRI) can determine clot composition. For example, clots with the hyperdense middle cerebral artery sign (HMCAS) and blooming artifact (BA) are more likely to be RBC-rich. Conversely, the absence of the HMCAS and BA likely indicated thrombi predominant in fibrin [84, 85]. An early study by Liebeskind et al. [84] demonstrated that HMCAS was seen in 100% of patients with RBC-dominant clot with a significant correlation between the degree of RBC composition and the presence of HMCAS. Similarly, BA was present in all patients with RBC-dominant clots [84]. A later systematic review reinforced these associations [86]. Therefore, it is important to consider the use of proximal balloon catheters in clots with HMCAS and BA to minimize embolization risk considering the clot is likely to be RBC-dominant [87, 88]. Furthermore, newer *ex vivo* studies are promising. Diffuse reflectance spectroscopy (DRS) detects RBC-rich clots with sensitivity and specificity of 0.722 and 0.846, respectively. DRS also discriminated between RBC- and fibrin-rich clots [89]. Another study showed that fibrin-rich have high penetrating homogeneous signals and RBC-rich clots have superficial low penetrating signals on optical coherence tomography (OCT) [90]. Lastly, an *in vitro* study revealed that Mono +50 keV dual energy computed tomography (CT) can successfully differentiate clot composition in an *ex vivo* model [91]. Recent *in vivo* studies incorporating machine learning in differentiating thrombus composition are also promising [92, 93].

## Short-term outcomes

Several clinical outcome metrics are commonly used post thrombectomy during hospitalization. Important metrics include reperfusion success, the mRS, the National Institutes of Health Stroke Scale (NIHSS), and the occurrence of symptomatic intracerebral hemorrhage (sICH) [94–97]. Patients who achieve successful reperfusion post thrombectomy experience better clinical outcomes than those who are unsuccessfully reperfused [98, 99]. The mRS is a valid and reliable clinician-reported measure of global disability in patients who have suffered a stroke [94]. It can be measured over time (at discharge, at 30 days, and at 90 days) to assess health outcomes. The mRS ranges from 0 (no disability) to 6 (death). A score of 0–3 at hospital discharge is an early favorable outcome for independent ambulation [100]. Additionally, providers widely use the NIHSS as an indicator for functional outcomes and early mortality. It is a 15-item neurological examination scale investigating the impact of cerebral infarction on the level of consciousness, visual fields, neglect, extraocular movements, strength, ataxia, sensation, and dysarthria. Patients with lower NIHSS had much better survival rates than those with significantly higher scores [101, 102]. sICH potentially increases the risk of functional dependence and was found to increase their ninety-day mortality [96, 97].

Reperfusion success following MT has been measured and categorized into five different grades by the thrombolysis in cerebral infarction (TICI) scale, yet there is variability in definitions [98]. Reperfusion is graded by visually examining the extent of tissue reperfusion as depicted by the capillary blush on

a digital subtraction angiography [103, 104]. The TICI scale spans from no perfusion (grade 0) to complete reperfusion (grade 3), with grade two subdivided into groups 2a and 2b (Table 3).

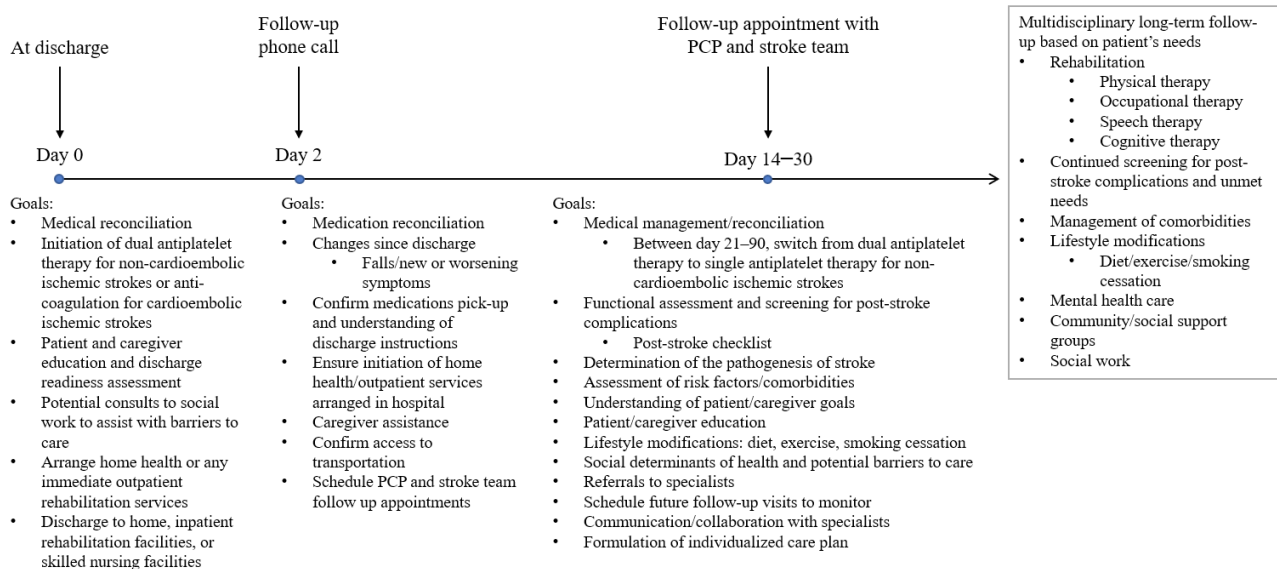
**Table 3.** TICI scale [104]

Category	Description
Grade 0	No perfusion
Grade 1	Minimal flow past the occlusion but no perfusion
Grade 2a	Minor partial reperfusion (< 50%)
Grade 2b	Major partial reperfusion (> 50%)
Grade 3	Complete reperfusion with no flow defects

Patients who undergo mechanical thrombectomies are closely monitored postoperatively in the neuro-intensive care unit (ICU). The first 24 h following intervention are the most crucial and require heightened awareness of complications. Potential complications include, but are not limited to, access site complications, vasospasms, iatrogenic arterial dissections, hemorrhagic complications, and embolic and ischemic events [105]. Thus, inpatient care includes continuous monitoring of vital signs and serial assessment of neurological and neurovascular status [106]. Suspected changes in the patient's neurological assessment should be immediately reported to the team. Airway and oxygenation should be strictly monitored. Recommendations exist to maintain oxygen saturation above 94% in patients who have suffered from acute ischemic strokes [107]. Additionally, strict control of blood pressure management tends to lead to better outcomes; guidelines recommend always maintaining a systolic blood pressure of 140–180 mmHg with mean arterial pressure (MAP) greater than or equal to 70 mmHg [108]. Post-operative care also includes assessment of the groin site and distal extremities for infection, hematoma, or femoral nerve injuries.

## Long-term outcomes

Research evaluating post-discharge care after stroke treated with MT is lacking. It is not yet known whether follow-up for MT should differ from more traditional treatment options. The optimal strategy for post-discharge care for stroke patients in general is still being elucidated as researchers and clinicians work to determine the most beneficial and feasible way to help patients transition from the hospital to long-term follow-up. Depending on their functional status and individual needs, after acute care in the hospital, patients can be discharged home with outpatient follow-up or home health care, to a skilled nursing facility, to a long-term acute care hospital, or to inpatient rehabilitation [109–111]. The transition from the hospital to home can be especially difficult and patients and their caregivers often feel overwhelmed and unprepared as transitional care remains fragmented between providers and varied between hospitals [112–117]. Current American Stroke Association/American Heart Association guidelines emphasize a structured, individualized, and interdisciplinary approach to post-acute care. Follow-up should be focused on patient and caregiver education and support, screening for post-stroke complications, management of comorbidities and modifiable risk factors, and referral to community support and local outpatient resources [109, 118–120]. A current model for transitional care between discharge and long-term follow-up integrating current guidelines and evidence-based approaches is proposed (Figure 1) [109, 110, 117, 119–135]. This model includes a follow-up telephone call two days post-discharge and early follow-up with both a primary care physician and the stroke team. Based on the patient's individual deficits and needs, an individualized care plan should be designed, referrals should be sent to rehabilitation specialists, and long-term follow-up care should be initiated.



**Figure 1.** Recommended post-stroke objectives. PCP: primary care provider

Long-term follow-up focuses on continued rehabilitation, screening and treatment of post-stroke complications, and secondary prevention of stroke [109, 120, 127, 131]. Continued long-term follow-up visits and tools such as the post-stroke checklist can be used to routinely screen patients for post-stroke sequelae such as inability to perform activities of daily living, immobility, falls, swallowing dysfunction, spasticity, pain, incontinence, communication deficits, cognitive impairments, depression or anxiety, and social isolation [117]. Physical, speech, occupational, and cognitive therapy can help provide functional recovery and help patients adapt to continued deficits following a stroke [120, 131, 136]. Earlier rehabilitation is strongly associated with greater functional recovery [137-142]. Secondary prevention of stroke is accomplished through medications, management of comorbidities, and lifestyle changes. Patients with a non-cardioembolic ischemic stroke are prescribed dual antiplatelet therapy in the hospital which should be continued for 21-90 days [126, 143]. After 90 days, patients should be switched to single antiplatelet therapy such as low dose aspirin to prevent the recurrence of stroke [127]. Patients with a cardioembolic ischemic stroke should be started directly on anticoagulation such as warfarin, factor Xa inhibitors, and thrombin inhibitors [126, 127, 143]. Comorbidities such as hypertension, hyperlipidemia, and diabetes should be managed medically and through lifestyle modifications to prevent subsequent strokes [119, 126, 127, 143-149]. Smoking is a strong independent risk factor for stroke so patients should be counseled on smoking cessation and provided with appropriate resources [119, 127, 131].

Although there have been recent advances towards creating an organized, cohesive, and multidisciplinary plan of care for patients after discharge from the hospital, further work should be done to determine the barriers to incorporating these recommendations and guidelines into widespread clinical use. Additionally, research should be done to determine how post-stroke follow-up should be modified for patients receiving innovative treatments such as MT.

## Conclusions

In conclusion, there have been significant advances and achievements in treating stroke using MT. We look forward to further research investigating the use of stent retriever, aspiration, and occlusive balloon devices alone and in combination in different clinical scenarios. We make recommendations for post-thrombectomy discharge care and also look forward to further research in this area. Particularly, systematic reviews and meta-analyses examining the efficacy of available devices will be beneficial. Further research examining the detection of thrombus composition using non-invasive imaging, evaluation of the impact of structured post-stroke objectives on outcomes, optimization of patient transfer networks, development of new MT devices, and use of neuroprotective drugs may help improve outcomes for patients with ischemic stroke.

## Abbreviations

BA: blooming artifact

BGC: balloon guide catheter

ERIC: Embolus Retriever with Interlinked Cages

FDA: Food and Drug Administration

HMCAS: hyperdense middle cerebral artery sign

mRS: modified Rankin scale

MT: mechanical thrombectomy

NIHSS: National Institutes of Health Stroke Scale

PC: posterior circulation

RBCs: red blood cells

TICI: thrombolysis in cerebral infarction

tPA: tissue plasminogen activator

## Declarations

### Author contributions

BO wrote the original draft of the introduction. CPV wrote the original draft of the section on stent retrievers. ME wrote the original draft of the section on aspiration devices. ME wrote the original draft of the clinical considerations section. RH wrote the original draft of the section on short-term outcomes. AF wrote the original first draft of the section on long-term outcomes. As such, these individuals were responsible for data curation. KP and BLW contributed to the conceptualization and design of the study, provided guided supervision, and reviewed and edited the manuscript. All authors approved the submitted version.

### Conflicts of interest

The authors declare that they have no conflicts of interest.

### Ethical approval

Not applicable.

### Consent to participate

Not applicable.

### Consent to publication

Not applicable.

### Availability of data and materials

Not applicable.

### Funding

Not applicable.

### Copyright

© The Author(s) 2022.

## References

1. Stroke facts [Internet]. Atlanta: Centers for Disease Control and Prevention; [cited 2022 Jul 20]. Available from: <https://www.cdc.gov/stroke/facts.htm>
2. Cerebrovascular disease or stroke [Internet]. Atlanta: Centers for Disease Control and Prevention; [cited 2022 Jul 20]. Available from: <https://www.cdc.gov/nchs/fastats/stroke.htm>



3. Virani SS, Alonso A, Benjamin EJ, Bittencourt MS, Callaway CW, Carson AP, et al.; American Heart Association Council on Epidemiology and Prevention Statistics Committee and Stroke Statistics Subcommittee. Heart disease and stroke statistics-2020 update: a report from the American Heart Association. *Circulation*. 2020;141:e139–596.
4. Prabhakaran S, Ruff I, Bernstein RA. Acute stroke intervention: a systematic review. *JAMA*. 2015;313:1451–62.
5. Powers WJ, Rabinstein AA, Ackerson T, Adeoye OM, Bambakidis NC, Becker K, et al. Guidelines for the early management of patients with acute ischemic stroke: 2019 update to the 2018 guidelines for the early management of acute ischemic stroke: a guideline for healthcare professionals from the American Heart Association/American Stroke Association. *Stroke*. 2019;50:e344–418. Erratum in: *Stroke*. 2019;50:e440–1.
6. Turc G, Bhogal P, Fischer U, Khatri P, Lobotesis K, Mazighi M, et al. European Stroke Organisation (ESO) - European Society for Minimally Invasive Neurological Therapy (ESMINT) guidelines on mechanical thrombectomy in acute ischaemic stroke endorsed by Stroke Alliance for Europe (SAFE). *Eur Stroke J*. 2019;4:6–12.
7. Nogueira RG, Frei D, Kirmani JF, Zaidat O, Lopes D, Turk AS 3rd, et al.; Penumbra Separator 3D Investigators. Safety and efficacy of a 3-dimensional stent retriever with aspiration-based thrombectomy vs aspiration-based thrombectomy alone in acute ischemic stroke intervention: a randomized clinical trial. *JAMA Neurol*. 2018;75:304–11.
8. Dargazanli C, Fahed R, Blanc R, Gory B, Labreuche J, Duhamel A, et al.; ASTER Trial Investigators. Modified thrombolysis in cerebral infarction 2C/thrombolysis in cerebral infarction 3 reperfusion should be the aim of mechanical thrombectomy: insights from the ASTER trial (contact aspiration *versus* stent retriever for successful revascularization). *Stroke*. 2018;49:1189–96.
9. Flynn D, Francis R, Halvorsrud K, Gonzalo-Almorox E, Craig D, Robalino S, et al. Intra-arterial mechanical thrombectomy stent retrievers and aspiration devices in the treatment of acute ischaemic stroke: a systematic review and meta-analysis with trial sequential analysis. *Eur Stroke J*. 2017;2:308–18.
10. Oliveira-Filho J, Samuels OB. Mechanical thrombectomy for acute ischemic stroke [Internet]. Beijing: UpToDate, Inc. and/or its affiliates; 2022 [cited 2022 Jul 20]. Available from: <https://www.uptodate.com/contents/mechanical-thrombectomy-for-acute-ischemic-stroke>
11. Berkhemer OA, Fransen PS, Beumer D, van den Berg LA, Lingsma HF, Yoo AJ, et al.; MR CLEAN Investigators. A randomized trial of intraarterial treatment for acute ischemic stroke. *N Engl J Med*. 2015;372:11–20. Erratum in: *N Engl J Med*. 2015;372:394.
12. Samaniego EA, Roa JA, Limaye K, Adams HP Jr. Mechanical thrombectomy: emerging technologies and techniques. *J Stroke Cerebrovasc Dis*. 2018;27:2555–71.
13. Raychev R, Saver JL. Mechanical thrombectomy devices for treatment of stroke. *Neurol Clin Pract*. 2012;2:231–5.
14. Koga M, Reutens DC, Wright P, Phan T, Markus R, Pedreira B, et al. The existence and evolution of diffusion-perfusion mismatched tissue in white and gray matter after acute stroke. *Stroke*. 2005;36:2132–7.
15. Leng X, Fang H, Leung TW, Mao C, Miao Z, Liu L, et al. Impact of collaterals on the efficacy and safety of endovascular treatment in acute ischaemic stroke: a systematic review and meta-analysis. *J Neurol Neurosurg Psychiatry*. 2016;87:537–44.
16. Leigh R, Zaidat OO, Suri MF, Lynch G, Sundararajan S, Sunshine JL, et al. Predictors of hyperacute clinical worsening in ischemic stroke patients receiving thrombolytic therapy. *Stroke*. 2004;35:1903–7.
17. Mazighi M, Chaudhry SA, Ribo M, Khatri P, Skoloudik D, Mokin M, et al. Impact of onset-to-reperfusion time on stroke mortality: a collaborative pooled analysis. *Circulation*. 2013;127:1980–5.

18. Henkes H, Flessler A, Brew S, Miloslavski E, Doerfler A, Felber S, et al. A novel microcatheter-delivered, highly-flexible and fully-retrievable stent, specifically designed for intracranial use: technical note. *Interv Neuroradiol.* 2003;9:391–3.
19. Saver JL, Goyal M, Bonafe A, Diener HC, Levy EI, Pereira VM, et al.; SWIFT PRIME Investigators. Stent-retriever thrombectomy after intravenous t-PA vs. t-PA alone in stroke. *N Engl J Med.* 2015;372:2285–95.
20. Pierot L, Soize S, Benaissa A, Wakhloo AK. Techniques for endovascular treatment of acute ischemic stroke: from intra-arterial fibrinolytics to stent-retrievers. *Stroke.* 2015;46:909–14.
21. Becker KJ, Brott TG. Approval of the MERCI clot retriever: a critical view. *Stroke.* 2005;36:400–3.
22. Saver JL, Jahan R, Levy EI, Jovin TG, Baxter B, Nogueira RG, et al.; SWIFT Trialists. Solitaire flow restoration device *versus* the Merci retriever in patients with acute ischaemic stroke (SWIFT): a randomised, parallel-group, non-inferiority trial. *Lancet.* 2012;380:1241–9.
23. Fischer U, Kaesmacher J, Strbian D, Eker O, Cognard C, Plattner PS, et al.; SWIFT DIRECT Collaborators. Thrombectomy alone *versus* intravenous alteplase plus thrombectomy in patients with stroke: an open-label, blinded-outcome, randomised non-inferiority trial. *Lancet.* 2022;400:104–15.
24. Jovin TG, Chamorro A, Cobo E, de Miquel MA, Molina CA, Rovira A, et al.; REVASCAT Trial Investigators. Thrombectomy within 8 hours after symptom onset in ischemic stroke. *N Engl J Med.* 2015;372:2296–306.
25. Campbell BC, Mitchell PJ, Kleinig TJ, Dewey HM, Churilov L, Yassi N, et al.; EXTEND-IA Investigators. Endovascular therapy for ischemic stroke with perfusion-imaging selection. *N Engl J Med.* 2015;372:1009–18.
26. Goyal M, Demchuk AM, Menon BK, Eesa M, Rempel JL, Thornton J, et al.; ESCAPE Trial Investigators. Randomized assessment of rapid endovascular treatment of ischemic stroke. *N Engl J Med.* 2015;372:1019–30.
27. Nogueira RG, Jadhav AP, Haussen DC, Bonafe A, Budzik RF, Bhuva P, et al.; DAWN Trial Investigators. Thrombectomy 6 to 24 hours after stroke with a mismatch between deficit and infarct. *N Engl J Med.* 2018;378:11–21.
28. Nogueira RG, Lutsep HL, Gupta R, Jovin TG, Albers GW, Walker GA, et al.; TREVO 2 Trialists. Trevo *versus* Merci retrievers for thrombectomy revascularisation of large vessel occlusions in acute ischaemic stroke (TREVO 2): a randomised trial. *Lancet.* 2012;380:1231–40. Erratum in: *Lancet.* 2012;380:1230.
29. Smith WS, Sung G, Saver J, Budzik R, Duckwiler G, Liebeskind DS, et al.; Multi MERCI Investigators; Frei D, Grobelny T, Hellinger F, Huddle D, Kidwell C, Koroshetz W, et al. Mechanical thrombectomy for acute ischemic stroke: final results of the Multi MERCI trial. *Stroke.* 2008;39:1205–12.
30. Zaidat OO, Bozorgchami H, Ribó M, Saver JL, Mattle HP, Chapot R, et al. Primary results of the multicenter ARISE II study (analysis of revascularization in ischemic stroke with EmboTrap). *Stroke.* 2018;49:1107–15.
31. Sakai N, Imamura H, Adachi H, Tani S, Tokunaga S, Funatsu T, et al. First-in-man experience of the Versi retriever in acute ischemic stroke. *J Neurointerv Surg.* 2019;11:296–9.
32. Ter Schiphorst A, Peres R, Dargazanli C, Blanc R, Gory B, Richard S, et al.; ETIS Registry Investigators. Endovascular treatment of ischemic stroke due to isolated internal carotid artery occlusion: ETIS registry data analysis. *J Neurol.* 2022;269:4383–95.
33. Kara B, Selcuk HH, Erbahceci Salik A, Zalov H, Yildiz O, Gul G, et al. Single-center experience with the Tigertriever device for the recanalization of large vessel occlusions in acute ischemic stroke. *J Neurointerv Surg.* 2019;11:455–9.
34. Broussalis E, Trinka E, Hitzl W, Wallner A, Chroust V, Killer-Oberpfalzer M. Comparison of stent-retriever devices *versus* the Merci retriever for endovascular treatment of acute stroke. *AJNR Am J Neuroradiol.* 2013;34:366–72.

35. Srivatsan A, Srinivasan VM, Starke RM, Peterson EC, Yavagal DR, Hassan AE, et al. Early postmarket results with EmboTrap II stent retriever for mechanical thrombectomy: a multicenter experience. *AJNR Am J Neuroradiol*. 2021;42:904–9.
36. Kahles T, Garcia-Esperon C, Zeller S, Hlavica M, Añon J, Diepers M, et al. Mechanical thrombectomy using the new ERIC retrieval device is feasible, efficient, and safe in acute ischemic stroke: a Swiss Stroke Center experience. *AJNR Am J Neuroradiol*. 2016;37:114–9.
37. Mendonça N, Flores A, Pagola J, Rubiera M, Rodríguez-Luna D, De Miquel MA, et al. Trevo *versus* solitaire a head-to-head comparison between two heavy weights of clot retrieval. *J Neuroimaging*. 2014;24:167–70.
38. Liang CW, Toor HJ, Duran Martinez E, Sheth SA, Chao K, Feng L, et al. First pass recanalization rates of Solitaire vs Trevo vs primary aspiration: the Kaiser Southern California experience. *Perm J*. 2020;25:1–3.
39. Yi HJ, Lee DH, Kim SU. Effectiveness of Trevo stent retriever in acute ischemic stroke: comparison with Solitaire stent. *Medicine (Baltimore)*. 2018;97:e10747.
40. Baek JW, Heo YJ, Kim ST, Seo JH, Jeong HW, Kim EG. Comparison of the Solitaire and Trevo stents for endovascular treatment of acute ischemic stroke: a single-center experience. *Neurol India*. 2021;69:378–82.
41. Turk AS, Spiotta A, Frei D, Mocco J, Baxter B, Fiorella D, et al. Initial clinical experience with the ADAPT technique: a direct aspiration first pass technique for stroke thrombectomy. *J Neurointerv Surg*. 2014;6:231–7.
42. Li J, Castaño O, Tomasello A, de Dios Lascuevas M, Canals P, Engel E, et al. Catheter tip distensibility substantially influences the aspiration force of thrombectomy devices. *J Neurointerv Surg*. 2022;14:neurintsurg-2021-017487.
43. Li J, Ribo M. REACT aspiration catheters: clinical experience and technical considerations. *Neurointervention*. 2022;17:70–7.
44. Kyselyova AA, Fiehler J, Leischner H, Flottmann F, Buhk JH, Frölich AM. Vessel diameter and catheter-to-vessel ratio affect the success rate of clot aspiration. *J Neurointerv Surg*. 2021;13:605–8.
45. Penumbra Pivotal Stroke Trial Investigators. The penumbra pivotal stroke trial: safety and effectiveness of a new generation of mechanical devices for clot removal in intracranial large vessel occlusive disease. *Stroke*. 2009;40:2761–8.
46. Sila D, Lenski M, Vojtková M, Elgharbawy M, Charvát F, Rath S. Efficacy of mechanical thrombectomy using Penumbra ACE™ aspiration catheter compared to stent retriever Solitaire™ FR in patients with acute ischemic stroke. *Brain Sci*. 2021;11:504.
47. Caranfa JT, Nguyen E, Ali R, Francis I, Zichichi A, Bosco E, et al. Mechanical endovascular therapy for acute ischemic stroke: an indirect treatment comparison between Solitaire and Penumbra thrombectomy devices. *PLoS One*. 2018;13:e0191657.
48. Baik SH, Kwak HS, Hwang SB, Chung GH. Manual aspiration thrombectomy using a Penumbra catheter in patients with acute migrated MCA occlusion. *Interv Neuroradiol*. 2017;23:173–9.
49. Park JS, Kwak HS. Manual aspiration thrombectomy using Penumbra catheter in patients with acute M2 occlusion : a single-center analysis. *J Korean Neurosurg Soc*. 2016;59:352–6.
50. Bose A, Henkes H, Alfke K, Reith W, Mayer TE, Berlis A, et al.; Penumbra Phase 1 Stroke Trial Investigators. The Penumbra system: a mechanical device for the treatment of acute stroke due to thromboembolism. *AJNR Am J Neuroradiol*. 2008;29:1409–13.
51. Raymond SB, Nasir-Moin M, Koch MJ, Rabinov JD, Leslie-Mazwi T, Patel AB. Initial experience with React 68 aspiration catheter. *Interv Neuroradiol*. 2020;26:358–63.
52. Almallouhi E, Anadani M, Al Kasab S, Lena JR, Spiotta AM. Initial experience in direct aspiration thrombectomy using a novel 0.071-inch aspiration catheter. *World Neurosurg*. 2019;126:272–5.
53. Long TD, Kallmes DF, Hanel R, Shigematsu T, Halaszyn AM, Wolter J, et al. Novel aspiration catheter design for acute stroke thrombectomy. *J Neurointerv Surg*. 2019;11:190–5.

54. Bolognini F, Lebedinsky PA, Musacchio M, Delaitre M, Traoré AM, Vuillemet F, et al. SOFIA catheter for direct aspiration of large vessel occlusion stroke: a single-center cohort and meta-analysis. *Interv Neuroradiol*. 2021;27:850–7.
55. Gross BA, Hudson JS, Tonetti DA, Desai SM, Lang MJ, Jadhav AP, et al. Bigger is still better: a step forward in reperfusion with React 71. *Neurosurgery*. 2021;88:758–62.
56. Requena M, Piñana C, Olive-Gadea M, Hernández D, Boned S, De Dios M, et al. Combined technique as first approach in mechanical thrombectomy: efficacy and safety of REACT catheter combined with stent retriever. *Interv Neuroradiol*. 2022;[Epub ahead of print].
57. Penumbra system® [Internet]. Penumbra, Inc.; c2022 [cited 2022 Sep 25]. Available from: <https://www.penumbrainc.com/neuro-device/penumbra-system/>
58. REACT™ [Internet]. Minneapolis: Medtronic; c2022 [cited 2022 Sep 25]. Available from: <https://www.medtronic.com/us-en/healthcare-professionals/products/neurological/revascularization-stroke/react-catheters.html>
59. AXS Vecta [Internet]. Stryker; c1998–2022 [cited 2022 Sep 25]. Available from: <https://www.stryker.com/us/en/neurovascular/products/axs-vecta-intermediate-catheter.html>
60. Super Q™ aspiration system [Internet]. Eden Prairie: MIVI Neuroscience, Inc.; c2022 [cited 2022 Sep 25]. Available from: <https://www.mivineuro.com/q-catheter-eu/>
61. Sofia™ [Internet]. MicroVention Inc.; c2022 [cited 2022 Sep 25]. Available from: <https://www.microvention.com/product/sofia>
62. Mpotsaris A, Bussmeyer M, Weber W. Mechanical thrombectomy with the penumbra 3D separator and lesional aspiration: technical feasibility and clinical outcome. *Clin Neuroradiol*. 2014;24:245–50.
63. Schartz DA, Ellens NR, Kohli GS, Akkipeddi SMK, Colby GP, Bhalla T, et al. A meta-analysis of combined aspiration catheter and stent retriever *versus* stent retriever alone for large-vessel occlusion ischemic stroke. *AJNR Am J Neuroradiol*. 2022;43:568–74.
64. Ospel JM, Volny O, Jayaraman M, McTaggart R, Goyal M. Optimizing fast first pass complete reperfusion in acute ischemic stroke - the BADDASS approach (BALloon guiDe with large bore Distal Access catheter with dual aspiration with Stent-retriever as Standard approach). *Expert Rev Med Devices*. 2019;16:955–63.
65. Massari F, Henninger N, Lozano JD, Patel A, Kuhn AL, Howk M, et al. ARTS (Aspiration-Retriever Technique for Stroke): initial clinical experience. *Interv Neuroradiol*. 2016;22:325–32.
66. Goto S, Ohshima T, Ishikawa K, Yamamoto T, Shimato S, Nishizawa T, et al. A stent-retrieving into an aspiration catheter with proximal balloon (ASAP) technique: a technique of mechanical thrombectomy. *World Neurosurg*. 2018;109:e468–75.
67. Brehm A, Maus V, Tsogkas I, Colla R, Hesse AC, Gera RG, et al. Stent-retriever assisted vacuum-locked extraction (SAVE) *versus* a direct aspiration first pass technique (ADAPT) for acute stroke: data from the real-world. *BMC Neurol*. 2019;19:65.
68. Maegerlein C, Berndt MT, Mönch S, Kreiser K, Boeckh-Behrens T, Lehm M, et al. Further development of combined techniques using stent retrievers, aspiration catheters and BGC: the PROTECT<sup>PLUS</sup> technique. *Clin Neuroradiol*. 2020;30:59–65.
69. Yeo LLL, Jing M, Bhogal P, Tu T, Gopinathan A, Yang C, et al. Evidence-based updates to thrombectomy: targets, new techniques, and devices. *Front Neurol*. 2021;12:712527.
70. Nouh A, Remke J, Ruland S. Ischemic posterior circulation stroke: a review of anatomy, clinical presentations, diagnosis, and current management. *Front Neurol*. 2014;5:30.
71. Gulli G, Marquardt L, Rothwell PM, Markus HS. Stroke risk after posterior circulation stroke/transient ischemic attack and its relationship to site of vertebrobasilar stenosis: pooled data analysis from prospective studies. *Stroke*. 2013;44:598–604.
72. van Raamt AF, Mali WP, van Laar PJ, van der Graaf Y. The fetal variant of the circle of Willis and its influence on the cerebral collateral circulation. *Cerebrovasc Dis*. 2006;22:217–24.

73. de Monyé C, Dippel DW, Siepmann TA, Dijkshoorn ML, Tanghe HL, van der Lugt A. Is a fetal origin of the posterior cerebral artery a risk factor for TIA or ischemic stroke? A study with 16-multidetector-row CT angiography. *J Neurol*. 2008;255:239–45.
74. Perren F, Poglia D, Landis T, Sztajzel R. Vertebral artery hypoplasia: a predisposing factor for posterior circulation stroke? *Neurology*. 2007;68:65–7.
75. Grunwald IQ, Walter S, Papanagiotou P, Krick C, Hartmann K, Dautermann A, et al. Revascularization in acute ischaemic stroke using the penumbra system: the first single center experience. *Eur J Neurol*. 2009;16:1210–6.
76. Papanagiotou P, Ntaios G. Endovascular thrombectomy in acute ischemic stroke. *Circ Cardiovasc Interv*. 2018;11:e005362.
77. Jindal G, Serulle Y, Miller T, Le E, Wozniak M, Phipps M, et al. Stent retrieval thrombectomy in acute stroke is facilitated by the concurrent use of intracranial aspiration catheters. *J Neurointerv Surg*. 2017;9:944–7.
78. Nogueira RG, Liebeskind DS, Sung G, Duckwiler G, Smith WS; MERCI, Multi MERCI Writing Committee. Predictors of good clinical outcomes, mortality, and successful revascularization in patients with acute ischemic stroke undergoing thrombectomy: pooled analysis of the Mechanical Embolus Removal in Cerebral Ischemia (MERCI) and Multi MERCI trials. *Stroke*. 2009;40:3777–83.
79. Kumar G, Shahripour RB, Alexandrov AV. Recanalization of acute basilar artery occlusion improves outcomes: a meta-analysis. *J Neurointerv Surg*. 2015;7:868–74.
80. Singer OC, Berkefeld J, Nolte CH, Bohner G, Haring HP, Trenkler J, et al.; ENDOSTROKE Study Group. Mechanical recanalization in basilar artery occlusion: the ENDOSTROKE study. *Ann Neurol*. 2015;77:415–24.
81. Staessens S, Denorme F, Francois O, Desender L, Dewaele T, Vanacker P, et al. Structural analysis of ischemic stroke thrombi: histological indications for therapy resistance. *Haematologica*. 2020;105:498–507.
82. Kaesmacher J, Maegerlein C, Kaesmacher M, Zimmer C, Poppert H, Friedrich B, et al. Thrombus migration in the middle cerebral artery: incidence, imaging signs, and impact on success of endovascular thrombectomy. *J Am Heart Assoc*. 2017;6:e005149.
83. Yuki I, Kan I, Vinters HV, Kim RH, Golshan A, Vinuela FA, et al. The impact of thromboemboli histology on the performance of a mechanical thrombectomy device. *AJNR Am J Neuroradiol*. 2012;33:643–8.
84. Liebeskind DS, Sanossian N, Yong WH, Starkman S, Tsang MP, Moya AL, et al. CT and MRI early vessel signs reflect clot composition in acute stroke. *Stroke*. 2011;42:1237–43.
85. Froehler MT, Tateshima S, Duckwiler G, Jahan R, Gonzalez N, Vinuela F, et al.; UCLA Stroke Investigators. The hyperdense vessel sign on CT predicts successful recanalization with the Merci device in acute ischemic stroke. *J Neurointerv Surg*. 2013;5:289–93.
86. Brinjikji W, Duffy S, Burrows A, Hacke W, Liebeskind D, Majoie CBLM, et al. Correlation of imaging and histopathology of thrombi in acute ischemic stroke with etiology and outcome: a systematic review. *J Neurointerv Surg*. 2017;9:529–34.
87. Wei M, Wei Z, Li X, Li H. Retrograde semi-retrieval technique for combined stentriever plus aspiration thrombectomy in acute ischemic stroke. *Interv Neuroradiol*. 2017;23:285–8.
88. Nguyen TN, Malisch T, Castonguay AC, Gupta R, Sun CH, Martin CO, et al. Balloon guide catheter improves revascularization and clinical outcomes with the Solitaire device: analysis of the North American Solitaire Acute Stroke Registry. *Stroke*. 2014;45:141–5.
89. Skyrman S, Burström G, Aspegren O, Babic D, Lucassen G, Edström E, et al. Clot composition characterization using diffuse reflectance spectroscopy in acute ischemic stroke. *Biomed Opt Express*. 2022;13:3311–23.
90. Ding Y, Abbasi M, Eltanahy AM, Jakaitis DR, Dai D, Kadirvel R, et al. Assessment of blood clot composition by spectral optical coherence tomography: an *in vitro* study. *Neurointervention*. 2021;16:29–33.

91. Ding YH, Abbasi M, Michalak G, Leng S, Dai D, Fitzgerald S, et al. Characterization of thrombus composition with multimodality CT-based imaging: an *in-vitro* study. *J Neurointerv Surg.* 2021;13:738–40.
92. Hanning U, Sporns PB, Psychogios MN, Jeibmann A, Minnerup J, Gelderblom M, et al. Imaging-based prediction of histological clot composition from admission CT imaging. *J Neurointerv Surg.* 2021;13:1053–7.
93. Jiang J, Wei J, Zhu Y, Wei L, Wei X, Tian H, et al. Clot-based radiomics model for cardioembolic stroke prediction with CT imaging before recanalization: a multicenter study. *Eur Radiol.* 2022;[Epub ahead of print].
94. Banks JL, Marotta CA. Outcomes validity and reliability of the modified Rankin scale: implications for stroke clinical trials: a literature review and synthesis. *Stroke.* 2007;38:1091–6.
95. Lyden PD, Lu M, Levine SR, Brott TG, Broderick J; NINDS rtPA Stroke Study Group. A modified National Institutes of Health Stroke Scale for use in stroke clinical trials: preliminary reliability and validity. *Stroke.* 2001;32:1310–7.
96. Zhang X, Xie Y, Wang H, Yang D, Jiang T, Yuan K, et al. Symptomatic intracranial hemorrhage after mechanical thrombectomy in Chinese ischemic stroke patients: the ASIAN score. *Stroke.* 2020;51:2690–6.
97. Hao Y, Yang D, Wang H, Zi W, Zhang M, Geng Y, et al.; ACTUAL Investigators (Endovascular Treatment for Acute Anterior Circulation Ischemic Stroke Registry). Predictors for symptomatic intracranial hemorrhage after endovascular treatment of acute ischemic stroke. *Stroke.* 2017;48:1203–9.
98. Tonetti DA, Desai SM, Casillo S, Stone J, Brown M, Jankowitz B, et al. Successful reperfusion, rather than number of passes, predicts clinical outcome after mechanical thrombectomy. *J Neurointerv Surg.* 2020;12:548–51.
99. Wollenweber FA, Tiedt S, Alegiani A, Alber B, Bangard C, Berrouschot J, et al. Functional outcome following stroke thrombectomy in clinical practice. *Stroke.* 2019;50:2500–6.
100. Boltyenkov AT, Wang JJ, Malhotra A, Katz JM, Martinez G, Sanelli PC. Early thrombectomy outcomes in transfer patients. *Air Med J.* 2021;40:102–7.
101. Wirtz MM, Hendrix P, Goren O, Beckett LA, Dicristina HR, Schirmer CM, et al. Predictor of 90-day functional outcome after mechanical thrombectomy for large vessel occlusion stroke: NIHSS score of 10 or less at 24 hours. *J Neurosurg.* 2021;134:115–21.
102. Kurmann CC, Beyeler M, Grunder L, Lang MF, Piechowiak EI, Meinel TR, et al. Association of the 24-hour National Institutes of Health Stroke Scale after mechanical thrombectomy with early and long-term survival. *Stroke Vasc Interv Neurol.* 2022;2:e000244.
103. Zaidat OO, Yoo AJ, Khatri P, Tomsick TA, von Kummer R, Saver JL, et al.; Cerebral Angiographic Revascularization Grading (CARG) Collaborators, STIR Revascularization working group, STIR Thrombolysis in Cerebral Infarction (TICI) Task Force. Recommendations on angiographic revascularization grading standards for acute ischemic stroke: a consensus statement. *Stroke.* 2013;44:2650–63.
104. Fugate JE, Klunder AM, Kallmes DF. What is meant by “TICI”? *AJNR Am J Neuroradiol.* 2013;34:1792–7.
105. Pilgram-Pastor SM, Piechowiak EI, Dobrocky T, Kaesmacher J, Den Hollander J, Gralla J, et al. Stroke thrombectomy complication management. *J Neurointerv Surg.* 2021;13:912–7.
106. Nakamura C, Serondo D. Caring for the post procedure mechanical thrombectomy patient [Internet]. Chicago: Neurocritical Care Society; [cited 2022 Sep 25]. Available from: <https://currents.neurocriticalcare.org/blogs/currents-editor/2019/02/08/caring-for-the-post-procedure-mechanical-thrombect>
107. Jadhav AP, Molyneaux BJ, Hill MD, Jovin TG. Care of the post-thrombectomy patient. *Stroke.* 2018;49:2801–7.
108. Dinsmore JE, Tan A. Anaesthesia for mechanical thrombectomy: a narrative review. *Anaesthesia.* 2022;77:59–68.

109. Adeoye O, Nyström KV, Yavagal DR, Luciano J, Nogueira RG, Zorowitz RD, et al. Recommendations for the establishment of stroke systems of care: a 2019 update. *Stroke*. 2019;50:e187–210. Erratum in: *Stroke*. 2020;51:e70.
110. Burris JE. Stroke rehabilitation: current American Stroke Association guidelines, care, and implications for practice. *Mo Med*. 2017;114:40–3.
111. Mees M, Klein J, Yperzeele L, Vanacker P, Cras P. Predicting discharge destination after stroke: a systematic review. *Clin Neurol Neurosurg*. 2016;142:15–21.
112. Boehme C, Toell T, Lang W, Knoflach M, Kiechl S. Longer term patient management following stroke: a systematic review. *Int J Stroke*. 2021;16:917–26.
113. Broderick JP, Abir M. Transitions of care for stroke patients: opportunities to improve outcomes. *Circ Cardiovasc Qual Outcomes*. 2015;8:S190–2.
114. Coleman EA. Falling through the cracks: challenges and opportunities for improving transitional care for persons with continuous complex care needs. *J Am Geriatr Soc*. 2003;51:549–55.
115. Coleman EA, Berenson RA. Lost in transition: challenges and opportunities for improving the quality of transitional care. *Ann Intern Med*. 2004;141:533–6.
116. Murray J, Ashworth R, Forster A, Young J. Developing a primary care-based stroke service: a review of the qualitative literature. *Br J Gen Pract*. 2003;53:137–42.
117. Philp I, Brainin M, Walker MF, Ward AB, Gillard P, Shields AL, et al.; Global Stroke Community Advisory Panel. Development of a poststroke checklist to standardize follow-up care for stroke survivors. *J Stroke Cerebrovasc Dis*. 2013;22:e173–80.
118. Adams HP Jr, del Zoppo G, Alberts MJ, Bhatt DL, Brass L, Furlan A, et al.; American Heart Association, American Stroke Association Stroke Council, Clinical Cardiology Council, Cardiovascular Radiology and Intervention Council, Atherosclerotic Peripheral Vascular Disease and Quality of Care Outcomes in Research Interdisciplinary Working Groups. Guidelines for the early management of adults with ischemic stroke: a guideline from the American Heart Association/American Stroke Association Stroke Council, Clinical Cardiology Council, Cardiovascular Radiology and Intervention Council, and the Atherosclerotic Peripheral Vascular Disease and Quality of Care Outcomes in Research Interdisciplinary Working Groups: the American Academy of Neurology affirms the value of this guideline as an educational tool for neurologists. *Stroke*. 2007;38:1655–711. Erratum in: *Stroke*. 2007;38:e38. Erratum in: *Stroke*. 2007;38:e96.
119. Furie KL, Kasner SE, Adams RJ, Albers GW, Bush RL, Fagan SC, et al.; American Heart Association Stroke Council, Council on Cardiovascular Nursing, Council on Clinical Cardiology, Interdisciplinary Council on Quality of Care and Outcomes Research. Guidelines for the prevention of stroke in patients with stroke or transient ischemic attack: a guideline for healthcare professionals from the American Heart Association/American Stroke Association. *Stroke*. 2011;42:227–76.
120. Winstein CJ, Stein J, Arena R, Bates B, Cherney LR, Cramer SC, et al.; American Heart Association Stroke Council, Council on Cardiovascular and Stroke Nursing, Council on Clinical Cardiology, Council on Quality of Care and Outcomes Research. Guidelines for adult stroke rehabilitation and recovery: a guideline for healthcare professionals from the American Heart Association/American Stroke Association. *Stroke*. 2016;47:e98–169. Erratum in: *Stroke*. 2017;48:e78. Erratum in: *Stroke*. 2017;48:e369.
121. Allen A, Barron T, Mo A, Tangel R, Linde R, Grim R, et al. Impact of neurological follow-up on early hospital readmission rates for acute ischemic stroke. *Neurohospitalist*. 2017;7:127–31.
122. Duncan PW, Abbott RM, Rushing S, Johnson AM, Condon CN, Lycan SL, et al.; COMPASS Investigative Team. COMPASS-CP: an electronic application to capture patient-reported outcomes to develop actionable stroke and transient ischemic attack care plans. *Circ Cardiovasc Qual Outcomes*. 2018;11:e004444.
123. Duncan PW, Bushnell C, Sissine M, Coleman S, Lutz BJ, Johnson AM, et al. Comprehensive stroke care and outcomes: time for a paradigm shift. *Stroke*. 2021;52:385–93.

124. Duncan PW, Bushnell CD, Jones SB, Psioda MA, Gesell SB, D'Agostino RB Jr, et al.; COMPASS Site Investigators and Teams. Randomized pragmatic trial of stroke transitional care: the COMPASS study. *Circ Cardiovasc Qual Outcomes*. 2020;13:e006285.
125. Duncan PW, Bushnell CD, Rosamond WD, Jones Berkeley SB, Gesell SB, D'Agostino RB Jr, et al. The Comprehensive Post-Acute Stroke Services (COMPASS) study: design and methods for a cluster-randomized pragmatic trial. *BMC Neurol*. 2017;17:133.
126. Kernan WN, Viera AJ, Billinger SA, Bravata DM, Stark SL, Kasner SE, et al.; American Heart Association Stroke Council, Council on Arteriosclerosis, Thrombosis and Vascular Biology, Council on Cardiovascular Radiology and Intervention, Council on Peripheral Vascular Disease. Primary care of adult patients after stroke: a scientific statement from the American Heart Association/American Stroke Association. *Stroke*. 2021;52:e558–71.
127. Kleindorfer DO, Towfighi A, Chaturvedi S, Cockcroft KM, Gutierrez J, Lombardi-Hill D, et al. 2021 guideline for the prevention of stroke in patients with stroke and transient ischemic attack: a guideline from the American Heart Association/American Stroke Association. *Stroke*. 2021;52:e364–467. Erratum in: *Stroke*. 2021;52:e483–4.
128. Leppert MH, Sillau S, Lindrooth RC, Poisson SN, Campbell JD, Simpson JR. Relationship between early follow-up and readmission within 30 and 90 days after ischemic stroke. *Neurology*. 2020;94:e1249–58.
129. Leppin AL, Gionfriddo MR, Kessler M, Brito JP, Mair FS, Gallacher K, et al. Preventing 30-day hospital readmissions: a systematic review and meta-analysis of randomized trials. *JAMA Intern Med*. 2014;174:1095–107.
130. Lichtman JH, Leifheit-Limson EC, Jones SB, Wang Y, Goldstein LB. Preventable readmissions within 30 days of ischemic stroke among Medicare beneficiaries. *Stroke*. 2013;44:3429–35.
131. Lindsay P, Furie KL, Davis SM, Donnan GA, Norrving B. World Stroke Organization global stroke services guidelines and action plan. *Int J Stroke*. 2014;9:4–13.
132. Mittal MK, Rabinstein AA, Mandrekar J, Brown RD Jr, Flemming KD. A population-based study for 30-d hospital readmissions after acute ischemic stroke. *Int J Neurosci*. 2017;127:305–13.
133. Terman SW, Reeves MJ, Skolarus LE, Burke JF. Association between early outpatient visits and readmissions after ischemic stroke. *Circ Cardiovasc Qual Outcomes*. 2018;11:e004024. Erratum in: *Circ Cardiovasc Qual Outcomes*. 2018;11:e000042.
134. Turner GM, Mullis R, Lim L, Kreit L, Mant J. Using a checklist to facilitate management of long-term care needs after stroke: insights from focus groups and a feasibility study. *BMC Fam Pract*. 2019;20:2.
135. Ward AB, Chen C, Norrving B, Gillard P, Walker MF, Blackburn S, et al.; Global Stroke Community Advisory Panel (GSCAP). Evaluation of the post stroke checklist: a pilot study in the United Kingdom and Singapore. *Int J Stroke*. 2014;9:76–84.
136. Dobkin BH. Strategies for stroke rehabilitation. *Lancet Neurol*. 2004;3:528–36.
137. Cichon N, Wlodarczyk L, Saluk-Bijak J, Bijak M, Redlicka J, Gorniak L, et al. Novel advances to post-stroke aphasia pharmacology and rehabilitation. *J Clin Med*. 2021;10:3778.
138. Cifu DX, Stewart DG. Factors affecting functional outcome after stroke: a critical review of rehabilitation interventions. *Arch Phys Med Rehabil*. 1999;80:S35–9.
139. Ottenbacher KJ, Jannell S. The results of clinical trials in stroke rehabilitation research. *Arch Neurol*. 1993;50:37–44.
140. Paolucci S, Antonucci G, Grasso MG, Morelli D, Troisi E, Coiro P, et al. Early *versus* delayed inpatient stroke rehabilitation: a matched comparison conducted in Italy. *Arch Phys Med Rehabil*. 2000;81:695–700.
141. REhabilitation and recovery of peopLE with Aphasia after StrokeE (RELEASE) Collaborators. Predictors of poststroke aphasia recovery: a systematic review-informed individual participant data meta-analysis. *Stroke*. 2021;52:1778–87.
142. Robey RR. A meta-analysis of clinical outcomes in the treatment of aphasia. *J Speech Lang Hear Res*. 1998;41:172–87.



143. Rothwell PM, Algra A, Amarenco P. Medical treatment in acute and long-term secondary prevention after transient ischaemic attack and ischaemic stroke. *Lancet*. 2011;377:1681–92.
144. Heuschmann PU, Kircher J, Nowe T, Dittrich R, Reiner Z, Cifkova R, et al. Control of main risk factors after ischaemic stroke across Europe: data from the stroke-specific module of the EUROASPIRE III survey. *Eur J Prev Cardiol*. 2015;22:1354–62.
145. Kim J, Lee HS, Nam CM, Heo JH. Effects of statin intensity and adherence on the long-term prognosis after acute ischemic stroke. *Stroke*. 2017;48:2723–30.
146. McAlister FA, Majumdar SR, Padwal RS, Fradette M, Thompson A, Buck B, et al. Case management for blood pressure and lipid level control after minor stroke: PREVENTION randomized controlled trial. *CMAJ*. 2014;186:577–84. Erratum in: *CMAJ*. 2014;186:698.
147. Razmara A, Ovbiagele B, Markovic D, Towfighi A. Patterns and predictors of blood pressure treatment, control, and outcomes among stroke survivors in the United States. *J Stroke Cerebrovasc Dis*. 2016;25:857–65.
148. Turan TN, Nizam A, Lynn MJ, Egan BM, Le NA, Lopes-Virella MF, et al. Relationship between risk factor control and vascular events in the SAMMPRIS trial. *Neurology*. 2017;88:379–85.
149. White CL, Pergola PE, Szychowski JM, Talbert R, Cervantes-Arriaga A, Clark HD, et al.; SPS3 Investigators. Blood pressure after recent stroke: baseline findings from the secondary prevention of small subcortical strokes trial. *Am J Hypertens*. 2013;26:1114–22.