

Upper limb cortical maps in amputees with targeted muscle and sensory reinnervation

Andrea Serino,^{1,2,3,*} Michel Akselrod,^{1,2,3,*} Roy Salomon,^{1,2,4} Roberto Martuzzi,^{1,2,5} Maria Laura Blefari,^{1,2} Elisa Canzoneri,^{1,2} Giulio Rognini,^{1,2} Wietske van der Zwaag,^{6,7} Maria Iakova,⁸ François Luthi,⁸ Amedeo Amoresano,⁹ Todd Kuiken¹⁰ and Olaf Blanke^{1,2,11}

*These authors contributed equally to this work.

Neuroprosthetics research in amputee patients aims at developing new prostheses that move and feel like real limbs. Targeted muscle and sensory reinnervation (TMSR) is such an approach and consists of rerouting motor and sensory nerves from the residual limb towards intact muscles and skin regions. Movement of the myoelectric prosthesis is enabled via decoded electromyography activity from reinnervated muscles and touch sensation on the missing limb is enabled by stimulation of the reinnervated skin areas. Here we ask whether and how motor control and redirected somatosensory stimulation provided via TMSR affected the maps of the upper limb in primary motor (M1) and primary somatosensory (S1) cortex, as well as their functional connections. To this aim, we tested three TMSR patients and investigated the extent, strength, and topographical organization of the missing limb and several control body regions in M1 and S1 at ultra high-field (7 T) functional magnetic resonance imaging. Additionally, we analysed the functional connectivity between M1 and S1 and of both these regions with fronto-parietal regions, known to be important for multisensory upper limb processing. These data were compared with those of control amputee patients ($n = 6$) and healthy controls ($n = 12$). We found that M1 maps of the amputated limb in TMSR patients were similar in terms of extent, strength, and topography to healthy controls and different from non-TMSR patients. S1 maps of TMSR patients were also more similar to normal conditions in terms of topographical organization and extent, as compared to non-targeted muscle and sensory reinnervation patients, but weaker in activation strength compared to healthy controls. Functional connectivity in TMSR patients between upper limb maps in M1 and S1 was comparable with healthy controls, while being reduced in non-TMSR patients. However, connectivity was reduced between S1 and fronto-parietal regions, in both the TMSR and non-TMSR patients with respect to healthy controls. This was associated with the absence of a well-established multisensory effect (visual enhancement of touch) in TMSR patients. Collectively, these results show how M1 and S1 process signals related to movement and touch are enabled by targeted muscle and sensory reinnervation. Moreover, they suggest that TMSR may counteract maladaptive cortical plasticity typically found after limb loss, in M1, partially in S1, and in their mutual connectivity. The lack of multisensory interaction in the present data suggests that further engineering advances are necessary (e.g. the integration of somatosensory feedback into current prostheses) to enable prostheses that move and feel as real limbs.

- 1 Center for Neuroprosthetics, Swiss Federal Institute of Technology of Lausanne (EPFL), chemin des mines 9, 1202 Geneva, Switzerland
- 2 Laboratory of Cognitive Neuroscience, Faculty of Life Science, Swiss Federal Institute of Technology of Lausanne (EPFL), chemin des mines 9, 1202 Geneva, Switzerland
- 3 Department of Clinical Neurosciences, University Hospital Lausanne (CHUV), Switzerland
- 4 The Gonda Multidisciplinary Brain Research Center, Bar-Ilan University, Ramat Gan, Israel
- 5 Campus Biotech Geneva, Geneva, Switzerland
- 6 Biomedical Imaging Research Center, Swiss Federal Institute of Technology of Lausanne (EPFL), Lausanne, Switzerland
- 7 Spinoza Centre for Neuroimaging, Amsterdam, The Netherlands
- 8 Département de l'appareil locomoteur, Clinique Romande de Réadaptation SUVA Care, Sion, Switzerland

Received June 3, 2016. Revised July 13, 2017. Accepted August 3, 2017

© The Author (2017). Published by Oxford University Press on behalf of the Guarantors of Brain. All rights reserved.

For Permissions, please email: journals.permissions@oup.com

9 Centro Protesi INAIL, Vigorso di Budrio, Bologna, Italy

10 Center for Bionic Medicine, Rehabilitation Institute of Chicago, Chicago, IL, USA

11 Department of Neurology, University Hospital, Geneva, Switzerland

Correspondence to: Andrea Serino,
Campus Biotech, Chemin des Mines 9, 1202 Geneva, Switzerland
E-mail: andrea.serino@epfl.ch

Correspondence may also be addressed to: Olaf Blanke. E-mail: olaf.blanke@epfl.ch

Keywords: TMSR; primary motor and somatosensory representations; 7 T functional MRI

Abbreviations: M1 = primary motor cortex; TMSR = targeted muscle and sensory reinnervation; S1 = primary somatosensory cortex; SMN = sensorimotor network; VET = visual enhancement of touch

Introduction

The loss of an upper limb results in functional reorganization of primate primary motor (M1) and somatosensory (S1) areas as originally demonstrated in non-human primates (Kaas *et al.*, 1983; Merzenich *et al.*, 1983; Kaas, 1991; Pons, 1991). In humans, such reorganization after limb amputation has also been observed and considered a form of maladaptive plasticity, linked to the phantom limb syndrome and associated chronic pain (Flor *et al.*, 1995; Lotze *et al.*, 2001; Foell *et al.*, 2014; but see Makin *et al.*, 2013*b*). Subsequently, it has been proposed that motor activity and usage of the missing limb, as well as related sensory feedback, may in principle counteract maladaptive reorganization of sensory-motor cortices in amputees, thus inspiring several rehabilitation techniques, based on motor imagery and mirror box therapy (Chan *et al.*, 2007; Rothgangel *et al.*, 2011). These approaches, however, require long sessions of training and are unrelated to true ecological limb usage. Thus, optimal sensory-motor training should consist of naturalistic control of a prosthetic limb.

The field of neuroprosthetics pursues various approaches for the development of bidirectional interfaces allowing amputees to feel and control a prosthetic limb in the most intuitive and natural fashion. A key example of these techniques is the so-called targeted muscle and sensory reinnervation (TMSR) (Kuiken, *et al.*, 2004, 2007*b*). It consists of de-innervating spare muscle groups in the residual limb or the chest of the amputee (i.e. target muscles) and reinnervating them with the residual arm nerves of the amputated limb. In this way, motor commands generated to control the arm or hand are decoded from electromyographical signals of the target muscles and used to control a prosthetic limb (Kuiken, *et al.*, 2004, 2007*b*). In some patients the approach may also include targeted sensory reinnervation, for which de-innervated skin regions near or over the target muscle are reinnervated with afferent fibres of the residual somatosensory nerves of the amputated limb (Kuiken *et al.*, 2007*a*; Hebert *et al.*, 2014). As a consequence, stimuli applied to the reinnervated skin regions evoke somatosensory sensations as if the missing limb were stimulated. Thus, amputees may

use such TMSR systems to control their prosthetic limb by recruiting central motor representations of the missing limb and may perceive sensory feedback as arising from the missing limb, likely activating central somatosensory representations. However, while there exists evidence of motor and sensory cortical plasticity in patients who underwent the TMSR procedure (Chen *et al.*, 2013; Yao *et al.*, 2015), it is not clearly demonstrated to what extent TMSR-based prostheses recruit and reinstate cortical representations of the missing limb. A way to answer this question would be testing whether and how the TMSR procedure affects cortical body representations in primary motor and somatosensory cortices, potentially impacting current trends to improve motor control and tactile perception as well as phantom limb pain due to maladaptive plasticity (Flor *et al.*, 1995; Lotze *et al.*, 2001).

In the present study, we first investigated whether movement and somatosensory feedback linked to TMSR prosthesis is associated with more normal somatotopic maps in M1 and S1 in TMSR patients, predicting that, compared to amputee patients without TMSR (non-TMSR), M1 and S1 organization would be more similar to the normal organization in healthy participants. To this aim, we used ultra high-field functional MRI (7 T) paradigms to map upper limb representations (and neighbouring regions) in M1 and S1 in TMSR patients as described previously in healthy subjects (Martuzzi *et al.*, 2014, 2015; Siero *et al.*, 2014; Ejaz *et al.*, 2015; Akselrod *et al.*, 2017). In particular, we examined M1 activity induced by movements of different parts of the upper limb (Porro *et al.*, 1996; Lotze *et al.*, 2000; Alkadhi *et al.*, 2002; Zeharia *et al.*, 2012). Moreover, by applying touch cues to reinnervated skin regions resulting in clear tactile percepts on the missing limb, we also mapped the somatosensory representation of the upper limb in S1, at the level of single fingers (Sanchez-Panchuelo *et al.*, 2010; Stringer *et al.*, 2011; Martuzzi *et al.*, 2014, 2015; Akselrod *et al.*, 2017). Specifically, we studied the extent, strength, location, and topographical sequence of upper limb representations in M1 and S1 using 7 T functional MRI in TMSR patients.

In addition, it is well known that perception of body parts does not rely only on unimodal representations in M1 and

S1, but also on multimodal body representations, especially in multisensory-motor frontoparietal areas, as well as on distributed processing between unimodal and multimodal brain regions (Serino and Haggard, 2010; Blanke *et al.*, 2015). In fact, key rehabilitative approaches for phantom limb syndrome, such as the mirror box treatment, are based on integration of multimodal visual, somatosensory, and motor cues (Chan *et al.*, 2007; Ramachandran and Altschuler, 2009). Therefore, we also applied resting state functional connectivity analysis (Fox and Raichle, 2007) to study the functional organization between maps of the different body parts (including the amputated limb) in M1 and S1, and to investigate how these representations are integrated into sensory-motor networks processing bodily information (Graziano and Cooke, 2006; Dijkerman and de Haan, 2007; Berlucchi and Aglioti, 2010). This analysis was complemented by a psychophysical investigation of the visual enhancement of touch (VET) effect in TMSR patients, testing how vision of the missing limb affects somatosensory perception of the targeted skin region. The presence of VET in TMSR patients would demonstrate existing interactions between visual and somatosensory representations of the missing limb, pointing to normal multisensory representations. Three patients, who received TMSR to control a prosthetic arm, were studied and their functional MRI and behavioural results were compared with those from six non-TMSR control amputees, suffering from comparable upper limb amputation (without any TMSR), and with 12 healthy control subjects.

Materials and methods

Participants

Three TMSR patients, who have been extensively tested previously (Kuiken *et al.*, 2004, 2007b; Marasco *et al.*, 2009), were enrolled in the present study. Patient TMSR-01 was a 45-year-old female, who suffered left trans-humeral amputation due to a car accident. Fifteen months after injury and 7 years before the current investigation, her residual median and distal radial nerves were transferred to the medial biceps and lateral triceps muscles, respectively. Her intercostobrachial nerve was cut to facilitate sensory reinnervation of her arm. Patient TMSR-02 was a 33-year-old female, who suffered left shoulder disarticulation following a motor vehicle collision. Fifteen months after amputation and 8 years before the current investigation, the median, ulnar and radial nerves on the left side were transferred to different segments of her ipsilateral pectoralis major and serratus anterior muscles. In addition, the supraclavicular cutaneous and the intercostobrachial cutaneous nerves were cut and their distal portions were co-apted to the ulnar and median nerves, respectively. Patient TMSR-03 was a 66-year-old male, who lost both his arms at the shoulders due to electrical burns. Nine months after injury and 16 years before the current testing, his remaining left median, ulnar, radial, and musculocutaneous nerves were transferred to different segments of his left pectoralis major and minor muscles. For all patients, more detailed clinical information regarding surgical procedures and outcomes is reported in

previous papers (Kuiken *et al.*, 2004, 2007a, b; Hijawi *et al.*, 2006; O'Shaughnessy *et al.*, 2008; Dumanian *et al.*, 2009).

Six upper limb amputated patients who did not receive TMSR surgery (non-TMSR amputees) and whose site of amputation globally matched the amputation site of the three TMSR patients were recruited [mean age = 45 years, standard deviation (SD) = ± 14.5 years, six males] (see Supplementary material for details). All patients underwent a semi-structured interview, via a revised version of 'The Changes in Body Sensation Following Limb Loss' questionnaire (CUBS-questionnaire) (adapted from Giummarra and Moseley, 2011; see Supplementary material). Additional information extracted from the interview regarding the phenomenology of phantom limbs is presented in Table 1. Time since amputation and intensity of phantom pain did not differ between TMSR and non-TMSR patients (Wilcoxon rank-sum tests: $W = 19.0$, $P = 0.36$ and $W = 13.5$, $P = 0.71$, respectively). A group of 12 healthy controls performed functional MRI scanning (mean age = 29.75 years, SD = ± 12.0 years, three females) and another group of 18 healthy participants took part as a control group in the experiment on VET (mean age = 22 years, SD = ± 2.3 years, five males).

All participants were originally right-handed, as confirmed by the Edinburgh Oldfield Handedness Inventory (Oldfield, 1971). The study was approved by the Ethics Committee of the University of Lausanne (Reference number: 113/2013) and conducted in accordance with the Declaration of Helsinki. All participants provided written informed consent to participate to the study.

Assessment of somatosensory sensation from the missing limb

All amputee patients were interviewed (semi-structured interview; adapted from Giummarra and Moseley, 2011) (Supplementary material) about residual sensations, phantom limb experiences and pain. All TMSR patients reported a clear sensation of the presence of a phantom limb, in a natural and comfortable posture. At the time of testing none of the patients reported phantom pain, except Patient TMSR-03. All TMSR patients claimed to be able to move their phantom limbs. All patients reported well-defined tactile sensation following tactile stimulation of different skin regions from the reinnervated residual limb (Supplementary material).

To quantify these referred sensations to the amputated limb and to precisely localize the regions over the reinnervated skin inducing reliable tactile percepts on different parts of the missing limb, we conducted a detailed psychophysical assessments on the first day of testing, and a second shorter assessment at the beginning of later sessions to confirm the reliability of stimulation (for details about mapping of referred sensations on the reinnervated skin see Supplementary material). Results are reported in Fig. 1, showing that all TMSR participants perceived reliable sensations from the amputated limb, mostly localized on the palm, thumb, index, middle and little fingers. A similar mapping procedure was used with non-TMSR patients to identify possible areas of tactile sensations referred to the amputated limb from stimulation of the skin over the residual limb. These examinations were used to select

Table 1 Patient characteristics

	TMSR-01	TMSR-02	TMSR-03	Non-TMSR-01	Non-TMSR-02	Non-TMSR-03	Non-TMSR-04	Non-TMSR-05	Non-TMSR-06
Time since amputation, years	9	10	17	3	2	2	1	46	15
Use of a prosthesis	7 years	8 years	16 years	Cosmetic (never)	Cosmetic (all day)	Cosmetic (all day)	Cinematic (all day)	Myoelectric (all day)	Myoelectric (all day)
Phantom limb	Yes, sometimes	Yes, sometimes	Yes, often	Yes, always	Yes, often	Yes, always	Yes, always	Yes, always	Yes, always
Itching	Yes	Yes	Yes	Yes	No	No	A little	No	Yes
Perceived size	Yes	Yes	Yes	Yes, telescoping	Yes, telescoping	No	No	Yes, telescoping	Yes, telescoping
Perceived shape	Yes	Yes	Yes	Yes, fingers contracted	Yes	No	Yes, swollen	Yes, telescoping	No
Perceived position	Yes	Yes	Yes	Yes	Yes	Yes	Yes	Yes, fist	No
Something touching	No	No	No	No	Yes	Yes	No	No	No
Pressure	Yes	Yes	No	Yes	Yes	Yes	Yes, sometimes	No	Yes
Temperature	No	Yes (cold)	Yes (burning)	Yes (cold and hot)	Yes	Yes (hot)	Yes (hot)	No	Yes (cold)
Electric sensation	No	No	Yes	Yes	Yes	Yes, electric	Yes	No	Yes, electric
Pain (rating 0–10)	Sometimes (1/10)	No	Always (8/10)	Yes (5/10)	Yes (4/10)	Yes (4/10)	Yes (6/10)	No	Yes (5/10)

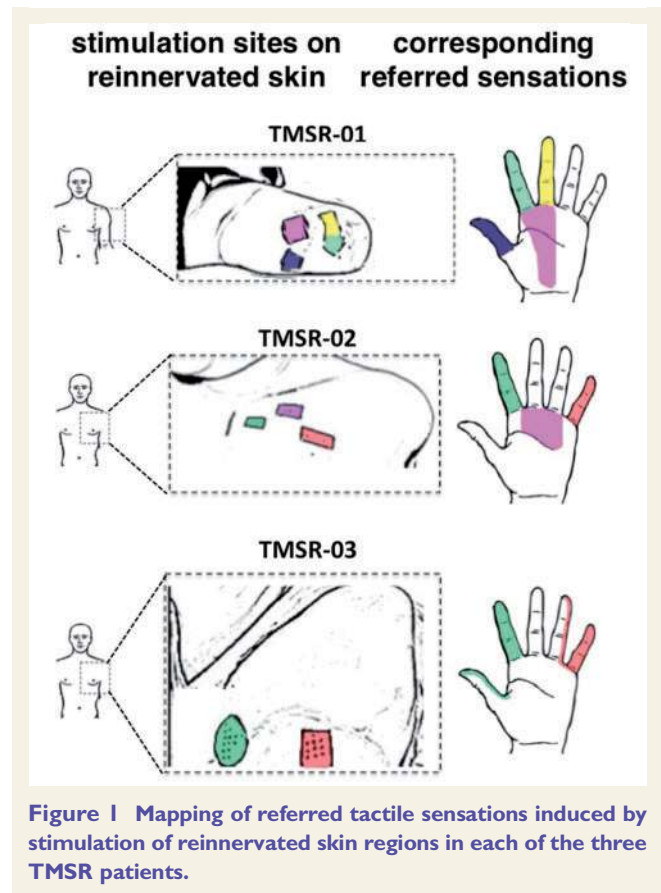


Figure 1 Mapping of referred tactile sensations induced by stimulation of reinnervated skin regions in each of the three TMSR patients.

the skin regions that were used for S1 mapping using 7T functional MRI and the VET experiment in TMSR patients.

Functional MRI data acquisition

Images were acquired on a short-bore head-only 7T scanner (Siemens Medical) with a 32-channel Tx/Rx rf-coil (Nova Medical) (Salomon *et al.*, 2014). Functional images were acquired using a sinusoidal readout EPI sequence (Speck *et al.*, 2008) and comprised 28 axial slices. Slices were placed over the postcentral gyrus (approximately orthogonal to the central sulcus) to cover the primary somatosensory and motor cortices (in-plane resolution $1.3 \times 1.3 \text{ mm}^2$; slice thickness 1.3 mm; no gap; matrix size 160×160 , repetition time = 2 s, field of view = 210 mm, echo time = 27 ms, GRAPPA = 2). Two functional MRI sessions were performed on different days, to map motor and somatosensory representations, respectively. A 5-min resting state acquisition was also performed and participants were asked to lay relaxed and still with the eyes closed and to refrain from any goal-oriented thinking.

Motor representations were mapped using a block design [participants performed in each run three types of movements of one out of six body parts (see below) for 20 times, one movement per second, followed by 10 s of rest]. One run per body side (i.e. left and right) was performed and each block was repeated eight times. Movements were selected based on prosthesis movements (Zhou *et al.*, 2007) and included: hand closure and opening, wrist pronation/supination and elbow

extension/flexion for left and right hands. Blocks of tongue, chest and finger movements on both sides were also included. All participants were trained on the movements before entering the functional MRI scanner and successfully executed the requested movements on the healthy and amputated side.

Somatosensory representations were mapped by adapting the procedure described by Martuzzi *et al.* (2014, 2015): each mapped body regions was manually stroked by the experimenter positioned at the entrance of the bore, with a Q-tip probe (mounted on a stick if necessary). Each area was stroked for 20 s, followed by 10 s of rest (no stroking); the stroking sequence was repeated four times, keeping the order of the stroked body parts fixed. Participants were instructed to pay attention to the body region being stroked. For TMSR and non-TMSR patients, tactile stimulations were delivered on skin regions inducing well-defined referred sensations of the missing limb (Supplementary materials). Additionally, we mapped the lips and the big toe bilaterally, to identify the full extent of the somatotopic homunculus in S1. The stimulation protocol used in amputees was adapted in healthy controls to map the comparable body parts in non-amputated individuals. Mapped body parts included: right and left fingers, palm, arm, chest, lips and big toe (Supplementary material).

Functional MRI data analysis

Statistical analyses were conducted using SPM8 (Wellcome Department of Cognitive Neurology, London, UK), Brainvoyager QX 2.4 (Brain Innovation, Maastricht, The Netherlands), and custom routines running in MATLAB (Mathworks, Boston). Functional volumes were spatially realigned to the first volume. For M1 mapping in which somatotopy is more variable (Beisteiner *et al.*, 2001; Alkadhi *et al.*, 2002), no smoothing was applied to M1 images in order to retain the highest level of spatial specificity. For S1 mapping, images were smoothed with an isotropic Gaussian kernel (full-width at half-maximum = 2 mm) following the procedure presented in Martuzzi *et al.* (2014).

For M1 and S1 mapping, separate statistical analyses were performed using a general linear model (GLM), where each different movement/tactile stimulation was modelled as a boxcar regressor and convolved with the canonical haemodynamic response function (HRF) as basis function and six motion parameters were added as nuisance regressors.

Motor mapping of the hand, wrist, elbow, chest, fingers and tongue movements were calculated for each body side by contrasting each movement to rest epochs (e.g. Hand > Rest). Regions of interest for each body part were collected using False Detection Rate $q < 0.05$ (FDR, Genovese *et al.*, 2002) to correct for multiple comparisons. However, in one participant (Patient non-TMSR-01) we had to use a threshold of $P < 0.0001$ uncorrected because no voxels were activated otherwise (for movements of the elbow on the amputated side).

S1 mapping was performed by computing an F -contrast ($P < 0.001$ uncorrected) including HRF regressors of all the body regions stimulated during the same run, to identify all voxels responding to the stimulation of at least one body region. The result was used as an S1 mask. Maps of single region responses were computed by means of a t -contrast ($P < 0.001$ uncorrected). Within the S1 mask, each voxel was independently labelled as representing the region

demonstrating the highest t -value for that particular voxel leading to a ‘winner takes all’ competition between the stimulated body regions. This procedure was applied independently for the regions of the reinnervated skin for TMSR patients and of the residual limb for non-TMSR patients, for the chest and arm on the intact limb (bilaterally for controls), for the palm and fingers on the intact limb (bilaterally for controls), for right and left big toes, and for right and left lips.

Using resting state data, the functional connections (when available) between left M1–left S1 and between right M1–right S1 were investigated in all TMSR patients, non-TMSR patients and healthy control subjects. In addition, we investigated how each of these regions was functionally connected with the so-called ‘sensorimotor’ network (SMN) (Biswal *et al.*, 1995; Lowe *et al.*, 1998; Xiong *et al.*, 1999; Cordes *et al.*, 2000, 2001; Beckmann *et al.*, 2005; De Luca *et al.*, 2005; Fox *et al.*, 2006). Further details about this analysis are provided in the Supplementary material. The statistical analyses performed on M1 mapping, S1 mapping and functional connectivity data are described below.

Visual enhancement of touch

VET was studied by comparing two-point discrimination thresholds (2PDT; Weinstein, 1968) when subjects saw either the stimulated body part (without viewing the actual tactile stimuli) or another body part (Serino *et al.*, 2009; Serino and Haggard, 2010) (Supplementary material). TMSR patients, comfortably lying down on a bed in a prone position, were presented with tactile stimulation delivered by four mechanical solenoids (M and E Solve), on the target area (non-TMSR or TMSR region), in different experimental blocks. In each trial, subjects were lightly tapped either by a single stimulus (single tap) or by two simultaneous spatially separated stimuli (double tap). Patients were requested to discriminate between single and double taps, by verbally responding ‘one’ (32 trials) or ‘two’ (45 trials). Patients performed the tactile task in two visual conditions, while viewing their hand (‘View Hand’) or the chest/arm (‘View Chest’/‘View Arm’), filmed through a video camera. In the ‘View Hand’ condition patients saw their intact hand, flipped so as to resemble the amputated one (a video of a man’s hand was used for Patient TMSR-03).

A control group of healthy participants performed the task with the same procedure as for TMSR patients. They performed the tactile task either on the chest (‘Touch Chest’) or the hand (‘Touch Hand’), while viewing their chest (‘View Chest’) or their Hand (‘View Hand’).

Signal detection measures were used to quantify tactile performance. Double taps were defined as the to-be-detected signal. D prime (d') was calculated as a measure of perceptual sensitivity (Green and Swets, 1966; Krantz, 1969). For each condition, we calculated the rate of Hits, Misses, False Alarms and Correct Rejections. Hit rates correspond to the number of times participants correctly reported double taps. Misses correspond to the number of times participants reported feeling one tap when two taps were presented. False Alarms correspond to the number of times participants reported two taps when only one was presented. Correct Rejection corresponds to the number of times participants correctly reported feeling one tap. D prime (d') is calculated as the difference between the z -transformations of hit and false alarm rates (Serino *et al.*, 2007). We first verified whether the VET effect could be

reproduced in healthy participants. D' scores of healthy participants were analysed using a repeated measures ANOVA with Stimulation type ('Touch Hand', 'Touch Chest') and Congruency of visual feedback ('Congruent', 'Incongruent') as within-subject factors. VET data were further analysed to statistically compare TMSR patients with healthy controls as described below. We note that the VET experiment could not be conducted in non-TMSR patients because in most cases, the skin area inducing referred sensations was smaller than the 2PDT threshold.

Statistical analyses

For M1 mapping, S1 mapping and functional connectivity data, we first defined an index as the difference between the dependent variables for the body part of interest (TMSR regions) and the corresponding control part (intact region). For VET, we defined an index of the VET effect for the TMSR region and the non-TMSR control region as the difference in d' scores when viewing the body part stimulated or when viewing the other body part. To statistically compare the neuroimaging and behavioural indices between TMSR, non-TMSR and healthy controls, data from single TMSR patients were compared to the non-TMSR and healthy control groups using Crawford tests (Crawford and Garthwaite, 2002). The Crawford test allows one to statistically evaluate the score of a single patient against a modest normative sample and makes use of non-central t -distributions. This test is typically used in case studies, as it is more conservative than standard single-sample t -test; it is thus well suited to compare TMSR patients with the two control groups in the present study. In addition, we made group-level comparisons by computing non-parametric rank-sum Wilcoxon tests (Mann and Whitney, 1947) between TMSR and healthy controls and, between TMSR and non-TMSR controls, as well as between non-TMSR and healthy controls.

Results

M1 mapping

All three TMSR patients showed a normal somatotopic location and order of body part activations in contralateral M1 for different movements of the amputated hand, which were similar to regions activated by the movements made by their intact hand. The same movement-related activations in non-TMSR amputees were reduced or even absent. Moreover, in the two unilateral TMSR patients, activation in the M1 hand area contralateral to the amputated hand was stronger than that induced by movements of the healthy hand; this was not found for any of the non-TMSR patients. In the bilateral TMSR patient, consistent with these findings, activation in the M1 hand area contralateral to the reinnervated side was higher than that induced by movements of the non-reinnervated side. The regions of M1 associated with specific movements of the hand and upper limb in TMSR, non-TMSR amputees, and healthy controls are shown in Fig. 2A.

To quantify M1 activations between TMSR patients, non-TMSR patients, and healthy control subjects we analysed

three main parameters: (i) the extent of the activation for each mapped movement was given by the number of active voxels; (ii) the strength of each activation was quantified by determining the peak activity (max t -value); and (iii) the topographical order of these activations was described by calculating the distance between the centres of mass of activation clusters for different movements.

Extent

We first extracted the number of voxels active during movements of the amputated and healthy hand in the contralateral M1 regions as a measure of the extent of the hand representation. For each patient, we then calculated an index of activation extent, as the difference between the number of active voxels in the right (contralateral to amputation) and the left hemisphere. The index of activation extent was positive in the two unilateral TMSR amputees, indicating more widespread activation in the contralateral M1 during movements of the amputated limb, as compared to the intact limb. The index was positive also in Patient TMSR-03, meaning in this case, that more voxels were activated when he moved his reinnervated amputated hand as compared to the non-reinnervated amputated hand. For each TMSR patient, the index of activation extent was equivalent to that recorded in healthy controls (Fig. 2B) ($t = 1.37$, $P = 0.1$; $t = 1.01$, $P = 0.17$; and $t = 0.81$, $P = 0.22$ for Patients TMSR-01, TMSR-02, and TMSR-03, respectively, as compared to healthy controls using the Crawford test). In contrast, for each TMSR patient this index was larger than for the non-TMSR amputees (Fig. 2B; $t = 2.32$, $P = 0.03$; $t = 2.16$, $P = 0.04$; and $t = 2.07$, $P = 0.04$, for Patients TMSR-01, TMSR-02, and TMSR-03, respectively, as compared to non-TMSR controls using the Crawford test). This analysis therefore suggests that the extent of activations during hand movements in the M1 contralateral to amputation is more similar to normal conditions in TMSR patients as compared to non-TMSR patients. This observation at the single patient level was corroborated at the group level, as non-parametric Wilcoxon comparisons showed that the index of activation extent was not significantly different between TMSR patients and healthy controls ($W = 35.0$, $P = 0.14$), whereas it was significantly more positive in TMSR patients compared to non-TMSR controls ($W = 24.0$, $P = 0.02$). In addition, the index of activation extent was more negative in non-TMSR controls compared to healthy controls ($W = 21.0$, $P < 0.001$). This shows that in non-reinnervated patients, contralateral M1 activity is significantly weaker when performing movements with the amputated arm compared to the healthy arm. The distribution of individual data for all participants for M1 extent indices is shown in Fig. 2C.

Strength

Similar analyses were performed on the peak t -values, taken as an index of activation strength of the representations in M1 concerning hand movements (i.e. the maximal t -value

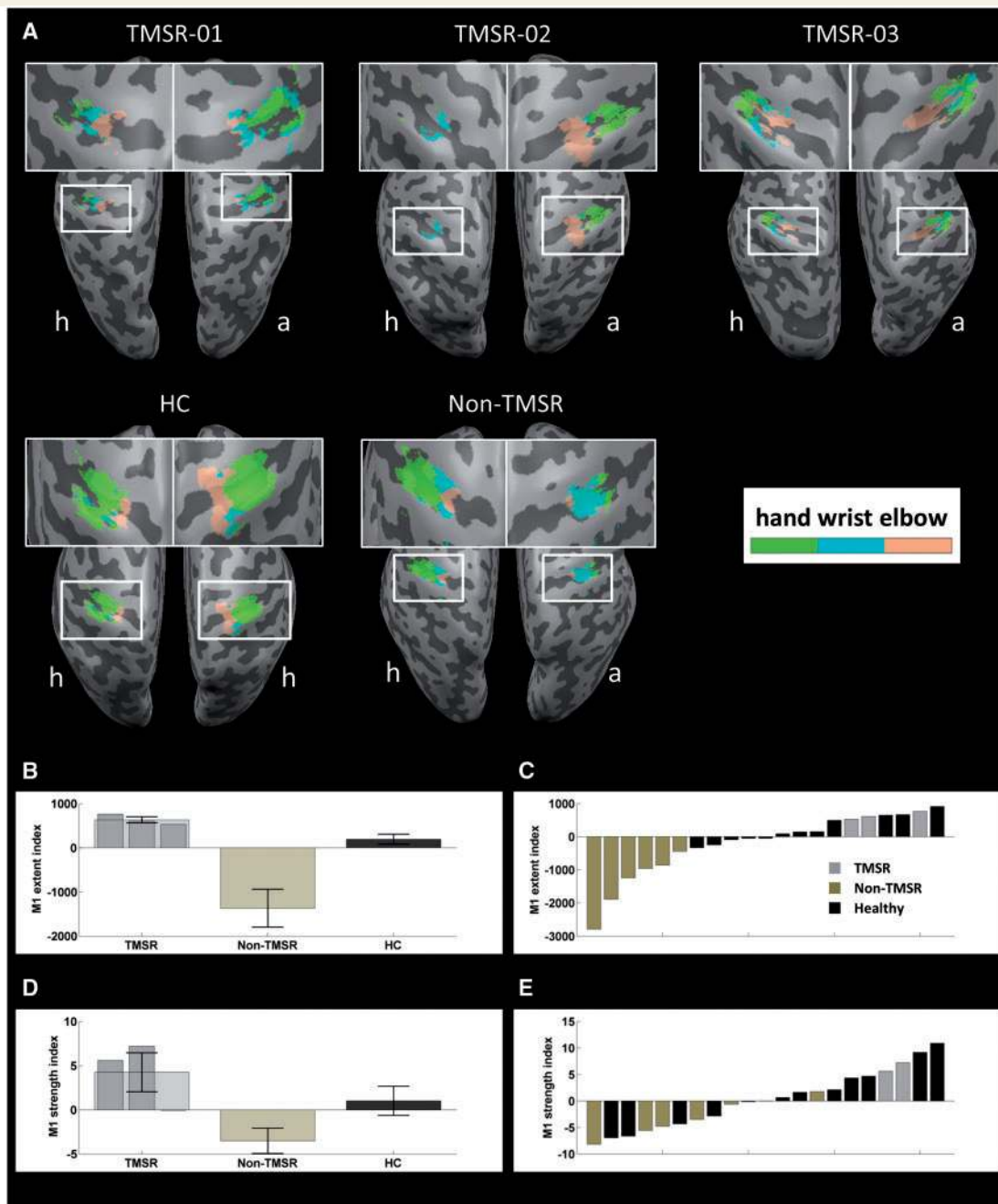


Figure 2 Representations of upper limb movements in M1. (A) M1 regions activated by movements of the contralateral hand in each TMSR and on average in non-TMSR patients and in healthy controls (HC). (B) Indices of differential M1 activations for the right (i.e. contralateral to amputation in unilateral amputees) and left M1 for number of activated voxels, analysed as a measure of the extent of M1 hand representations. (C) Distribution of M1 extent indices for all participants. (D) Indices of differential M1 activations for the right (i.e. contralateral to amputation in unilateral amputees) and left M1 for maximal t -values, analysed as a measure of the strength of M1 hand representations. (E) Distribution of M1 strength indices for all participants. Error bars represent the standard error of the mean (SEM). The labels a and h indicate the hemisphere contralateral to the amputated and healthy side, respectively.

on the side representing the amputated limb minus the maximal t -value representing the healthy limb). These results mimic those of the index of activation extent: the index of activation strength in TMSR patients was positive and not significantly different from healthy controls (Fig. 2D) ($t = 0.77$, $P = 0.23$; $t = 1.04$, $P = 0.16$; and $t = -0.18$,

$P = 0.43$ for Patients TMSR-01, -02 and -03, respectively), whereas it was significantly larger in the two unilateral TMSR patients compared to non-TMSR controls (Fig. 2D) ($t = 2.36$, $P = 0.03$; $t = 2.77$, $P = 0.02$; and $t = 0.89$, $P = 0.2$ for Patients TMSR-01, -02 and -03, respectively). This was confirmed by group-level comparisons showing that the

index was not significantly different between TMSR and healthy controls ($W = 31.0$, $P = 0.37$), but differed between TMSR and non-TMSR controls ($W = 23.0$, $P = 0.04$). Although the comparison between non-TMSR and healthy controls was not significant, there was a trend towards smaller indices in non-TMSR patients compared to healthy controls, as expected ($W = 39.0$, $P = 0.10$). The distribution of individual data for all participants for M1 strength indices is shown in Fig. 2E.

Similar analyses were performed for wrist and elbow movements, and led to findings similar to hand activations (Supplementary material and Supplementary Fig. 2).

Distance

To study whether in addition to the normal extent and strength of M1 activations, patients with TMSR also have a normal location and topographical sequence of activations of the different movements in M1, we localized the centres of mass of activation clusters for hand movements and tongue movements in each hemisphere and calculated their distance (measured as the 3D-Euclidian distance) as a proxy of reorganization due to amputation (Supplementary material and Supplementary Fig. 3). This distance index was calculated by subtracting the hand-to-tongue centre of mass distance in the right hemisphere (contralateral to amputation in unilateral amputees) and in the left hemisphere (Supplementary Fig. 3). The distance index was close to zero in healthy controls, confirming a symmetrically large distance between the representations of the hand and tongue in both hemispheres and the same was found for both patient groups. In none of the TMSR patients were these indices significantly different from healthy and non-TMSR controls at the single-subject level (non-significant Crawford tests) (all $P > 0.06$). Thus, in terms of distance in M1 between body representations, TMSR patients did not differ from the two control groups (healthy and non-TMSR).

These analyses of M1 activity induced by movements of the amputated limb suggest that TMSR results in an almost normal representation of hand movements in contralateral M1 in extent and strength, which were reduced in non-TMSR patients. The location of these different body part representations did not differ between TMSR, non-TMSR patients and healthy controls.

S1 mapping

Activation maps in S1 induced by tactile stimulation of the different body regions are shown in Fig. 3A. For Patient TMSR-01, we observed significant activations within the right S1 (contralateral to the amputated limb) in response to the stimulation of all three skin areas of the residual limb that elicited hand sensations (i.e. the index, the middle finger, and the palm on the left reinnervated residual limb). The representations of the amputated hand were located in corresponding portions of right S1 (i.e. compared to those representing the right healthy

hand in left S1). For Patient TMSR-02, we observed a significant activation within right S1 (though small in size) in response to the stimulation of the regions of the left chest resulting in sensations on the amputated left index finger and on the amputated left little finger. These activations were contralateral and at a corresponding location within S1 with respect to the representation of the fingers of the non-amputated hand. For Patient TMSR-03 (who suffered bilateral amputation), the stimulation of the different body parts did not yield any significant response within S1 on either side of the body. Patient TMSR-03 was then excluded from further S1 analyses. These S1 maps suggest that multiple and reliable finger-specific S1 representations of the missing hand are accessible in TMSR patients. Activations evoked by stimulation of the healthy side of the body resulted in well-defined somatotopically organized activity in the contralateral S1 in TMSR, non-TMSR and healthy control groups.

To compare statistically the S1 representations for the amputated and the healthy limb we performed the same analyses as performed for M1 (extent, strength, distance). Thus, we also computed the difference between contralateral S1 activity when stimulating the amputated versus the healthy limb. For each patient, these values were compared to the homologous indices computed in healthy controls (i.e. as the difference between activity evoked by left and right upper limb stimulation in the contralateral S1).

Extent

Concerning the number of voxels in TMSR patients, the index of activation extent was close to 0 and not significantly different to healthy controls in Patient TMSR-02 ($t = -0.01$, $P = 0.50$) and was even positive in Patient TMSR-01 ($t = 5.19$, $P < 0.001$) (Fig. 3B). Thus, S1 activity evoked by applying touch to reinnervated skin regions that induces tactile sensation on the missing hand and fingers was comparable (or even enhanced) in extent with respect to S1 activations induced by stimulation of the contralateral healthy limb. Compared to non-TMSR controls, the index was significantly larger for Patient TMSR-01 ($t = 2.67$, $P = 0.02$), but not for Patient TMSR-02 ($t = 0.43$, $P = 0.35$). Group-level comparisons did not reveal any significant difference between the three groups (all $P > 0.29$). The distribution of individual data for all participants for S1 extent indices is shown in Fig. 3C.

Strength

S1 activity evoked by stimulation of reinnervated skin regions was lower in intensity, as compared to stimulation of the healthy limb and this was found in all TMSR patients. Indeed, activation indices for t -max values were negative in all TMSR patients and different from those in healthy controls ($t = -2.31$, $P = 0.02$; $t = -1.79$, $P = 0.05$ for Patients TMSR-01 and TMSR-02), but did not differ from those in non-TMSR controls (all $P > 0.3$) (Fig. 3D). This was confirmed by group-level comparisons showing lower values in TMSR patients compared to healthy controls ($W = 3.0$,

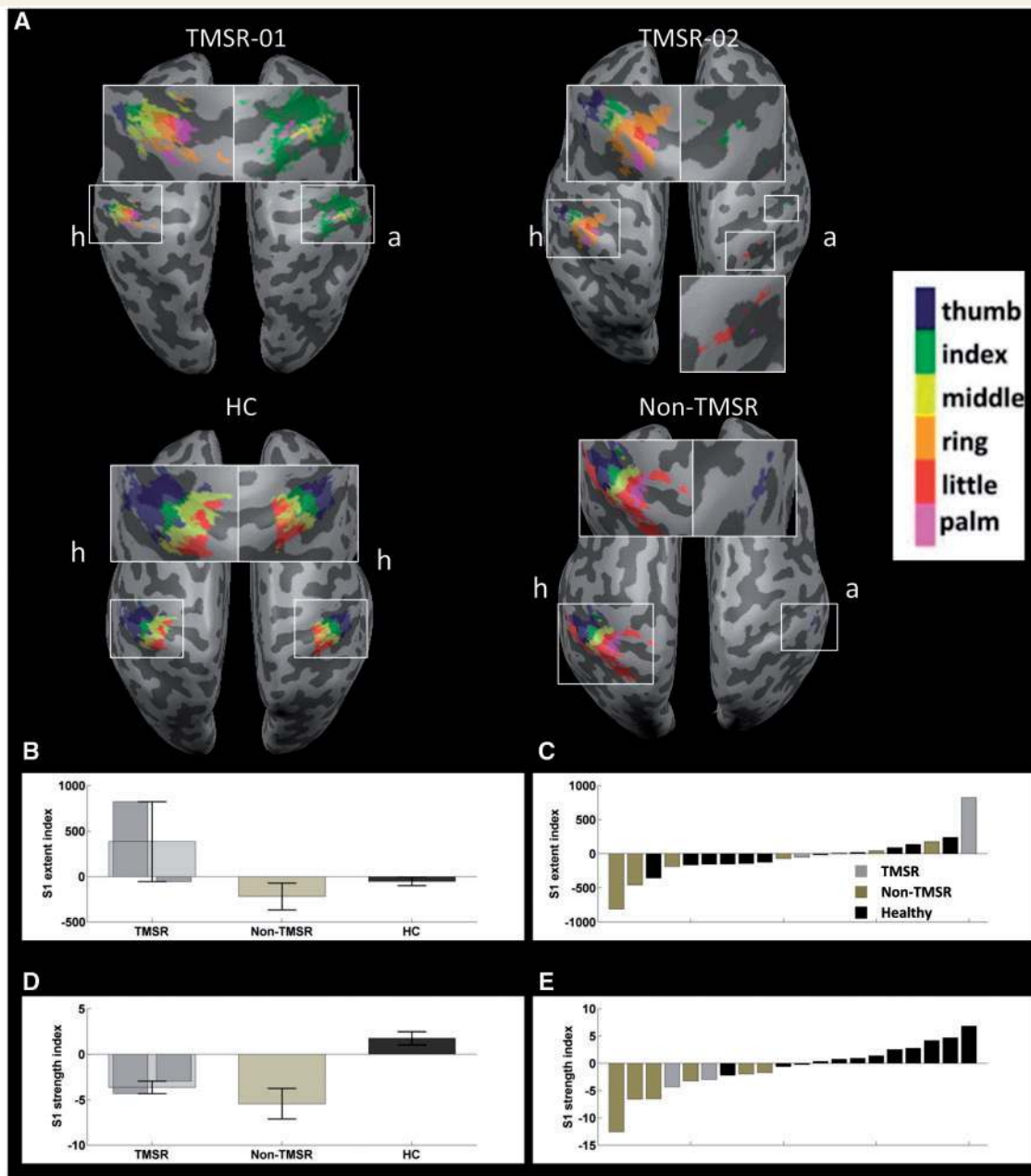


Figure 3 Representations of upper limb tactile processing in S1. (A) S1 regions activated by stimulation of different intact body parts of the reinnervated skin regions inducing well-localized referred tactile sensations on the missing limb in TMSR amputees, of regions of the residual limb inducing referred tactile sensations in non-TMSR patients and of the five fingers in healthy controls. (B) Indices of differential S1 activations for the right (i.e. contralateral to amputation in unilateral amputees) and left S1 for number of activated voxels, analysed as a measure of the extent of S1 hand representations. (C) Distribution of S1 extent indices for all participants. (D) Indices of differential S1 activations for the right (i.e. contralateral to amputation in unilateral amputees) and left S1 for maximal *t*-values, analysed as a measure of the strength of S1 hand representations. (E) Distribution of S1 strength indices for all participants. Error bars represent the standard error of the mean (SEM). The labels a and h show the hemisphere contralateral to the amputated and healthy side, respectively. HC = healthy controls.

$P = 0.02$), but no difference between TMSR and non-TMSR controls ($W = 10.0$, $P = 0.86$). In addition, indices for non-TMSR controls were smaller compared to healthy controls ($W = 23.0$, $P < 0.001$). The distribution of individual data for all participants for S1 strength indices is shown in Fig. 3E.

Distance

To study whether TMSR also resulted in a differential reorganization of S1 as compared to non-TMSR amputees, for each participant we calculated the 3D-Euclidian distance between the centres of mass of the representations of the index finger and the lips in each hemisphere

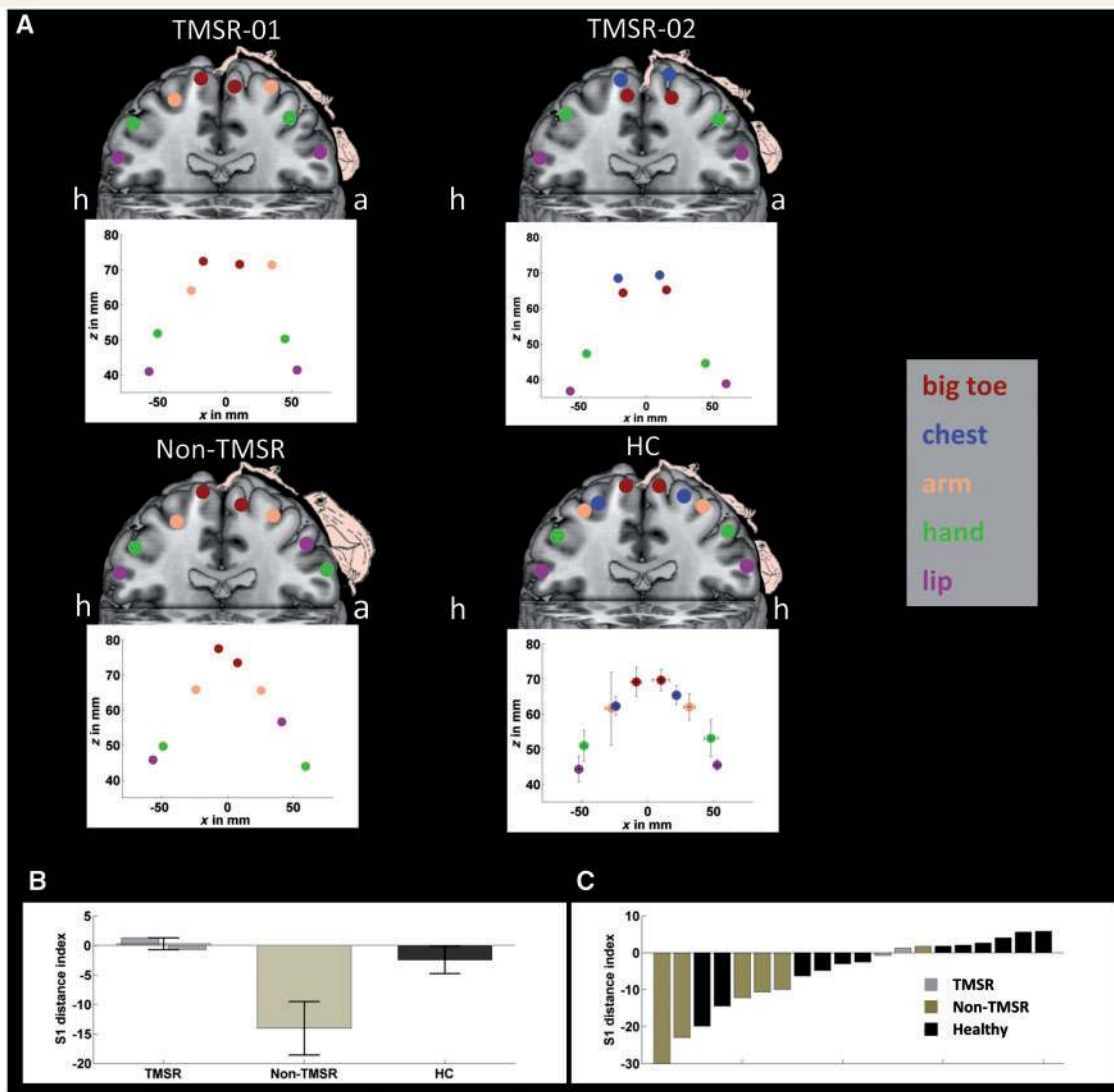


Figure 4 Localization and plasticity in S1 body parts representations. (A) Centre of mass for the representations of different body parts mapped in S1 and their correspondence in S1 homunculus. (B) Index of organization of S1 representations in the two hemispheres computed as the difference in the right (i.e. contralateral to amputation in unilateral amputees) and left S1 of the distance between the centre of mass for activity evoked by lip and by index finger stimulation. (C) Distribution of S1 distance indices for all participants. The labels 'a' and 'h' show the hemisphere contralateral to the amputated and healthy side, respectively. HC = healthy controls.

(Fig. 4A). The distance index in S1 was calculated by subtracting the lip-to-hand distance in the right hemisphere (contralateral to amputation) and in the left hemisphere (Fig. 4B). This index was close to 0 for the TMSR amputees, where hands and lips representations were symmetrical and not significantly different than those in healthy controls ($t = 0.44$, $P = 0.33$; and $t = 0.21$, $P = 0.42$ for Patients TMSR-01 and TMSR-02). This was confirmed by group-level comparison between TMSR patients and healthy controls ($W = 15.0$, $P = 1$). Both single patient and group level comparisons between TMSR patients and non-TMSR controls did not reach significance (all $P > 0.12$), likely due to the small sample size. Group level comparison between non-TMSR and healthy controls showed significantly lower values in non-TMSR ($W = 33.0$,

$P = 0.02$), compatible with S1 reorganization, with an invasion of face areas into the hand areas for the hemisphere contralateral to amputation. The distribution of individual data for all participants for S1 distance indices is shown in Fig. 4C.

To summarize, the TMSR procedure is associated with a residual somatotopic representation in S1 hand region for the parts of the missing limb whose peripheral nerves were retargeted to different skin regions and whose stimulation leads to tactile sensation on the missing hand and fingers. The extent of those representations was similar to those of homologous body parts in the contralateral hemisphere, as in healthy controls. However, the strength of these representations was weaker as compared to those for the intact body parts on the healthy limb and to healthy controls.

Functional connectivity between M1 and S1 and between M1/S1 and the sensorimotor network

To study how M1 and S1 limb representations were interconnected functionally and how each area was integrated with the SMN, we analysed resting state functional connectivity between (i) the hand maps in M1 and in S1; (ii) the hand maps in M1 and SMN; and (iii) the hand maps in S1 and SMN. The results are presented in Fig. 5.

For the M1-S1 analysis, we compared the strength of functional connectivity in the hemisphere contralateral and ipsilateral to amputation by computing an index of M1-S1 connectivity as the difference between the connectivity Z-scores for the right and the left hemisphere. This index was positive in Patient TMSR-01, close to zero in Patient TMSR-02, and in both cases within the normal limits obtained in healthy controls ($t = 0.41$, $P = 0.35$ and $t = -0.15$, $P = 0.44$, respectively), indicating a symmetric pattern of connectivity between the primary motor and somatosensory cortices. The same index was negative in non-TMSR patients, although there was no statistical difference when computing single patient comparisons between TMSR patients and the group of non-TMSR patients ($t = 1.39$, $P = 0.11$ for Patient TMSR-01 and $t = 1.06$, $P = 0.17$ for Patient TMSR-02). Statistical analysis at the group level showed a significant difference in connectivity indices between non-TMSR and healthy controls, showing reduced connectivity in non-TMSR amputees (Wilcoxon rank-sum test, $W = 33.0$, $P = 0.02$), but not between TMSR patients and healthy controls ($W = 18.0$, $P = 0.66$), showing more normal connectivity in TMSR patients (Fig. 5B and C).

We then analysed the functional connectivity between M1-SMN and between S1-SMN in TMSR, non-TMSR controls and healthy controls. Connectivity indices were computed as the difference in Z-scores for M1-SMN and S1-SMN connectivity in the right (contralateral to amputation for patients) minus the left hemisphere (ipsilateral to amputation for patients). Concerning M1-SMN connectivity, the indices were positive in all TMSR patients and not different from healthy controls (Patient TMSR-01: $t = 0.17$, $P = 0.44$; Patient TMSR-02: $t = 0.93$, $P = 0.19$; Patient TMSR-03: $t = 0.52$, $P = 0.31$) (Fig. 5D and E). These indices were on average negative in non-TMSR controls indicating stronger M1-SMN connectivity (for the healthy limb region compared to the amputated limb region). Statistical comparisons between single TMSR patients and the group of non-TMSR patients did not reveal significant differences (Patient TMSR-01: $t = 0.54$, $P = 0.31$; Patient TMSR-02: $t = 1.01$, $P = 0.18$; Patient TMSR-03: $t = 0.76$, $P = 0.24$) (Fig. 5D and E). There were no significant differences at the group level (all $P > 0.26$).

For S1-SMN indices, functional connectivity indices were positive for Patient TMSR-01 and negative for Patient TMSR-02. These indices were on average negative in non-TMSR controls and close to zero in healthy controls. Single subject comparisons showed no differences between

TMSR patients and healthy controls (Patient TMSR-01: $t = 0.19$, $P = 0.43$; Patient TMSR-02: $t = -1.12$, $P = 0.14$) (Fig. 5F and G), or between TMSR patients and non-TMSR controls (Patient TMSR-01: $t = 0.67$, $P = 0.27$; Patient TMSR-02: $t = -0.09$, $P = 0.47$) (Fig. 5F and G). At the group level, there were no statistical differences between the three groups (all $P > 0.18$).

Taken together, these results suggest that TMSR is associated with normal connectivity between S1 and M1, while such connectivity is reduced in non-TMSR amputees. Connectivity results between M1/S1 and SMN are less consistent, due to large between-subjects variability and low statistical power. Generally, and confirmed from inspection of individual data (Fig. 5C, E and G), connectivity between M1 and SMN appeared not to differ between healthy controls and TMSR participants, and was reduced in non-TMSR subjects, while the connectivity between S1 and SMN appeared to be reduced in both groups of patients.

Visual enhancement of touch

Based on the previous results, one might predict that primary sensory functions of the TMSR skin region are normal and acquire some of the tactile properties of the missing hand before amputation, as shown by previous studies demonstrating enhanced tactile acuity on TMSR regions as compared to homologous non-reinnervated skin regions (Marasco *et al.*, 2009). However, because of the partially reduced functional connectivity between S1 and SMN, TMSR patients might show impaired multisensory integrative behavioural effects, typically present for intact body representations, as these rely on the interaction between unisensory and multisensory areas (Taylor-Clarke *et al.*, 2002; Ro *et al.*, 2004; Konen and Haggard, 2014). To test this hypothesis, we studied VET in TMSR amputees, as an index of visuo-tactile interaction (Kennett *et al.*, 2001; Serino and Haggard, 2010). VET consists of a facilitation of tactile acuity if subjects simultaneously see the stimulated body part (without seeing the actual tactile stimulation), as compared to conditions of no visual stimulation, vision of a non-bodily stimulus, or vision of a non-homologous body part (Serino *et al.*, 2009). Here, we compared the effectiveness of the VET effect for reinnervated and non-reinnervated body parts by measuring tactile acuity on TMSR and non-TMSR regions of the residual limb or chest, while patients were either viewing the body part to which tactile sensations were referred to (i.e. the hand or the physically stimulated body part, i.e. the arm in Patient TMSR-01 or chest in Patients TMSR-02 and TMSR-03). These results were compared to the VET effect in healthy participants on the hand and the chest (see ‘Materials and methods’ section).

In line with previous reports (Kennett *et al.*, 2001; Haggard *et al.*, 2007; Serino *et al.*, 2009), in healthy participants, tactile acuity (d' scores) was higher when visual information matched the stimulated body part (Fig. 6). The ANOVA run on d' scores with Stimulation type (‘Touch Hand’, ‘Touch Chest’) and Congruency of visual feedback

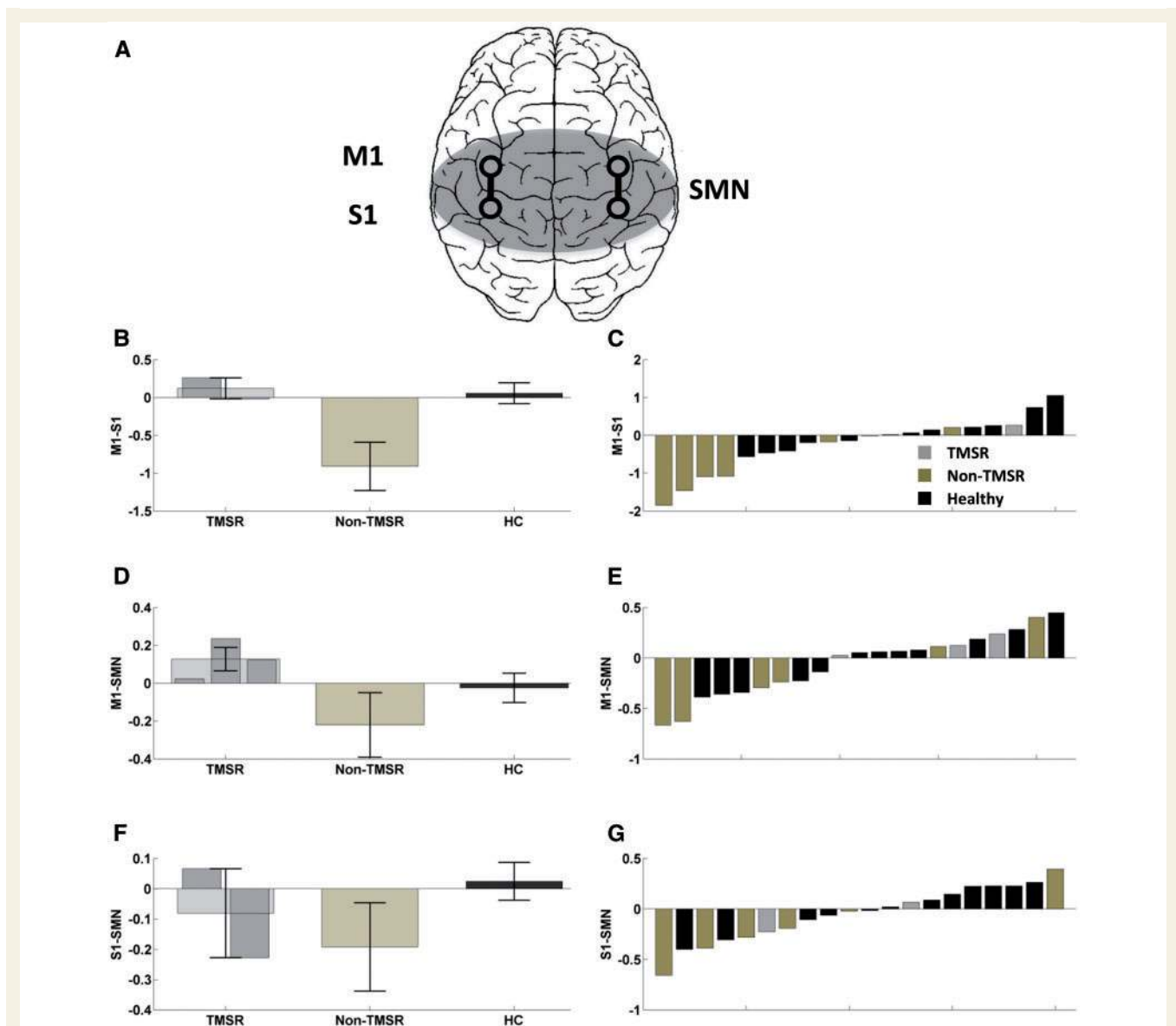


Figure 5 Connectivity between M1, S1 and the SMN. (A) Schematic representation of M1 and S1 regions of interest in the right and left hemisphere, as well as the SMN. (B) Index of differential connectivity between the right (contralateral to amputation) and the left hemisphere for M1-S1. (C) Distribution of M1-S1 connectivity indices for all participants. (D) Index of differential connectivity between the right (contralateral to amputation) and the left hemisphere for M1-SMN. (E) Distribution of M1-SMN connectivity indices for all participants. (F) Index of differential connectivity between the right (contralateral to amputation) and the left hemisphere for S1-SMN. (G) Distribution of S1-SMN connectivity indices for all participants. Error bars represent the standard error of the mean (SEM). HC = healthy controls.

(‘Congruent’, ‘Incongruent’) as within subjects factors, showed a significant main effect of Congruency [$F(1,17) = 25.55$, $P < 0.0001$]. Since there was no main effect of stimulation type, hand and chest data were averaged for further analysis. Thus, in healthy participants, a clear somatotopic pattern in the VET effect was found (Serino *et al.*, 2009), both for the hand and the chest.

As shown in Fig. 6, in all TMSR patients, an amelioration of tactile acuity was found when tactile stimulation was administered on the non-TMSR skin region when patients were looking at the congruent body part (chest or

arm), as compared to when they were looking at a hand, thus showing a somatotopically determined VET effect. However, crucially, for the present study, this effect was absent when tactile stimulation was provided to the TMSR region (chest or residual limb) evoking tactile perception on the hand while patients were looking at the hand, as compared to when looking at their chest or arm.

To provide statistical support to these observations, we calculated an index of the VET effect for the TMSR and the non-TMSR region as the difference in d' scores when viewing the body part stimulated (congruent) or when

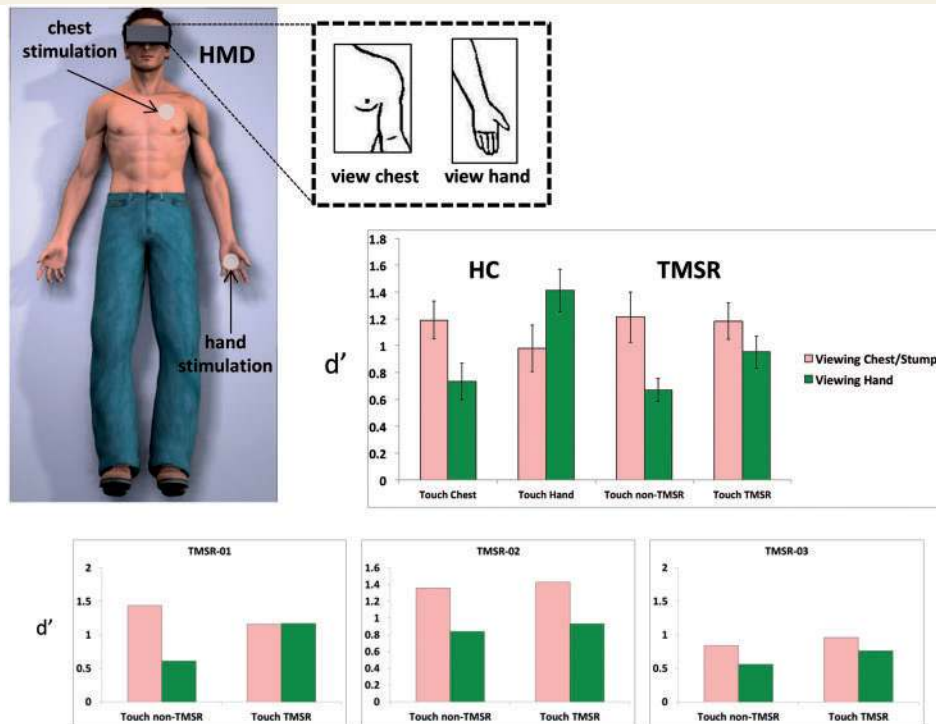


Figure 6 Visual enhancement of touch. Schematic representation of the VET set-up, showing the participants' posture during the experiment and visual stimulation provided via head-mounted displays (HMD). Accuracy in two-point discrimination task (measured as d' score) for tactile stimuli administered to the each of two target body parts [hand-chest in healthy controls (HC); TMSR or non-TMSR skin regions in TMSR amputees], while participants viewed either stimulated or the non-stimulated body part.

viewing the other body part (incongruent). Those values were compared to the analogues indices computed in healthy controls for VET effect (d' congruent – d' incongruent). For the non-TMSR regions, the VET index was equivalent in the three TMSR patients to the VET index in healthy controls (Crawford test: Patient TMSR-01: $t = 1.03$, $P = 0.16$; Patient TMSR-02: $t = 0.21$, $P = 0.42$; Patient TMSR-03: $t = -0.42$, $P = 0.34$). In contrast, the VET index for the TMSR region was significantly lower in Patients TMSR-02 and TMSR-03 compared to in controls, with a trend for Patient TMSR-01 (Patient TMSR-01: $t = -1.13$, $P = 0.13$; Patient TMSR-02: $t = -2.47$, $P = 0.01$; Patient TMSR-03: $t = -1.68$, $P = 0.05$). These findings were confirmed by group-level analyses, showing equivalent VET indices for non-TMSR regions in patients compared to controls (Wilcoxon rank-sum test: $W = 40.0$, $P = 0.51$), and significantly lower indices for TMSR regions in patients compared to controls ($W = 9.0$, $P = 0.02$). Thus, these psychophysical data reveal an absence of visuo-tactile interaction for TMSR body regions.

Discussion

This study is the first systematic investigation of how a bionic prosthesis for upper limb amputees based on TMSR impacts the functional organization of the missing

limb in M1 and S1, their mutual connectivity, and their connectivity with the frontoparietal sensorimotor network. We report that, first, the M1 maps for hand and arm movements controlling the prosthetic limb appear intact in TMSR patients: they are similar in extent and strength compared to healthy individuals performing the same actions with physically existing limbs and are stronger than those in non-TMSR amputees. Second, S1 activity evoked by applying touch to reinnervated skin regions on the chest or residual limb (inducing tactile sensation on the missing hand) activated well-defined portions in locations that were comparable to the normal hand region in S1, although these activations were weaker compared to healthy controls. Third, TMSR is associated with normal local functional connectivity between M1-S1 upper limb regions, whereas this was not the case for non-TMSR amputees. Finally, functional connectivity with sensorimotor areas was reduced in both amputee groups for S1 and associated with the absence of the VET, shown previously to depend on projections to S1 from multisensory regions in the superior parietal cortex and ventral premotor cortex (Serino and Haggard, 2009), part of the sensorimotor network. Although these findings are based on a relatively limited sample of patients, primarily due to the fact that TMSR patients are rare (see limitations of the study section), we were able to exploit the high spatial resolution of ultra

high-field 7 T functional MRI and single case analysis. Here, we discuss what these findings reveal about plasticity of body maps in S1 and in M1 and the relevance of our findings for current and future approaches in bionic limbs.

TMSR reinstates M1 upper limb representation

In order to map motor cortex in amputees, we used a paradigm employed by previous investigators, consisting of asking patients to perform movements with their amputated limb or with their mouth and studied the associated functional MRI activity in M1 (Lotze *et al.*, 1999; Makin *et al.*, 2013a, 2015b; van den Heiligenberg *et al.*, 2015). Due to the lower spatial resolution of earlier work using 1.5 T or 3 T functional MRI (and because of somatosensory-related processing associated with the tested movements), previous reports were not able to distinguish between motor versus somatosensory evoked activity or whether the activity was in the anterior or posterior banks of the central sulcus. Accordingly, it was not separately investigated how M1 and S1 contributed to the reported activation patterns in amputees. Across these studies it was found that, compared to healthy participants, sensorimotor activations in upper limb amputees differ in terms of strength, extent and location (see Reilly and Sirigu, 2008 for a review). Extending our previous work on human S1 using ultra high-field functional MRI in healthy subjects (Martuzzi *et al.*, 2014, 2015; Akselrod *et al.*, 2017) we were here able to separately investigate S1 and M1 in TMSR patients. We found that the M1 activations during movements of the phantom limb in non-TMSR amputees were reduced in terms of extension and strength compared to healthy controls, in line with previous findings (reporting activations in M1 and S1). This was different in the three TMSR patients in whom M1 activations were comparable to controls. Thus, M1 activity related to the control of the prosthetic limb (via decoded EMG signals recorded from muscles reinnervated by residual arm nerves) is associated with normal upper limb activations in TMSR amputees. This suggests that the functional solicitation of M1 upper limb areas associated with the use of a prosthetic limb is potentially able to reinstate normal M1 maps. In all participants (TMSR, non-TMSR and healthy controls), the mapped motor activations were located on the precentral gyrus corresponding to M1, and showed the normal somatotopic organization within M1, compatible with a recent 7 T study reporting finger somatotopy in M1 in healthy participants (Siero *et al.*, 2014). We note that although the somatotopic organization was observed in all participants, the exact location of motor maps differed across participants, highlighting the importance of single subject analysis at ultra-high field strength to study the organization of M1.

We also measured the degree of cortical reorganization within M1 following amputation, by quantifying the

displacement of mouth activations towards the missing hand activations as measured by previous authors using 1.5 or 3 T functional MRI (Lotze *et al.*, 1999, 2001; see Mercier *et al.*, 2006; Reilly *et al.*, 2006; Reilly and Sirigu, 2008 for evidence from TMS). The present 7 T functional MRI investigation, however, did not reveal any evidence for cortical reorganization (i.e. changes in the location of the lip M1 representation with respect to the hand M1 representation in either group of amputees). Some important studies in the field suggest that the amount of cortical reorganization is strongly correlated with the degree of phantom pain (Flor *et al.*, 1995; Lotze *et al.*, 2001). One recent report showed a small, but consistent displacement of lip representation, which was, however, not correlated to phantom limb pain (Makin *et al.*, 2015b). Considering these controversial reports, currently the existence and nature of the relationship between the phenomenology of phantom limbs and cortical reorganization following limb loss remains unclear. The present data do not allow us to draw firm conclusions about it in TMSR patients, because of the small sample size. On the one hand, the absence of phantom limb pain in two of three TMSR patients in the present study would predict low cortical reorganization accordingly to Flor *et al.*'s (1995) findings. On the other hand, the patient who presented chronic and severe phantom pain, i.e. Patient TMSR-03, did not show significant cortical reorganization. However, he suffered bilateral shoulder disarticulation, which may have induced a rather different pattern of cortical reorganization as compared to unilateral amputees, previously tested. A previous study with larger sample size ($n = 28$) suggested that TMSR is a promising approach to reduce neuroma pain (Souza *et al.*, 2014). It would be interesting in the future to test cortical reorganization in these patients to provide novel insight about the relationship between cortical reorganization and pain and the role of TMSR in modulating it.

TMSR allows accessing S1 upper limb representation

Mapping somatosensory activations of the missing limb in S1 in amputees has been more challenging than mapping movements in M1 (Yang *et al.*, 1994; Flor *et al.*, 1995; Ramachandran *et al.*, 1995; Björkman *et al.*, 2012). Influential MEG studies assessed the maps of the missing limb in S1 by stimulating the patient's lip region and revealed evidence for a distorted somatotopic organization in S1 after amputation, suggesting that the face area shifted medially towards or into the hand area (Yang *et al.*, 1994; Flor *et al.*, 1995; Ramachandran *et al.*, 1995). A more recent 3 T functional MRI study investigated the maps of the missing limb in S1 by stimulating specific residual limb regions that evoked referred tactile sensations on the missing hand (Björkman *et al.*, 2012). These authors found that activity in several S1 regions that were activated by stimulation of the residual limb showed differences in location

and extent depending on whether stimulation induced referred tactile sensation on the missing hand or not (Björkman *et al.*, 2012). In the present study, we used 7 T functional MRI and extended this approach to TMSR patients, in whom specific tactile-referred sensations can be induced by stimulating reinnervated skin regions on the chest or the residual arm. Such surgically reinnervated skin regions have the advantage of covering larger portions of skin and of being spatially well segregated, offering a high resolution tactile interface to induce controlled, reliable and specific phantom limb sensations in TMSR patients (Kuiken *et al.*, 2007a; Hebert *et al.*, 2014). Thus, we asked whether spontaneous S1 reorganization as occurring in non-TMSR-amputees, differs from S1 reorganization associated with the surgical redirection of somatosensory nerve fibres in the TMSR procedure. Our data reveal two findings. First, S1 tactile activations concerning the missing limb of TMSR patients were located at a position corresponding to the S1 hand activations in healthy controls, although they were weaker in terms of strength of activation. Second, TMSR-related S1 activations were somatotopically organized and comparable to those in healthy controls (based on the distance between hand and lip representations); this was not the case for non-TMSR patients, who showed larger shifts of maps in S1. The displacement of the lip map has been proposed as a marker of maladaptive plasticity in amputee patients, due to lack of hand-related sensory inputs in amputation (Flor *et al.*, 1995). Moreover, the degree of such maladaptive changes has been related to the level of phantom pain in amputees (but see Makin *et al.*, 2013a, 2015b) and has been shown to be reversible after an extensive tactile training over the residual limb region, which also decreased pain ratings (Flor *et al.*, 2001). Based on these earlier findings and on the normal topographical S1 organization and smaller degree of maladaptive plasticity found in TMSR patients, we speculate that TMSR might reduce maladaptive plasticity in S1 (in addition to M1) maps by restoring the representations of the missing limb and may potentially prevent or diminish phantom limb-related symptoms. However, we note that the present investigation, based on data from three TMSR patients, was not aimed at and does not allow for establishing a direct link between S1 organization and phantom limb pain.

TMSR reinstates functional connectivity between M1-S1 upper limb maps

The interaction between motor and somatosensory maps is crucial during action execution and studies in healthy subjects have revealed strong functional connectivity within a network formed by the motor and somatosensory cortex and other higher-order sensorimotor areas (e.g. premotor cortex, Yeo *et al.*, 2011), as well as with association cortex (e.g. the superior parietal lobe, Rizzolatti and Matelli,

2003; Markov *et al.*, 2013), i.e. the so-called SMN (Biswal *et al.*, 1995; Lowe *et al.*, 1998; Xiong *et al.*, 1999; Cordes *et al.*, 2000, 2001; Beckmann *et al.*, 2005; De Luca *et al.*, 2005; Fox *et al.*, 2006). This sensorimotor functional connectivity has been shown to be altered in many clinical conditions, such as stroke or schizophrenia (Meyer-Lindenberg *et al.*, 2001; Gerloff *et al.*, 2006; Mostofsky *et al.*, 2009; Helmich *et al.*, 2010; Wang *et al.*, 2010). Recently, it has been observed in amputees that the functional connectivity between the representation of the missing limb and the rest of the SMN is decreased (Makin *et al.*, 2015a). Based on the present high resolution and functionally specific mapping approach, we were able to directly test M1-S1 connectivity and found that the M1 hand map was normally connected with the S1 hand map in TMSR patients, while M1-S1 functional connectivity was significantly reduced in non-TMSR amputees. Together M1-S1 connectivity data and M1 and S1 mapping data suggest therefore that the TMSR procedure is associated with normal upper limb sensorimotor maps and stronger functional mutual interconnections between M1 and S1, as compared to non-TMSR amputees.

On the other hand, upper limb control and perception depend not only on neural processing within motor and unisensory cortices, but on a more widely distributed network of areas integrating multisensory and motor signals that involve higher-level motor regions and multisensory regions in the posterior parietal cortex. In particular, the posterior parietal cortex and the premotor cortex contain neuronal populations integrating multisensory bodily signals (Graziano and Botvinick, 2002; Berlucchi and Aglioti, 2010; Serino and Haggard, 2010; Blanke *et al.*, 2015), and neural processing in these areas has been linked to multisensory visuo-tactile stimulation and the sense of hand ownership (Ehrsson *et al.*, 2004, 2005; Gentile *et al.*, 2015; Grivaz *et al.*, 2017). Prominent functional and structural connectivity exist between posterior parietal and premotor areas, part of the sensorimotor network and primary motor and somatosensory regions (Rushworth *et al.*, 2006; Tomassini *et al.*, 2007; Uddin *et al.*, 2010; Mars *et al.*, 2011; Yeo *et al.*, 2011), underlying motor execution and motor imagery (Solodkin *et al.*, 2004; Gao *et al.*, 2011). Therapeutically, paradigms used to treat phantom limb syndrome (such as the mirror box therapy) directly exploit the multisensory nature of limb representation and likely rely on multimodal (i.e. visuo-somatosensory-motor) maps of the upper limb within an extended multisensory-motor network (Chan *et al.*, 2007; Ehrsson *et al.*, 2008; Ramachandran and Altschuler, 2009). When we investigated the integrity of functional connectivity of M1 and of S1 with the rest of the SMN, including key parietal and premotor multisensory regions, we found less consistent and solid results as compared to S1-M1 connectivity data, likely due to higher variability between individuals, combined with low statistical power. In general, the upper limb functional maps identified in M1 appeared functionally connected with the rest of the SMN in TMSR patients.

Instead, individual patients' data suggested reduced connectivity between S1 unimodal and multimodal areas both for non-TMSR and TMSR patients. These results extend recent reports by Makin *et al.* (2015a) showing that in amputees, the combined S1-M1 map of the missing limb is less connected with the SMN, as defined by Beckmann *et al.* (2005). Importantly, our connectivity results show that only distant (i.e. within the whole sensorimotor network), but not local (i.e. between M1 and S1) connectivity of the upper limb is impaired in TMSR patients. Thus, although the repetitive movements of the EMG-driven myoelectric prosthesis in TMSR patients seems to reinstate M1 (and partially S1) representations and their mutual local functional connectivity, current TMSR systems do not completely normalize connectivity with more distant parietal and premotor multi-sensory regions.

The latter finding, and in particular the reduced connectivity between S1 and SMN, was further supported by the behavioural data on VET, showing that—although touch sensation on the missing limb can be reliably evoked in TMSR patients—this information is not integrated with visual bodily cues. Indeed, viewing a hand, while performing a tactile spatial discrimination task on the reinnervated skin region, did not improve tactile perception in TMSR patients: the VET effect that occurs in healthy participants (Kennett *et al.*, 2001; Haggard *et al.*, 2003; Serino and Haggard, 2010) is absent for the reinnervated body part in TMSR patients. The VET effect depends on the integration of visual cues related to the body with tactile inputs, based on projections from multimodal areas in posterior parietal cortex to S1 (Taylor-Clarke *et al.*, 2002; Ro *et al.*, 2004; Serino *et al.*, 2009; Cardini *et al.*, 2011; Konen and Haggard, 2014). The lack of hand-related VET in TMSR patients, therefore, corroborates the reduction of functional interactions between the sensorimotor network and S1 hand maps. We speculate that this is due to the fact that current TMSR interfaces do not utilize somatosensory inputs (via the reinnervated skin regions) in current prostheses. Such integrated tactile input seems important for the development of future TMSR devices as under normal conditions, when we move our hands and touch different objects, we receive coherent visual, auditory, tactile, and proprioceptive cues that the brains integrates for optimal control (Maravita *et al.*, 2003; Blanke *et al.*, 2015). However, in current TMSR prostheses (and most other bionic limbs), motor commands generated to drive the prosthesis are controlled only with visual information related to the prosthetic limb, without integrated somatosensory feedback. Our behavioural and imaging data suggest that current procedures are not able to reinstate multimodal upper limb representations that are based on interactions between unimodal and multimodal hand maps.

Limitations of the study

The present study suffers from limitations. First, because TMSR patients belong to a very rare population, the

number of TMSR patients investigated in this study is relatively small. For this reason, we used a single-subject approach to fully describe their results. At the same time, generalization to the group-level based on these results should be considered with caution. In addition, given the small number of patients, we could not establish any link between upper limb representation in S1 and M1 and clinical features of phantom limb syndrome, such as pain, which is a topic of debate in the field (see Flor *et al.* 1995; Makin *et al.*, 2013a, b; Souza *et al.*, 2014). Second, we could not assess the effects of TMSR in a pre/post-intervention design; therefore the results are based on comparisons with other control subjects, rather than longitudinal within-subject comparisons. For this reason, we are not able to determine whether TMSR prevents cortical reorganization in sensorimotor areas or rather restores a normal organization in these areas. Third, considering that there was no blind design, we cannot completely rule out the possible presence of unconscious biases from the experimenter who administered somatosensory stimulation. Nevertheless, the experimenter providing the stimulation was highly trained prior to data acquisition to reduce the variability of the stimulation, and we have used a method that is consolidated (Martuzzi *et al.*, 2014, 2015), whereas sometimes automatic mechanical stimulation leads to inconclusive results (van der Zwaag *et al.*, 2015). A similar argument holds for motor mapping, as we cannot rule out unconscious biases in our amputee patients when performing phantom movements (for example asymmetry in effort). Nevertheless, all patients were well trained and able to easily execute the task before entering the scanning and it is unlikely that TMSR and non-TMSR patients could bias the results of the study in the direction predicted by our experimental hypotheses. In addition, we note that the sample size of the non-TMSR group is relatively small. Although the statistical approach considered in the present study specifically addresses this issue (Crawford and Garthwaite, 2002) and although the results obtained for the non-TMSR group are in line with results reported in studies using larger samples (Reilly and Sirigu, 2008), generalization of the present results to all non-TMSR patients, based on the present data, should be regarded with caution.

Conclusions and outlook

'Closing the loop' between motor control and sensory feedback is a key target for the next generation of bidirectional neuroprosthetic devices. Recent advances have been made with peripheral implants (Raspovic *et al.*, 2014) and likely target the brain and S1 in particular (i.e. Bensmaia and Miller, 2014; Bensmaia, 2015) to inject tactile information sensed by the prosthetic device directly into the nervous system. These advancements may not only improve prosthesis control during hand-object interaction, but may also minimize abnormal cortical reorganization, boost

prostheses acceptance and somatosensory experiences. Indeed, current models in neuroscience propose that complex bodily experiences such as the experience of the body as one's own (body ownership) normally arise through the integration of multisensory body-related cues, within a distributed network of unisensory and multi-sensory fronto-parietal areas (Tsakiris, 2010; Blanke, 2012; Ehrsson, 2012; Blanke *et al.*, 2015). A prosthesis, being able not only to transform the patient's motor commands into movements of the prosthesis, but also to interface motor control with integrated multisensory signals from the robotic hand and objects it is in contact with, may be felt like a real limb (De Preester and Tsakiris, 2014; Bensmaia, 2015). Such an embodied prosthetic limb would become 'part of the patient's body' and have less maladaptive plasticity through full functional integration within and beyond the sensorimotor cortex. Recent experiments with bidirectional signal flow including somatosensory feedback to the reinnervated skin regions (Marasco *et al.*, 2011) or the peripheral nervous system (Raspopovic *et al.*, 2014) suggest that this is feasible and potentially effective.

Acknowledgements

The authors would like to thank the patients who participated with enthusiasm and commitment to this study, in particular A, C and J.

Funding

This work has been funded by the Swiss National Science Foundation and the Bertarelli Foundation.

Supplementary material

Supplementary material is available at *Brain* online.

References

- Alkadhi H, Crelier GR, Boendermaker SH, Golay X, Hepp-Reymond MC, Kollias SS. Reproducibility of primary motor cortex somatotopy under controlled conditions. *Am J Neuroradiol* 2002; 23: 1524–32.
- Akselrod M, Martuzzi R, Serino A, van der Zwaag W, Gassert R, Blanke O. Anatomical and functional properties of the foot and leg representation in areas 3b, 1 and 2 of primary somatosensory cortex in humans: A 7T fMRI study. *Neuroimage* 2017; 159: 473–87.
- Beckmann CF, DeLuca M, Devlin JT, Smith SM. Investigations into resting-state connectivity using independent component analysis. *Philos Trans R Soc Lond B Biol Sci* 2005; 360: 1001–1013.
- Beisteiner R, Windischberger C, Lanzenberger R, Edward V, Cunningham R, Erdler M, et al. Finger somatotopy in human motor cortex. *Neuroimage* 2001; 13: 1016–26.
- Bensmaia SJ. Biological and bionic hands: natural neural coding and artificial perception. *Philos Trans R Soc Lond B Biol Sci* 2015; 370: 20140209.
- Bensmaia SJ, Miller LE. Restoring sensorimotor function through intracortical interfaces: progress and looming challenges. *Nat Rev Neurosci* 2014; 15: 313–25.
- Berlucchi G, Aglioti SM. The body in the brain revisited. *Exp Brain Res* 2010; 200: 25–35.
- Biswal B, Yetkin FZ, Haughton VM, Hyde JS, Zerrin Yetkin F, Haughton VM, et al. Functional connectivity in the motor cortex of resting human brain using echo-planar MRI. *Magn Reson Med* 1995; 34: 537–41.
- Björkman A, Weibull A, Olsrud J, Ehrsson HH, Rosén B, Björkman-Burtscher IM. Phantom digit somatotopy: a functional magnetic resonance imaging study in forearm amputees. *Eur J Neurosci* 2012; 36: 2098–106.
- Blanke O. Multisensory brain mechanisms of bodily self-consciousness. *Nat Rev Neurosci* 2012; 13: 556–71. doi: 10.1038/nrn3292
- Blanke O, Slater M, Serino A. Behavioral, neural, and computational principles of bodily self-consciousness. *Neuron* 2015; 88: 145–66.
- Cardini F, Longo MR, Haggard P. Vision of the body modulates somatosensory intracortical inhibition. *Cereb Cortex* 2011; 21: 2014–22.
- Chan BL, Witt R, Charrow AP, Magee A, Howard R, Pasquina PF, et al. Mirror therapy for phantom limb pain. *N Engl J Med* 2007; 357: 2206–7.
- Chen A, Yao J, Kuiken T, Dewald JPA. Cortical motor activity and reorganization following upper-limb amputation and subsequent targeted reinnervation. *Neuroimage Clin* 2013; 3: 498–506.
- Cordes D, Haughton VM, Arfanakis K, Carew JD, Turski PA, Moritz CH, et al. Frequencies contributing to functional connectivity in the cerebral cortex in "resting-state" data. *Am J Neuroradiol* 2001; 22: 1326–33.
- Cordes D, Haughton VM, Arfanakis K, Wendt GJ, Turski PA, Moritz CH, et al. Mapping functionally related regions of brain with functional connectivity MR imaging. *Am J Neuroradiol* 2000; 21: 1636–44.
- Crawford JR, Garthwaite PH. Investigation of the single case in neuropsychology: confidence limits on the abnormality of test scores and test score differences. *Neuropsychologia* 2002; 40: 1196–1208
- De Luca M, Smith S, De Stefano N, Federico A, Matthews PM. Blood oxygenation level dependent contrast resting state networks are relevant to functional activity in the neocortical sensorimotor system. *Exp Brain Res* 2005; 167: 587–94.
- De Preester H, Tsakiris M. Sensitivity to differences in the motor origin of drawings: from human to robot. *PLoS One* 2014; 9: e102318.
- Dijkerman HC, de Haan EHF. Somatosensory processes subserving perception and action. *Behav Brain Sci* 2007; 30: 189–201; discussion 201–39.
- Dumanian GA, Ko JH, O'Shaughnessy KD, Kim PS, Wilson CJ, Kuiken TA. Targeted reinnervation for transhumeral amputees: current surgical technique and update on results. *Plast Reconstr Surg* 2009; 124: 863–9.
- Ehrsson HH. The concept of body ownership and its relation to multisensory integration. In: Stein BE, editor. *The new handbook of multisensory processes*, chapter 43. Cambridge: MIT Press; 2012. p. 775–92.
- Ehrsson HH, Holmes NP, Passingham RE. Touching a rubber hand: feeling of body ownership is associated with activity in multisensory brain areas. *J Neurosci* 2005; 25: 10564–73.
- Ehrsson HH, Rosén B, Stockselius A, Ragnö C, Köhler P, Lundborg G. Upper limb amputees can be induced to experience a rubber hand as their own. *Brain* 2008; 131(Pt 12): 3443–52.
- Ehrsson HH, Spence C, Passingham RE. That's my hand! Activity in premotor cortex reflects feeling of ownership of a limb. *Science* 2004; 305: 875–7.

- Ejaz N, Hamada M, Diedrichsen JOR. Hand use predicts the structure of representations in sensorimotor cortex. *Nat Neurosci* 2015; 18: 1034–40.
- Flor H, Denke C, Schaefer M, Grusser S. Effect of sensory discrimination training on cortical reorganisation and phantom limb pain. *Lancet* 2001; 357: 1763–4.
- Flor H, Elbert T, Knecht S, Wienbruch C, Pantev C, Birbaumer N, et al. Phantom-limb pain as a perceptual correlate of cortical reorganization following arm amputation. *Science* 1995; 375: 482–4.
- Foell J, Bekrater-Bodmann R, Diers M, Flor H. Mirror therapy for phantom limb pain: brain changes and the role of body representation. *Eur J Pain* 2014; 18: 729–39.
- Fox MD, Raichle ME. Spontaneous fluctuations in brain activity observed with functional magnetic resonance imaging. *Nat Rev Neurosci* 2007; 8: 700–11.
- Fox MD, Snyder AZ, Zacks JM, Raichle ME. Coherent spontaneous activity accounts for trial-to-trial variability in human evoked brain responses. *Nat Neurosci* 2006; 9: 23–5.
- Gao Q, Duan X, Chen H. Evaluation of effective connectivity of motor areas during motor imagery and execution using conditional Granger causality. *Neuroimage* 2011; 54: 1280–8.
- Genovese CR, Lazar NA, Nichols T. Thresholding of statistical maps in functional neuroimaging using the false discovery rate. *Neuroimage* 2002; 15: 870–8.
- Gentile G, Bjornsdotter M, Petkova VI, Abdulkarim Z, Ehrsson HH. Patterns of neural activity in the human ventral premotor cortex reflect a whole-body multisensory percept. *Neuroimage* 2015; 109: 328–40.
- Gerloff C, Bushara K, Sailer A, Wassermann EM, Chen R, Matsuoka T, et al. Multimodal imaging of brain reorganization in motor areas of the contralesional hemisphere of well recovered patients after capsular stroke. *Brain* 2006; 129(Pt 3): 791–808.
- Giummarra MJ, Moseley GL. Phantom limb pain and bodily awareness: current concepts and future directions. *Curr Opin Anaesthesiol* 2011; 24: 524–31.
- Grivaz P, Blanke O, Serino A. Common and distinct brain regions processing multisensory bodily signals for peripersonal space and body ownership. *Neuroimage* 2017; 147: 602–18.
- Graziano MS, Borvinick MM. How the brain represents the body: insights from neurophysiology and psychology. In: *Common mechanisms in perception and action: attention and performance XIX*. Oxford: Oxford University Press; 2002, p. 136–57.
- Graziano MS, Cooke DF. Parieto-frontal interactions, personal space, and defensive behavior. *Neuropsychologia* 2006; 44: 845–59.
- Green DM, Swets JA. Signal detection theory and psychophysics. *Society* 1966; 1: 521.
- Haggard P, Christakou A, Serino A. Viewing the body modulates tactile receptive fields. *Exp Brain Res* 2007; 180: 187–93.
- Haggard P, Taylor-Clarke M, Kennett S. Tactile perception, cortical representation and the bodily self. *Curr Biol* 2003; 13: R170–3.
- Hebert JS, Olson JL, Morhart MJ, Dawson MR, Marasco PD, Kuiken TA, et al. Novel targeted sensory reinnervation technique to restore functional hand sensation after transhumeral amputation. *IEEE Trans Neural Syst Rehabil Eng* 2014; 22: 765–73.
- Helmich RC, Derikx LC, Bakker M, Scheeringa R, Bloem BR, Toni I. Spatial remapping of cortico-striatal connectivity in Parkinson's disease. *Cereb Cortex* 2010; 20: 1175–86.
- Hijjawi JB, Kuiken TA, Lipschutz RD, Miller LA, Stubblefield KA, Dumanian GA. Improved myoelectric prosthesis control accomplished using multiple nerve transfers. *Plast Reconstr Surg* 2006; 118: 1573–8.
- Kaas JH. Plasticity of sensory and motor maps in adult mammals. *Annu Rev Neurosci* 1991; 14: 137–67.
- Kaas JH, Merzenich MM, Killackey HP. The reorganization of somatosensory cortex following peripheral nerve damage in adult and developing mammals. *Annu Rev Neurosci* 1983; 6: 325–56.
- Kennett S, Taylor-Clarke M, Haggard P. Noninformative vision improves the spatial resolution of touch in humans. *Curr Biol* 2001; 11: 1188–91.
- Konen CS, Haggard P. Multisensory parietal cortex contributes to visual enhancement of touch in humans: a single-pulse TMS study. *Cereb Cortex* 2014; 24: 501–7.
- Krantz DH. Threshold theories of signal detection. *Psychol Rev* 1969; 76: 308–24.
- Kuiken TA, Dumanian GA, Lipschutz RD, Miller LA, Stubblefield KA. The use of targeted muscle reinnervation for improved myoelectric prosthesis control in a bilateral shoulder disarticulation amputee. *Prosthet Orthot Int* 2004; 28: 245–53.
- Kuiken TA, Marasco PD, Lock BA, Harden RN, Dewald JP. Redirection of cutaneous sensation from the hand to the chest skin of human amputees with targeted reinnervation. *Proc Natl Acad Sci USA* 2007a; 104: 20061–6.
- Kuiken TA, Miller LA, Lipschutz RD, Lock BA, Stubblefield K, Marasco PD, et al. Targeted reinnervation for enhanced prosthetic arm function in a woman with a proximal amputation: a case study. *Lancet* 2007b; 369: 371–80.
- Lotze M, Erb M, Flor H, Huelsmann E, Godde B, Grodd W. fMRI evaluation of somatotopic representation in human primary motor cortex. *Neuroimage* 2000; 11: 473–81.
- Lotze M, Flor H, Grodd W, Larbig W, Birbaumer N. Phantom movements and pain. An fMRI study in upper limb amputees. *Brain* 2001; 124(Pt 11): 2268–77.
- Lotze M, Grodd W, Birbaumer N, Erb M, Huse E, Flor H. Does use of a myoelectric prosthesis prevent cortical reorganization and phantom limb pain? *Nat Neurosci* 1999; 2: 501–2.
- Lowe MJ, Mock BJ, Sorenson JA. Functional connectivity in single and multislice echoplanar imaging using resting-state fluctuations. *Neuroimage* 1998; 7: 119–32.
- Makin TR, Cramer AO, Scholz J, Hahamy A, Henderson Slater D, Tracey I, et al. Deprivation-related and use-dependent plasticity go hand in hand. *Elife* 2013a; 2: e01273.
- Makin TR, Filippini N, Duff EP, Henderson Slater D, Tracey I, Johansen-Berg H. Network-level reorganisation of functional connectivity following arm amputation. *Neuroimage* 2015a; 114: 217–25.
- Makin TR, Scholz J, Filippini N, Henderson Slater D, Tracey I, Johansen-Berg H. Phantom pain is associated with preserved structure and function in the former hand area. *Nat Commun* 2013b; 4: 1570.
- Makin TR, Scholz J, Henderson Slater D, Johansen-Berg H, Tracey I. Reassessing cortical reorganization in the primary sensorimotor cortex following arm amputation. *Brain* 2015b; 138(Pt 8): 2140–6.
- Mann HB, Whitney DR. On a test of whether one of two random variables is stochastically larger than the other. *Ann Math Stat* 1947; 18: 50–60.
- Marasco PD, Kim K, Colgate JE, Peshkin MA, Kuiken TA. Robotic touch shifts perception of embodiment to a prosthesis in targeted reinnervation amputees. *Brain* 2011; 134(Pt 3): 747–58.
- Marasco PD, Schultz AE, Kuiken TA. Sensory capacity of reinnervated skin after redirection of amputated upper limb nerves to the chest. *Brain* 2009; 132(Pt 6): 1441–8.
- Maravita A, Spence C, Driver J. Multisensory integration and the body schema: close to hand and within reach. *Curr Biol* 2003; 13: R531–9.
- Markov NT, Ercsey-Ravasz M, Lamy C, Ribeiro Gomes AR, Magrou L, Misery P, et al. The role of long-range connections on the specificity of the macaque interareal cortical network. *Proc Natl Acad Sci USA* 2013; 110: 5187–92.
- Mars RB, Jbabdi S, Sallet J, O'Reilly JX, Croxson PL, Olivier E, et al. Diffusion-weighted imaging tractography-based parcellation of the human parietal cortex and comparison with human and macaque resting-state functional connectivity. *J Neurosci* 2011; 31: 4087–100.
- Martuzzi R, van der Zwaag W, Dieguez S, Serino A, Gruetter R, Blanke O. Distinct contributions of Brodmann areas 1 and 2 to body ownership. *Soc Cogn Affect Neurosci* 2015; 10: 1449–59.

- Martuzzi R, van der Zwaag W, Farthouat J, Gruetter R, Blanke O. Human finger somatotopy in areas 3b, 1, and 2: a 7T fMRI study using a natural stimulus. *Hum Brain Mapp* 2014; 35: 213–26.
- Mercier C, Reilly KT, Vargas CD, Aballea A, Sirigu A. Mapping phantom movement representations in the motor cortex of amputees. *Brain* 2006; 129(Pt 8): 2202–10.
- Merzenich MM, Kaas JH, Wall JT, Sur M, Nelson RJ, Felleman DJ. Progression of change following median nerve section in the cortical representation of the hand in areas 3b and 1 in adult owl and squirrel monkeys. *Neuroscience* 1983; 10: 639–65.
- Meyer-Lindenberg A, Poline JB, Kohn PD, Holt JL, Egan MF, Weinberger DR, et al. Evidence for abnormal cortical functional connectivity during working memory in schizophrenia. *Am J Psychiatry* 2001; 158: 1809–17.
- Mostofsky SH, Powell SK, Simmonds DJ, Goldberg MC, Caffo B, Pekar JJ. Decreased connectivity and cerebellar activity in autism during motor task performance. *Brain* 2009; 132(Pt 9): 2413–25.
- O'Shaughnessy KD, Dumanian GA, Lipschutz RD, Miller LA, Stubblefield K, Kuiken TA. Targeted reinnervation to improve prosthesis control in transhumeral amputees. A report of three cases. *J Bone Joint Surg Am* 2008; 90: 393–400.
- Oldfield RC. The assessment and analysis of handedness: the Edinburgh inventory. *Neuropsychologia* 1971; 9: 97–113.
- Pons TP, Garraghty PE, Ommaya AK, Kaas JH, Taub E, Mishkin M. Massive cortical reorganization after sensory deafferentation in adult macaques. *Science* 1991; 252: 1857–60.
- Porro CA, Franciscato MP, Cettolo V, Diamond ME, Baraldi P, Zuiani C, et al. Primary motor and sensory cortex activation during motor performance and motor imagery: a functional magnetic resonance imaging study. *J Neurosci* 1996; 16: 7688.
- Ramachandran VS, Rogers-Ramachandran D, Cobb S. Touching the phantom limb. *Nature* 1995; 377: 489–90.
- Ramachandran VS, Altschuler EL. The use of visual feedback, in particular mirror visual feedback, in restoring brain function. *Brain* 2009; 132(Pt 7): 1693–710.
- Raspopovic S, Capogrosso M, Petrini FM, Bonizzato M, Rigosa J, et al. Restoring natural sensory feedback in real-time bidirectional hand prostheses. *Sci Transl Med* 2014; 6: 222ra219.
- Reilly KT, Mercier C, Schieber MH, Sirigu A. Persistent hand motor commands in the amputees' brain. *Brain* 2006; 129(Pt 8): 2211–23.
- Reilly KT, Sirigu A. The motor cortex and its role in phantom limb phenomena. *Neuroscientist* 2008; 14: 195–202.
- Rizzolatti G, Matelli M. Two different streams form the dorsal visual system: anatomy and functions. *Exp Brain Res* 2003; 153: 146–57.
- Ro T, Wallace R, Hagedorn J, Farne A, Pienkos E. Visual enhancing of tactile perception in the posterior parietal cortex. *J Cogn Neurosci* 2004; 16: 24–30.
- Rothgangel AS, Braun SM, Beurskens AJ, Seitz RJ, Wade DT. The clinical aspects of mirror therapy in rehabilitation: a systematic review of the literature. *Int J Rehab Res* 2011; 34: 1–13.
- Rushworth MFS, Behrens TEJ, Johansen-Berg H. Connection patterns distinguish 3 regions of human parietal cortex. *Cereb Cortex* 2006; 16: 1418–30.
- Salomon R, Darulova J, Narsude M, Van Der Zwaag W. Comparison of an 8-channel and a 32-channel coil for high-resolution fMRI at 7 T. *Brain Topogr* 2014; 27: 209–12.
- Sanchez-Panchuelo RM, Francis S, Bowtell R, Schluppeck D. Mapping human somatosensory cortex in individual subjects with 7T functional MRI. *J Neurophysiol* 2010; 103: 2544–56.
- Serino A, Farnè A, Rinaldesi ML, Haggard P, Ladavas E. Can vision of the body ameliorate impaired somatosensory function? *Neuropsychologia* 2007; 45: 1101–7.
- Serino A, Haggard P. Touch and the body. *Neurosci Biobehav Rev* 2010; 34: 224–36.
- Serino A, Padiglioni S, Haggard P, Ladavas E. Seeing the hand boosts feeling on the cheek. *Cortex* 2009; 45: 602–9.
- Siero JCW, Hermes D, Hoogduin H, Luijten PR, Ramsey NF, Petridou N. BOLD matches neuronal activity at the mm scale: a combined 7T fMRI and ECoG study in human sensorimotor cortex. *Neuroimage* 2014; 101: 177–84.
- Souza JM, Cheesborough JE, Ko JH, Cho MS, Kuiken TA, Dumanian GA. Targeted muscle reinnervation: a novel approach to postamputation neuroma pain. *Clin Orthop Relat Res* 2014; 472: 2984–90.
- Solodkin A, Hlustik P, Chen EE, Small SL. Fine modulation in network activation during motor execution and motor imagery. *Cereb Cortex* 2004; 14: 1246–55.
- Speck O, Stadler J, Zaitsev M. High resolution single-shot EPI at 7T. *MAGMA* 2008; 21: 73–86.
- Stringer EA, Chen LM, Friedman RM, Gatenby C, Gore JC. Differentiation of somatosensory cortices by high-resolution fMRI at 7T. *Neuroimage* 2011; 54: 1012–20.
- Taylor-Clarke M, Kennett S, Haggard P. Vision modulates somatosensory cortical processing. *Curr Biol* 2002; 12: 233–6.
- Tomassini V, Jbabdi S, Klein JC, Behrens TEJ, Pozzilli C, Matthews PM, et al. Diffusion-weighted imaging tractography-based parcellation of the human lateral premotor cortex identifies dorsal and ventral subregions with anatomical and functional specializations. *J Neurosci* 2007; 27: 10259–69.
- Tsakiris M. My body in the brain: a neurocognitive model of body-ownership. *Neuropsychologia* 2010; 48: 703–12.
- Uddin LQ, Supekar K, Amin H, Rykhlevskaia E, Nguyen DA, Greicius MD, et al. Dissociable connectivity within human angular gyrus and intraparietal sulcus: evidence from functional and structural connectivity. *Cereb Cortex* 2010; 20: 2636–46.
- van den Heiligenberg F, Macdonald S, Duff E, Henderson Slater D, Johansen-Berg H, Culham J, et al. Activity in hand- and tool-selective regions for prosthetic limbs in amputees is associated with prosthesis usage in everyday life. *J Vis* 2015; 15: 983.
- van der Zwaag W, Gruetter R, Martuzzi R. Stroking or Buzzing? A comparison of somatosensory touch stimuli using 7 Tesla fMRI. *PloS One* 2015; 10: e0134610.
- Wang L, Yu C, Chen H, Qin W, He Y, Fan F, et al. Dynamic functional reorganization of the motor execution network after stroke. *Brain* 2010; 133(Pt 4): 1224–38.
- Weinstein S. Intensive and extensive aspects of tactile sensitivity as a function of body part, sex, and laterality. In Kenshalo DR, editor, *The skin sense*. Springfield, IL: Thomas. 1968, p. 195–18.
- Xiong J, Parsons LM, Gao JH, Fox PT. Interregional connectivity to primary motor cortex revealed using MRI resting state images. *Hum Brain Mapp* 1999; 8: 151–6.
- Yang TT, Gallen CC, Schwartz B, Bloom FE, Ramachandran VS, Cobb S. Sensory maps in the human brain. *Nature* 1994; 368: 592–3.
- Yao J, Chen A, Kuiken T, Carmona C, Dewald J. Sensory cortical remapping following upper-limb amputation and subsequent targeted reinnervation: a case report. *Neuroimage Clin* 2015; 8: 329–36.
- Yeo BTT, Krienen FM, Sepulcre J, Sabuncu MR, Lashkari D, Hollinshead M, et al. The organization of the human cerebral cortex estimated by intrinsic functional connectivity. *Journal of Neurophysiology* 2011; 106: 1125–65.
- Zeharia N, Hertz U, Flash T, Amedi A. Negative blood oxygenation level dependent homunculus and somatotopic information in primary motor cortex and supplementary motor area. *Proc Natl Acad Sci USA* 2012; 109: 18565–70.
- Zhou P, Lowery MM, Englehart KB, Huang H, Li G, Hargrove L, et al. Decoding a new neural machine interface for control of artificial limbs. *J Neurophysiol* 2007; 98: 2974–82.