

CASE REPORT

URETERAL TRIPLICATION AND CONTRALATERAL DUPLICATION WITH VESICoureTERAL REFLUX

Sohrab Naushad Ali, Aymon Naushad Ali*, Niqad Ahmad**, Mian Naushad Ali

Shifa College of Medicine, Islamabad, *Khyber Medical College, **Department of Surgery Northwest General Hospital, Peshawar

Ureteral triPLICATION is a rare congenital anomaly of the urinary tract. Since the first description by Waryn in 1870, approximately 100 known cases have been reported in the literature, often accompanied by a variety of associated anomalies in contralateral kidney. This report presents a case of ureteral triPLICATION with contralateral duplication and vesicoureteral reflux (VUR) of the upper moiety on the triplicate side. The patient was a 10 year old male who presented with a history of recurrent urinary tract infections and right loin pain. ACT urogram was performed which showed a triplicate right ureter with gross hydroureter of the upper moiety. There was a duplex system present on the left side. The patient underwent right upper pole heminephroureterectomy.

Keywords: Hydronephrosis, vesicoureteric reflux, ureteral, duplication, triPLICATION

J Ayub Med Coll Abbottabad 2014;26(2):258-60

INTRODUCTION

Ureteral triPLICATION is a rare congenital anomaly which was first described by Waryn in 1870.¹ A review of the literature showed that there have been only about 100 reported cases of this condition. Ureter triPLICATION is more common in females.² The following case report discusses a patient with ureteral triPLICATION and contralateral duplication in a 10 year old male. In addition, there was an upper moiety uretero-hydronephrosis.

CASE REPORT

A 10 year old male presented to our outpatient department with six year history of recurrent urinary tract infections and right sided loin pain. He had been previously treated in peripheral hospital for his complaints but the diagnosis had been missed at the time. On physical examination, the child appeared frail and was afebrile. A systemic examination was performed with no significant findings.

The patient was sent for urinalysis and a complete blood count which were essentially normal. An ultrasound was performed in which a dilated upper moiety and gross hydro-ureter was detected on the right. CT urography showed a triPLICATION of the ureter on the right and duplication on the left.

This was accompanied by a gross hydro-ureter of one of the triplicate ureters leading to an upper pole moiety (Figure-1). The aforementioned ureter appeared to be opening separately in the bladder on delayed films. A MAG-3 isotope scan showed normal excreting kidneys with normal GFR and no obstruction on either side. MCUG on a delayed MAG-3 scan showed a faint reflux probably due to a dilution because of a dilated Ureter of the upper moiety. (Figure-2.)

A cystoscopy was performed which showed two ureteral orifices on both sides. On right side both ureteric orifices were catheterized (Figure-3.) and retrograde pyelography showed two normal ureters and third ureter which was grossly dilated not identified in previous investigations.

The bladder was explored for an ectopic opening but could not be found. It was concluded that this case was likely to be a Smith Type-2 TriPLICATION. Upon further exploration it was discovered that the ureter did not fuse with another ureter up to the bladder level. A more distal intramural fusion could not be ruled out so a Type-1 triPLICATION could not be conclusively ruled out.

Guide wires were passed in both visible orifices, and right renal exploration through the flank revealed three separate ureters leading up to the bladder. (Figure-4). An upper pole heminephroureterectomy was performed with no complications (Figure-5). The patient had a complete recovery.

DISCUSSION

Ureteral development occurs in the 4th week of gestation. The Ureteric buds arise from the mesonephric (Wolffian) duct and extend to invade nephrogenic blastema to form the renal pelvis and calyces. In a duplication or triPLICATION of the ureters, it is suggested that three separate ureteric buds arise from the mesonephric duct producing a duplex or triplex ureter.

Complete triPLICATION of the ureter is the rarest congenital anomaly of the urinary tract which was first described by Waryn in 1870, and subsequently first reported in the literature by Lau and Henline in 1931.³ In 1946, Smith presented a simple classification of Triplicate ureter, which is still in use today (Figure-6).⁴

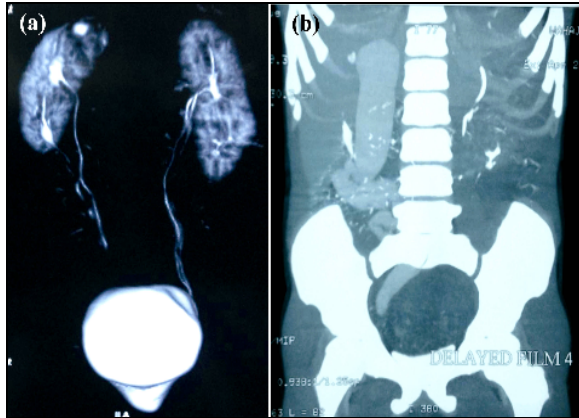


Figure-1(a):– CT Urogram. Early film showed bilateral duplex kidneys and right side triplex ureter not opacified. **(b):** CT-urogram (Delayed Film) outlined grossly dilated ureter of triplex right upper moiety.

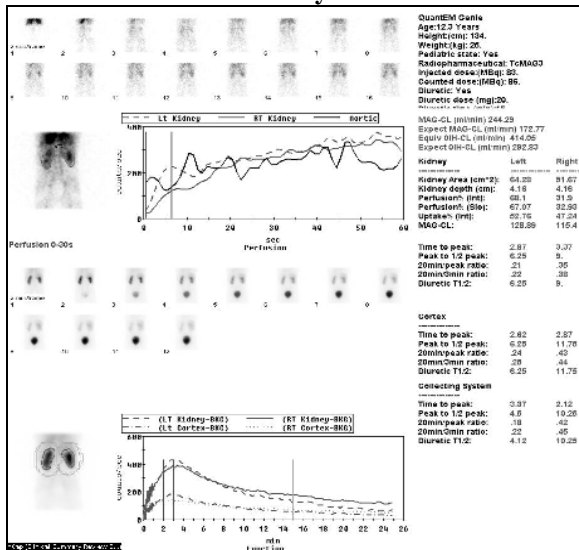


Figure-2: Mag-3 Scan

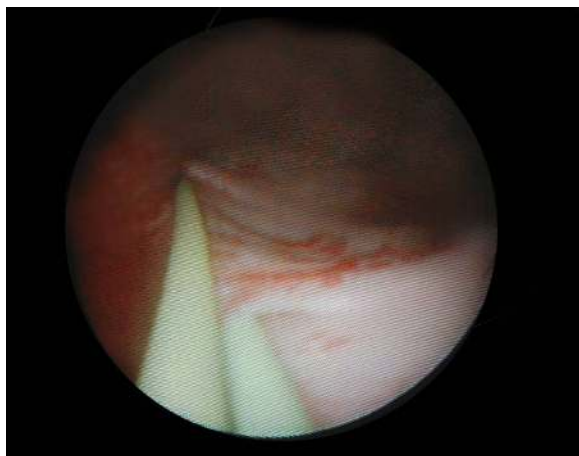

Figure-3: Cystoscopy Cystoscopy only showed two ureteric openings. 3rd opening could not be localized, probably in ectopic location.

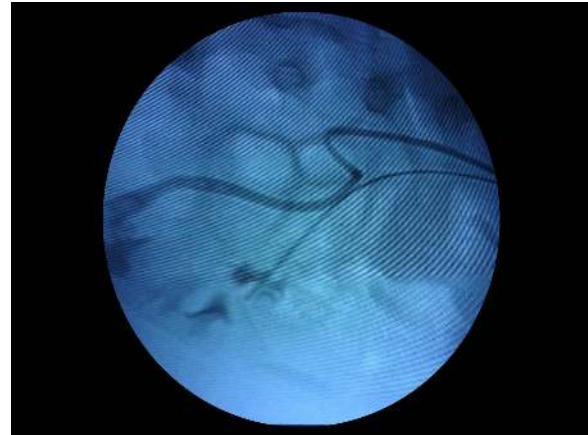

Figure-4: Retrograde pyelography through the identifiable openings opacified the lower and middle moieties, confirming that upper pole ureter is not connected with other two and probably in some remote ectopic location

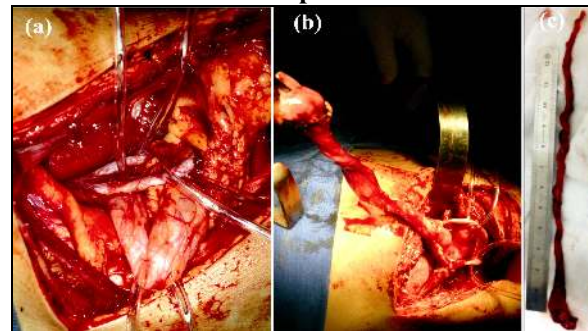
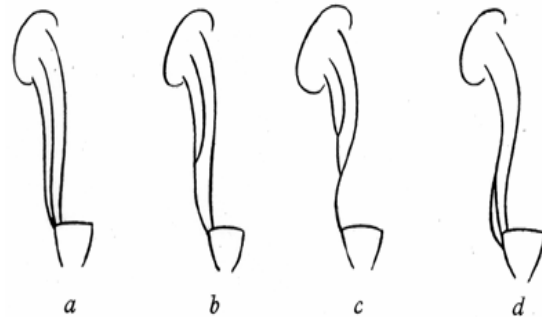


Figure-5 (a): On exploration three separate ureters identifiable. Guide wires palpable in normal looking ureters. **(b):** Grossly dilated ureter followed to upper pole and partial Nephroureterectomy accomplished.



Type	Smith Classification
a.	Triple ureters, (Complete triplication) Three separate ureters and three separate ureteral orifices in bladder, urethra or ectopic location. (35%)
b.	Incomplete triplication Three ureters arise from the kidney. Two join on the way to the bladder and two orifices present in the bladder (21%)
c.	Trifid ureter. All three ureters unite and drain through a single orifice (31%)
d.	Two ureters from the kidney. One divides into two to have three draining orifices (9%)

Figure-6: Smith Classification

Triplication of ureter has been reported with a variety of associated anomalies. Haluk Soylemez⁵ reported a case with vesicoureteral reflux in a contralateral duplex system. H. Ander reported a case of triplex ureter in solitary kidney.⁶ Mills reported a rather unique case with ureter triplication with a blind ending bifid ureter.⁷ This form of triplication is beyond the scope of the Smith classification. In some exceptional forms of presentation in cross ectopia⁸, Horseshoe kidneys⁹ and bilateral triplicity of ureters.¹⁰ Very few cases of ureteral quadruplication have been reported.^{11,12}

Clinical signs of triplication are non-specific, and duplication and triplication are often incidental findings on investigation. They consist of abdominal or back pain, hematuria, fever and urine storage and voiding symptoms.¹³ Triplication can occasionally be associated with urinary tract calculi, infection, obstruction and recurrent acute epididymitis.⁵

Diagnostic tools include ultrasonography, intravenous pyelography, CT urography, retrograde pyelography, MRU and cystoscopy. A large battery of tests may be needed to diagnose and classify the disease accurately.¹³

REFERENCES:

1. Mubarak MY, Zainun AR, Rohaya M. Ureteral triplication with

- contralateral partial duplex system. *Med J Malaysia* 2009;64(3):236–7.
2. Sánchez-de-Badajoz E, Ramos J, Burgos R. Ureteral Triplication with contralateral ureter duplication. *Urol Int* 1992;48:217–8.
3. Splanger EB. Complete triplication of the ureter. *Radiology* 1963;80:795–7.
4. Smith I. Triplicate ureter. *Br J Surg* 1946;34:182–5
5. Soyklemmez H, Koplay M, Altunoduk B, Oguz F. Ureteral triplication and contralateral duplication with vesicoureteral reflux. *Balkan Med J* 2011;28:469–70.
6. Ander H, Ziyilan O, Cayan S, Kadioğlu TC, Beşişik A - Ureteral triplication (Type I) associated with vesicoureteral reflux in solitary kidney. *Int Urol Nephrol* 1997;29:537–40
7. I.W. Mills, G. M. Oades, M. D. Dinn. Ureteric triplication with a blind ending bifid ureter – *BJU International* 2000;86(3):402.
8. Golomb J, Ehrlich RM. Bilateral ureteral triplication with crossed fused ectopic kidneys associated with the VACTREL Syndrome. *J Urol* 1989;141:1398–99.
9. Pode D, Shapiro A, Lebensart P. Unilateral triplication of the collecting system in a horseshoe kidney. *J Urol* 1983;130:533–4.
10. Shoda R, Ejiri S, Fujita T, Wada N. A case of bilateral ureteral triplication. *Hinyokika Kyo* 1985;31:475–81.
11. Klinge L, Kobiak R, Slongo T. Quadruplication of ureter in combination with a large ureteral cyst. *Pediatr Surg Int* 2001;17(7):566–8.
12. Koszutski T, Kudela G, Mikosinski M, Utrata W. Quadruplication of dystopic kidney in combination with ureteral cyst. *J Pediatr Surg* 2008;43(12):e 13–5.
13. Villanueva Peña A, De Diego Rodríguez E. Ureteral triplication, an unusual isolated presentation. *Actas Urol Esp* 2004;28(10):766–70.

Address for Correspondence:

Dr. Aymon Naushad Ali, House 69, Street 6, Sector G-2, Phase 2, Hayatabad, Peshawar, KPK, Pakistan.

Cell: +92-300-8596269

Email: aymon.n@gmail.com