

## CASE REPORT

# URETERIC ENDOMETRIOSIS: A 39 YEARS OLD LADY PRESENTED WITH CYCLICAL LOWER ABDOMINAL PAIN

HASAN MN<sup>1</sup>, AKTER M<sup>2</sup>, ISLAM MN<sup>3</sup>, CHOWDHURY MN<sup>4</sup>, ANOWER ASMT<sup>5</sup>, AHMED PT<sup>6</sup>

*J Dhaka Med Coll. 2018; 27(1) : 98-101*

### Introduction:

Endometriosis of Ureter is an uncommon presentation of a common diseases. It is divided into two groups: extrinsic & intrinsic. If the endometrial glands and stroma are present in the lamina propria or the tunica muscularis of ureter, the lesion is designated as intrinsic variety. When the endometrial glands and stroma are present in the adventitia and surrounding connective tissue and do not invade the tunica muscularis of ureter the lesion is classified as extrinsic variety.

Randall reported the first case of ureteral endometriosis with an intrinsic lesion that protrude into the lumen of the ureter.<sup>1</sup> Ratliff and Crenshaw published an excellent review of ureteric endometriosis and they made the important observation that the point of obstruction was always in the lower third of the ureter.<sup>2</sup> Simon and associates reported the only case of bilateral ureteral obstruction secondary to endometriosis.<sup>3</sup> Little attention has been paid, so far by the renal literature to ureteral endometriosis, a silent disorder that can eventually lead to renal failure. The true incidence of renal failure caused by endometriosis is completely unknown. The diagnosis is often difficult because of its clinically silent presentation or association with non specific symptoms. Only a high index of suspicion & radiological support is necessary for early diagnosis. Renal imaging is often sufficient to detect extrinsic endometriosis but

ureteroscopy or laparoscopy is invariably required to detect intrinsic endometriosis

Endometriosis is an estrogen dependent chronic inflammatory condition affecting 6% to 10% of reproductive aged women.<sup>4-5</sup> Although a relatively common gynecologic condition, localization to areas distinct from the peritoneum, ovary and recto-vaginal septum occurs in up to 12% of women with endometriosis.<sup>[6]</sup> Pelvic endometriosis can infrequently involve the urinary tract systems in approximately 1% of cases, which is a prevalence of 3.5 million women world-wide.<sup>7</sup>

The bladder is the most commonly involved site and the urethrae the least. Of these localization of diseases, ureteral endometriosis account for approximately 10% of genitourinary involvement

In endometriosis ureteral involvement is often limited to one ureter, commonly the left and can potentially lead to urinary obstruction, ureterohydronephrosis, and loss of renal function. These are estimates that 30% of women with Ureteral endometriosis will have 25-50% loss of nephrons at the time of diagnosis and an unknown number will then have loss of the kidney.<sup>8</sup> This final insult of complete loss of renal function is exceedingly rare.

### Case Reports:

A 39 Years old school teacher suffering from primary infertility presented in October 2017 in DMCH for right sided lower abdominal pain which was colicky in nature, intermittent,

1. Dr. Md. Naheed Hasan: Resident-phase B (Nephrology)
2. Dr. Mithila Akter :Resident -phase B (Nephrology)
3. Dr. Md Nazrul Islam: Associate Professor (Nephrology), Dhaka Medical College.
4. Dr. Md Nizamuddin Chowdhury: Professor (Nephrology), Dhaka Medical College.
5. Dr. Tanim Anowar: Registrar (Nephrology), Dhaka Medical College
6. Dr. Parvez Iftekhar Ahmed: Associate Professor (Nephrology), Dhaka Medical College.

**Correspondence:** Dr. Md. Naheed Hasan: Resident-phase B (Nephrology)

**Received:** 21 July 2017

**Revision:** 01 September 2017

**Accepted:** 15 September 2017

**DOI:** <http://dx.doi.org/10.3329/jdmc.v27i1.38955>

radiates to right loin and downwards with no aggravating and relieving factors. There was no history of fever, weight loss, dysuria, hematuria, oliguria and alternation of bowel habit.

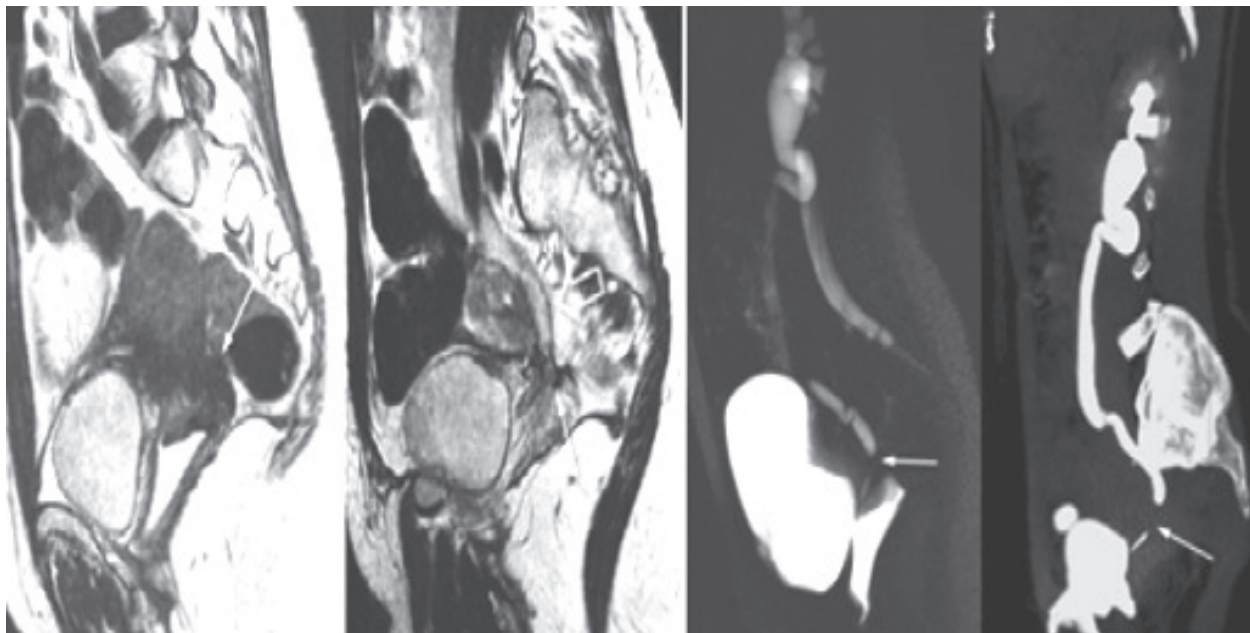
The pain was cyclical from the very beginning of her menarche which was initially mild, improved after completion of menstruation and taking NSAID. This pain was gradually increasing in duration and severity. Patient remained asymptomatic after cessation of menstruation and taking hormonal preparation like OCP and nor-ethisterone. But this time patient experienced pain persisting even after menstruation and taking analgesics.

After admission, she was evaluated thoroughly. Her general and systemic examination revealed no abnormality except moderate tenderness in her right lower abdomen.

In 2014, she was diagnosed as a case of endometriosis on the basis of clinical presentation and investigations like imaging and diagnostic laparoscopy. In diagnostic laparoscopy the panoramic view of pelvis was not seen due to severe adhesion. Dye test was negative. Post operative diagnosis was densely obliterated stage IV endometriosis.

At this time she was counseled for IVF. Subsequently CT scan showed thick wall cystic lesions with septation in both adnexal region and multiple adhesions. In 2015, she was diagnosed as obstructive uropathy (Rt) and advised for further evaluation by ureterorenoscopy and D-J stenting. Split function is DTPA- renogram showed features of dilatation, obstruction and mild nephropathy in right Kidney. Her serum LH and FSH level was below normal. To exclude malignancy S. CA-19.9, CA-125, S. CEA was done and showed normal level.

She is married for 9 years and has no children. Her menstrual cycle is irregular for the last five years and menstrual flow is below average. She has no significant family history. During this prolonged period of illness she has been treated by different NSAIDs and hormonal preparations. Taking all these account under consideration, she was undergone total abdominal hysterectomy (TAH) with bilateral salpingoophorectomy. In a second operation ureteroneocystostomy was done. Now she is symptom free and on hormonal preparation.



*(CT-abdomen shows multiple adhesions in pelvic organs)*

## Discussion

Endometriosis is an important gynaecologic clinical disorder characterized by the ectopic presence and growth of functional endometrial tissue, glands and stroma outside the uterus.<sup>9</sup> The organs most commonly involved include the ovaries, the ureterosacral ligaments, the fallopian tube, the cervix, the cul-de-sac.<sup>10</sup>

Endometriosis can be classified in a various way. American society of Endometriosis established the accepted classification based on number, size, superficial or deep implantations of endometrial implants, plaques, endometriomas and or adhesions which is as follows: stage-1 (minimal points 1-5), stage II (mild points 6-15), stage III (moderate points 16-40), stage IV (severe points > 40).<sup>11</sup>

The endometriotic cells may originate from retrograde menstruation, blood and lymphatic dissemination, stem cells and metaplasia of coelomic epithelium.<sup>12</sup> The pathogenesis of endometriosis and more specifically of ureteric involvement has been widely investigated. The most common theory is that of retrograde menstruation which also explains the asymmetrical localization of ureteric endometriosis. The sigmoid colon contributes to the creation of an isolated microenvironment around the left adnexa. Macrophages, the first line of immune system cannot reach the endometrial cells coming from the left fallopian tube into the peritoneal environment. On the right side, the cecum cannot provide such protection because of its more cranial anatomical position.<sup>13</sup> The second theory is the embryonal one. According to this, endometriosis may develop primarily in the retroperitoneum from the embryonic remnants of Mullerian duct. A further spread of the diseases up to and around the ureter may be explained by the proliferation of smooth muscle surrounding the ureteric wall.<sup>14</sup>

Benign metastasis could also potentially provide a theory for some cases of endometriosis. In addition, other hormonal and molecular pathways play an important role in the pathophysiology of deep endometriotic lesion in ureters.

The insidious onset of endometriosis portends considerable morbidity and thus the diseases need a high index of suspicion. About 10% of women in the reproductive age have involvement of the genitourinary tract by endometriosis. Whereas diseases affecting the ureter is very infrequent accounting for < 0.3% of all types of endometriosis. Although the morbidity of ureteral lesion is relatively low, the diseases can cause severe silent loss of renal function. The peak incidence of ureteral endometriosis is around 30-40 years.<sup>[15]</sup> Our present case is a 39 years old female involving the lower third of ureter of right side. She has no renal involvement (S. Creatinine is normal) but DTPA - renogram shows features of dilatation with obstruction and mild nephropathy of right kidney.

Ureteral endometriosis is often asymmetrical, more commonly, involving the distal segment of the left ureter. But the case we reported, has involvement of right ureter and it is in the lower third.

Heqing Guo and associates undergo a research study taking 23 patients. He showed all cases of ureteral endometriosis involved distal third of ureter and occur in a single site. There is no bilateral involvement. Of 23 patients, 18 cases (75.3%) presented with extrinsic lesions where as 14.7% (5 patient) presented with intrinsic forms. The histologic reports of our case showed involvement of muscularis mucosa of ureteric wall that is intrinsic variety.

The onset of ureteric endometriosis is latent. Clinical sign and symptoms are often silent. The diseases always progressed to silent obstruction and loss of renal function. Therefore the diagnosis of Ureteric endometriosis is very difficult. Along with extrinsic pelvic endometriosis some patients presented with clinical symptoms of dysmenorrhea, dyspareunia, pelvic pain, infertility and repeated urinary tract infection. Our patient mainly presented with right lion pain, dyspareunia and infertility which is similar to the research reports.

The prospective diagnosis of our case was difficult initially as there is no definitive clue

for diagnosis both in history and clinical examination. A delay in diagnosis can lead to significant morbidity. Multiple diagnostic tests are applied in our case to confirm the diseases. Ultrasonography, laparoscopy, intravenous urography, CT-Scan, MRI and finally tissue biopsy was done to have a conclusion.

The general principle of treatment for ureteral endometriosis should be considered to relieve ureteral obstructions and to protect renal function. The therapeutic methods for endometriosis include medical and surgical therapy.<sup>16</sup> Surgical therapy is the paramount consideration for patients with hydronephrosis. Most scholars surge that ureterolysis is the first choice for treating patients with hydronephrosis.<sup>17</sup> Boseu and colleagues believe that Ureterolysis is an effective treatment option in a vast majority of cases that can be safely accomplished even in patient with moderate to severe hydro ureteronephrosis.<sup>18</sup> However, the management of ureteral endometriosis in cases of moderate to severe hydronephrosis is still contentious. Some researchers believe that ureterolysis is more suited to cases with mild hydronephrosis whereas patients with moderate or severe hydronephrosis should be treated by desection of the diseased ureter and subsequent ureteroneocystostomy which can prevent further renal damage.<sup>19</sup> Our patient underwent ureteroneocystostomy along with total abdominal hysterectomy (TAH). Tissue was sent separately for histological diagnosis. Tissue diagnosis proved the case as intrinsic variety of Ureteric endometriosis.

The operations were uneventful. Post operative follow up was maintained strictly up to discharge. Now patient is symptom free and remains on conservative hormonal therapy.

### Conclusion:

It is very much challenging to diagnose ureteric endometriosis due to its non-specific and atypical presentation. The diagnosis should be suspected when women of child bearing age appear with atypical urological and pelvic symptoms. Preoperative imaging is helpful for the planning of operative management. Surgery

depends on the type, extent and location of diseases, and a laparoscopic approach is preferred. Surgical management is effective in relieving symptoms and improving fertility. Ultimately a multidisciplinary approach from an experienced Gynecologist, Urologist and Nephrologists are mandatory for the management of this type of cases.

### References:

1. Randall A. Endometrioma of the ureter: Journal Urology; 1941. 419-422.
2. Ratliff RK, Crenshaw WB. Ureteral obstruction from endometriosis: Surg Gynec & Obst; 1955. 100:414-418.
3. Simon HB, Zimet RR, Schneider E, Morgenstern LL. Bilateral ureteral obstruction due to endometriosis: JAMA; 1963. 183:487-489, 4. Giudice LC. Clinical practice Endometriosis: N Engl J Med; 2010. 362:2389-2398.
5. Bulun SE. Endometriosis: N Engl J Med; 2009. 360:268-279.
6. Veeraswamy A, Lewis M, Mann A, Kotikela S, Hajhosseini B, Nezhat C. Extragenital endometriosis: Clin Obstet Gynecol; 2010. 53: 449-466.
7. Abeshouse BS, Abeshouse G. Endometriosis of the urinary tract, a review of the literature and a report of four cases of visceral endometriosis: J Int Coll Surg; 1960. 34:43-63.
8. Horn LC, Do Minh M, Stolzenburg JU. Intrinsic form of ureteral endometriosis causing ureteral obstruction and partial loss of kidney function: Urol Int; 2004. 73:181-184.
9. Baldi A, Campioni M, Signorile PG. Endometriosis: Pathogenesis, diagnosis, therapy and association with cancer (review): Oncol Rep; 2008. 19:843-6.
10. Viganò P, Parazzini F, Somigliana E, Vercellini P. Endometriosis: Epidemiology and aetiological factors: Best Pract Res Clin Obstet Gynaecol; 2004. 18:177-200.
11. Tosti C, Pinzauti S, Santulli P, Chapron C, Petraglia F. Pathogenetic mechanisms of deep infiltrating endometriosis: Reprod Sci; 2015. 22:1053-9.
12. Takagi H, Matsunami K, Ichigo A. Novel medical management of primary bladder endometriosis with dienogest: A case report: Clin Exp Obstet Gynecol; 2011. 38:184-5.
13. Burney RO, Giudice LC. Pathogenesis and pathophysiology of endometriosis. Fertil Steril 2012; 98:511-9.
14. Nezhat C, Nezhat F, Nezhat C, editors. video-Assisted and Robotic-Assisted Laparoscopy and Hysterectomy