

Ureteroscopy Under Spinal Versus General Anaesthesia: Morbidity and Stone Clearance

Aatif Hassan Shaikh¹, Salman El Khalid¹ and Syed Zafar Zaidi²

ABSTRACT

Objective: To compare morbidity and stone clearance by ureteroscopy carried out under spinal anaesthesia with that carried out under general anaesthesia.

Study Design: Quasi-experimental study.

Place and Duration of Study: The study was conducted at the Kidney Centre, Postgraduate Training Institute, Karachi, from September 2005 to December 2006.

Patients and Methods: A total number of 60 patients were enrolled for the study. All patients underwent ureteroscopic procedure for a calculus disease, using a semi-rigid ureteroscope of 10 Fr. These patients were divided in 2 groups of 30 patients, receiving general or spinal anaesthesia. Operative time, stone clearance, hospital stay, intra- and postoperative complications and visual analogue score for pain were noted in each case.

Results: There were 30 patients each in both groups, with 73% males and 27% females in group A (general anaesthesia) and 93% males and 7% females in group B (spinal anaesthesia). Mean age of the patients were 33.9 and 36.9 years in groups A and B respectively. The average stone size was 0.79 cm in group A and 1.14 cm in group B ($p=0.001$). Duration of surgery was 41.4 ± 1.29 minutes in group A and 30.5 ± 2.13 minutes in group B ($p=0.033$). Mean hospital stay was 21.6 and 18.1 hours in group A and B respectively ($p=0.073$). Mean visual analogue score for pain in group A was 3.1 and group B was 1.8.

Conclusion: Ureteroscopy under spinal anaesthesia resulted in decreased length of operative time and shortened hospital stay in this series and did not carry any additional risk of major complications.

Key words: Ureteroscopy (URS). Spinal anaesthesia. General anaesthesia. Ureteric stone.

INTRODUCTION

Since its introduction in 1980,¹ ureteroscopy is a routine urological procedure. Use of advanced technology and modern equipment has not only increased the success rate of the procedure but also widened its indications.² Endoscopic lithotripsy, treatment of urothelial malignancies, incising strictures, and repairing ureteropelvic junction obstructions are all current treatments facilitated by contemporary ureteroscopic techniques. The procedure has been accepted as the treatment of choice for the lower ureteric stones with a success rate of 80-100%.³⁻⁵ It is infrequently used for most upper and mid ureteric stones and where available, ESWL (extra corporeal shock wave lithotripsy) is the preferred method.⁶ With improved instrumentation and evolution of surgical technique, the complication rate from ureteropyeloscopy has actually also

decreased markedly. The present complication rates are low as 0-6%⁷ with high success rate of stone clearance.⁸⁻¹¹

Initially, the procedure was performed under general anaesthesia, but the use of spinal anaesthesia⁷ or intravenous sedation is also reported to be well-tolerated by the patients.¹²⁻¹⁷

The possible complications¹⁸ of the procedure can be ureteral perforations, avulsions or strictures, bleeding, septic episodes, urinomas, pain, urinary retention and residual stone fragments. Untreated urinary tract infection, endoscopy without appropriate antibiotic coverage and uncorrected bleeding diathesis are relative contraindications for diagnostic and therapeutic ureteroscopy.

The aim of this study was to compare the morbidity, stone clearance and associated factors in ureteroscopy carried out under spinal anaesthesia with that carried out under general anaesthesia.

PATIENTS AND METHODS

It was a quasi-experimental study of 60 patients who underwent ureteroscopic procedure at the Kidney Centre, Postgraduate Institute, Karachi, from September 2005 to December 2006 for urinary calculus disease.

¹ Department of Urology, The Kidney Centre Postgraduate Institute, Karachi.

² Department of Urology, The Indus Hospital, Karachi.

Correspondence: Dr. Aatif Hassan Shaikh,
Bungalow No. 10, Mustafa Avenue, F-4, Off Khayaban-e-Jami,
Block-9, Clifton, Karachi.
E-mail: aatifshaikh@hotmail.com

Received March 09, 2007; accepted: February 17, 2008.

Data of the patients was recorded through convenience sampling. Every patient was informed about the study and was given the choice to opt for the type of anaesthesia to be administered. Almost all the patients left the decision best to be taken by the surgeon and the anaesthetist.

All adult patients (at or above 15 years of age) with lower ureteric stone i.e. stone below sacroiliac joint on X-ray were included in the study. Patients with upper ureteric stones, urinary tract infection, bleeding, ASA (American Society of Anaesthesiology) category III and IV,¹⁹ previous open surgery and any co-morbidity due to which spinal or general anaesthesia could not be given, were excluded. Each extracted stone was sent for chemical analysis to ascertain its type.

Thirty patients were given spinal anaesthesia while the remaining 30 had surgery done under general anaesthesia. The type of anaesthesia was selected according to patient's choice and anaesthetist's preference.

Most of the patients were admitted in the morning of the surgery day and kept overnight after the procedure. The total duration of stay in the hospital was recorded in each case. Prophylactic antibiotic were given as a routine to all 60 patients.

All patients underwent rigid cystoscopy with placement of a guide wire into the renal collecting system under fluoroscopic guidance. Semi-rigid ureteroscope of 10 Fr was used in each case. Ureteral orifice was balloon dilated when the ureterscope did not pass easily into the ureteric orifice. Calculi were extracted with forceps or fragmented using a pneumatic lithoclast. A stent was placed postoperatively as per surgeon's discretion. Operative time, defined as the time elapsed from cystoscope placement to final removal of ureterscope, was noted in each case.

Patients were observed for any intra-operative complication. Stone clearance was assessed by means of X-ray KUB and/or excretory urography (for radiolucent stone) in every case. All the patients were evaluated for postoperative events like pain, fever, infection, haematoma formation and residual stone leading to obstruction. Visual analogue score for pain²⁰ was recorded in each case postoperatively. Blood culture and sensitivity was sent in case of suspected infection. An ultrasound abdomen was planned in case of abdominal swelling or otherwise symptomatic patients for the formation of haematoma.

Total stay in the hospital in hours was calculated in each case. It was defined as the time from admission to discharge.

Morbidity was defined as the general well-being of the patient following surgery, the total duration of hospital stay, complications related to the procedure (pain and

fever) and complications related to anaesthesia (vomiting and headache).

Stone clearance was defined as the absence of any residual stone after the procedure, confirmed by X-ray Kidney/Urinary Bladder (KUB) or Intravenous Urography (IVU), on first follow-up visit that is 7th postoperative day.

All the data was recorded and analyzed statistically on SPSS 10.0 to compare the results in terms of morbidity and stone clearance. Continuous response variables like length of hospital stay, stone size and duration of surgery were presented by means \pm SD. Student's t-test was applied to compare the means between the two groups.

RESULTS

Sixty patients were selected for general or spinal anaesthesia randomly after taking the informed consent. The indication for surgery was urinary calculus disease in all cases. Each group comprised of 30 patients who were then compared for the success of procedure, operative time, length of hospital stay and complications.

In group A (general anaesthesia), there were 22 (73.3%) males while in group B (spinal anaesthesia), there were 28 (93.3%) males. There were 8 (26.6%) female patients in group A and 2 (6.6%) female patients in group B (Figure 1). The mean age was 33.9 years (15-71 years) in group A while it was 36.9 years (22-72 years) in the other group. In group A, the mean stone size was 0.79 ± 0.21 cm with 1.5 cm being the largest and 0.5 cm the smallest stone. In group B, the mean stone size was 1.14 ± 0.41 cm ($p=0.001$). The mean operative time for the procedure was 41.4 ± 1.29 minutes in group A and for group B it was 30.5 ± 2.13 minutes ($p=0.033$). The mean hospital stay was 21.6 ± 7.7 hours (ranging from 8 to 48 hours) in group A. In group B, it was 18.1 ± 6.8 hours (ranging from 6 to 24 hours, $p=0.073$). Stone removal was successful in 100% patients.

In group A, postoperatively, all 30 patients complained

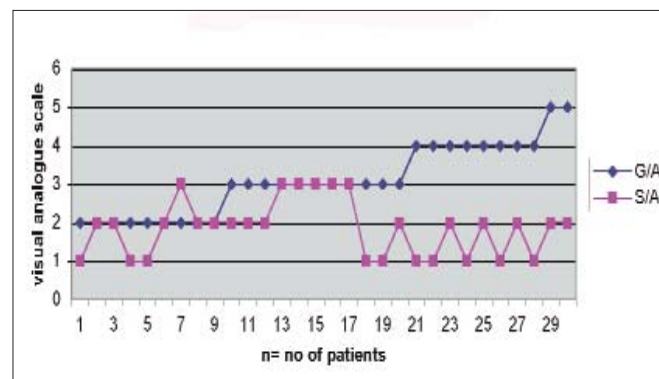


Figure 1: Visual analogue score.

of pain with mean visual analogue score of 3.1 ± 0.922 (ranging from 2 to 5) with '0' as no pain and '10' as maximum pain ever felt (Figure 1). All patients required oral and/or intravenous analgesia. Four (13.3%) patients developed pyrexia with a mean temperature of 38.6°C (ranging from 38 to 40°C). One (3.3%) patient developed urinary tract infection and was treated with antibiotics according to culture/sensitivity. No patient had haematoma or obstruction following the procedure.

In group B, postoperatively all patients complained of pain with mean visual analogue score of 1.8 ± 0.73 (ranging from 1 to 3). Except for 2 (6.6%) patients who developed fever, there was no other complication in any case.

DISCUSSION

Ureteroscopy is a safe and simple routine procedure performed by urologists. The most common indication is to treat urinary tract calculi, particularly those that are either unsuitable for extracorporeal shock wave lithotripsy or are refractory to that form of treatment. Other common indications include evaluation of an abnormal lesion noted on findings from less invasive imaging tools e.g. IVU, MRI, CT scan or localizing the source of positive urine culture or cytology results.²¹⁻²² The procedure can be used for a variety of minimally invasive therapies such as upper and lower urinary tract stones, obstruction at pelvi-uretric junction, urethral strictures and various local malignancies.²³

Major intra-operative problems include excessive trauma to tissues leading to large wall perforations, avulsions, or foreign body (e.g. stone) migration into the ureteral wall. The rate of these complications has decreased markedly and currently occurs in approximately 1% of all ureteroscopic procedures. With the advancement in techniques and hospital facilities, the procedure can now be performed as a day care surgical procedure with 78-95% patients being sent home the same day.¹⁸

Traditionally, the procedure is performed under general anaesthesia with muscle paralysis to avoid the potential ureteral injuries, resulting from sudden and unexpected patient movements.⁷ Despite this fact, spinal and epidural anaesthesia¹² has also been proved to be equally safe, as seen in many independent trials.^{1-3,5-6}

Some researchers successfully used epidural or local anaesthesia in combination with intravenous sedation^{3,6,24} while the use of intravenous sedation alone has also shown promising results in few reported studies⁵⁻⁶ in which flexible ureteroscope was used. The outcome of a ureteroscopic procedure is based on the underlying disorder and whether a diagnostic or therapeutic endoscopy was performed. In diagnostic ureteroscopy finding, the source of bleeding or defining

the nature of a filling defect most frequently is the end point.

Therapeutic ureteroscopy for the treatment of upper urinary tract calculi should resolve ureteral obstruction and decrease the stone burden. Endoscopic treatment of stricture disease also should improve drainage. Thus, ureteroscopy is a surgical platform from which a variety of disease processes can be treated, each with their own specific postoperative expectations and outcomes.

The mean stone size was 0.79 cm in group A as compared to 1.14 cm in group B patients. Despite of larger stone size in group B, there were no complications such as ureteral avulsion or perforation. The stones were successfully removed in all cases.

The mean operative time in group B was 30.5 minutes, which is significantly lower as compared to 41.4 in group A. With prolonged procedures, the risk of traumatic injuries can be increased due to sudden, unintentional movements of the patient. Therefore, it is safer to use general anaesthesia when a longer procedure is anticipated.⁷

In group B, the mean hospital stay was 18.1 hours as compared to 21.6 hours in group A. Although in both groups some patients could be sent home within 6-8 hours, in group A, one patient had to be retained in the hospital for 48 hours. The reason of this long stay was uncontrolled vomiting. Not a single patient operated under spinal anaesthesia stayed in the hospital for more than 24 hours. It seems that type of anaesthesia has no significant effect on the hospital stay ($p=0.073$). The results are comparable to other published studies.^{1-2,18}

Postoperatively all patients complained of pain with mean visual analogue score (VAS) of 3.1 and 1.8 in group A and B respectively (Figure 1). Pain is the commonest postoperative complication.^{2,7,11} All patients were given oral analgesia (Diclofenac sodium 50 mg twice a day for 3 days) in addition to a single shot of intravenous pethidine given immediately after the surgery. Twelve (40%) patients in group B and 25 (83.3%) in group A, required additional 1 or 2 doses of intravenous analgesia. A marked difference in VAS was observed in the two groups. The cause may be that the effect of spinal anaesthesia lasts for 5-6 hours and, therefore, postoperatively these patients experienced less pain as compared to the general anaesthesia group.

Four (13.3%) patients in group A and 2 (6.6%) in group B developed postoperative pyrexia and were treated with oral antipyretics. One patient operated under general anaesthesia developed UTI and was treated accordingly. In either group, there were no major complications such as urinary retention, haematoma formation, ureteric perforation or avulsion.

All patients undergoing spinal anaesthesia were comfortable with the procedure and satisfied with the outcome. Since, they were shown their stone being

fragmented on endovision camera monitor, it advanced their confidence in their stone management.

CONCLUSION

Spinal anaesthesia is a safe method for ureteroscopy of calculi in the lower ureter. As observed in this study, the operative time and hospital stay is shorter as compared to general anaesthesia and there is no additional risk of any major complication. There is marked patient satisfaction and minimal postoperative pain.

REFERENCES

- Taylor AL, Oakley N, Das S, Parys BT. Day-case ureteroscopy: an observational study. *BJU Int* 2002; **89**:181-5.
- Cheung MC, Lee F, Leung YL, Wong BB, Chu SM, Tam PC. Outpatient ureteroscopy: predictive factors for postoperative events. *Urology* 2001; **58**: 914-8.
- Wills TE, Burns JR. Ureteroscopy: an outpatient procedure? *J Urol* 1994; **151**: 1185-7.
- Cheung MC, Yip SK, Lee FC, Tam PC. Outpatient ureteroscopic lithotripsy: selective internal stenting and factors enhancing success. *J Endourol* 2000; **14**: 559-64.
- Schow DA, Jackson TL, Samson JM, Hightower SA, Johnson DL. Use of intravenous alfentanil-midazolam anaesthesia for sedation during brief endourologic procedures. *J Endourol* 1994; **8**: 33-6.
- Rittenberg MH, Ellis DJ, Bagley DH. Ureteroscopy under local anaesthesia. *Urology* 1987; **30**: 475-8.
- Harmon WJ, Sershon PD, Blute ML, Patterson DE, Sequra JW. Ureteroscopy: current practice and long-term complications. *J Urol* 1997; **157**: 28-32.
- Geavlete P, Multescu R, Georgescu D. Flexible ureteroscopic approach in upper urinary tract pathology. *Chirurgia (Bucur)* 2006; **101**: 497-503.
- Osorio L, Lima E, Soares J, Autorino R, Versos R, Lhamas A, et al. Emergency ureteroscopic management of ureteral stones: why not? *Urology* 2007; **69**: 27-31.
- Hollowell CM, Patel RV, Bales GT, Gerber GS. Internet postal survey of endourologic practice patterns among American urologists. *J Urol* 2000; **163**: 1779-82.
- Schuster TG, Hollenbeck BK, Faerber GJ, Wolf JS Jr. Complications of ureteroscopy: analysis of predictive factors. *J Urol* 2001; **166**: 538-40.
- Netto Junior NR, Claro Jde A, Esteves SC, Andrade EF. Ureteroscopic stone removal in the distal ureter. Why change? *J Urol* 1997; **157**: 2081-3.
- Liatsichos EN, Dinlec C, Kapoor R, Bemardo RO, Fogarthy J. Rigid ureteroscopy: how to avoid problems? *J AUA* 2000; **163**: 52-5.
- Hollenbeck BK, Schuster TG, Faerber GJ, Wolf JS. Flexible ureteroscopy in conjunction with *in situ* lithotripsy for lower pole calculi. *Urology* 2001; **58**: 859-63.
- Gurbuz ZG, Mimaroglu S, Gurkan L, Oder M, Verim L. Ureteroscopic treatment of multiple distal-ureteral stones. *J Endourol* 2006; **20**: 1022-4.
- Akhter MS, Hameed F, Akhtar FK. Ureteroscopy: its diagnostic value. *Ann KE Med Coll* 2000; **6**: 245-8.
- Akhter MS, Hameed F, Akhtar FK. Ureteroscopy: new therapeutic indications. *Biomedica* 2000; **16**: 66-70.
- Bagley DH. Editorial: ureteroscopy continues to evolve. *J Urol* 2003; **170**: 111.
- Al Fallouji MAR. High risk patients in surgery. In: Al Fallouji MAR, (edi). Postgraduate surgery. The candidate's guide. 2nd ed. UK: *Butterworth-Heinemann*; 1998. p.169.
- Rabow MW, Pantilat SZ. Care at the end of life: pain assessment scales. In: Tierney LM, McPhee SJ, Papadakis MA, (edi). Current medical diagnosis and treatment 2003. 24th ed. New York: *McGraw Hill*; 2003.p.60-4.
- Johnson GB, Grasso M. Exaggerated primary endoscope deflection: initial clinical experience with prototype flexible ureteroscopes. *BJU Int* 2004; **93**: 109-14.
- Grasso M. Ureteropyeloscopic treatment of ureteral and intrarenal calculi. *Urol Clin North Am* 2000; **27**: 623-31.
- Razdan S, Johannes J, Cox M, Bagley DH. Current practice patterns in urologic management of upper-tract transitional-cell carcinoma. *J Endourol* 2005; **19**: 366-71.
- Vogelli A, Mellin HE, Hopf B, Ackermann R. Ureteroscopy under local anaesthesia with and without intravenous analgesia. *Br J Urol* 1993; **72**: 161-4.

.....★.....