

The New England Journal of Medicine

© Copyright, 2000, by the Massachusetts Medical Society

VOLUME 342

JUNE 8, 2000

NUMBER 23



UROTHELIAL CARCINOMA ASSOCIATED WITH THE USE OF A CHINESE HERB (*ARISTOLOCHIA FANGCHI*)

JOËLLE L. NORTIER, M.D., PH.D., MARIE-CARMEN MUNIZ MARTINEZ, M.D., HEINZ H. SCHMEISER, PH.D., VOLKER M. ARLT, CHRISTIAN A. BIELER, PH.D., MICHEL PETEIN, M.D., PH.D., MICHEL F. DEPIERREUX, M.D., LUC DE PAUW, M.D., DANIEL ABRAMOWICZ, M.D., PH.D., PIERRE VEREERSTRAETEN, M.D., PH.D., AND JEAN-LOUIS VANHERWEGHEM, M.D., PH.D.

ABSTRACT

Background Chinese-herb nephropathy is a progressive form of renal fibrosis that develops in some patients who take weight-reducing pills containing Chinese herbs. Because of a manufacturing error, one of the herbs in these pills (*Stephania tetrandra*) was inadvertently replaced by *Aristolochia fangchi*, which is nephrotoxic and carcinogenic.

Methods The diagnosis of a neoplastic lesion in the native urinary tract of a renal-transplant recipient who had Chinese-herb nephropathy prompted us to propose regular cystoscopic examinations and the prophylactic removal of the native kidneys and ureters in all our patients with end-stage Chinese-herb nephropathy who were being treated with either transplantation or dialysis. Surgical specimens were examined histologically and analyzed for the presence of DNA adducts formed by aristolochic acid. All prescriptions written for weight-reducing compounds during the period of exposure (1990 to 1992) in these patients were obtained, and the cumulative doses were calculated.

Results Among 39 patients who agreed to undergo prophylactic surgery, there were 18 cases of urothelial carcinoma (prevalence, 46 percent; 95 percent confidence interval, 29 to 62 percent): 17 cases of carcinoma of the ureter, renal pelvis, or both and 1 papillary bladder tumor. Nineteen of the remaining patients had mild-to-moderate urothelial dysplasia, and two had normal urothelium. All tissue samples analyzed contained aristolochic acid-related DNA adducts. The cumulative dose of aristolochia was a significant risk factor for urothelial carcinoma, with total doses of more than 200 g associated with a higher risk of urothelial carcinoma.

Conclusions The prevalence of urothelial carcinoma among patients with end-stage Chinese-herb nephropathy (caused by aristolochia species) is high. (N Engl J Med 2000;342:1686-92.)

©2000, Massachusetts Medical Society.

RAPIDLY progressive renal failure resulting in end-stage renal disease has been reported to occur in women who have taken weight-reducing pills containing the Chinese herbs *Stephania tetrandra* and *Magnolia officinalis*.¹ This so-called Chinese-herb nephropathy is characterized by a pattern of interstitial fibrosis similar to that of Balkan endemic nephropathy.¹⁻³ Since the importation of Chinese herbs into Belgium was terminated in 1992, we have admitted 43 patients with end-stage renal failure related to exposure to these herbs.

Since the herb powders taken by these patients did not contain tetrandrine, which is present in *S. tetrandra*, but did contain aristolochic acids, it was suspected that a nephrotoxic herb, *Aristolochia fangchi*, had inadvertently been substituted for *S. tetrandra*.⁴ This herb contains aristolochic acids, a mixture of nitrophenanthrene derivatives known for their potent carcinogenic action in rats⁵ and their mutagenic properties in bacterial⁶ and mammalian⁷ models. Moreover, Schmeiser et al. were able to detect DNA adducts formed by metabolites of aristolochic acid (aristolactams) in samples of kidneys removed from five patients with Chinese-herb nephropathy.⁸ These adducts are specific markers of exposure to aristolochic acids and are directly involved in tumorigenesis.^{5,9}

For these reasons, patients with Chinese-herb nephropathy, or aristolochia nephropathy, appear to be at risk for the development of cancer. In 1994, attention was drawn to the presence of cellular atypia throughout the urothelium of native kidneys removed at the time of renal-allograft transplantation in three

From the Departments of Nephrology (J.L.N., M.-C.M.M., L.D., D.A., P.V., J.-L.V.) and Pathology (M.P., M.F.D.), Hôpital Erasme, Université Libre de Bruxelles, Brussels, Belgium; and the Division of Molecular Toxicology, German Cancer Research Center, Heidelberg, Germany (H.H.S., V.M.A., C.A.B.). Address reprint requests to Dr. Nortier at the Nephrology Department, Hôpital Erasme, Université Libre de Bruxelles, Route de Lennik, 808, B-1070 Brussels, Belgium, or at jnortier@ulb.ac.be.

patients with Chinese-herb nephropathy.³ Soon thereafter, two cases of urothelial carcinoma were reported in such patients.^{10,11} The development of urothelial carcinoma in one of our patients who underwent renal transplantation because of Chinese-herb nephropathy caused us to inform our 43 other patients with Chinese-herb nephropathy, who were being treated for terminal renal failure by dialysis or who had received a renal allograft, about the risk of urothelial carcinoma. We suggested that they undergo regular cystoscopic examination and prophylactic removal of their native kidneys and ureters.

After a preliminary report,¹² and when the current study was nearly completed, another group reported the presence of urothelial carcinoma in 4 of 10 patients with Chinese-herb nephropathy.¹³ Our findings among 39 patients with Chinese-herb nephropathy confirm the high prevalence of urothelial carcinoma. Moreover, we found that all these patients were exposed to derivatives of aristolochia species and that the risk of urothelial carcinoma was related to the cumulative dose of the herb. Our findings reinforce the idea that the use of natural herbal medicine may not be without risk.¹⁴

METHODS

Patients

Among the group of 105 patients with Chinese-herb (*A. fangchi*) nephropathy who were treated in our department, 43 had reached end-stage renal failure at the time of the study. Twelve were receiving dialysis and waiting for a renal transplant, and 31 had already undergone successful transplantation. Thirty patients had received a cadaveric kidney transplant between 1993 and 1997, and 1 had received a kidney from her husband. The immunosuppressive treatment consisted of muromonab-CD3 (5 mg per day for the first two weeks) plus cyclosporine, azathioprine, and various doses of corticosteroids.

Except for one 60-year-old man, all the patients were women (mean [\pm SD] age, 54 \pm 7 years). All had been prescribed weight-reducing pills containing powdered Chinese herbs; such pills were not available over the counter in Belgium. The period of use (mean, 13.3 months) was closely related to the period of distribution in Belgium of pills that were supposed to contain *S. tetrandra* but actually contained *A. fangchi*: 1990 to 1992. End-stage renal failure occurred 3 to 85 months after the patients had stopped taking these pills.

The diagnosis of Chinese-herb nephropathy was based on a history of the use of these pills and the occurrence of rapidly progressive deterioration of previously normal renal function. It was confirmed by typical histologic findings² in renal-biopsy specimens from 27 patients and from specimens of the native kidneys obtained postoperatively from all 39 patients who agreed to undergo prophylactic surgery.

Tissue specimens from eight patients with end-stage renal failure unrelated to Chinese-herb nephropathy were used as controls for the analyses of DNA adducts in renal tissue. These patients had the hemolytic-uremic syndrome, analgesic nephropathy (without tumors), lupus nephritis, membranoproliferative glomerulonephritis type I, chronic idiopathic interstitial nephritis, pyelonephritis due to lithiasis, cystic nephropathy, or nephrosclerosis.

Surgical Procedure

After informing the patients about the risk of cancer in the native urinary tract, we suggested the prophylactic removal of their nonfunctioning atrophic native kidneys, including the ureters. If the

preoperative cystoscopy (one biopsy of the bladder trigone and two biopsies of random areas) did not reveal any cancer, the native bladder was left in place to preserve the natural route of elimination of urine originating from the present graft in the case of transplant recipients or the future renal graft in the case of patients receiving dialysis. However, we recommended regular postoperative cystoscopy during the follow-up period. In one patient, preoperative cystoscopy revealed a papillary tumor, which was removed endoscopically. The 31 transplant recipients and 8 of the 12 patients who were undergoing dialysis provided oral consent for the surgery.

Histologic Analyses

All samples of native kidney and ureter and all bladder-biopsy specimens obtained preoperatively were subjected to histologic analysis. After gross examination of the organs, serial specimens were obtained that included the lower part of each ureter, renal pelvis, and kidney. The specimens were fixed in formalin, dehydrated, and embedded in paraffin. The sections were stained with hematoxylin and eosin, periodic acid-Schiff, and Masson's trichrome.

The urothelial epithelium was classified as normal, dysplastic, or neoplastic.¹⁵ The stage of the tumors was defined according to the tumor-node-metastasis classification.¹⁶ We used the histologic grading system of the World Health Organization for invasive urothelial carcinoma, which has three histologic grades: mild, moderate, and severe dysplasia.¹⁷ Severe dysplasia was considered to indicate carcinoma in situ.^{18,19}

Detection of DNA Adducts in Tissue Samples

Tissue samples from each kidney and ureter from 38 of the 39 patients were frozen and stored at -80°C for subsequent isolation of DNA and the detection of DNA adducts formed by aristolochic acid. We used the nuclease P1 enrichment version of the phosphorus-32 postlabeling method, as described previously.^{8,9} Adduct levels were determined in triplicate in all renal-tissue samples. With respect to the determinations of adduct levels, the coefficient of variation for the reproducibility of the method is approximately 20 percent.

Samples of surgical specimens from 22 patients were also analyzed for ochratoxin A-related DNA adducts with use of the phosphorus-32 postlabeling method described by Pfohl-Leszkoicz et al.²⁰

Evaluation of Exposure

All prescriptions given to the patients from 1990 to 1992 were obtained from the pharmacists with the help of the Belgian Ministry of Health and were reviewed. The usual treatment consisted of a mixture of *M. officinalis* and the presumed *S. tetrandra*, in various concentrations, and appetite suppressants (fenfluramine and diethylpropion); in addition, some patients also received acetazolamide, cascara sagrada, or belladonna extract. For each patient, the cumulative doses were calculated. The results were expressed as the mean ingested dose of each compound (in grams).

Each patient was also interviewed to determine whether he or she had concomitantly received subcutaneous injections of artichoke extracts, theophylline, or both, given every two weeks (mesotherapy). The patient's smoking status and the frequency of use of analgesics, nonsteroidal antiinflammatory drugs, or both (regular use was defined as daily intake for a minimum of six months) during the period of treatment were also recorded.

Statistical Analysis

We used Fisher's exact test and unpaired t-tests to compare nominal and continuous variables, respectively. All P values are two-tailed.

RESULTS

Exposure

Our survey confirmed that all female patients had been prescribed both *S. tetrandra* and *M. officinalis*

(the male patient did not receive *M. officinalis*) as well as fenfluramine and diethylpropion. Twenty-seven patients were given acetazolamide, whereas 31 received concomitant mesotherapy. Fourteen patients received dexfenfluramine, and seven received phentermine.

Histologic Findings

Specimens from 77 kidneys and 78 ureters were available for systematic grading of urothelial lesions; 1 kidney had been previously removed during transplantation in Switzerland. For specimens with abnormal histologic findings, the findings were classified according to the highest grade and stage. Among 39 patients, 18 cases of urothelial carcinoma were found (prevalence, 46 percent; 95 percent confidence interval, 29 to 62 percent). Except in the case of one patient with bladder involvement, which had been treated by local endoscopic resection before prophylactic surgery was performed, the neoplastic lesions were located in the upper urinary tract and were almost equally distributed between the pelvis and the ureter. Urothelial lesions resulting from mild-to-moderate dysplasia were found in 19 of the 21 patients without urothelial carcinoma (Table 1).

Analyses of DNA Adducts in Tissue Samples

Tissue samples of kidneys and ureters from 38 patients and 8 controls were analyzed for the presence of DNA adducts.

Aristolochic Acid–Related DNA Adducts

The kidneys from the patients with Chinese-herb nephropathy had the same pattern of adducts — one that is typically found after exposure to aristolochic acid (Fig. 1A). This pattern consisted of one major DNA adduct, 7-(deoxyadenosine-*N*⁶-yl)-aristolactam

I, and two minor adducts, 7-(deoxyadenosine-*N*⁶-yl)-aristolactam II and 7-(deoxyguanosine-*N*²-yl)-aristolactam I. The total adduct levels ranged from 1.7 to 175 per 10⁹ normal (unaffected) nucleotides. In four patients who were long-term smokers, a diffuse band of radioactivity typical of smoking-related adducts (referred to as the diagonal radioactive zone)²¹ was present in addition to the aristolochic acid–related DNA adducts (Fig. 1B).

Levels of aristolochic acid–related DNA adducts in individual patients ranged from 1.2 to 165 per 10⁹ normal nucleotides in the case of 7-(deoxyadenosine-*N*⁶-yl)-aristolactam I, from 0.6 to 6.8 per 10⁹ normal nucleotides in the case of 7-(deoxyadenosine-*N*⁶-yl)-aristolactam II, and from 0.4 to 8.2 per 10⁹ normal nucleotides in the case of 7-(deoxyguanosine-*N*²-yl)-aristolactam I. The major DNA adduct — 7-(deoxyadenosine-*N*⁶-yl)-aristolactam I — was still detectable in native kidney tissue up to 89 months after the discontinuation of the weight-reducing pills (mean interval between discontinuation of the medication and surgery, 73 months; range, 56 to 89).

No statistically significant differences were observed in the mean levels of 7-(deoxyadenosine-*N*⁶-yl)-aristolactam I DNA adducts in renal-tissue samples between patients in whom urothelial carcinoma had developed and those in whom it had not developed (Table 2).

Analyses of DNA isolated in 17 ureteral specimens from 11 patients had the same aristolochic acid–specific pattern of adducts, although the levels of adducts were markedly lower than those found in kidneys; the range for 7-(deoxyadenosine-*N*⁶-yl)-aristolactam I was 2.2 to 34 per 10⁹ normal nucleotides.

No DNA adduct formed by aristolochic acid was detected in kidney samples from the eight control patients.

Ochratoxin A–Related DNA Adducts

Tissue samples from 25 kidney specimens from patients with a histologic diagnosis of neoplasia (12 specimens), dysplasia (7), or no abnormalities (6) were analyzed for ochratoxin A–related DNA adducts. This assay was used to exclude ochratoxin A nephropathy as a possible cause of renal failure. Four of these 25 samples (2 with carcinoma in situ [neoplasia] and 2 with dysplasia) had a pattern of DNA-adduct spots similar to those detected in kidney specimens from animals given ochratoxin, which served as positive controls.²² Levels of these adducts were quite low (ranging from 1.3 to 6.8 per 10⁹ normal nucleotides) and were close to the background level of the assay. Analyses of renal-tissue samples from all control patients were free of spots in the area where adducts associated with ochratoxin A were located.

Risk Factors for Urothelial Carcinoma

Quantitative estimates of the amounts of herbs and other compounds ingested by patients with uro-

TABLE 1. HISTOLOGIC FINDINGS IN SPECIMENS OF NATIVE KIDNEY AND URETER FROM 39 PATIENTS WITH END-STAGE CHINESE-HERB NEPHROPATHY.

HISTOLOGIC FINDING*	LOCATION	NO. OF PATIENTS
Mild-to-moderate dysplasia	Pelvis	4
Stage pTa	Pelvis	1
Stage pTis	Pelvis	5
Stage T3	Pelvis	1
Mild-to-moderate dysplasia	Ureter	5
Stage pTis	Ureter	5
Stage pTa and pTis	Ureter	1
Stage T1 (grade III)	Ureter	1
Stage T2	Ureter	1
Normal	Pelvis and ureter	2
Mild-to-moderate dysplasia	Pelvis and ureter	10
Stage pTis	Pelvis and ureter	2
Stage pTa	Bladder	1

*The findings were classified according to the highest stage and grade identified; pTa denotes noninvasive papillary carcinoma, and pTis noninvasive (flat) carcinoma in situ.

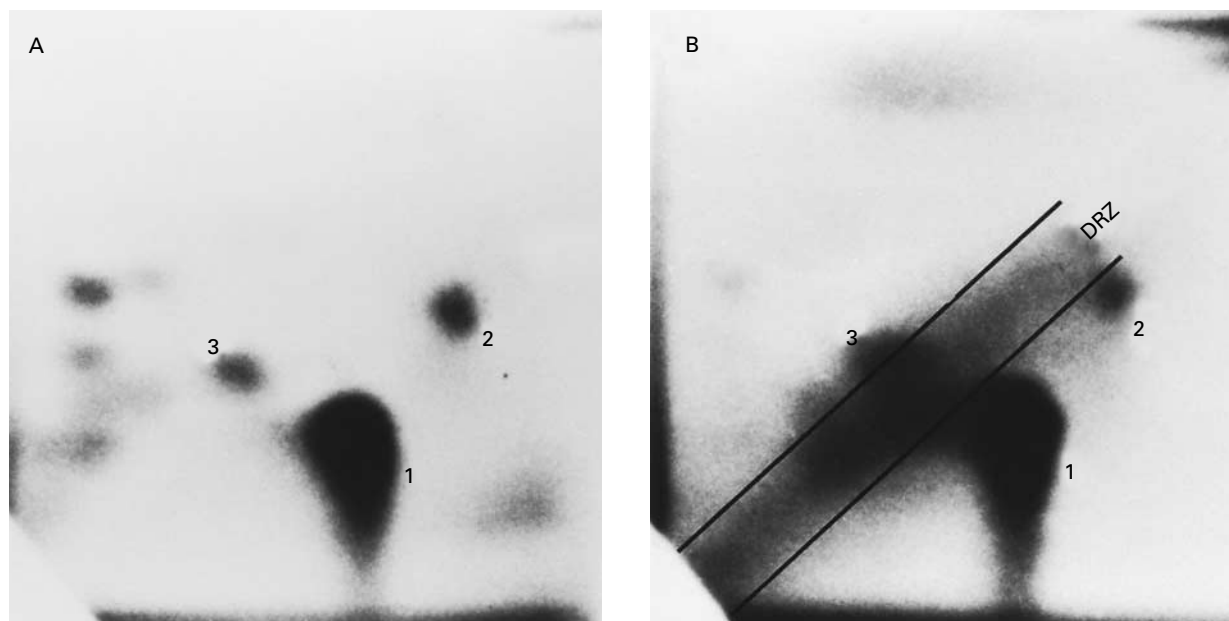


Figure 1. Autoradiograms of DNA Adducts in Renal Tissue from Two Patients with Chinese-Herb Nephropathy.

Panel A shows a specimen obtained from a nonsmoker: spots 1, 2, and 3 reflect the typical pattern of aristolochic acid-related DNA adducts. In spot 1, the adduct was identified as 7-(deoxyadenosine- N^6 -yl)-aristolactam I, in spot 2 as 7-(deoxyadenosine- N^6 -yl)-aristolactam II, and in spot 3 as 7-(deoxyguanosine- N^2 -yl)-aristolactam I. Panel B shows a specimen obtained from a smoker in which a diagonal radioactive zone (DRZ) is present — the typical pattern of smoking-related adducts.

TABLE 2. MEAN DURATION OF USE AND TOTAL DOSES OF COMPONENTS OF WEIGHT-REDUCING PILLS AND LEVELS OF ARISTOLOCHIC ACID-RELATED DNA ADDUCTS IN 18 PATIENTS WITH CHINESE-HERB NEPHROPATHY AND UROTHELIAL CARCINOMA AND 21 PATIENTS WITH CHINESE-HERB NEPHROPATHY WITHOUT UROTHELIAL CARCINOMA.

VARIABLE	UROTHELIAL CARCINOMA PRESENT (N=18)	UROTHELIAL CARCINOMA ABSENT (N=21)	P VALUE
	mean \pm SD		
Compound labeled as containing <i>Stephania tetrandra</i> *			
Total dose (g)	226 \pm 23	167 \pm 17	0.035
Duration of use (mo)	15 \pm 1.4	12 \pm 1.1	0.09
<i>Magnolia officinalis</i> (g)	95.1 \pm 10.3	66 \pm 7.5	0.026
Acetazolamide (g)	47.3 \pm 6.1	24.8 \pm 5.5	0.012
Fenfluramine (g)	17.8 \pm 2.6	12.5 \pm 2.1	0.13
Diethylpropion (g)	16.9 \pm 2.2	13.2 \pm 1.9	0.20
No. of 7-(deoxyadenosine- N^6 -yl)-aristolactam I DNA adducts/ 10^9 normal nucleotides	29.9 \pm 9.3	31.2 \pm 7.8	0.91

*The compound actually contained *Aristolochia fangchi*.

thelial carcinoma and those without urothelial carcinoma were compared (Table 2). The mean cumulative doses of fenfluramine and diethylpropion in the two groups were not significantly different, whereas those of the compound labeled as containing *S. tetrandra* but actually containing *A. fangchi*, as con-

firmed by the detection of aristolochic acid-related DNA adducts ($P=0.035$), *M. officinalis* ($P=0.026$), and acetazolamide ($P=0.012$), were significantly different. Among these three compounds, which were almost always prescribed together, the association between urothelial carcinoma and the intake of aceta-

TABLE 3. RISK FACTORS FOR UROTHELIAL CARCINOMA IN PATIENTS WITH END-STAGE CHINESE-HERB NEPHROPATHY.

VARIABLE	ALL PATIENTS	UROTHELIAL CARCINOMA PRESENT (N=18)	UROTHELIAL CARCINOMA ABSENT (N=21)	P VALUE*
		number (percent)		
Use of compound labeled as containing <i>Stephania tetrandra</i> †	39 (100)	18 (100)	21 (100)	1.00
Concomitant use of <i>Magnolia officinalis</i>	38 (97)	18 (100)	21 (100)	0.99
Concomitant use of acetazolamide	27 (69)	14 (78)	13 (62)	0.32
Concomitant use of dexfenfluramine	16 (41)	5 (28)	11 (52)	0.19
Concomitant use of phentermine	7 (18)	2 (11)	5 (24)	0.42
Mesotherapy	31 (79)	15 (83)	16 (76)	0.70
Concomitant regular use of analgesics‡	8 (21)	3 (17)	5 (24)	0.70
Concomitant regular use of nonsteroidal antiinflammatory drugs‡	7 (18)	4 (22)	3 (14)	0.68
Concomitant smoking	12 (31)	7 (39)	5 (24)	0.49

*P values are for the comparison of patients with urothelial carcinoma and those without urothelial carcinoma.

†The compound actually contained *Aristolochia fangchi*.

‡Regular use was defined as daily intake for a minimum of six months.

zolamide was the strongest. However, the proportion of patients with urothelial cancer who took both *A. fangchi* and acetazolamide and the proportion among those who took *A. fangchi* without this diuretic were not significantly different (14 of 27 patients vs. 4 of 12 patients, $P=0.32$). Among the 24 patients with a total dose of *A. fangchi* of 200 g or less, 8 cases of urothelial cancer were detected, whereas among the 15 patients who had ingested 201 g or more there were 10 cases ($P=0.05$).

The possible influence of the use of mesotherapy, the use of nonsteroidal antiinflammatory drugs, and smoking status on the development of urothelial carcinoma was evaluated in a univariate analysis. There were no significant differences in these variables between the patients with urothelial carcinoma and those without urothelial carcinoma (Table 3). Urothelial carcinoma developed in 3 of 8 patients who took analgesics regularly while they were receiving the weight-reducing pills and in 15 of 31 who did not take analgesics ($P=0.70$).

DISCUSSION

We found that carcinoma developed in the native urinary tract in 18 of 39 patients with end-stage renal disease related to the regular intake of aristolochia species.

The role of Chinese herbs (specifically, aristolochia species) as a cause of renal failure and urothelial carcinoma is still a matter of debate, for several reasons. First, promoters of Chinese herbs have claimed that the renal disease originated from the injection of a "hidden substance" (serotonin) at the time of meso-

therapy; this claim has not been confirmed.^{23,24} Second, analgesic nephropathy is a frequent type of renal disease in Belgium²⁵ and could thus be misdiagnosed as Chinese-herb nephropathy, since urothelial cancer develops in up to 10 percent of patients with analgesic nephropathy.²⁶ Third, similarities between Chinese-herb nephropathy and Balkan endemic nephropathy have been described,¹⁻³ including the association of both with urothelial carcinoma. Some evidence suggests that Balkan endemic nephropathy is an environmentally induced disease, perhaps related to exposure to fungal or plant nephrotoxins such as ochratoxin A and aristolochic acids.²⁷ Both compounds are nephrotoxic and carcinogenic.

Our results enable us to address these issues. Thanks to the collaboration of the Belgian Ministry of Health and of pharmacists, we were able to quantify the cumulative doses of the compounds taken by our patients. Insofar as DNA adducts in tissue samples are valid biomarkers, we assessed possible exposure to tobacco, aristolochic acid, and ochratoxin A. We found that renal failure with or without urothelial carcinoma developed in some patients who never received mesotherapy (and thus were not exposed to any "hidden substance"), who were not regular users of analgesics or tobacco, and who had not been exposed to ochratoxin A (which is classified as a possible carcinogen in humans).²⁸ No trace of ochratoxin A was detected by Vanhaelen et al. in several samples of *S. tetrandra*.⁴ Only a small number of renal-tissue samples that we analyzed were weakly positive for ochratoxin A-related DNA adducts, indicating that ochratoxin A does not have a key role in Chinese-herb nephropathy.

Conversely, all patients had been exposed to aristolochic acids and had aristolochic acid-related DNA adducts in specimens of renal tissue. Moreover, the risk of urothelial carcinoma was related to the cumulative intake of *A. fangchi*. Our evidence indicates that the regular intake of powdered Chinese herbs of the aristolochia species dramatically increases the risk of urothelial carcinoma.

Since most of our patients were treated with appetite suppressants as well as acetazolamide, we cannot exclude the possibility that the former, which are serotonin agonists or sympathomimetic drugs with vasoconstrictive properties,²⁹ or the latter, which alkalinizes the urine, enhances the toxicity of the aristolochia species.

High doses of the natural mixture of aristolochic acids I and II induce acute tubular necrosis in animals³⁰ and humans,³¹ but chronic interstitial fibrosis has not been reported. The carcinogenic and mutagenic effects associated with the binding of metabolites of aristolochic acid to DNA have been extensively described in studies in animals and in vitro studies^{8,32} and resulted in the classification of aristolochic acid as a genotoxic carcinogen. Indeed, the 7-(deoxyadenosine-*N*⁶-yl)-aristolactam I adduct is a premutagenic lesion in genomic DNA and is associated with mutations in biologically important genes involved in carcinogenesis, such as the *H-ras* proto-oncogene³³ and the *p53* gene.¹³ In this respect, the absence of significant differences in the levels of 7-(deoxyadenosine-*N*⁶-yl)-aristolactam I DNA adducts in specimens of native kidney between patients with and those without urothelial carcinoma may be due to the fact that levels of these adducts are most likely the result of a balance between their formation and their loss through either DNA-repair processes or apoptosis. The observation that the amounts of 7-(deoxyadenosine-*N*⁶-yl)-aristolactam I DNA adducts did not correlate with the cumulative dose of *A. fangchi* is not disturbing, since the aristolochic acid content of the delivered powders differed by a factor of 1 to 10 from one batch to another.⁴

Our data suggest that aristolochia toxins (aristolochic acids and also possibly other derivatives) cause renal disease and urothelial cancer. Until recently, Chinese-herb nephropathy seemed to be limited to an outbreak in Belgium. Now, other cases have been reported in France,³⁴ Spain,³⁵ Japan,^{36,37} the United Kingdom,³⁸ and Taiwan,³⁹ where cases of urothelial carcinoma have also been detected. Our results should prompt physicians to inquire about the use of herbal medicine when patients have a renal disease or urothelial tumor of unknown origin.

Dr. Nortier is a research fellow with the Foundation Erasme (Université Libre de Bruxelles, Brussels, Belgium).

We are indebted to Drs. A. Pfohl-Leszkowicz and M. Castegnaro for providing DNA samples from ochratoxin A-treated animals; to

Drs. C. Richard, M. Dratwa, and J.-J. Cuykens for referring several patients to us; to the late Dr. J. Simon (urology department) for his collaboration; to the Belgian Ministry of Health (Inspection de la Pharmacie) for giving us permission to examine patients' prescriptions; to Drs. C. Tielemans, M. Wissing, and N. Broeders for care of the patients; to Dr. P. Kinnaert for his helpful criticism of the manuscript; and to the nursing and technical staffs of the nephrology and pathology departments for their continuous cooperation.

REFERENCES

1. Vanherweghem J-L, Depierreux M, Tielemans C, et al. Rapidly progressive interstitial renal fibrosis in young women: association with slimming regimen including Chinese herbs. *Lancet* 1993;341:387-91.
2. Depierreux M, Van Damme B, Vanden Houste K, Vanherweghem J-L. Pathologic aspects of a newly described nephropathy related to the prolonged use of Chinese herbs. *Am J Kidney Dis* 1994;24:172-80.
3. Cosyns J-P, Jadoul M, Squifflet J-P, et al. Chinese herbs nephropathy: a clue to Balkan endemic nephropathy? *Kidney Int* 1994;45:1680-8.
4. Vanhaelen M, Vanhaelen-Fastre R, But P, Vanherweghem J-L. Identification of aristolochic acid in Chinese herbs. *Lancet* 1994;343:174.
5. Mengs U, Lang W, Poch J-A. The carcinogenic action of aristolochic acid in rats. *Arch Toxicol* 1982;51:107-19.
6. Schmeiser HH, Pool BL, Wiessler M. Identification and mutagenicity of metabolites of aristolochic acid formed by rat liver. *Carcinogenesis* 1986;7:59-63.
7. Pezzuto JM, Swanson SM, Mar W, Che C, Cordell GA, Fong HHS. Evaluation of the mutagenic and cytostatic potential of aristolochic acid (3,4-methylenedioxy-8-methoxy-10-nitrophenanthrene-1-carboxylic acid) and several of its derivatives. *Mutat Res* 1988;206:447-54.
8. Schmeiser HH, Bieler CA, Wiessler M, van Ypersele de Strihou C, Cosyns J-P. Detection of DNA adducts formed by aristolochic acid in renal tissue from patients with Chinese herbs nephropathy. *Cancer Res* 1996;56:2025-8.
9. Bieler CA, Stiborova M, Wiessler M, Cosyns J-P, van Ypersele de Strihou C, Schmeiser HH. ³²P-post-labelling analysis of DNA adducts formed by aristolochic acid in tissues from patients with Chinese herbs nephropathy. *Carcinogenesis* 1997;18:1063-7.
10. Cosyns J-P, Jadoul M, Squifflet J-P, Van Cangh P-J, van Ypersele de Strihou C. Urothelial malignancy in nephropathy due to Chinese herbs. *Lancet* 1994;344:188.
11. Vanherweghem J-L, Tielemans C, Simon J, Depierreux M. Chinese herbs nephropathy and renal pelvic carcinoma. *Nephrol Dial Transplant* 1995;10:270-3.
12. Nortier J, Simon J, Petein M, et al. Chinese herbs nephropathy and urinary tract carcinoma. *J Am Soc Nephrol* 1998;9:164A. abstract.
13. Cosyns J-P, Jadoul M, Squifflet J-P, Wese F-X, van Ypersele de Strihou C. Urothelial lesions in Chinese-herb nephropathy. *Am J Kidney Dis* 1999;33:1011-7.
14. Angell M, Kassirer JP. Alternative medicine — the risks of untested and unregulated remedies. *N Engl J Med* 1998;339:839-41.
15. Cabanne F, Pagès A, Billerey C, Oppermann A, Carbillet J-P, eds. Pathologie génitale masculine: uropathologie. Paris: Masson, 1992:354-5.
16. Sobin LH, Wittekind C, eds. TNM classification of malignant tumors. 5th ed. New York: Wiley-Liss, 1997.
17. Bostwick DG, Eble JN, eds. Urologic surgical pathology. St. Louis: Mosby-Year Book, 1997:246-7.
18. Murphy WM, Soloway MS. Urothelial dysplasia. *J Urol* 1982;127:849-54.
19. Richards B, Parmar MKB, Anderson CK, et al. Interpretation of biopsies of "normal" urothelium in patients with superficial bladder cancer. *Br J Urol* 1991;67:369-75.
20. Pfohl-Leszkowicz A, Grosse Y, Castegnaro M, et al. Ochratoxin A-related DNA adducts in urinary tract tumours of Bulgarian subjects. In: Phillips DH, Castegnaro M, Bartsch H, eds. Postlabelling methods for detection of DNA adducts. Lyon, France: International Agency for Research on Cancer, 1993:141-8. (IARC scientific publications no. 124.)
21. Everson RB, Randerath E, Santella RM, Cefalo RC, Avitts TA, Randerath K. Detection of smoking-related covalent DNA adducts in human placenta. *Science* 1986;231:54-7.
22. Castegnaro M, Mohr U, Pfohl-Leszkowicz A, et al. Sex- and strain-specific induction of renal tumors by ochratoxin A in rats correlates with DNA adduction. *Int J Cancer* 1998;77:70-5.
23. McIntyre M. Chinese herbs: risk, side effects, and poisoning: the case for objective reporting and analysis reveals serious misrepresentation. *J Altern Complement Med* 1998;4:15-6.
24. Malak J. Chinese herb nephropathy is not a (dex)fenfluramine nephropathy but a serotonin nephropathy. *J Altern Complement Med* 1998;4:131-5.

25. De Broe ME, Elseviers MM. Analgesic nephropathy. *N Engl J Med* 1998;338:446-52.
26. Kliem V, Thon W, Krautzig S, et al. High mortality from urothelial carcinoma despite regular tumor screening in patients with analgesic nephropathy after renal transplantation. *Transpl Int* 1996;9:231-5.
27. Stefanović V, Polenaković MH. Balkan nephropathy: kidney disease beyond the Balkans? *Am J Nephrol* 1991;11:1-11.
28. Ochratoxin A. In: IARC monographs on the evaluation of carcinogenic risks of chemicals to humans. Vol. 56. Some naturally occurring substances: food items and constituents, heterocyclic aromatic amines and mycotoxins. Lyon, France: International Agency for Research on Cancer, 1993:489-521.
29. De Broe ME. On a nephrotoxic and carcinogenic slimming regimen. *Am J Kidney Dis* 1999;33:1171-3.
30. Mengs U, Stotzem CD. Renal toxicity of aristolochic acid in rats as an example of nephrotoxicity testing in routine toxicology. *Arch Toxicol* 1993;67:307-11.
31. Jackson L, Kofman S, Weiss A, Brodovsky H. Aristolochic acid (NSC-50413): phase I clinical study. *Cancer Chemother Rep* 1964;42:35-7.
32. Schmeiser HH, Pool BL, Wiessler M. Mutagenicity and in vitro metabolism of aristolochic acid. *Biochem Pharmacol* 1985;34:455-6.
33. Schmeiser HH, Janssen JWG, Lyons J, et al. Aristolochic acid activates *ras* genes in rat tumors at deoxyadenosine residues. *Cancer Res* 1990;50:5464-9.
34. Pourrat J, Montastruc JL, Lecombe JL, Cisterne JM, Rascol O, Dumazer P. Néphropathie associée à des herbes chinoises: 2 cas. *Presse Med* 1994;23:1669-70.
35. Peña JM, Borrás M, Ramos J, Montoliu J. Rapidly progressive interstitial renal fibrosis due to a chronic intake of a herb (*Aristolochia pistolochia*) infusion. *Nephrol Dial Transplant* 1996;11:1359-60.
36. Tanaka A, Shinkai S, Kasuno K, et al. Chinese herbs nephropathy in the Kansai area: a warning report. *Jpn J Nephrol* 1997;39:438-40. (In Japanese.)
37. Tanaka A, Nishida R, Sawai K, et al. Traditional remedy-induced Chinese herbs nephropathy showing rapid deterioration of renal function. *Jpn J Nephrol* 1997;39:794-7. (In Japanese.)
38. Lord GM, Tagore R, Cook T, Gower P, Pusey CD. Nephropathy caused by Chinese herbs in the UK. *Lancet* 1999;354:481-2.
39. Yang C-S, Lin C-H, Chang S-H, Hsu H-C. Rapidly progressive fibrosing interstitial nephritis associated with Chinese herbal drugs. *Am J Kidney Dis* 2000;35:313-8.

IMAGES IN CLINICAL MEDICINE

The *Journal* has a large backlog of Images in Clinical Medicine that have been accepted for publication. Therefore, we will not consider new submissions in 2000. This decision will be reevaluated in December.
