

Use of a new videolaryngoscope (GlideScope®) in the management of a difficult airway

[L'usage d'un nouveau vidéolaryngoscope (GlideScope®) pour une intubation difficile]

Richard M. Cooper BSc MSc MD FRCPC

Purpose: To describe the clinical use of a new videolaryngoscope in a patient who had repeatedly been difficult or impossible to intubate by conventional direct laryngoscopy. This device provided excellent glottic visualization and permitted easy endotracheal intubation.

Clinical features: A 74-yr-old male presenting for repeat elective surgery had a history of failed intubations by direct laryngoscopy and pulmonary aspiration with a laryngeal mask airway. He refused awake flexible fiberoptic intubation. After the induction of general anesthesia, laryngoscopy was performed using a GlideScope®. This provided complete glottic exposure and easy endotracheal intubation.

Conclusion: This new videolaryngoscope provided excellent laryngeal exposure in a patient whom multiple experienced anesthesiologists had repeatedly found to be difficult or impossible to intubate using direct laryngoscopy. The clinical role of this device awaits confirmation in a large series of difficult airways.

Objectif : Décrire l'utilisation clinique d'un nouveau vidéolaryngoscope chez un patient pour qui l'intubation avait été difficile ou impossible à quelques reprises en laryngoscopie directe traditionnelle. Ce dispositif a fourni une excellente visualisation glottique et permis une intubation endotrachéale facile.

Éléments cliniques : Un homme de 74 ans, vu à maintes reprises en chirurgie élective, avait subi des intubations souvent impossibles par laryngoscopie directe et une aspiration pulmonaire lors de l'usage d'un masque laryngé. Il refusait l'intubation vigile avec un fibroscope flexible. Après l'induction de l'anesthésie générale, la laryngoscopie a été réalisée avec un GlideScope®. L'appareil a fourni une exposition glottique complète et permis une intubation endotrachéale facile.

Conclusion : Ce nouveau vidéolaryngoscope a fourni une excellente exposition laryngée chez un patient qui avait subi à de multiples reprises des difficultés ou même l'impossibilité d'intubation par laryngoscopie directe. Le rôle clinique de cet appareil devrait être confirmé par une grande série sur les intubations difficiles.

INTUBATION using direct laryngoscopy is successful in the majority of patients, even when a line-of-sight view of the glottis is not possible. Although poor glottic visualization is encountered between 1.5–8.5% of attempts,¹ success can generally be achieved with additional force, external laryngeal manipulation, the use of airway adjuncts such as articulated laryngoscopes, bougies and stylets or alternative techniques such as a lightwand or intubating laryngeal mask. Poor glottic exposure is more likely to require prolonged or multiple attempts and be associated with complications.² Flexible fiberoptic devices are well suited for many settings where a line-of-sight cannot be achieved, however after the fibrescope is introduced into the trachea, tube advancement is usually accomplished without visual control. Though rigid fiberoptic laryngoscopes do not suffer from the above limitation, they are not widely used, perhaps in part because they are perceived as being difficult to use.³ A new videolaryngoscope is described which is similar in technique to direct laryngoscopy but does not depend upon a line-of-sight. The image is captured by a miniature video camera embedded in the undersurface of the blade and transmitted to a monitor, permitting verifiable glottic exposure and video capture of the image. Larger studies, however will be required to determine its role in routine and complex airway cases.

Case report

A 74-yr-old male (110 kg, 180 cm) presented for elective transurethral resection of recurrent bladder tumours. He provided a history of gastroesophageal reflux and hypertension. He denied knowledge of any prior difficulties with anesthesia.

From the University of Toronto, Department of Anesthesia and Pain Management, Toronto General Hospital, Toronto, Ontario, Canada.

Address correspondence to: Dr. Richard M. Cooper, University of Toronto, Department of Anesthesia and Pain Management, Toronto General Hospital, 200 Elizabeth Street, 3EN-421, Toronto, Ontario M5G 2C4, Canada. Phone: 416-340-5164; Fax: 416-340-3698; E-mail: richard.cooper@uhn.on.ca

Accepted for publication January 24, 2003.

Revision accepted March 14, 2003.

Review of the medical records, revealed five previous general anesthetics. On two occasions, the airway was electively managed with a size 4 Laryngeal Mask Airway (LMA; The Laryngeal Mask Company, Henley-on-Thames, UK) without incident. Three other times, direct laryngoscopy was attempted. Twice the laryngeal view as described was consistent with a Cormack-Lehane grade III view and once a grade IV view.⁴ On one of these occasions, endotracheal intubation was achieved with difficulty. On another occasion, intubation was unsuccessful and again a size 4 LMA was easily inserted. Finally, for the remaining procedure, spinal anesthesia was proposed but rejected by the patient. A ProSeal LMA (PLMA; size not recorded) was inserted without difficulty. It appeared to be well seated and positive pressure ventilation was provided, however airway obstruction developed. The record did not indicate how proper placement was confirmed. Ventilation became difficult despite efforts to deepen the level of anesthesia. Regurgitation of gastric contents was noted in the oropharynx and oxygen desaturation developed.

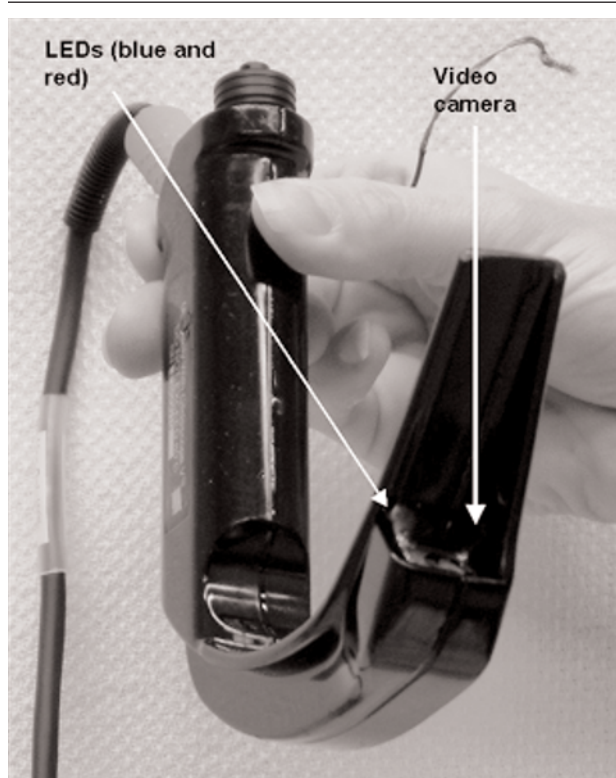


FIGURE 1 The GlideScope® videolaryngoscope is shown. Note the 60° upward angulation of the blade. A power cord/video cable, emerging from the handle, attaches to a dedicated LCD monitor. Illumination is provided by two light emitting diodes (red and blue). A small black and white CCD camera is lateral to the diodes.

The oropharynx was suctioned and the PLMA was removed. A Cormack-Lehane grade IV view was observed by direct laryngoscopy and endotracheal intubation could not be accomplished. Flexible fiberoptic intubation was successful but aspiration and arterial desaturation to a nadir of 87% occurred. The patient's clinical condition improved, permitting extubation at the conclusion of the case.

Seven months later, the patient presented for repeat cystoscopic bladder tumour resection. He professed a lack of awareness of any prior anesthetic problems. On examination, he had a normal interincisor gap, thyromental distance, cervical range of motion and a class II Mallampati view.⁵ He declined the recommendation of awake fiberoptic intubation but agreed to this if laryngoscopy or fiberoptic intubation following induction proved unsuccessful. Sodium citrate was administered and anesthesia was induced with fentanyl, propofol and succinylcholine following preoxygenation. Cricoid pressure was maintained and a videolaryngoscope



FIGURE 2 This is a typical view seen on the LCD monitor – not that of the patient described in this report. It illustrates the endotracheal tube passing through the larynx. Complete control throughout tube insertion can be achieved.

(GlideScope®, Saturn Biomedical Systems, Burnaby, BC, Canada) was inserted. The glottic opening was readily visualized (Cormack-Lehane grade I) and endotracheal intubation was accomplished using a malleable stylet within approximately 15 sec. At the conclusion of an uneventful case, extubation was performed using a tube exchanger (ETVC, CardioMed Supplies, Gormley, ON, Canada).⁶ The latter was removed shortly thereafter in the postanesthesia care unit.

Discussion

This case is the first publication describing the use of the GlideScope® videolaryngoscope (GSVL; Figure 1). At the time, the author had used this device in over 80 patients, including several who were predicted or proved to be difficult by conventional direct laryngoscopy. The plastic laryngoscope blade incorporates red and blue light emitting diodes providing illumination and contrast. The image is obtained from a fog-resistant, high-resolution videochip, angled upward at 60°. The image is transmitted to a dedicated 7-inch LCD panel (Figure 2). The orientation of the videochip imparts a very different laryngoscopic view than the one seen when simultaneously looking into the mouth. It is not uncommon to encounter Cormack-Lehane class III or IV views by direct laryngoscopy while much or most of the glottis is visualized on the video display. An example of a typical laryngoscopy and intubation with the GSVL accompanies this article as "additional material" at www.cja-jca.org. Clinical experience to-date, confirms the lack of correlation between the usual predictors of difficulty for direct laryngoscopy and the difficulty experienced with the GSVL. This is similar to the experience reported by others using rigid fiberoptic laryngoscopy.⁷ In the present case, several experienced anesthesiologists described poor laryngeal views and were generally unable to accomplish endotracheal intubation despite proper positioning, a variety of laryngoscope blades and external laryngeal manipulation. In the present report, superb laryngeal visualization and easy endotracheal intubation was achieved using the GSVL.

Rigid fiberoptic laryngoscopy (e.g., Bullard laryngoscope™ [ACMI, Southborough, MA, USA], WuScope™ [Achi Corporation, Freemont, CA, USA], Shikani Seeing Optical Stylet™ [Clarus Medical, Minneapolis, MN, USA], Upsherscope Ultra™ [Mercury Medical, Clearwater, FL, USA]) often provide excellent glottic visualization, but generally require a significant amount of experience to achieve proficiency. The latter devices are often used with cumbersome external light sources, video cameras and monitors. The view is also susceptible to fogging. The GSVL, on the

other hand, is self-contained, and very similar in appearance and technique to direct laryngoscopy, making this clinical approach very accessible. This technique potentially challenges the prevailing wisdom that such patients must be managed by awake fiberoptic intubation and may prove useful when the patient refuses or clinical circumstances make such an approach inappropriate. Clinical experience from a number of operators in a large number of patients with wide variety of airways is anxiously awaited.

The patient was subsequently provided with a "Difficult Airway Letter" and registration with the MedicAlert Foundation was strongly encouraged.^{1,8} It is important to emphasize that success with an alternative device does not change his designation as a difficult airway (or more precisely, a "difficult laryngoscopy"), particularly when the difficulty is not apparent from examination. As this case illustrates, even a properly informed patient cannot be relied upon as a historian and expertise with a successful alternative technique should be readily available.

References

- 1 Crosby ET, Cooper RM, Douglas MJ, et al. The unanticipated difficult airway with recommendations for management. *Can J Anaesth* 1998; 45: 757-76.
- 2 Rose DK, Cohen MM. The airway: problems and predictions in 18,500 patients. *Can J Anaesth* 1994; 41: 372-83.
- 3 Rosenblatt WH, Wagner PJ, Ovassapian A, Kain ZN. Practice patterns in managing the difficult airway by anesthesiologists in the United States. *Anesth Analg* 1998; 87: 153-7.
- 4 Cormack RS, Lehane J. Difficult tracheal intubation in obstetrics. *Anaesthesia* 1984; 39: 1105-11.
- 5 Mallampati SR, Gatt SP, Gugino LD, et al. A clinical sign to predict difficult tracheal intubation: a prospective study. *Can Anaesth Soc J* 1985; 32: 429-34.
- 6 Cooper RM. The use of an endotracheal ventilation catheter in the management of difficult extubations. *Can J Anaesth* 1996; 43: 90-3.
- 7 Cooper SD, Benumof JL, Ozaki GT. Evaluation of the Bullard laryngoscope using the new intubating stylet: comparison with conventional laryngoscopy. *Anesth Analg* 1994; 79: 965-70.
- 8 Mark LJ, Beattie C, Ferrell CL, Trempey G, Dorman T, Schauble JF. The difficult airway: mechanisms for effective dissemination of critical information. *J Clin Anesth* 1992; 4: 247-51.