

# Vascular and Biliary Variants in the Liver: Implications for Liver Surgery<sup>1</sup>

## CME FEATURE

See accompanying test at [http://www.rsna.org/education/rg\\_cme.html](http://www.rsna.org/education/rg_cme.html)

## LEARNING OBJECTIVES FOR TEST 1

After reading this article and taking the test, the reader will be able to:

- Discuss the relevant surgical steps in living donor liver transplantation, hepatic tumorectomy, and placement of hepatic intraarterial pumps.
- Identify the normal and variant hepatic arterial, hepatic venous, portal venous, and bile duct anatomy.
- Describe the variant hepatic vascular and biliary anatomy relevant to hepatic surgery.

*Onofrio A. Catalano, MD • Anandkumar H. Singh, MD • Raul N. Uppot, MD • Peter F. Hahn, MD, PhD • Cristina R. Ferrone, MD • Dushyant V. Sahani, MD*

Accurate preoperative assessment of the hepatic vascular and biliary anatomy is essential to ensure safe and successful hepatic surgery. Such surgical procedures range from the more complex, like tumor resection and partial hepatectomy for living donor liver transplantation, to others performed more routinely, like laparoscopic cholecystectomy. Modern noninvasive diagnostic imaging techniques, such as multidetector computed tomography (CT) and magnetic resonance (MR) imaging performed with liver-specific contrast agents with biliary excretion, have replaced conventional angiography and endoscopic cholangiography for evaluation of the hepatic vascular and biliary anatomy. These techniques help determine the best hepatectomy plane and help identify patients in whom additional surgical steps will be required. Preoperative knowledge of hepatic vascular and biliary anatomic variants is mandatory for surgical planning and to help reduce postoperative complications. Multidetector CT and MR imaging, with the added value of image postprocessing, allow accurate identification of areas at risk for venous congestion or devascularization. This information may influence surgical planning with regard to the extent of hepatic resection or the need for vascular reconstruction.

©RSNA, 2008

## TEACHING POINTS

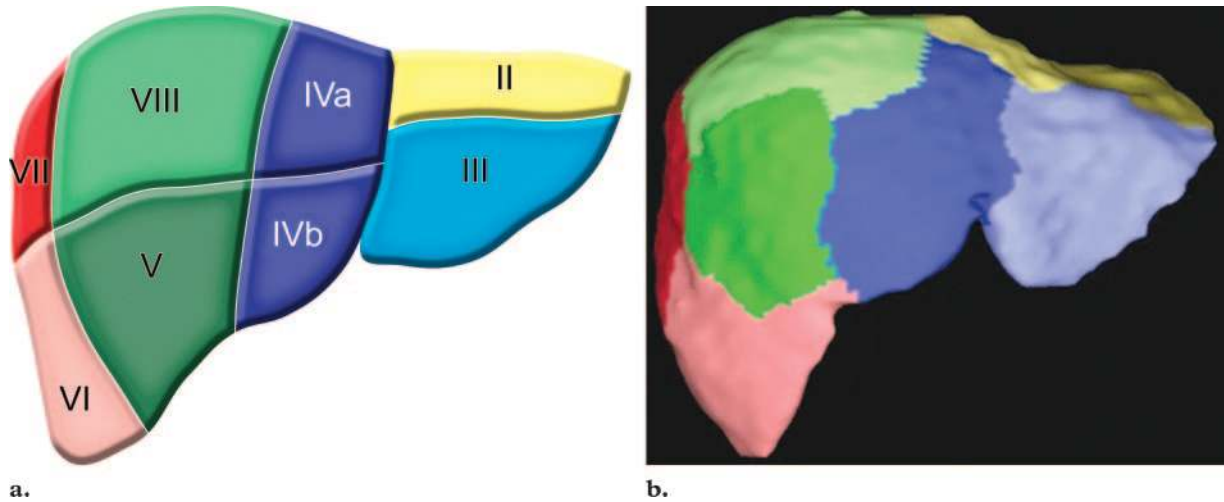
See last page

**Abbreviations:** BOPTA = benzyloxypropionictetraacetate, HAIP = hepatic arterial infusion pump, IVC = inferior vena cava, MIP = maximum intensity projection, 3D = three-dimensional

**RadioGraphics 2008;** 28:359–378 • **Published online** 10.1148/rg.282075099 • **Content Codes:** CT GI MR

<sup>1</sup>From the Department of Radiology, Division of Abdominal Imaging and Intervention (O.A.C., A.H.S., R.N.U., P.F.H., D.V.S.), and Department of Surgery (C.R.F.), Massachusetts General Hospital, 55 Fruit St, WHT 270, Boston, MA 02114. Presented as an education exhibit at the 2006 RSNA Annual Meeting. Received May 4, 2007; revision requested June 15 and received June 29; accepted July 3. D.V.S. receives research support from General Electric and consults for the Bracco Group; all other authors have no financial relationships to disclose. **Address correspondence to** D.V.S. (e-mail: [dsahani@partners.org](mailto:dsahani@partners.org)).

©RSNA, 2008



**Figure 1.** Hepatic segmental anatomy. Diagram (a) and corresponding color-coded three-dimensional (3D) CT image from a liver donor (b) show the various liver segments (except segment I).

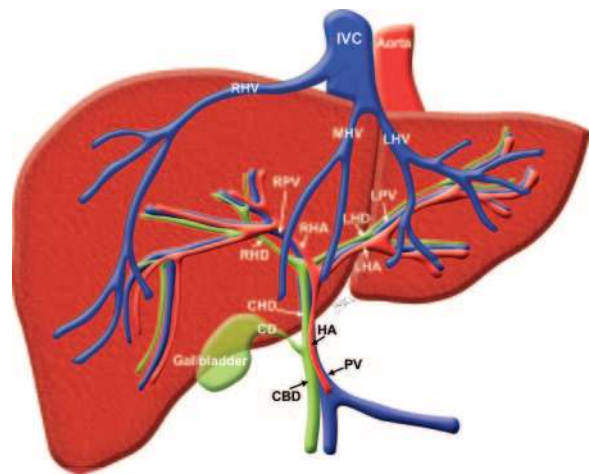
## Introduction

With the increasing complexity and prevalence of hepatobiliary surgery (eg, transplantation surgery and hepatic resection), a detailed preoperative evaluation of hepatic vascular and biliary anatomy is mandatory. The goals are to choose the best therapeutic approach, to reduce complications, and to identify the anatomy requiring special attention at surgery. Diagnostic imaging with multidetector computed tomography (CT) and magnetic resonance (MR) imaging allows accurate and noninvasive preoperative evaluation of the hepatobiliary anatomy (Figs 1, 2) (1,2).

In transplantation surgery, a road map of the biliary and arterial vascularity of the donor and recipient is a prerequisite for the procedure. Especially when there are arterial variants, accurate surgical planning and close monitoring of hepatic arterial patency are required.

Anatomic variants of the biliary and hepatic arterial anatomy are common, with the classic anatomy being found in only 58% and 55% of the population, respectively. Variant hepatic arterial anatomy not only dictates the surgical technique but may also predict the risk of hepatic arterial complications and of subsequent biliary strictures and liver abscesses. Unanticipated anatomic variants may necessitate additional anastomoses, increasing graft ischemia time and the risk of postoperative graft dysfunction (3).

In laparoscopic cholecystectomy, although the complication rate is less than 1%, some anatomic variants increase the risk of biliary or arterial injuries if unrecognized by the surgeon.



**Figure 2.** Normal anatomy of the liver. *CBD* = common bile duct, *CD* = cystic duct, *CHD* = common hepatic duct, *HA* = hepatic artery, *IVC* = inferior vena cava, *LHA* = left hepatic artery, *LHD* = left hepatic duct, *LHV* = left hepatic vein, *LPV* = left portal vein, *MHV* = middle hepatic vein, *PV* = portal vein, *RHA* = right hepatic artery, *RHD* = right hepatic duct, *RHV* = right hepatic vein, *RPV* = right portal vein.

Multidetector CT and MR imaging, especially when hepatobiliary contrast agents are used such as mangafodipir trisodium or gadolinium benzyl-oxypropionictetraacetate (BOPTA) for MR imaging, clearly depict both biliary and arterial anatomic variants, with a high degree of correlation with digital subtraction angiography and with intraoperative cholangiography.

## Imaging Techniques

### Multidetector CT

Multidetector CT, performed with intravenous injection of iodinated contrast medium, permits

**Table 1**  
**Protocol for Multidetector CT Angiography**

Parameter	Hepatic Arterial Phase	Venous Phase
Range	Entire liver	Entire liver
Scan delay		
Empirical (sec)*	20–25	60–65
Bolus tracking (HU)†	125	...
Pitch	1.0–1.5	1.0–1.5
Section thickness (mm)	1–2	2–5
Tube potential (kVp)	120–140	120–140
Tube current (mA)	200–280	200–280
Image reconstruction thickness (mm)	1–2 with 50% overlap	2–5 with 50% overlap

\*Time after the start of the bolus injection.

†Scanning is automatically triggered at 125 HU in the aorta at the celiac artery level.

single-breath-hold volumetric data acquisition during multiphase imaging. This allows angiographic and parenchymal evaluation of the liver. Thin-section scanning of large anatomic areas can be performed at speeds three to seven times faster than possible with single-detector helical CT scanners.

Multidetector CT angiography, a noninvasive technique, has demonstrated excellent correlation with conventional angiography results, but it is devoid of some of the negative aspects of conventional angiography, and it reduces both the costs and the radiation burden (1,2,4–7).

Despite the challenge related to the small caliber of normal bile ducts, multidetector CT can also be used for noninvasive evaluation of the biliary tract in potential living liver donors. Multidetector CT cholangiography is performed as follows: After intravenous infusion of 25 mg of diphenhydramine (Benadryl; Pfizer, New York, NY) to reduce the risk of allergic reactions, 20 mL of the cholangiographic contrast agent iodipamide meglumine 52% (Cholografin; Bracco Diagnostics, Princeton, NJ) diluted in 80 mL of normal saline is administered as a 30–60-minute infusion. Fifteen minutes after completion of the infusion, multidetector CT of the liver is performed with 2.5-mm collimation; images are reconstructed at 1.25-mm intervals with a reduced field of view.

It has been demonstrated that multidetector CT cholangiography, owing to its higher spatial resolution, allows better visualization of second-order bile ducts than conventional MR cholangiography and mangafodipir-enhanced excretory MR cholangiography, either alone or in combination (8).

Our multidetector CT angiography protocol is as follows: Imaging is performed after injection of a maximum of 150 mL of nonionic iodinated contrast material (iodine concentration, 300

mg/mL) through an 18–20-gauge antecubital intravenous cannula at a rate of 5–7 mL/sec. The multidetector CT angiography technique is summarized in Table 1.

### MR Imaging

MR imaging is an accurate and noninvasive technique for evaluating the hepatic vascular and biliary anatomy that is devoid of ionizing radiation and safe for patients who are allergic to iodinated contrast agents.

Improvements in contrast agents, with the development of hepatocyte-specific contrast agents with biliary excretion, like mangafodipir trisodium (Teslascan; Nycomed, Princeton, NJ) and gadobenate dimeglumine (MultiHance; Bracco, Milan, Italy), coupled with advancements in gradient performance, coil design, and MR angiography software, permit faster imaging with improved spatial resolution and excellent depiction of hepatic vascular and biliary anatomy (9).

The MR imaging protocol at our institution involves a 1.5-T system (Signa; GE Healthcare, Waukesha, Wis) with a phased-array torso coil.

For MR angiography, 40 mL of gadopentetate dimeglumine (Magnevist; Berlex, Montville, NJ) is injected intravenously with a power injector (Medrad; Indianola, Pa) at a rate of 2 mL/sec.

For MR cholangiography with mangafodipir trisodium, a 5  $\mu$ mol/kg dose (0.1 mL/kg, up to a maximum of 15 mL) is administered intravenously by means of slow injection over 1–2 minutes, followed by a 10-mL saline flush. The patient is imaged 15–30 minutes after the injection to obtain T1-weighted manganese-enhanced MR cholangiopancreatography images.

For MR cholangiography with gadobenate dimeglumine, a 0.05 mmol/kg dose (0.1 mL/kg,

**Table 2**  
**Protocol for MR Angiography**

Parameter	Hepatic Arterial Phase	Venous Phase	Delayed Venous Phase
Imaging delay (sec)	15–18	60	180
Repetition time	Minimum	Minimum	Minimum
Echo time (msec)	15	15	15
Flip angle (degrees)	100	100	100
Field of view (mm)	400	400	400
Effective section thickness (mm)	2–4	2–4	2–4
Matrix	160 × 256	160 × 256	160 × 256

**Table 3**  
**Protocol for MR Cholangiography**

Parameter	T2-weighted MR Cholangiopancreatography	3D Spoiled Gradient-Echo Imaging
Imaging delay (min)	None	15–60*
Repetition time (msec)	2800–3300	6.5
Echo time (msec)	900–1100	2.1
Flip angle (degrees)	0	15
Field of view (mm)	400	400
Effective section thickness (mm)	60	2.4
Orientation	Coronal oblique	Axial, coronal
Matrix	160 × 256	160 × 256

\*15–30 minutes with mangafodipir and 60 minutes with gadolinium-BOPTA.

**Table 4**  
**Postprocessing Views for Looking at Relevant Anatomic Variants**

Type of Anatomy	Best Postprocessing View	Relevant Variants*
Hepatic arterial	3D	Michel types II, III, V, and IX
Hepatic venous	Axial	Accessory right inferior hepatic vein
Portal venous	Coronal	Separate origin of the right posterior portal vein
Biliary	Coronal oblique	RPHD draining directly into the LHD, LHD draining into the RAHD, trifurcation, RPHD draining directly into the CHD

\*CHD = common hepatic duct, LHD = left hepatic duct, RAHD = right anterior hepatic duct, RPHD = right posterior hepatic duct.

up to a maximum of 15 mL) is administered intravenously by means of a power injector at a rate of 2 mL/sec, followed by a 20-mL saline flush. During intravenous administration, dynamic vascular images are acquired, with the same imaging delay and parameters used for the MR angiography protocol, as specified in Table 2. At 30–60 minutes after injection, the patient is again imaged to take advantage of the biliary excretion and to obtain T1-weighted gadolinium-enhanced MR cholangiopancreatography images.

The sequences used for MR angiography are listed in Table 2; those used for biliary MR imaging are listed in Table 3.

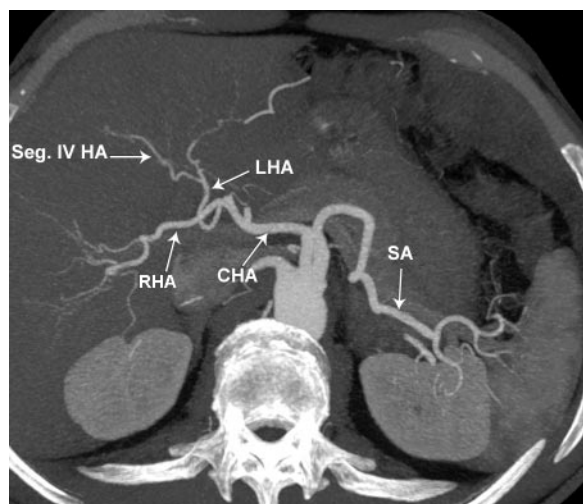
### Image Postprocessing

The raw imaging data obtained from multidetector CT or MR imaging are processed on a commercially available workstation (ADW 4; GE Healthcare) for multiplanar reformation as well as 3D reconstruction with maximum intensity projection (MIP) and volume rendering. The most useful planes for looking at the relevant anatomic variants on postprocessing views are listed in Table 4.

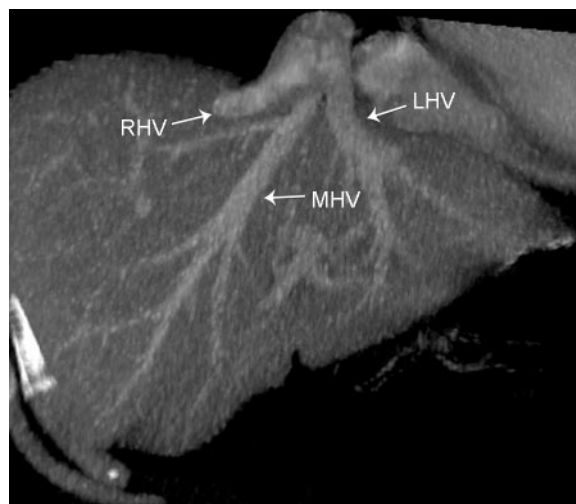
**Table 5**  
**Hepatic Arterial Variants according to the Michel Classification**

Type	Frequency (%)	Description*
I	55	RHA, MHA, and LHA arise from the CHA
II	10	RHA, MHA, and LHA arise from the CHA; replaced LHA from the LGA
III	11	RHA and MHA arise from the CHA; replaced RHA from the SMA
IV	1	Replaced RHA and LHA
V	8	RHA, MHA, and LHA arise from the CHA; accessory LHA from the LGA
VI	7	RHA, MHA, and LHA arise from the CHA; accessory RHA
VII	1	Accessory RHA and LHA
VIII	4	Replaced RHA and accessory LHA or replaced LHA and accessory RHA
IX	4.5	Entire hepatic trunk arises from the SMA
X	0.5	Entire hepatic trunk arises from the LGA

\*CHA = common hepatic artery, LGA = left gastric artery, LHA = left hepatic artery, MHA = middle hepatic artery, RHA = right hepatic artery, SMA = superior mesenteric artery.



**Figure 3.** Normal hepatic arterial anatomy in a 36-year-old living donor for liver transplantation. Axial MIP image shows the normal anatomy of the hepatic artery. *CHA* = common hepatic artery, *LHA* = left hepatic artery, *RHA* = right hepatic artery, *SA* = splenic artery, *Seg IV HA* = segment IV hepatic artery.



**Figure 4.** Hepatic venous confluence in a 47-year-old liver donor. Coronal MIP image from multidetector CT shows the confluence of the left hepatic vein (*LHV*), middle hepatic vein (*MHV*), and right hepatic vein (*RHV*).

## Vascular and Biliary Anatomy

### Hepatic Arterial Anatomy

The classic hepatic arterial anatomy, with the proper hepatic artery dividing into right and left hepatic arteries, is observed in approximately 55% of the population (Fig 3). The Michel classification of hepatic arterial variant anatomy is shown in Table 5 (1).

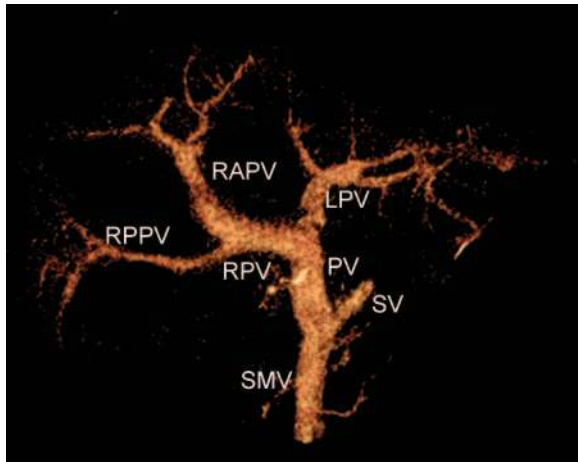
### Hepatic Venous Anatomy

In the classic hepatic venous anatomy, three main hepatic veins drain into the inferior vena cava (IVC). The left hepatic vein drains segments II and III, the middle hepatic vein drains segments

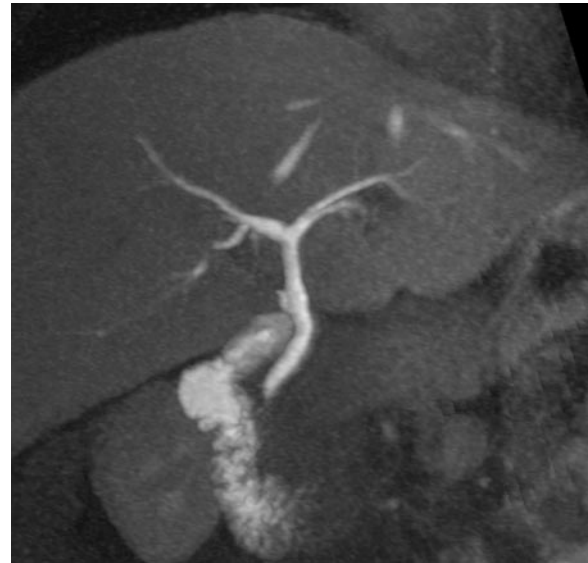
IV, V, and VIII, and the right hepatic vein drains segments V–VII. In approximately 60% of the population, the middle and left hepatic veins join to form a common trunk, which drains separately into the IVC (1,10,11) (Fig 4).

### Portal Venous Anatomy

The normal portal venous anatomy consists of the main portal trunk branching, at the porta hepatis, into the right and left portal veins, with the right portal vein subsequently dividing into anterior and posterior branches (12,13) (Fig 5).



**Figure 5.** Normal portal venous anatomy in a 52-year-old living donor for liver transplantation. Image from 3D CT portography shows the portal vein (PV) branching into the left portal vein (LPV) and right portal vein (RPV). The latter divides into the right anterior portal vein (RAPV) and right posterior portal vein (RPPV). SMV = superior mesenteric vein, SV = splenic vein.



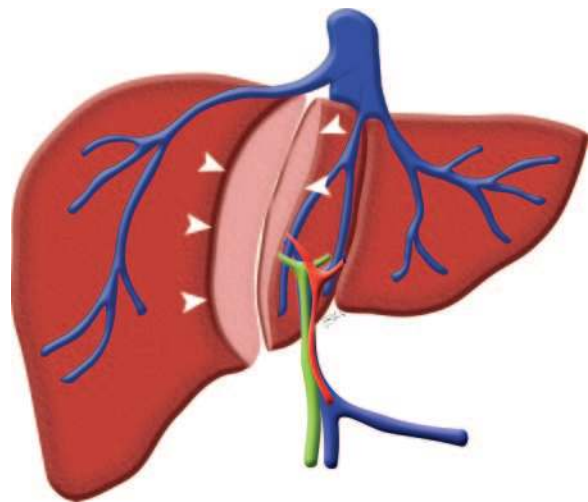
**Figure 6.** Normal biliary anatomy in a living liver donor. Coronal oblique image from 3D T1-weighted MR cholangiography, obtained after injection of mangafodipir trisodium, shows the right and left hepatic ducts draining the right and left lobes of the liver, respectively.

### Biliary Anatomy

The classic biliary anatomy appears in about 58% of the population and consists of the right hepatic duct and left hepatic duct draining the right and left lobes of the liver, respectively (Fig 6). The right duct branches into the right posterior hepatic duct, draining posterior segments VI and VII, and the right anterior hepatic duct, draining anterior segments V and VIII. The right posterior duct, which has a horizontal course, usually runs posterior to the right anterior duct, which is more vertically oriented, and fuses with it from a medial approach to constitute a short right hepatic duct. Segmental tributaries draining segments II–IV form the left hepatic duct. The fusion of the right and left hepatic ducts gives rise to the common hepatic duct. The caudate lobe usually drains to the origin of the left hepatic duct, or to the right hepatic duct. The cystic duct usually drains into the lateral aspect of the common hepatic duct below its origin (14).

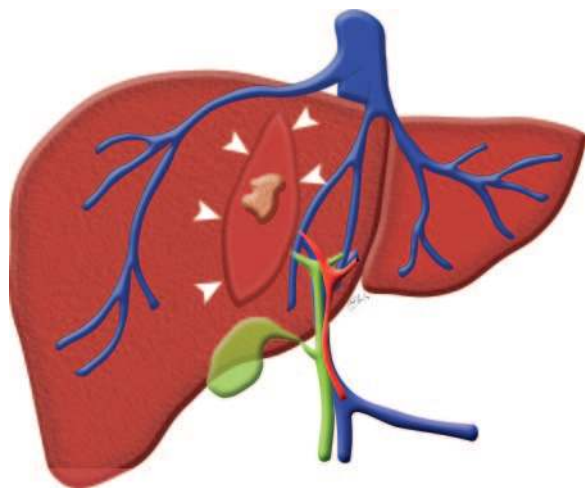
### Surgical Considerations

The most important concept to be kept in mind in the preoperative evaluation of a potential donor for living liver transplantation is the course of the hemihepatectomy plane. The incision is performed along a relatively avascular plane that separates the left and right lobes of the liver and runs 1 cm to the right of the middle hepatic vein, connecting the gallbladder fossa and IVC, close to the so-called Cantlie line (Fig 7).



**Figure 7.** Diagram shows the hemihepatectomy plane (arrowheads). This plane connects the gallbladder fossa and IVC and runs 1 cm to the right of the middle hepatic vein.

#### Teaching Point



**Figure 8.** Hepatectomy for a liver neoplasm requires complete tumor resection with tumor-free margins (arrowheads). In addition, the vascular supply and drainage of the residual liver need to be preserved.

The left lobe of the liver is left in the donor, while the right lobe is harvested for transplantation into the recipient; attention must be paid to ensure adequate metabolic vitality to both of them. Therefore, major vessels traversing the hepatectomy plane must be preoperatively identified to avoid damage with subsequent ischemic injury to the graft or the donor liver. Some of these anomalies may require modification of the surgical procedure or may even contraindicate the surgery to avoid irreversible damage to the donor liver; examples are provided later (15).

Hepatic tumor resection, mainly performed to treat hepatic metastasis, is another growing surgical field in which preoperative evaluation of vascular and biliary anatomy is of compelling importance.

About 50% of patients with colorectal cancer, the third most common malignancy in Western countries, develop hepatic metastases. Liver metastases are responsible for death in at least two-thirds of colorectal cancer patients with liver metastases. The only potentially curative treatment for these patients is liver resection, after which the 5-year overall survival rate, in selected patients, is 37%–58% (16).

The combination of advancements in diagnostic imaging, with more accurate preoperative staging, and of improvements in surgical techniques, has allowed increasingly complex liver surgeries to be performed with resultant reduction in the

number of patients undergoing nontherapeutic laparotomy (17).

Preoperative selection of patients with colorectal metastases relies heavily on diagnostic imaging, since the treatment strategy depends not only on distinguishing patients with or without liver metastases but also on assessing the number, size, location, and surgical margin of the liver metastases (Fig 8). The anticipated remaining liver needs to be evaluated in order to assess the ability to preserve sufficient remnant liver (>20% in a healthy liver), adequate vascular inflow and outflow as well as biliary drainage, and two contiguous hepatic segments (18,19).

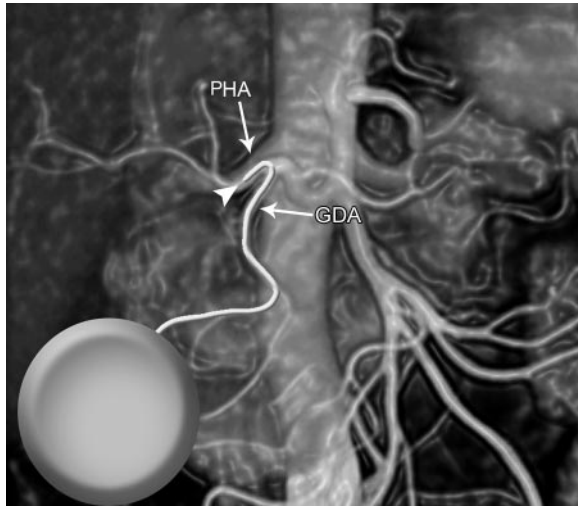
Multidetector CT and MR imaging, with the added value of postprocessed images, may allow accurate identification of areas at risk for venous congestion or devascularization, potentially influencing surgical planning with regard to the extent of hepatic resection or the need for vascular reconstructions.

The value of diagnostic imaging is even greater in cases of small residual liver volume or in patients with compromised hepatic function (eg, in hepatic cirrhosis), where minor complications such as partial hepatic necrosis or bile leakage may be fatal.

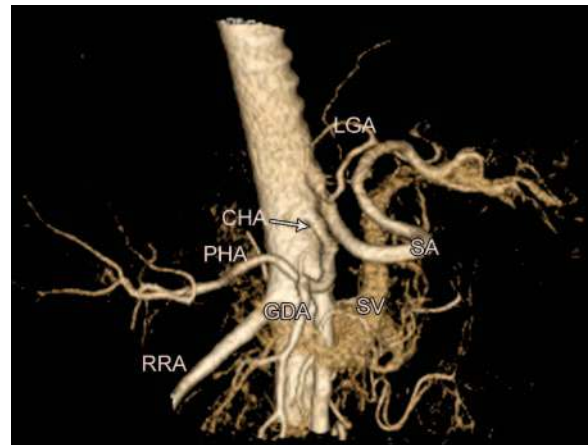
Owing to the greater variability of the right intrahepatic vascular anatomy, resections extensively involving the right hepatic lobe rely heavily on preoperative assessment of the liver with diagnostic imaging to detect vascular and biliary anatomic variants (20).

Another emerging surgical and radiologic field is intraarterial chemotherapy treatment of hepatic metastasis. After hepatic resection for colorectal cancer metastases, a combination of hepatic intraarterial chemotherapy and systemic chemotherapy is useful to treat micrometastases in the remaining liver and to prevent extrahepatic spread of malignancy.

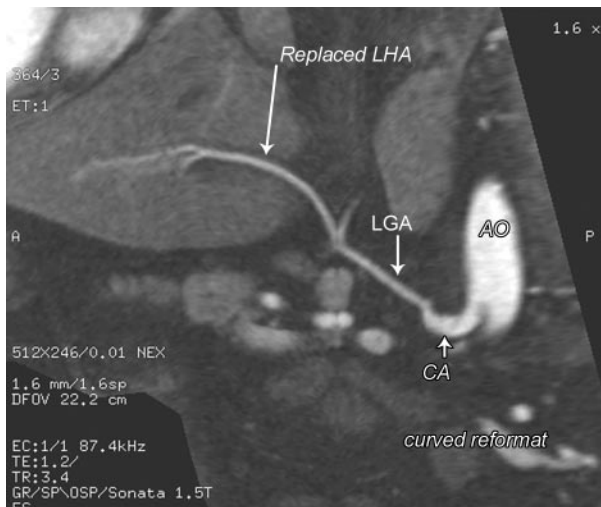
Hepatic intraarterial chemotherapy plus systemic chemotherapy has been compared with systemic therapy alone, and the combination has been demonstrated to decrease the rate of hepatic recurrence and to improve 2-year overall survival. Intraarterial chemotherapy infusion relies on the fact that hepatic metastases derive most of their blood supply from the hepatic artery, whereas



**Figure 9.** Placement of an HAIP catheter. Drawing shows an HAIP catheter inserted through the gastrooduodenal artery (*GDA*). The catheter tip (arrowhead) is then advanced into the proper hepatic artery (*PHA*).

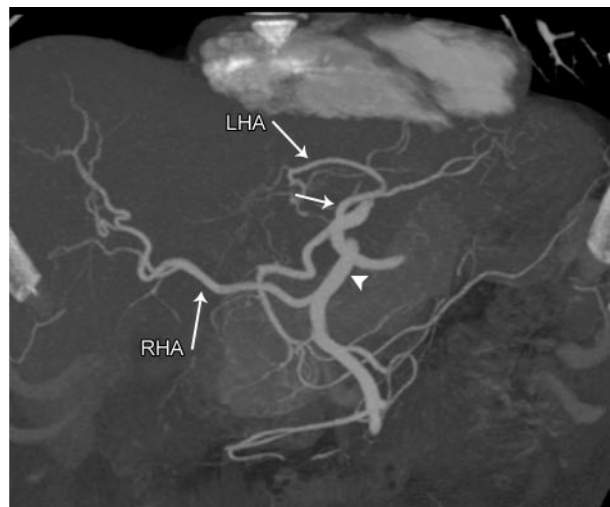


**Figure 10.** Variant hepatic arterial anatomy in a 49-year-old liver donor. Three-dimensional volume-rendered image from multidetector CT shows the common hepatic artery (*CHA*), splenic artery (*SA*), and left gastric artery (*LGA*) arising separately from the aorta. *GDA* = gastrooduodenal artery, *PHA* = proper hepatic artery, *RRA* = right renal artery, *SV* = splenic vein.



11.

**Figures 11, 12.** (11) Replaced left hepatic artery in a 42-year-old living donor for liver transplantation. Curved MIP image from multidetector CT shows a replaced left hepatic artery (*LHA*) arising from the left gastric artery (*LGA*). *AO* = aorta, *CA* = celiac artery. (12) Replaced right and left hepatic arteries in a 38-year-old man scheduled for liver transplantation. Coronal MIP image from multidetector CT shows a replaced left hepatic artery (*LHA*) from the gastric artery (arrow) and a replaced right hepatic artery (*RHA*) from the superior mesenteric artery (arrowhead).



12.

normal liver tissue is mainly perfused by the portal vein (21). Therefore, hepatic arterial infusion pumps (HAIPs) allow delivery of maximum doses of chemotherapeutic agents to hepatic malignancies and reduced amounts to normal liver tissue and other organs, minimizing chemotherapeutic toxicity (1).

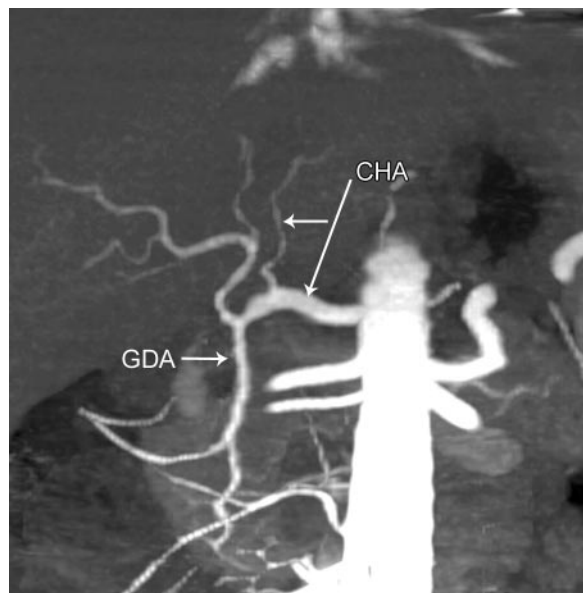
The success of hepatic arterial chemotherapy relies on accurate patient selection and surgical expertise in HAIP placement. The catheter must be inserted so as to ensure adequate and homogeneous distribution of the chemotherapy to the liver without perfusion of extrahepatic tissues. In order to preserve the long-term patency of the catheter and of the cannulated artery, the catheter tip must not create turbulence in the hepatic artery (Fig 9) (22,23).



**Table 6**  
**Hepatic Arterial Variants and Liver Transplantation**

Arterial Variants	Implications for Surgery
Variants relevant in donors	
MHA from the RHA	The hepatic plane would cut this artery, compromising arterial supply to the left lobe of the liver
CHA trifurcation into the RHA, LHA, and GDA	Clamping or ligation of the CHA can cause gastric or duodenal hypoperfusion
RHA or LHA from the CHA before origin of the GDA	Clamping or ligation of the CHA can cause gastric or duodenal hypoperfusion
Variants relevant in recipients	
Short RHA	Increases surgical complexity and can lead to difficult anastomosis
Celiac artery stenosis	Increases risks of graft failure and biliary complications
Replaced or accessory LHA (Michel types II and V)	Increases complexity of the surgery
Replaced hepatic trunk arising from the SMA (Michel type IX)	Increases complexity of the surgery

Note.—CHA = common hepatic artery, GDA = gastroduodenal artery, LHA = left hepatic artery, MHA = middle hepatic artery, RHA = right hepatic artery, SMA = superior mesenteric artery.



**Figure 13.** Early branching of the left hepatic artery in a living donor for liver transplantation. CT angiogram shows early branching of the left hepatic artery (arrow) from the common hepatic artery (CHA) before takeoff of the gastroduodenal artery (GDA).

### Vascular and Biliary Variants Relevant to Surgery

#### Hepatic Arterial Variants

Because of the considerable variability of hepatic arterial anatomy (Fig 10), assessment of this anatomy is crucial in the preoperative evaluation of

potential living liver donors (24). **Not all the anatomic variants have the same level of importance. It varies depending on whether the variants are found in the donor or in the recipient.** A replaced or accessory left hepatic artery from the left gastric artery is not important in a donor, whose left lobe is going to be left in place, but it is relevant in a recipient because, during native liver removal, extra steps are required to ligate it at the origin (Fig 11). A variant origin of the artery to the medial segment of the left hepatic lobe (segment IV) is not important in the recipient, but it is extremely relevant in the donor because the hepatectomy plane would cut the arterial supply of this segment. Other variants, such as a replaced right hepatic artery from the superior mesenteric artery, require extra surgical steps in both the donor and the recipient (Fig 12) (25).

Arterial variants relevant in donors and in recipients are summarized in Table 6 (Fig 13).

**Not all hepatic vascular variants are surgically relevant in hepatic tumor resection. The level of importance and influence on surgical technique mainly depend on the spatial relationship of the arterial variant to the tumor, to prevent injury to aberrant hepatic vessels and consequently to the hepatic parenchyma secondary to liver and biliary ischemia and to ensure complete tumor-free resection margins.** Although vascular and biliary

Teaching Point

Teaching Point

**Table 7**  
**Hepatic Arterial Variants and Relevance for Tumor Resection**

Arterial Variants*	Michel Type	Left Lobe Resection	Right Lobe Resection
Replaced LHA from the LGA	II	Yes	No
Replaced RHA from the SMA	III	No	Yes
Replaced RHA and LHA	IV	Yes	No
Accessory LHA from the LGA	V	Yes	No
Accessory RHA	VI	No	Yes
Accessory RHA and LHA	VII	Yes	Yes
Replaced RHA and accessory LHA or replaced LHA and accessory RHA	VIII	Yes	Yes
Entire hepatic trunk from the SMA	IX	Yes	Yes
Entire hepatic trunk from the LGA	X	Yes	Yes

\*LGA = left gastric artery, LHA = left hepatic artery, RHA = right hepatic artery, SMA = superior mesenteric artery.

**Table 8**  
**Hepatic Venous Variants and Liver Transplantation**

Venous Variants*	Implications for Surgery
Variants relevant in donors	
Accessory inferior RHV > 3 mm	Increases surgical complexity, and the surgical technique must be modified
Variants relevant in recipients	
Accessory inferior RHV draining into the IVC > 3 cm from the main hepatic venous confluence with the IVC	Increases surgical complexity, and the surgical technique must be modified
Early branching of the segment VIII vein	Increases surgical complexity, and the surgical technique must be modified
Anomalous drainage of segments V and VII into the MHV	Risk of medial sector congestion and atrophy
Early confluence of the hepatic veins	Increases surgical complexity, and the surgical technique must be modified

\*MHV = middle hepatic vein, RHV = right hepatic vein.

anatomic variants need to be evaluated on a case-by-case basis, Table 7 summarizes some of the most important variants relevant to hepatic tumor surgery, according to which liver lobe contains the tumor.

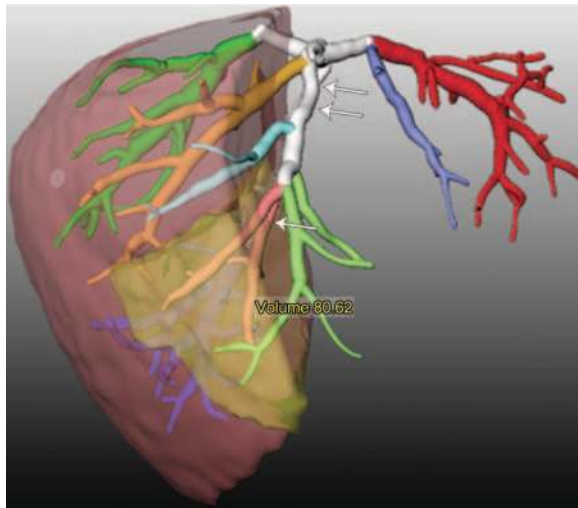
### Hepatic Venous Variants

A key point to successful living donor liver transplantation is to maintain the balance between the blood supply and venous drainage of the graft. Venous congestion can seriously damage the graft, causing its failure; therefore, even small hepatic venous branches, which run along the parenchymal dissection plane, need to be left intact or reconstructed (26).

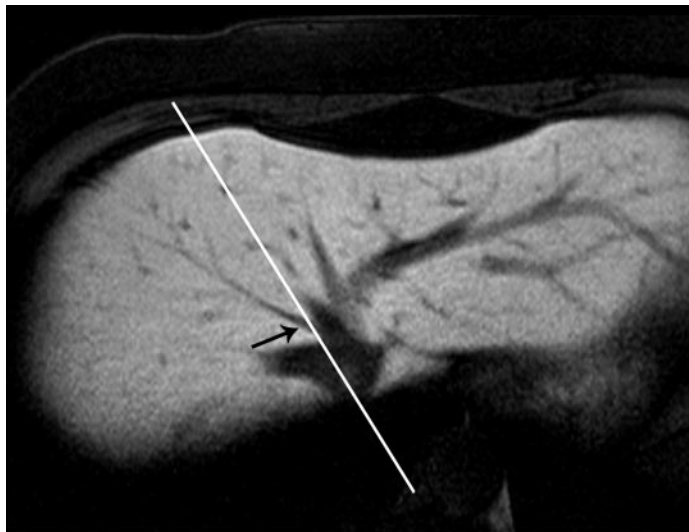
#### Teaching Point

Information relevant for the surgeon concerns the pattern of venous drainage into the IVC and around the hemihepatectomy plane. The branching pattern of the middle hepatic vein needs to be carefully scrutinized because it affects the location of the hepatectomy plane. Hepatic venous branches draining segments VIII and V may empty into the middle hepatic vein (Fig 14). A branch draining the right superior anterior segment (segment VIII) into the middle hepatic vein may be present in 9% of the population and has important implications, requiring extra surgical steps to avoid venous congestion of the segment (known as medial sector venous congestion) and segmental necrosis and atrophy (Fig 15) (25,26).

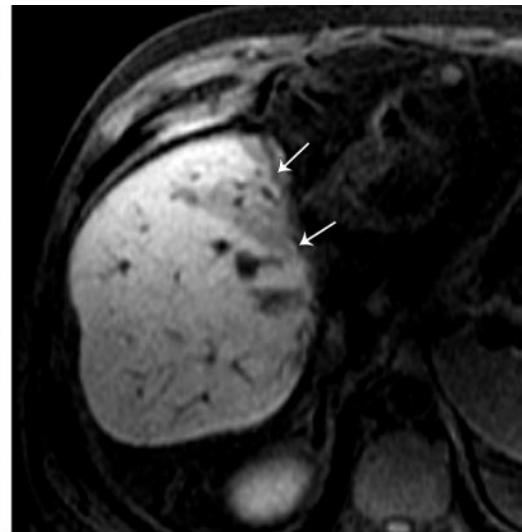
A venous anomaly relevant in donors is an accessory inferior right hepatic vein draining directly into the IVC, usually draining segment VI



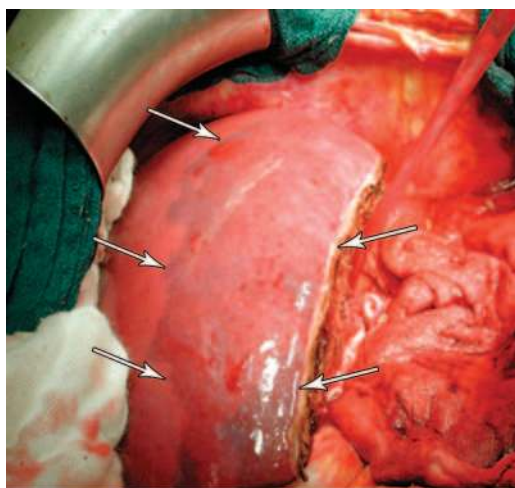
**Figure 14.** Segment V drainage into the middle hepatic vein. Color-coded 3D image shows the drainage of segmental liver anatomy from middle hepatic vein tributaries along the surgical plane (Cantlie line) for right hepatectomy. The image was created from multidetector CT data by using dedicated software (MeVis; MeVis Technology, Bremen, Germany). Drainage of segment V (single arrow) is into the middle hepatic vein (double arrows). The volume of the segment V drainage (light brown region) is about 80 mL; therefore, the vitality of this segment needs to be preserved despite the increased surgical difficulties.



a.



b.



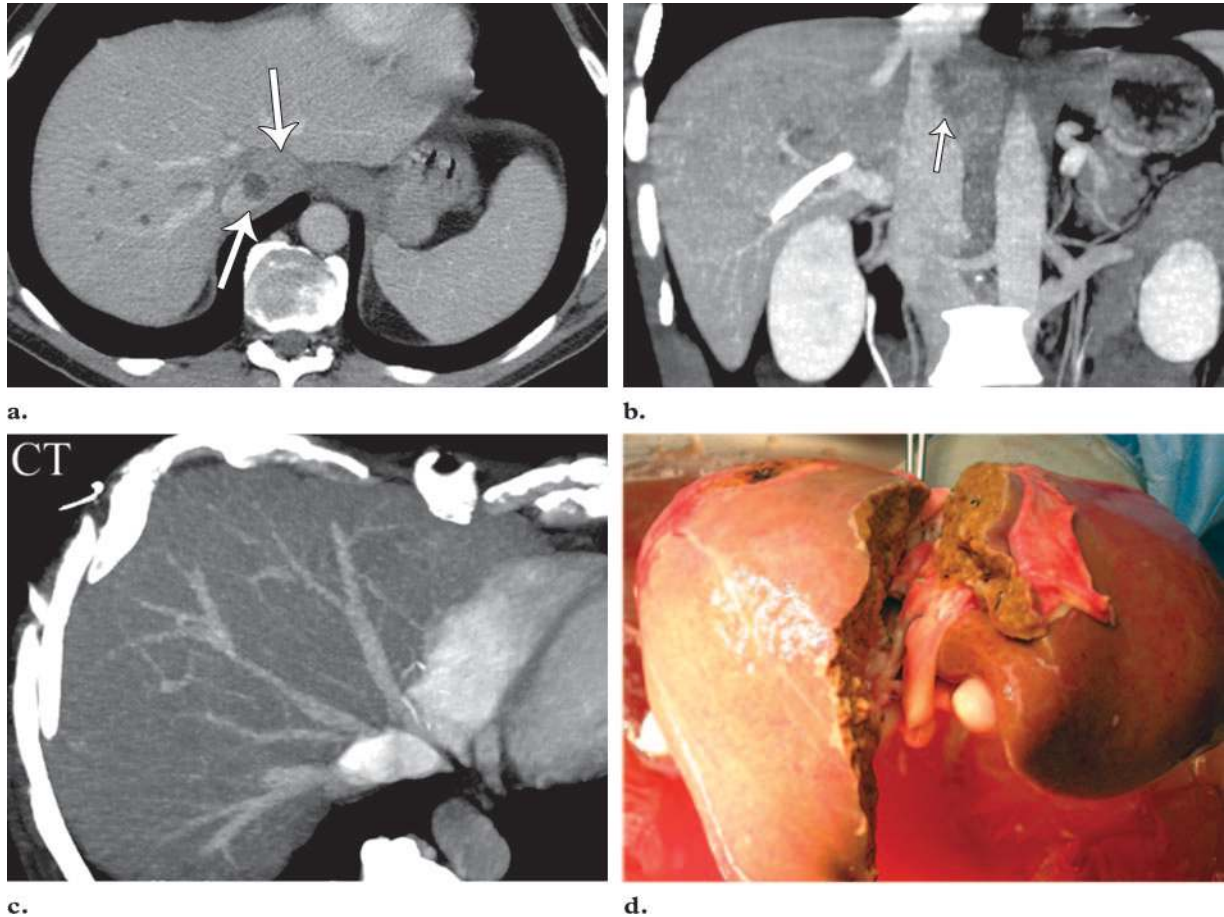
c.

**Figure 15.** Segment VIII drainage into the middle hepatic vein. (a) Axial T1-weighted MR image of a 46-year-old living donor for liver transplantation shows a tributary vein (arrow) draining segment VIII into the middle hepatic vein. The hemihepatectomy plane (white line) intersects the accessory vein before its confluence with the IVC. (b) Postoperative axial T1-weighted MR image of the recipient shows atrophy of the corresponding liver segment (arrows). (c) On a corresponding photograph obtained during the surgical procedure, the hepatic parenchyma drained by the accessory hepatic vein appears congested (arrows).

or VII, rarely segment V. The anomaly may be seen in as many as 47% of cases. Sometimes more than one vessel may be found. In preoperative

planning, it is important to highlight not only the presence and number of these accessory veins but also their size and their distance from the main hepatic venous drainage site along the IVC. When this distance is more than 40 mm, it may be technically difficult to implant both veins into the recipient's IVC (25).

Venous variants relevant in donors and in recipients are summarized in Table 8.



**Figure 16.** Cholangiocarcinoma in a 53-year-old man. **(a, b)** Axial **(a)** and coronal **(b)** images from preoperative multidetector CT angiography show a tumor (arrows) that touches the IVC. **(c)** MIP image of the hepatic venous confluence and hepatic arteries shows lack of involvement of the critical vasculature. **(d)** Photograph shows that surgical removal of the cholangiocarcinoma was possible with ex situ resection.

**Table 9**  
**Hepatic Venous Variants and Relevance for Tumor Resection**

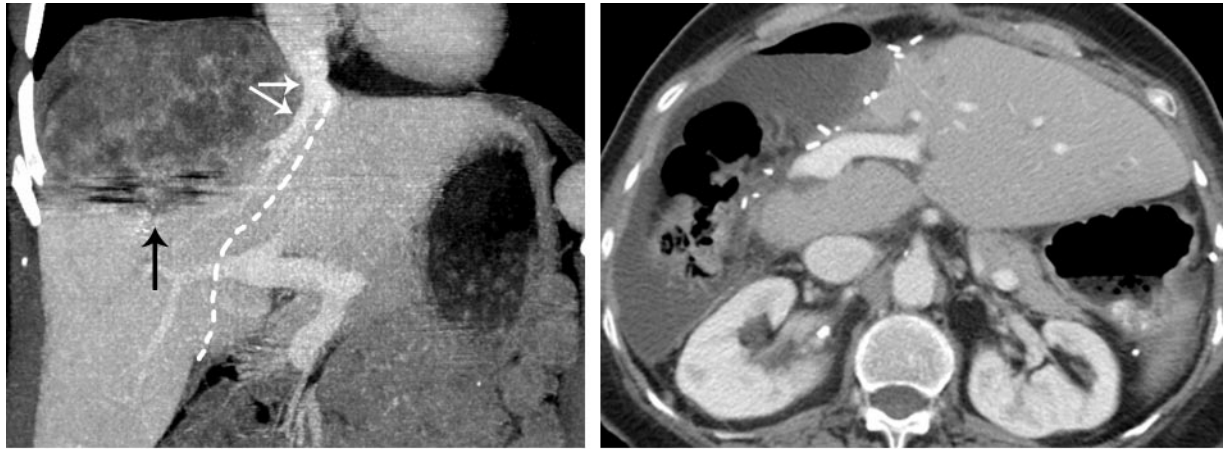Venous Variant*	Left Lobe Resection	Right Lobe Resection
Segment VIII drainage into the MHV	Yes	No
Segment V and VI accessory inferior hepatic veins draining directly into the IVC	No	Yes
Accessory MHV draining directly into the IVC	Yes	No

\*MHV = middle hepatic vein.

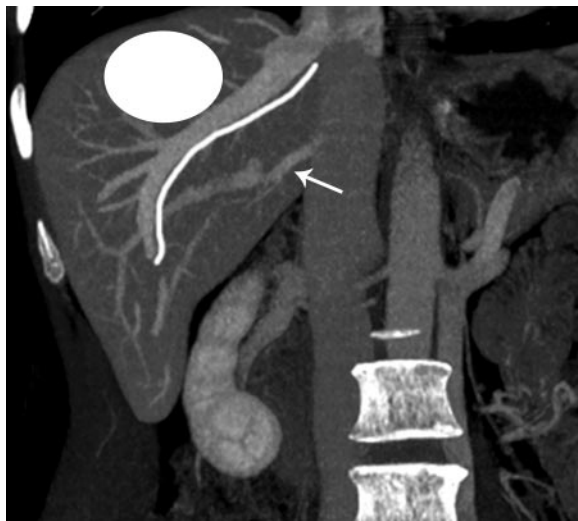
Not all hepatic venous variants are surgically relevant in hepatic tumor resection. The level of importance and influence they exert on surgical technique mainly depend on their spatial relationship to the tumor, to prevent injury to aberrant hepatic vessels and to hepatic parenchyma (ischemia and venous congestion) and to ensure complete tumor-free resection margins (Figs 16, 17). In the case of a right lobe hepatic tumor, accessory inferior hepatic veins, which usually drain

segments V and VI directly into the IVC, require additional surgical steps to be clamped or ligated. This increases the time required for the surgery and its complexity. In the case of left hepatectomy, if a large tributary vein drains segment VIII into the MHV, resection of the MHV may result in impairment of segment VIII venous drainage, with subsequent congestion, ischemia, and atrophy; therefore, extra surgical steps may be required and must be planned in advance.

Depending on the location of the tumor, vascular variants can sometimes be useful to perform unusual partial hepatectomies, providing suffi-

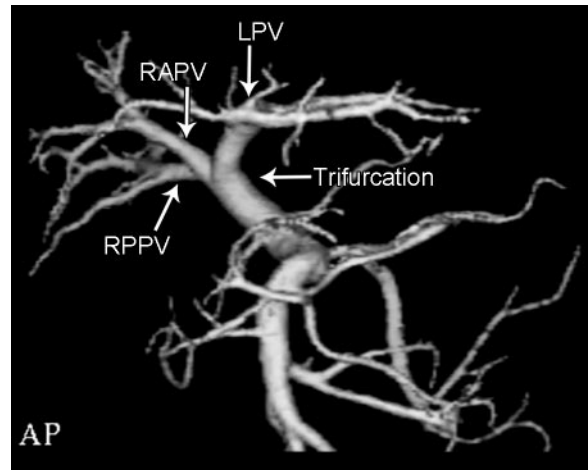


**Figure 17.** Extended hepatectomy for a right lobe metastasis in a 72-year-old woman with colorectal cancer. **(a)** Preoperative coronal CT image shows a tumor (black arrow) in the superior segments of the right hepatic lobe; the tumor compresses the IVC and middle hepatic vein (white arrows). Therefore, an extended right hepatectomy was performed that included the middle hepatic vein and a portion of segment IV to achieve tumor-free resection margins. **(b)** Postoperative axial CT image shows a perfused residual lobe, indicating that the extended right hepatectomy was successful.



**Figure 18.** Unusual partial hepatectomy for tumor resection in a patient with a vascular variant. Image shows a tumor (white oval) in liver segment VII. The patient has an accessory inferior right hepatic vein (arrow) that drains into the IVC more than 40 mm from the confluence with the main right hepatic vein. Owing to this vascular variant, an unusual partial hepatectomy (white line) was performed, which allowed safe resection without loss of the posterior-inferior segment.

cient hepatic tissue to ensure tumor-free resection margins without impairing vascular drainage and supply to the remainder of the liver. For example, a tumor located in segment VII, in a patient with an accessory right inferior hepatic vein, draining more than 40 mm from the confluence of the main right hepatic vein with the IVC, can be safely resected without taking away the posterior-inferior segment (Fig 18).



**Figure 19.** Portal vein trifurcation in a 52-year-old man undergoing right hepatectomy for hepatocellular carcinoma. Three-dimensional volume-rendered image (inferior oblique view) from CT angiography shows trifurcation of the portal vein into the right anterior portal vein (*RAPV*), right posterior portal vein (*RPPV*), and left portal vein (*LPV*).

A summary of some of the most important venous variants relevant to surgery, according to which lobe of the liver contains the tumor, is provided in Table 9.

**Portal Venous Variants**

Portal vein trifurcation is found in 10%–16% of patients (Fig 19). Although this variant does not

**Table 10**  
**Portal Venous Variants and Liver Transplantation**

Portal Venous Variants	Implications for Surgery
Variants relevant in donors	
Trifurcation of the portal vein	Surgical planning must be modified because of lack of a portal segment to clamp during surgery, as well as to prevent bleeding in the donor and difficult anastomosis in the recipient
Portal venules to segment V	Surgical planning must be modified to avoid bleeding and ischemia
Variants relevant in recipients	
Dorsal branch of segment VII supplying the posterior-superior area of the right lobe	Surgical planning must be modified to prevent ischemia in the recipient
Trifurcation of the portal vein	Surgical planning must be modified because of lack of a portal segment to clamp during surgery, as well as to prevent bleeding in the donor and difficult anastomosis in the recipient
Acute angle of portal vein branching	During regeneration, the liver may engulf the veins and reduce blood supply, causing ischemia in the graft
Short length of the portal vein	May cause allograft failure

**Table 11**  
**Portal Venous Variants and Relevance for Tumor Resection**

Portal Venous Variant	Left Lobe Resection	Right Lobe Resection
Trifurcation of the portal vein	Yes	No
Right and left portal vein branches supplying segment VIII	No	Yes

represent a contraindication to surgery, it needs to be known before the operation because extra surgical steps are necessary for isolation of portal vein branches.

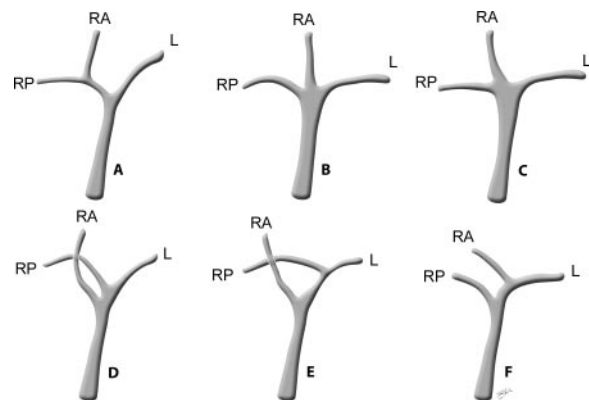
The distance between the bifurcation of the left portal vein and that of the right portal vein must be ascertained preoperatively because of its implications for the surgical technique (25,27).

Table 10 summarizes portal venous variants relevant in donors and in recipients.

In patients with complex anatomy, multiplanar images and 3D reconstructions may be useful to clarify the relationships of the tumor to the vascular anatomy, helping the surgical planning (1). Portal variants relevant for tumor resection surgery are reported in Table 11.

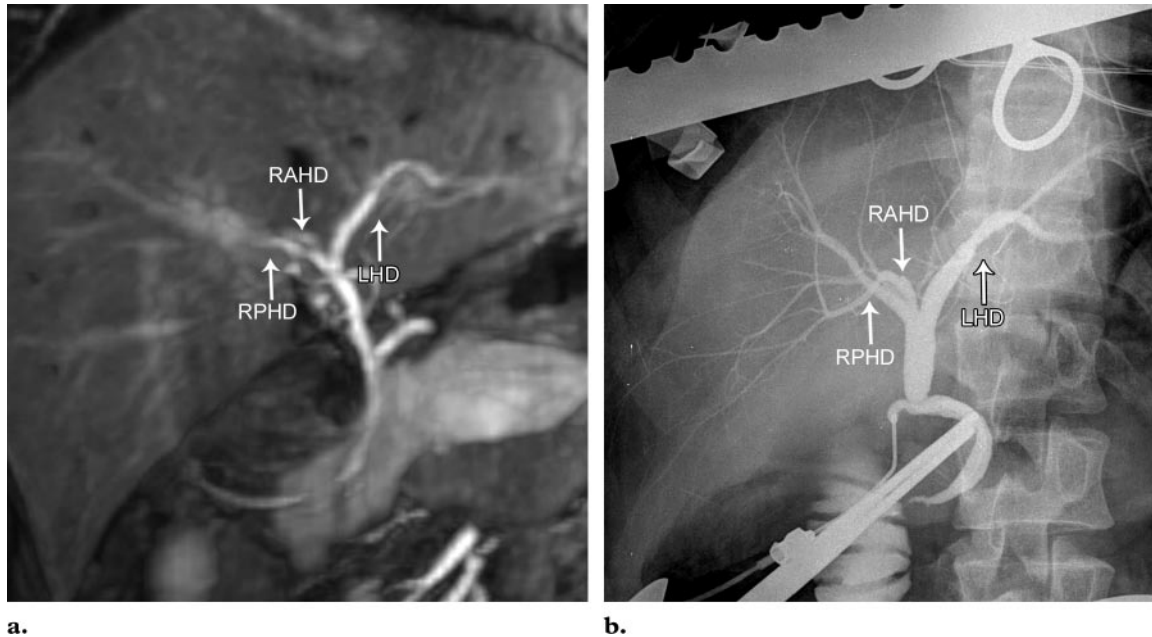
### Biliary Variants

Biliary complications, occurring in 7%–10% of donors, represent the most common cause of morbidity in living donor liver transplantation; they include bile leakage and bile duct stricture. Postoperative bile leakage can occur in different locations, but mainly occurs at the caudate

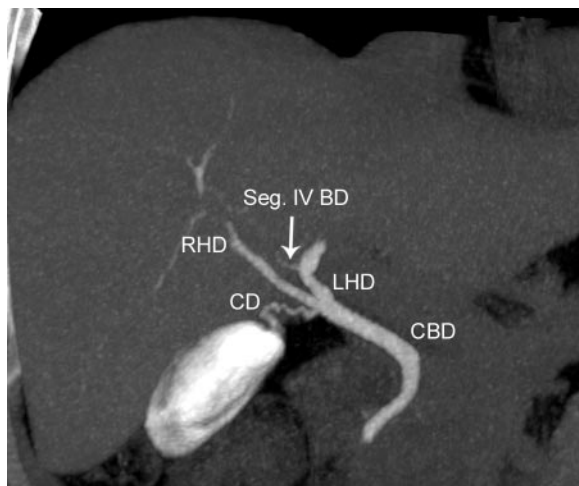


**Figure 20.** Normal and variant bile duct anatomy. L = left hepatic duct, RA = right anterior hepatic duct, RP = right posterior hepatic duct. Drawings show the normal anatomy (A), trifurcation (B), a short right hepatic duct (C), continuation of the right anterior hepatic duct into the common hepatic duct (D), drainage of the right posterior hepatic duct into the left hepatic duct (E), and drainage of the right anterior hepatic duct into the left hepatic duct (F).

branches in the hilar plate. Bile leakage may also occur at the repair site of the hepatic duct and rarely along the parenchymal transection surface of the liver.



**Figure 21.** Biliary trifurcation in a 52-year-old liver donor. *LHD* = left hepatic duct, *RAHD* = right anterior hepatic duct, *RPHD* = right posterior hepatic duct. **(a)** Mangafodipir-enhanced MIP image from preoperative MR cholangiography shows biliary trifurcation. **(b)** Corresponding intraoperative cholangiogram shows the variant biliary anatomy.



**Figure 22.** Segment IV drainage into the left hepatic duct in a 64-year-old man with a right lobe liver metastasis from colorectal cancer. Coronal MIP image from 3D multidetector CT cholangiography, performed after intravenous administration of iodipamide meglumine, shows the segment IV bile duct (*Seg IV BD*) draining into the left hepatic duct (*LHD*). *CBD* = common bile duct, *CD* = cystic duct, *RHD* = right hepatic duct.

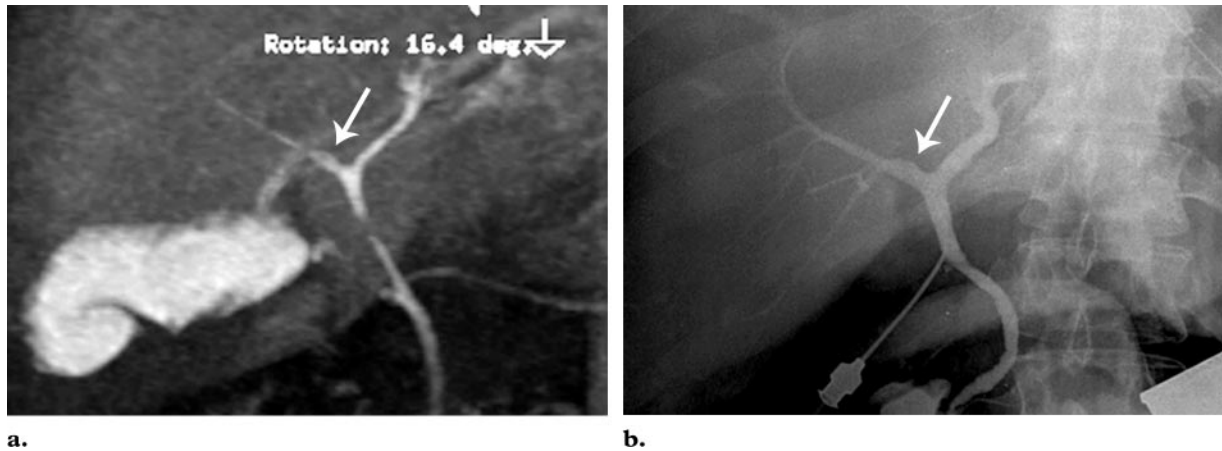
It has been demonstrated that detailed preoperative evaluation of biliary anatomic variants with CT cholangiography or MR cholangiopancreatography is useful for preventing this type of complication, helping the surgeons safely perform hepatectomy in the donor and biliary reconstruction in the recipient (Fig 20) (28,29). In the set-

ting of preoperative evaluation of the liver, T2-weighted MR cholangiopancreatography may be inadequate for identification of the intrahepatic biliary ducts and of biliary variants.

Mangafodipir trisodium (manganese dipyridoxyl diphosphate [Mn-DPDP]) and gadolinium-BOPTA are hepatospecific MR contrast agents, excreted into the biliary system, that produce T1 shortening of the bile. Mn-DPDP-enhanced 3D MR cholangiopancreatography has been demonstrated to be both sensitive and specific in identifying variants of the intrahepatic bile ducts (9,29).

One of the most common bile duct variants, found in 15.6% of cases in one series, is the right posterior hepatic duct draining into the left hepatic duct. This variant can lead to inadvertent biliary tract injury in the donor. Other common clinically relevant anatomic variants of the biliary tract that may complicate transplantation surgery include a posterior-inferior branch of the right hepatic duct draining into the left hepatic duct and biliary trifurcation (Fig 21). In some centers, biliary trifurcation may preclude graft harvesting because of the increase in the postoperative complication rate.

However, it has been demonstrated that accurate presurgical assessment of biliary anatomy variants, performed with multidetector CT cholangiography (Fig 22) or MR



**Figure 23.** Variant biliary anatomy in a 47-year-old living donor for liver transplantation. T1-weighted MIP image from 3D cholangiography (**a**) and intraoperative conventional cholangiogram (**b**) show early branching of the right hepatic duct (arrow).

cholangiopancreatography (Fig 23), allows surgeons to plan their approach before beginning the procedure and helps prevent biliary tract injuries, resulting in a low biliary complication rate of 1.9% in one series (28,30,31).

Biliary complications are also an important cause of major morbidity in hepatic tumor resection, with a prevalence of 3.6%–8.1% and high associated risks for liver failure (35.7%) and surgical mortality (39.3%). One of the most serious biliary complications is bile leakage, which has been demonstrated to increase when the resection is extended to segment I or IV. Anatomic factors, like the complexity of bile duct confluence and the variability of the left intrahepatic bile ducts, account for the higher prevalence of biliary complications after left-sided hepatectomy.

Despite advancements in hepatic resection surgical techniques, like use of an ultrasonic dissector, the prevalence of biliary complications has not substantially changed. Therefore, to delineate possible anatomic variants in the biliary tract, preoperative biliary diagnostic imaging is recommended before left-sided hepatic resection, particularly if extended hepatectomy or trisegmentectomy needs to be performed (32,33).

A summary of bile duct variants relevant in donors and in recipients is shown in Table 12,

and a summary of relevant bile duct variants in partial hepatic resection for tumor treatment is shown in Table 13.

Bile duct injuries can occur after either open or laparoscopic cholecystectomy. Today, laparoscopic surgery is the standard of care for treatment of cholelithiasis, but the risks of bile duct injuries associated with this technique are increased compared with open surgery. Variant biliary anatomy is one of the factors that may contribute to the occurrence of bile duct injury after laparoscopic cholecystectomy (34).

An aberrant right hepatic duct, which occurs in 3.2%–18.0% of patients, drains part of the right lobe of the liver directly into the extrahepatic biliary tree. Being close to the cystohepatic angle (formed by the cystic duct and gallbladder below, the right lobe of the liver above, and the common hepatic duct medially), the aberrant duct may undergo accidental transection or ligation during cholecystectomy and therefore complications may ensue. These complications include formation of a biliary fistula, biloma, sepsis, pain, and repetitive episodes of cholangitis. If the volume of parenchyma drained by the ligated duct is not small, biliary atrophy with resultant jaundice may occur (35).

In about 10% of the population, the cystic duct runs for a long length paralleling the common hepatic duct, within a common fibrous sheath. This variant anatomy, if not recognized, may



**Table 12**  
**Biliary Duct Variants and Liver Transplantation**

Biliary Variants*	Prevalence (%)
Variants relevant in donors	
RPHD draining directly into the LHD	13–19
Trifurcation†	11
RPHD draining directly into the CHD	5
Accessory hepatic ducts	2
Variants relevant in recipients	
LHD draining into the RAHD	4
Trifurcation†	11
Cystic duct draining into the RHD	~0 (very unusual)
Accessory hepatic ducts	2

\*CHD = common hepatic duct, LHD = left hepatic duct, RAHD = right anterior hepatic duct, RHD = right hepatic duct, RPHD = right posterior hepatic duct.

†Simultaneous emptying of the RAHD, RPHD, and LHD into the CHD.

**Table 13**  
**Biliary Duct Variants and Relevance for Tumor Resection**

Biliary Variant*	Left Lobe Resection	Right Lobe Resection
RPHD draining directly into the LHD	Yes	No
LHD draining directly into the RHD	No	Yes
Trifurcation†	Yes	Yes

\*CHD = common hepatic duct, LHD = left hepatic duct, RAHD = right anterior hepatic duct, RHD = right hepatic duct, RPHD = right posterior hepatic duct.

†Simultaneous emptying of the RAHD, RPHD, and LHD into the CHD.

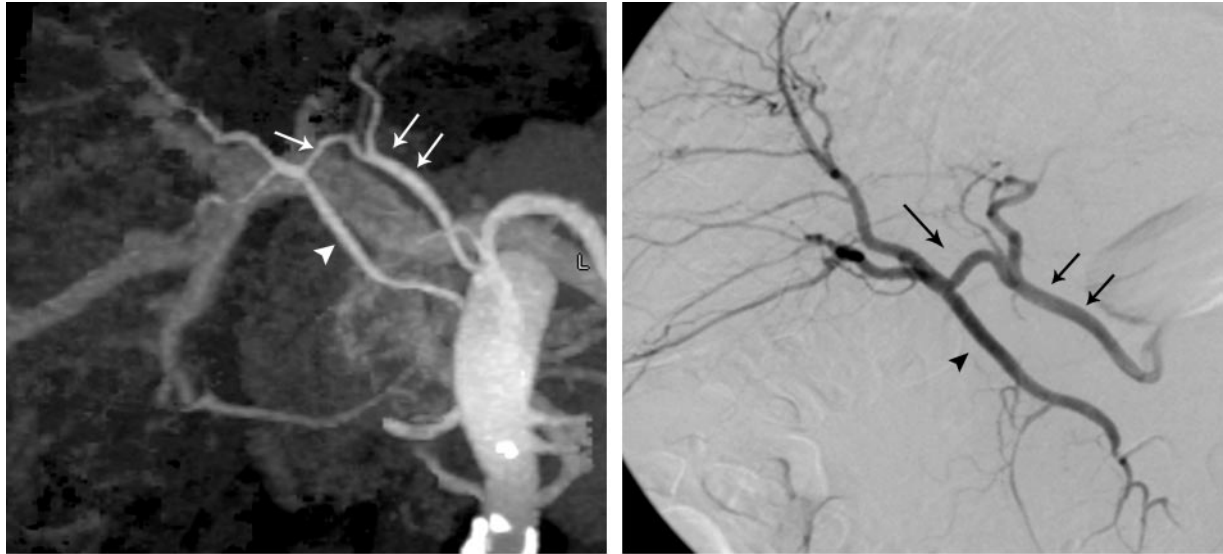
cause postcholecystectomy complications. The common bile duct may be misinterpreted as the cystic duct, with resultant inadvertent ligation or transection of the extrahepatic bile duct. The extrahepatic bile duct may also undergo stricture if the long parallel cystic duct is ligated too close to the common hepatic duct.

Another potential complication is an excessively long cystic duct remnant after surgery, which constitutes the anatomic basis for calculus formation and postcholecystectomy syndrome.

Multidetector CT cholangiography and MR cholangiography allow clear anatomic delineation of the variant biliary and cystic duct anatomy; therefore, they may be used to preoperatively identify those anatomic variants that require special attention by the surgeon (36,37).

### Placement of Intra-arterial Chemotherapy Pumps

In intraarterial chemotherapy pump placement, preoperative mapping of the hepatic arterial anatomy is mandatory because it aids in deciding whether the patient is suitable for the procedure itself and whether modifications of the technique are required. It is important to place the intraarterial infusion pump within the dominant hepatic artery, as proximal as possible but distal to the origin of the gastroduodenal artery. In patients with normal arterial anatomy, the chemotherapy pump is placed in the proper hepatic artery after the origin of the gastroduodenal artery (Fig 9). In



**a.** **Figure 24.** Arterial variant in a 64-year-old man with liver metastases from colorectal cancer. **(a)** Coronal MIP image from CT angiography shows an anomalous extrahepatic communication (single arrow) between a replaced right hepatic artery (double arrows) and an accessory right hepatic artery (arrowhead). The replaced right hepatic artery arises from the superior mesenteric artery. **(b)** Corresponding conventional angiogram shows the communication (single arrow) between the replaced (double arrows) and accessory (arrowhead) right hepatic arteries. Owing to the variant anatomy, the patient was unsuitable for HAIP placement and systemic chemotherapy was administered.

patients with variant vascular anatomy, the location of the pump varies according to the origin of the gastroduodenal artery and to the relationships between the dominant artery perfusing the liver and accessory hepatic arteries (Fig 24).

Hepatic lobar arteries are not end arteries. After occlusion of a variant hepatic artery, flow to the contralateral hepatic lobe is rapidly restored through collateral vessels. Therefore, in cases of variant hepatic arterial anatomy, the variant artery can be ligated, and the restored flow through the remaining dominant hepatic artery eliminates the need to implant separate infusion pumps.

In some patients with arterial vascular variants, like replaced right and left hepatic arteries (Michel types II and IV), modification of the technique may be required. In patients whose lesion is in the right hepatic lobe and who have a Michel type III vascular variant, a pump placed in the main hepatic artery would supply chemotherapeutic agent only to the left lobe and middle hepatic artery, leaving the lesion untreated (1).

It has been demonstrated that patients with variant arterial anatomy are more likely to experience HAIP complications if they undergo cannulation of a vessel other than the gastroduodenal artery. Moreover, in the setting of multiple vari-

ant vessels, patients experience increased pump-related complications compared to patients with a single artery variant (22,23). Complications of intraarterial pump placement like extrahepatic misperfusion and chemotoxic effects on normal hepatic tissue can be minimized by preoperative evaluation of the hepatic and extrahepatic vascular anatomy. Small duodenal arteries originating between the tip of the infusion catheter and the junction of the gastroduodenal artery and proper hepatic artery must be preoperatively detected to reduce the risks of chemical cholangitis, bleeding, and duodenitis (1).

## Conclusions

Multidetector CT and MR imaging with MR cholangiopancreatography, with image postprocessing, provide excellent delineation of hepatic vascular and biliary anatomy relevant to surgery. They help determine the best hepatectomy plane to avoid transecting major venous branches and identify patients in whom additional surgical steps will be required. Preoperative knowledge of hepatic vascular and biliary anatomic variants is mandatory for surgical planning and to help reduce postoperative complications in both the donor and the recipient. Multidetector CT and MR imaging, with the added value of postprocessed

images, allow accurate identification of areas at risk for venous congestion or devascularization. This information, in some anatomic variants, may influence surgical planning with regard to the extent of hepatic resection or the need for vascular reconstructions.

In cases of small liver remnants or compromised hepatic function (eg, in hepatic cirrhosis), where minor complications such as partial hepatic necrosis or bile leakage may have fatal consequences, this information is invaluable.

## References

- Sahani D, Mehta A, Blake M, Prasad S, Harris G, Saini S. Preoperative hepatic vascular evaluation with CT and MR angiography: implications for surgery. *RadioGraphics* 2004;24(5):1367–1380.
- Sahani D, D'souza R, Kadavigere R, et al. Evaluation of living liver transplant donors: method for precise anatomic definition by using a dedicated contrast-enhanced MR imaging protocol. *RadioGraphics* 2004;24(4):957–967.
- Limanond P, Raman SS, Ghobrial RM, Busuttill RW, Lu DS. Preoperative imaging in adult-to-adult living related liver transplant donors: what surgeons want to know. *J Comput Assist Tomogr* 2004;28(2):149–157.
- Taguchi K, Anno H. High temporal resolution for multislice helical computed tomography. *Med Phys* 2000;27(5):861–872.
- Chan JK, Tso WK, Lo CM, et al. Preoperative evaluation of potential living donors for liver transplantation: the role of helical computed tomography-angiography. *Transplant Proc* 1998;30(7):3197–3198.
- Pannu HK, Maley WR, Fishman EK. Liver transplantation: preoperative CT evaluation. *RadioGraphics* 2001;21(spec issue):S133–S146.
- Sahani D, Saini S, Nichols S, et al. Using multidetector CT for preoperative vascular evaluation of liver neoplasms: technique and results. *AJR Am J Roentgenol* 2002;179(1):53–59.
- Yeh BM, Breiman RS, Taouli B, Qayyum A, Roberts JP, Coakley FV. Biliary tract depiction in living potential liver donors: comparison of conventional MR, mangafodipir trisodium-enhanced excretory MR, and multi-detector row CT cholangiography—initial experience. *Radiology* 2004;230(3):645–651.
- Lim JS, Kim MJ, Kim JH, et al. Preoperative MRI of potential living-donor-related liver transplantation using a single dose of gadobenate dimeglumine. *AJR Am J Roentgenol* 2005;185(2):424–431.
- Soyer P, Heath D, Bluemke DA, et al. Three-dimensional helical CT of intrahepatic venous structures: comparison of three rendering techniques. *J Comput Assist Tomogr* 1996;20(1):122–127.
- Lerut JP, Mazza D, van Leeuw V, et al. Adult liver transplantation and abnormalities of splanchnic veins: experience in 53 patients. *Transpl Int* 1997;10(2):125–132.
- Sugarbaker PH, Nelson RC, Murray DR, Chezmar JL, Bernardino ME. A segmental approach to computerized tomographic portography for hepatic resection. *Surg Gynecol Obstet* 1990;171(3):189–195.
- Cheng YF, Huang TL, Lee TY, Chen TY, Chen CL. Variation of the intrahepatic portal vein: angiographic demonstration and application in living-related hepatic transplantation. *Transplant Proc* 1996;28(3):1667–1668.
- Mortele KJ, Ros PR. Anatomic variants of the biliary tree: MR cholangiographic findings and clinical applications. *AJR Am J Roentgenol* 2001;177(2):389–394.
- Guiney MJ, Kruskal JB, Sosna J, Hanto DW, Goldberg SN, Raptopoulos V. Multi-detector row CT of relevant vascular anatomy of the surgical plane in split-liver transplantation. *Radiology* 2003;229(2):401–407.
- Adams RB, Haller DG, Roh MS. Improving resectability of hepatic colorectal metastases: expert consensus statement by Abdalla et al. *Ann Surg Oncol* 2006;13(10):1281–1283.
- Chapman WC, Hoff PM, Strasberg SM. Selection of patients for resection of hepatic colorectal metastases: expert consensus statement by Charnsangavej et al. *Ann Surg Oncol* 2006;13(10):1269–1270.
- Bipat S, van Leeuwen MS, Comans EF, et al. Colorectal liver metastases: CT, MR imaging, and PET for diagnosis—meta-analysis. *Radiology* 2005;237(1):123–131.
- Charnsangavej C, Clary B, Fong Y, Grothey A, Pawlik TM, Choti MA. Selection of patients for resection of hepatic colorectal metastases: expert consensus statement. *Ann Surg Oncol* 2006;13(10):1261–1268.
- Lang H, Radtke A, Hindennach M, et al. Impact of virtual tumor resection and computer-assisted risk analysis on operation planning and intraoperative strategy in major hepatic resection. *Arch Surg* 2005;140(7):629–638; discussion 638.
- Kemeny N, Huang Y, Cohen AM, et al. Hepatic arterial infusion of chemotherapy after resection of hepatic metastases from colorectal cancer. *N Engl J Med* 1999;341(27):2039–2048.
- Allen PJ, Stojadinovic A, Ben-Porat L, et al. The management of variant arterial anatomy during hepatic arterial infusion pump placement. *Ann Surg Oncol* 2002;9(9):875–880.
- Allen PJ, Nissan A, Picon AI, et al. Technical complications and durability of hepatic artery infusion pumps for unresectable colorectal liver metastases: an institutional experience of 544 consecutive cases. *J Am Coll Surg* 2005;201(1):57–65.
- Coskun M, Kayahan EM, Ozbek O, Cakir B, Dalgic A, Haberal M. Imaging of hepatic arterial anatomy for depicting vascular variations in living related liver transplant donor candidates with multidetector computed tomography: comparison with conventional angiography. *Transplant Proc* 2005;37(2):1070–1073.

25. Erbay N, Raptopoulos V, Pomfret EA, Kamel IR, Kruskal JB. Living donor liver transplantation in adults: vascular variants important in surgical planning for donors and recipients. *AJR Am J Roentgenol* 2003;181(1):109–114.
26. Kamel IR, Lawler LP, Fishman EK. Variations in anatomy of the middle hepatic vein and their impact on formal right hepatectomy. *Abdom Imaging* 2003;28(5):668–674.
27. Atri M, Bret PM, Fraser-Hill MA. Intrahepatic portal venous variations: prevalence with US. *Radiology* 1992;184(1):157–158.
28. Itamoto T, Emoto K, Mitsuta H, et al. Safety of donor right hepatectomy for adult-to-adult living donor liver transplantation. *Transpl Int* 2006;19(3):177–183.
29. Goldman J, Florman S, Varotti G, et al. Non-invasive preoperative evaluation of biliary anatomy in right-lobe living donors with mangafodipir trisodium-enhanced MR cholangiography. *Transplant Proc* 2003;35(4):1421–1422.
30. Bassignani MJ, Fulcher AS, Szucs RA, Chong WK, Prasad UR, Marcos A. Use of imaging for living donor liver transplantation. *RadioGraphics* 2001;21(1):39–52.
31. Kapoor V, Peterson MS, Baron RL, Patel S, Eghtesad B, Fung JJ. Intrahepatic biliary anatomy of living adult liver donors: correlation of mangafodipir trisodium-enhanced MR cholangiography and intraoperative cholangiography. *AJR Am J Roentgenol* 2002;179(5):1281–1286.
32. Lo CM, Fan ST, Liu CL, Lai EC, Wong J. Biliary complications after hepatic resection: risk factors, management, and outcome. *Arch Surg* 1998;133(2):156–161.
33. Capussotti L, Ferrero A, Vigano L, Sgotto E, Muratore A, Polastri R. Bile leakage and liver resection: where is the risk? *Arch Surg* 2006;141(7):690–694; discussion 695.
34. Perini RF, Uflacker R, Cunningham JT, Selby JB, Adams D. Isolated right segmental hepatic duct injury following laparoscopic cholecystectomy. *Cardiovasc Intervent Radiol* 2005;28(2):185–195.
35. Christensen RA, vanSonnenberg E, Nemcek AA Jr, D'Agostino HB. Inadvertent ligation of the aberrant right hepatic duct at cholecystectomy: radiologic diagnosis and therapy. *Radiology* 1992;183(2):549–553.
36. Turner MA, Fulcher AS. The cystic duct: normal anatomy and disease processes. *RadioGraphics* 2001;21(1):3–22.
37. Hirao K, Miyazaki A, Fujimoto T, Isomoto I, Hayashi K. Evaluation of aberrant bile ducts before laparoscopic cholecystectomy: helical CT cholangiography versus MR cholangiography. *AJR Am J Roentgenol* 2000;175(3):713–720.

## Vascular and Biliary Variants in the Liver: Implications for Liver Surgery

*Onofrio A. Catalano, MD, et al*

RadioGraphics 2008; 28:359–378 • Published online 10.1148/rg.282075099 • Content Codes:  CT  GI  MR

---

### Page 364

The most important concept to be kept in mind in the preoperative evaluation of a potential donor for living liver transplantation is the course of the hemihepatectomy plane. The incision is performed along a relatively avascular plane that separates the left and right lobes of the liver and runs 1 cm to the right of the middle hepatic vein, connecting the gallbladder fossa and IVC, close to the so-called Cantlie line (Fig 7).

### Page 367

Not all the anatomic variants have the same level of importance. It varies depending on whether the variants are found in the donor or in the recipient.

### Page 367

Not all hepatic vascular variants are surgically relevant in hepatic tumor resection. The level of importance and influence on surgical technique mainly depend on the spatial relationship of the arterial variant to the tumor, to prevent injury to aberrant hepatic vessels and consequently to the hepatic parenchyma secondary to liver and biliary ischemia and to ensure complete tumor-free resection margins.

### Page 368

A key point to successful living donor liver transplantation is to maintain the balance between the blood supply and venous drainage of the graft. Venous congestion can seriously damage the graft, causing its failure; therefore, even small hepatic venous branches, which run along the parenchymal dissection plane, need to be left intact or reconstructed (26).

### Page 372

Biliary complications, occurring in 7%–10% of donors, represent the most common cause of morbidity in living donor liver transplantation; they include bile leakage and bile duct stricture.

# RadioGraphics 2008

## This is your reprint order form or pro forma invoice

(Please keep a copy of this document for your records.)

Reprint order forms and purchase orders or prepayments must be received 72 hours after receipt of form either by mail or by fax at 410-820-9765. It is the policy of Cadmus Reprints to issue one invoice per order.

**Please print clearly.**

Author Name \_\_\_\_\_  
Title of Article \_\_\_\_\_  
Issue of Journal \_\_\_\_\_ Reprint # \_\_\_\_\_ Publication Date \_\_\_\_\_  
Number of Pages \_\_\_\_\_ KB # \_\_\_\_\_ Symbol RadioGraphics  
Color in Article? Yes / No (Please Circle)

**Please include the journal name and reprint number or manuscript number on your purchase order or other correspondence.**

### Order and Shipping Information

#### Reprint Costs (Please see page 2 of 2 for reprint costs/fees.)

\_\_\_\_\_ Number of reprints ordered \$ \_\_\_\_\_  
\_\_\_\_\_ Number of color reprints ordered \$ \_\_\_\_\_  
\_\_\_\_\_ Number of covers ordered \$ \_\_\_\_\_  
**Subtotal** \$ \_\_\_\_\_  
Taxes \$ \_\_\_\_\_

*(Add appropriate sales tax for Virginia, Maryland, Pennsylvania, and the District of Columbia or Canadian GST to the reprints if your order is to be shipped to these locations.)*

First address included, add \$32 for  
each additional shipping address \$ \_\_\_\_\_

**TOTAL** \$ \_\_\_\_\_

#### Shipping Address (cannot ship to a P.O. Box) Please Print Clearly

Name \_\_\_\_\_  
Institution \_\_\_\_\_  
Street \_\_\_\_\_  
City \_\_\_\_\_ State \_\_\_\_\_ Zip \_\_\_\_\_  
Country \_\_\_\_\_  
Quantity \_\_\_\_\_ Fax \_\_\_\_\_  
Phone: Day \_\_\_\_\_ Evening \_\_\_\_\_  
E-mail Address \_\_\_\_\_

#### Additional Shipping Address\* (cannot ship to a P.O. Box)

Name \_\_\_\_\_  
Institution \_\_\_\_\_  
Street \_\_\_\_\_  
City \_\_\_\_\_ State \_\_\_\_\_ Zip \_\_\_\_\_  
Country \_\_\_\_\_  
Quantity \_\_\_\_\_ Fax \_\_\_\_\_  
Phone: Day \_\_\_\_\_ Evening \_\_\_\_\_  
E-mail Address \_\_\_\_\_

\* Add \$32 for each additional shipping address

### Payment and Credit Card Details

**Enclosed:** Personal Check \_\_\_\_\_  
Credit Card Payment Details \_\_\_\_\_  
Checks must be paid in U.S. dollars and drawn on a U.S. Bank.  
Credit Card:  VISA  Am. Exp.  MasterCard  
Card Number \_\_\_\_\_  
Expiration Date \_\_\_\_\_  
Signature: \_\_\_\_\_

Please send your order form and prepayment made payable to:

**Cadmus Reprints**  
**P.O. Box 751903**  
**Charlotte, NC 28275-1903**

*Note: Do not send express packages to this location, PO Box.  
FEIN #:541274108*

Signature \_\_\_\_\_ Date \_\_\_\_\_

Signature is required. By signing this form, the author agrees to accept the responsibility for the payment of reprints and/or all charges described in this document.

### Invoice or Credit Card Information

#### Invoice Address Please Print Clearly

Please complete Invoice address as it appears on credit card statement

Name \_\_\_\_\_  
Institution \_\_\_\_\_  
Department \_\_\_\_\_  
Street \_\_\_\_\_  
City \_\_\_\_\_ State \_\_\_\_\_ Zip \_\_\_\_\_  
Country \_\_\_\_\_  
Phone \_\_\_\_\_ Fax \_\_\_\_\_  
E-mail Address \_\_\_\_\_

**Cadmus will process credit cards and Cadmus Journal  
Services will appear on the credit card statement.**

*If you don't mail your order form, you may fax it to 410-820-9765 with  
your credit card information.*

# RadioGraphics 2008

## Black and White Reprint Prices

Domestic (USA only)						
# of Pages	50	100	200	300	400	500
1-4	\$221	\$233	\$268	\$285	\$303	\$323
5-8	\$355	\$382	\$432	\$466	\$510	\$544
9-12	\$466	\$513	\$595	\$652	\$714	\$775
13-16	\$576	\$640	\$749	\$830	\$912	\$995
17-20	\$694	\$775	\$906	\$1,017	\$1,117	\$1,220
21-24	\$809	\$906	\$1,071	\$1,200	\$1,321	\$1,471
25-28	\$928	\$1,041	\$1,242	\$1,390	\$1,544	\$1,688
29-32	\$1,042	\$1,178	\$1,403	\$1,568	\$1,751	\$1,924
Covers	\$97	\$118	\$215	\$323	\$442	\$555

## Color Reprint Prices

Domestic (USA only)						
# of Pages	50	100	200	300	400	500
1-4	\$223	\$239	\$352	\$473	\$597	\$719
5-8	\$349	\$401	\$601	\$849	\$1,099	\$1,349
9-12	\$486	\$517	\$852	\$1,232	\$1,609	\$1,992
13-16	\$615	\$651	\$1,105	\$1,609	\$2,117	\$2,624
17-20	\$759	\$787	\$1,357	\$1,997	\$2,626	\$3,260
21-24	\$897	\$924	\$1,611	\$2,376	\$3,135	\$3,905
25-28	\$1,033	\$1,071	\$1,873	\$2,757	\$3,650	\$4,536
29-32	\$1,175	\$1,208	\$2,122	\$3,138	\$4,162	\$5,180
Covers	\$97	\$118	\$215	\$323	\$442	\$555

International (includes Canada and Mexico)						
# of Pages	50	100	200	300	400	500
1-4	\$272	\$283	\$340	\$397	\$446	\$506
5-8	\$428	\$455	\$576	\$675	\$784	\$884
9-12	\$580	\$626	\$805	\$964	\$1,115	\$1,278
13-16	\$724	\$786	\$1,023	\$1,232	\$1,445	\$1,652
17-20	\$878	\$958	\$1,246	\$1,520	\$1,774	\$2,030
21-24	\$1,022	\$1,119	\$1,474	\$1,795	\$2,108	\$2,426
25-28	\$1,176	\$1,291	\$1,700	\$2,070	\$2,450	\$2,813
29-32	\$1,316	\$1,452	\$1,936	\$2,355	\$2,784	\$3,209
Covers	\$156	\$176	\$335	\$525	\$716	\$905

International (includes Canada and Mexico))						
# of Pages	50	100	200	300	400	500
1-4	\$278	\$290	\$424	\$586	\$741	\$904
5-8	\$429	\$472	\$746	\$1,058	\$1,374	\$1,690
9-12	\$604	\$629	\$1,061	\$1,545	\$2,011	\$2,494
13-16	\$766	\$797	\$1,378	\$2,013	\$2,647	\$3,280
17-20	\$945	\$972	\$1,698	\$2,499	\$3,282	\$4,069
21-24	\$1,110	\$1,139	\$2,015	\$2,970	\$3,921	\$4,873
25-28	\$1,290	\$1,321	\$2,333	\$3,437	\$4,556	\$5,661
29-32	\$1,455	\$1,482	\$2,652	\$3,924	\$5,193	\$6,462
Covers	\$156	\$176	\$335	\$525	\$716	\$905

Minimum order is 50 copies. For orders larger than 500 copies, please consult Cadmus Reprints at 800-407-9190.

### Reprint Cover

Cover prices are listed above. The cover will include the publication title, article title, and author name in black.

### Shipping

Shipping costs are included in the reprint prices. Domestic orders are shipped via UPS Ground service. Foreign orders are shipped via a proof of delivery air service.

### Multiple Shipments

Orders can be shipped to more than one location. Please be aware that it will cost \$32 for each additional location.

### Delivery

Your order will be shipped within 2 weeks of the journal print date. Allow extra time for delivery.

### Tax Due

Residents of Virginia, Maryland, Pennsylvania, and the District of Columbia are required to add the appropriate sales tax to each reprint order. For orders shipped to Canada, please add 7% Canadian GST unless exemption is claimed.

### Ordering

Reprint order forms and purchase order or prepayment is required to process your order. Please reference journal name and reprint number or manuscript number on any correspondence. You may use the reverse side of this form as a proforma invoice. Please return your order form and prepayment to:

**Cadmus Reprints**  
P.O. Box 751903  
Charlotte, NC 28275-1903

*Note: Do not send express packages to this location, PO Box. FEIN #: 541274108*

Please direct all inquiries to:

**Rose A. Baynard**  
800-407-9190 (toll free number)  
410-819-3966 (direct number)  
410-820-9765 (FAX number)  
[baynardr@cadmus.com](mailto:baynardr@cadmus.com) (e-mail)

**Reprint Order Forms and purchase order or prepayments must be received 72 hours after receipt of form.**