

# Vascular endothelial growth factor gene and protein: strong expression in thyroiditis and thyroid carcinoma

M Klein, E Picard, J-M Vignaud, B Marie, L Bresler, B Toussaint, G Weryha, A Duprez and J Leclère

Clinique Médicale et Endocrinologique, Laboratoire d'Anatomie Pathologique, Service de Chirurgie C and Service d'ORL, Centre Hospitalier et Universitaire de Nancy, 54000 Nancy, France

(Requests for offprints should be addressed to M Klein, Clinique Médicale et Endocrinologique, Hôpitaux de Brabois, Centre Hospitalier et Universitaire de Nancy, 54500 Vandoeuvre-lès-Nancy, France)

## Abstract

Angiogenesis is implicated in several pathological conditions, such as inflammation and tumor growth. Vascular endothelial growth factor (VEGF), also known as vascular permeability factor, is a potent stimulator of endothelial cell proliferation *in vitro* and *in vivo*. The present work aimed to compare VEGF expression in human normal thyroid glands, thyroiditis tissue and thyroid carcinomas using immunohistochemistry and *in situ* hybridization (ISH). Both chronic lymphocytic thyroiditis and differentiated thyroid carcinomas were found to strongly express VEGF mRNA and encode larger amounts of VEGF than normal thyroid tissue as attested by a VEGF immunostaining score. In addition, tumor samples from patients with

metastases showed a higher immunostaining score than their non-metastatic counterparts ( $P < 0.05$ ). Carcinomas with the greatest contents of VEGF mRNA and VEGF protein had the most intense mitogenic activity. Special focus on endothelial cells showed intense mitogenic activity in neoplastic tissues in contrast to the total quiescence of endothelial cells in non-tumoral tissues. An intense VEGF production by differentiated thyroid carcinoma, attested either by a higher immunostaining score or a strong VEGF mRNA expression using ISH, could be a promising marker of tumor aggressiveness and may also be useful as a predictor of metastatic potential.

*Journal of Endocrinology* (1999) **161**, 41–49

## Introduction

Angiogenesis, the formation of new blood vessels from pre-existing microvasculature, occurs during physiological processes, for instance *in utero* growth and development (Simon *et al.* 1995) and reparative conditions (Folkman 1997). Angiogenesis is also implicated in several pathological conditions such as inflammation and tumor growth (Ferrara 1995, Folkman 1997). The thyroid is a highly vascularized gland which is subject to inflammatory (thyroiditis) and neoplastic diseases (thyroid carcinomas). Vascular endothelial growth factor (VEGF), also known as vascular permeability factor, is a potent stimulator of endothelial cell proliferation *in vitro* and *in vivo* (Kondo *et al.* 1993, Plouet & Bayard 1994). This heparin-binding homodimeric glycoprotein exhibits a mitogenic and permeability enhancing activity directed toward vascular endothelial cells. It also induces vasodilatation (Ku *et al.* 1993) and stimulates hexose transport of vascular endothelium (Pekala *et al.* 1990). These properties outline a very important role in physiological angiogenesis (Brown *et al.* 1997, Ferrara & Keyt 1997, Kamat *et al.* 1995). VEGF has also been implicated in diabetic retinopathy (Aiello *et al.* 1994), various inflammatory diseases (Fava

*et al.* 1994, Koch *et al.* 1994, Brown *et al.* 1995a,b) and tumor growth (Plate *et al.* 1992, Senger *et al.* 1993, Dvorak *et al.* 1995, Ito *et al.* 1995, Brown *et al.* 1997, Ferrara & Davis-Smyth 1997). VEGF is a potent mitogen (ED<sub>50</sub> 2–10 pM) for endothelial cells, without significant mitogenic activity for other types of cells (Ferrara & Keyt 1997). It is encoded by a single-copy gene that produces multiple transcripts by alternative splicing of mRNA. The best studied isoforms are VEGF<sub>121</sub>, VEGF<sub>165</sub>, VEGF<sub>189</sub> and VEGF<sub>206</sub>. The production of VEGF in normal thyroid cells (Soh *et al.* 1996) and in Graves' disease (Sato *et al.* 1995) has recently been studied. VEGF is also found in large amounts in the cyst fluid of enlarging and recurrent thyroid nodules (Sato *et al.* 1997), as well as in thyroid cancers (Viglietto *et al.* 1995, Soh *et al.* 1996, 1997) or during goiter formation (Wang *et al.* 1998). Two tyrosine kinases act as VEGF receptors: the *fms*-like tyrosine kinase (Flt-1) and the kinase domain region (KDR) (De Vries *et al.* 1992, Ferrara & Keyt 1997). The aim of this study was to investigate the role of VEGF in the angiogenesis process occurring in thyroiditis and thyroid carcinoma. For this purpose, using immunohistochemistry and *in situ* hybridization (ISH) techniques, we studied the expression of VEGF and VEGF mRNA in normal thyroid samples,

chronic lymphocytic thyroiditis and thyroid carcinomas, the distribution of Flt-1 on endothelial cells, and the replicating status of epithelial and endothelial cell populations.

## Materials and Methods

### Study population

Human thyroid tissue samples from patients of both sexes, 18–72 years old, were obtained from the pathology archives of the Laboratoire d'Anatomie Pathologique du Centre Hospitalier et Universitaire, Hôpital Central, Nancy, France. The specimens included 6 specimens of normal thyroid tissue, 14 cases of Hashimoto's thyroiditis and 24 differentiated thyroid carcinomas. Among the thyroid carcinomas, 17 were papillary carcinomas and 7 follicular carcinomas. Four out of 17 papillary carcinomas developed lymph node metastases and 3 out of 7 follicular carcinomas bone or lung metastases.

### Immunohistochemistry

Immunohistochemistry was performed on 5 µm paraffin tissue sections. Paraffin sections were dewaxed with xylene and ethanol and processed in a pressure cooker in citrate buffer 0.1 M, pH 6.0 for 10 min, washed under running tap water and rehydrated in TBS-Tween (Tris-HCl 0.05 M, NaCl 150 mM, 0.1% Tween, pH 7.4) and incubated with 3% albumin for 20 min. Sections were incubated overnight at 4 °C in a humidified chamber with a rabbit anti-human VEGF antibody (Oncogene Research Products, Cambridge, MA, USA), recognizing VEGF<sub>121</sub>, VEGF<sub>165</sub>, VEGF<sub>189</sub> and VEGF<sub>206</sub>, diluted 1/200 in TBS-Tween, a rabbit anti-human Flt-1 antibody (Santa Cruz Biotechnology, Santa Cruz, CA, USA) diluted 1/100 in TBS-Tween and the following monoclonal antibodies: anti-Ki-67 antigen antibody (MIB1, Immunotech, Marseille, France) in order to show cell kinetics of thyrocytes and stromal cells, and anti-CD31 antibody, a specific marker of endothelial cells (Dako, A/S, Glostrup, Denmark) diluted 1/75 in TBS-Tween. The anti-VEGF antibody (VEGF(Ab-2), Oncogene Research Products) is a polyclonal antibody generated by immunizing rabbits with a peptide from the N-terminus region of VEGF<sub>165</sub>. Its reactivity and specificity against VEGF have been tested successfully. The anti-Flt-1 antibody reacts specifically with Flt-1 of mouse, rat and human origin by Western blotting and immunohistochemistry. It is raised against a peptide corresponding to the following amino acid sequence: S-P-P-D-Y-M-S-V-V-L-Y-S-T-P-P-I mapping at the C-terminus of the precursor form of Flt-1 of human origin. This antibody is not cross-reactive with Flk-1, FLT-4 or other receptor tyrosine kinases. This antibody has already been used for investigations with thyroid tissue samples (Viglietto *et al.*

1995). Sections studied for Ki-67 expression were previously digested with trypsin (trypsin 0.1% in CaCl<sub>2</sub> 4% buffer, pH 7.8 at 37 °C for 10 min) before immunohistochemistry processing. The sections were washed twice in TBS-Tween for 5 min and overlaid with a biotinylated goat anti-rabbit IgG (Dako) diluted 1/75 for 30 min at room temperature for VEGF and Flt-1, or with a biotinylated goat anti-mouse IgG (Dako) diluted 1/75 for 30 min at room temperature for CD31 and MIB1. The sections were washed again in TBS-Tween and each section was incubated with streptavidin-peroxidase complex (Dako) diluted 1/250 for 30 min. The sections were again washed thoroughly in TBS-Tween, and each section was incubated with 0.6 mg/ml 3,3'-diaminobenzidine in 0.5 M Tris-HCl buffer, pH 7.6, containing 0.01% hydrogen peroxide. Sections, bearing the brownish reaction products, were washed with water and counterstained with hematoxylin. Finally, the sections were mounted, dried and examined under a light microscope.

### Controls

To test the specificity of the labeling protocols, the following controls were carried out on selected sections for each antibody: omission of the incubation step with the primary antibody; substitution of a non-immune serum in place of the primary antibody; and omission of the incubation step with both primary and secondary antibodies. In order to test the specificity of anti-VEGF antibody, before the immunohistochemical study, a preincubation step of this antibody with an excess of recombinant human VEGF<sub>165</sub> (Pepro Tech, Rocky Hill, NJ, USA) was performed in all control tissue samples. Under these conditions, no labeling was observed in all tissue samples analyzed.

### VEGF immunostaining score

In order to show the extent of immunostaining with anti-VEGF antibody, a semi-quantitative score was established. For this purpose, each sample was scored: (a) for the percentage of labeled thyrocytes (0=absence of labeling over thyrocytes; 1=less than 30% of thyrocytes labeled; 2=30–60%; and 3=more than 60%); and (b) and for the intensity of the immunostaining (0=no staining; 1=weak; 2=mild; and 3=strong staining). Addition of both scores allowed the final scoring of samples, ranging from 0 to 6. Analysis was performed by two independent pathologists.

### ISH

Paraffin sections (5 µm) were mounted on 0.5% gelatine coated glass slides and dried for 2 h at 42 °C before the ISH procedure. The sections were processed in a pressure cooker in citrate buffer 0.1 M, pH 6.0 for 10 min,

washed under running tap water and rehydrated in TBS-Tween.

The probes were prepared as run-off transcripts using pBluescript KS plasmid containing cDNA insert for human VEGF<sub>121</sub> (517 bp) (gift from Georg Breier, Herbert A Weich and Werner Risau, Max-Planck-Institut für Klinische Forschung, Abteilung Molekulare Zellbiologie, Bad Nauheim, Germany). The vector was linearized with BamHI restriction enzyme and transcription used T3-RNA polymerase to yield antisense probes. Sense probe was generated using EcoRI and T7-RNA polymerase. The integrity of the probes was checked on a 6% denaturing polyacrylamide gel. *In vitro* transcription was carried out using 1 µg cDNA and 150 µCi [<sup>35</sup>S]UTP for each transcription reaction under the conditions described previously (Vignaud *et al.* 1994).

Hybridization was performed overnight, in a moist chamber, at 55 °C, in the following solution: 50% deionized formamide; 2 × SSC (300 mM NaCl, 30 mM Na citrate, pH 7.0); 100 mM dithiothreitol; 1 mg/ml yeast tRNA; 1 mg/ml sonicated salmon sperm DNA; 2 mg/ml BSA; and the <sup>35</sup>S-labeled sense or antisense human VEGF RNA probes (10<sup>6</sup> c.p.m./10 µl of hybridization solution). Following hybridization, the sections were rinsed with formamide (50%, 2 × SSC) at 55 °C for 2 h, and digested with RNase for 30 min at 37 °C according to Cox *et al.* (1984) (RNase A, 10 µg/ml; RNase T1, 500 units/ml; in 2 × SSC). The sections were washed again in formamide (50%, 2 × SSC) for 2 h at 55 °C, with a final wash in 0.5 × SSC at room temperature for 15 min. Hybridized slides were autoradiographed with NTB2 emulsion (Kodak, Rochester, NY, USA) and exposed at 4 °C. Triplicate sections from each specimen were developed at weekly intervals over 3 weeks with D19 Kodak developer before counterstaining with hematoxylin and eosin, dehydration and mounting in paraffin. Microscopic examination with a dark field gave the general pattern of labeling; adding bright light allowed us to determine the type of labeled cells displaying a perinuclear deposition of silver grains.

Controls included pretreatment of tissue sections with RNase for 1 h at 37 °C (RNase A, 10 µg/ml; RNase T1, 500 units/ml; in 2 × SSC) and hybridization with sense probes.

#### Silver grain counting

Silver grain counting allowed a semi-quantitative evaluation of VEGF mRNA production. For this purpose, silver grains generated by autohistoradiography were counted in two representative microscopic high-power fields of tumor and surrounding normal thyroid tissue, Hashimoto's thyroiditis and normal thyroid tissue controls. Results are given as mean for one cell ± 1 s.d. Analysis was performed by two independent pathologists.

#### Cell kinetics quantification

Growth activity in tissue samples was determined by an immunohistochemical staining procedure using monoclonal antibody MIB1. Cells were counted with an optical grid (Zeiss Kpl-W, Oberkochen, Germany) on non-consecutive random fields. The Ki-67 antigen labeling index was defined for tumor cells as the percentage of carcinoma cells with labeled nuclei among the total cancer cell nuclei scored. An average of 2500 cells was counted for each tumor, in three to nine microscopic fields, randomly distributed. At least three fields intersected the central part of the tumor, and three fields intersected the peripheral part. The same procedure was used to establish the Ki-67 antigen labeling index of endothelial cells, defined as the percentage of endothelial cells with nuclei labeled with anti-Ki-67 antibodies among the total endothelial cells. Endothelial cells were identified by standard histological criteria, and immunostaining for CD31 antigen. The results are expressed as mean ± 1 s.d.

#### Statistical analysis

In order to compare the different immunohistostaining scores, a Kruskal-Wallis one-way ANOVA was performed. In order to compare the immunohistostaining scores of the seven carcinomas associated with metastasis to those of carcinomas without metastatic spread, a Mann-Whitney independent rank sum test was performed. A Student *t*-test was performed to compare silver grain density in thyroid carcinoma or Hashimoto's thyroiditis versus normal thyroid.

## Results

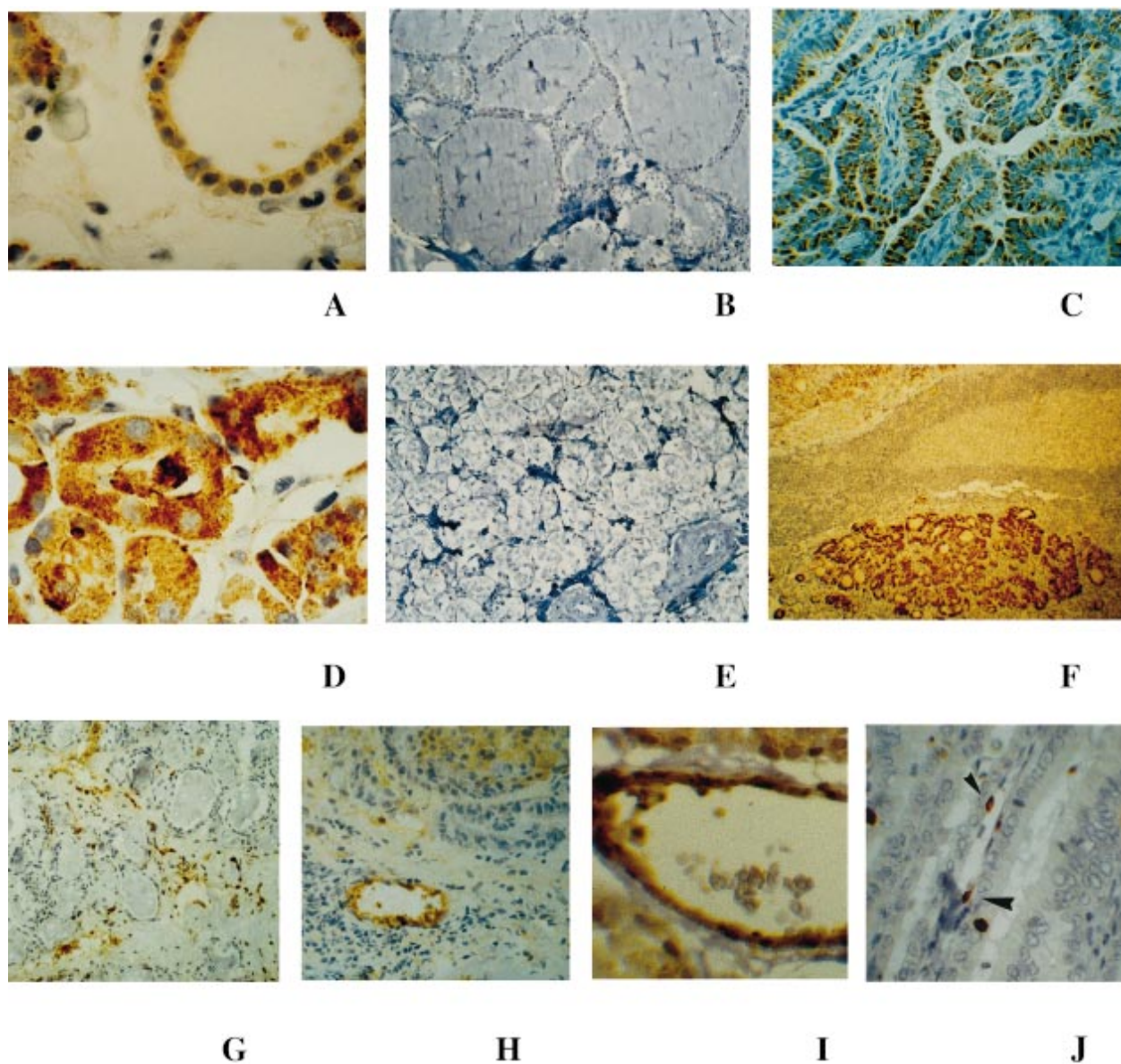
#### Immunohistochemistry

##### VEGF and Ki-67 expression

**Normal thyroid tissue** Moderate immunoreactivity with VEGF antibody was observed throughout the thyroid epithelial tissue, slightly increasing in active zones (Fig. 1A). This immunoreactivity was present in the thyrocyte cytoplasm. No labeling was observed in mesenchymal cells. A few small and medium size blood vessels had endothelial cells with weak immunoreactivity on the cytoplasmic membrane of the cells. No staining was detected in negative controls (Fig. 1B). VEGF immunostaining scores ranged from 2 to 5 with a mean of 3.0 (Fig. 2). The normal thyroid group, compared with all other groups by Kruskal-Wallis one-way ANOVA, had a significantly lower immunostaining score ( $P < 0.03$ ). The kinetic study using anti-Ki-67 antibody showed a very low labeling index of thyrocytes (less than 1%), and did not detect any replicating endothelial cell.

**Thyroid carcinoma** In contrast with normal thyroid tissue, an intense and homogeneous immunostaining with

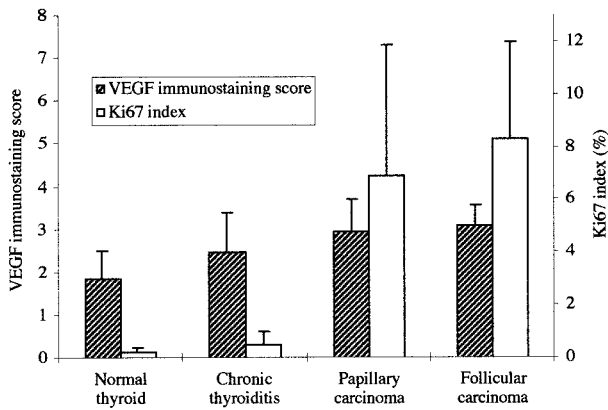




**Figure 1** Immunohistochemistry. (A–F) VEGF protein expression in normal, tumoral and inflammatory thyroid tissue: (A) normal thyroid tissue – a mild staining of thyrocytes was observed with anti-VEGF antibody (magnification  $\times 750$ ); (B) normal thyroid tissue, negative control (magnification  $\times 290$ ); (C) papillary carcinoma (magnification  $\times 750$ ) and (D) follicular carcinoma (magnification  $\times 1160$ ) – anti-VEGF antibody showed a strong cytoplasmic staining of tumor cells; (E) papillary carcinoma, negative control (magnification  $\times 750$ ); and (F) chronic lymphocytic thyroiditis – anti-VEGF antibody showed an intense cytoplasmic staining of thyrocytes (magnification  $\times 290$ ). (G–I) Flt-1 expression in thyroid tissue samples: (G) normal thyroid (magnification  $\times 290$ ); (H) chronic lymphocytic thyroiditis (magnification  $\times 450$ ); and (I) thyroid papillary carcinoma (magnification  $\times 1160$ ). (J) Kinetic study of endothelial cells: replicating endothelial cells stained with Ki-67 antigen antibody (arrowheads) in a thyroid papillary carcinoma (magnification  $\times 750$ ).

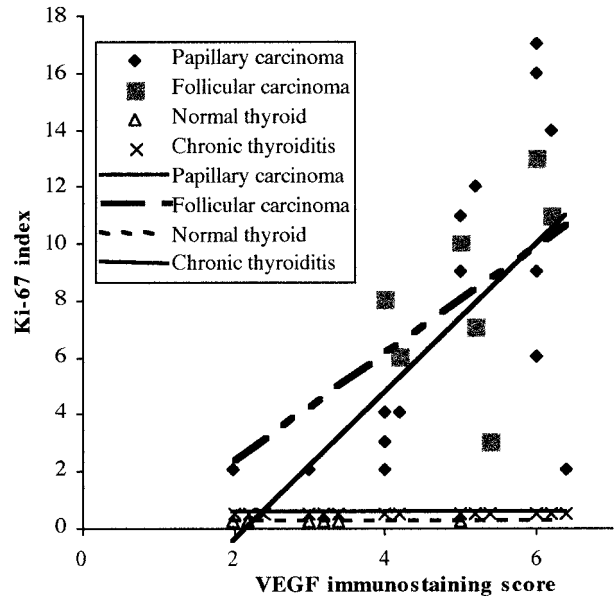
anti-VEGF antibody was observed in carcinoma cells (Fig. 1C and D). The normal thyroid tissue in close contact with the tumor was less strongly stained. The more distant normal thyroid tissue was weakly stained, as was normal thyroid tissue. However, in 3 out of 24 cancers, we observed a patchy immunoreactivity throughout the

tumor tissue. The immunoreactivity was always confined to epithelial cells, but there was occasional vascular staining that paralleled the lumen. Staining was in the cytoplasm of thyrocytes and restricted to the cytoplasmic membrane of endothelial cells. The anti-VEGF antibody did not stain mesenchymal or inflammatory cells. No

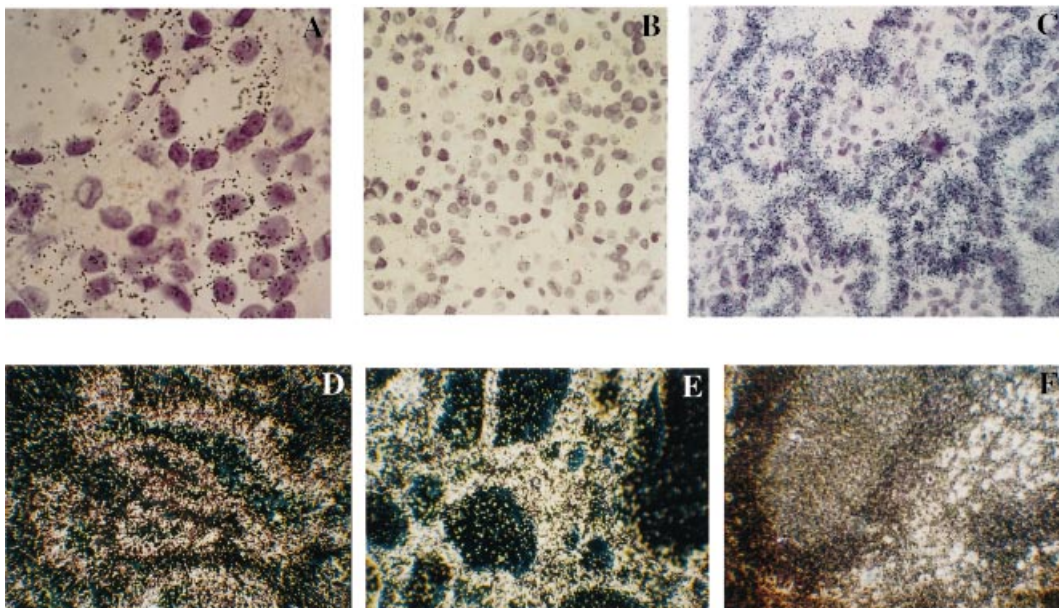


**Figure 2** Distribution of VEGF immunostaining score and Ki-67 index in normal thyroid tissue, thyroiditis, papillary and follicular thyroid carcinoma. Each sample was scored from 0 to 6 for VEGF immunostaining, as described in the text, according to the percentage of labeled cells and intensity of immunostaining. Ki-67 index reflects cell kinetics. Results are given as mean  $\pm$  1 S.D.

immunoreactivity was detected in negative controls (Fig. 1E). VEGF immunostaining scores ranged from 2 to 6 for papillary carcinoma and from 4 to 6 for follicular carcinoma. The mean score was 4.8 for papillary carcinoma and 5.0 for follicular carcinoma (Fig. 2). Within all thyroid carcinoma samples, only 2 out of 24 were scored 3 or less.



**Figure 3** Relationship between VEGF immunostaining score and Ki-67 index in normal thyroid tissue, thyroiditis, papillary and follicular thyroid carcinoma. The Ki-67 index, significantly lower in normal thyroid and chronic lymphocytic thyroiditis, did not change with increase of VEGF immunostaining score in these samples. In contrast, there was an increase of Ki-67 index with increase of VEGF score in both papillary and follicular thyroid carcinoma samples.



**Figure 4** ISH for VEGF mRNA expression with a  $^{35}\text{S}$ -labeled antisense probe. (A–C) Bright-field microscopy: (A) normal thyroid tissue showed a moderate silver grain formation over thyrocytes (magnification  $\times$  1160); (B) control with VEGF sense probe showed no silver grain formation over thyrocytes (magnification  $\times$  750); and (C) papillary carcinoma showed an intense silver grain formation over thyrocytes (magnification  $\times$  750). (D–F) Dark-field microscopy examination: (D) a papillary and (E) a follicular carcinoma (magnification  $\times$  750); and (F) a clear-cut signal over thyrocytes from a chronic lymphocytic thyroiditis ( $\times$  290).



The mean score for metastatic carcinoma was 5.4, versus 4.6 for non-metastatic cancers ( $P < 0.05$ ).

There was strong immunoreactivity for Ki-67 antigen in carcinoma cells throughout the tumor areas, sparing normal thyroid areas. Many carcinoma cells were stained, as were several endothelial cells from vessels between tumor sheets (Fig. 1J). The mean labeling index was not significantly different between papillary carcinomas ( $6.9 \pm 5\%$ ) and follicular carcinoma ( $8.3 \pm 3.7\%$ ), but higher than in normal thyroid tissue ( $P < 0.01$ ) (Fig. 2). Similarly, the Ki-67 antigen labeling index for endothelial cells was not significantly different between papillary carcinomas ( $4.5 \pm 2.3\%$ ) and follicular carcinoma ( $7.4 \pm 6.8\%$ ), but higher than in normal thyroid tissue, where it was less than 1% ( $P < 0.01$ ).

**Hashimoto's chronic lymphocytic thyroiditis** We observed an intense VEGF immunoreactivity of thyroid follicles surrounding germinal centers (Fig. 1F). Lymphocytes from germinal centers were also stained in 3 out of 14 cases. Thyroid tissue at some distance from these areas showed a staining similar to that of normal thyroid tissue. Mesenchymal cells and endothelial cells had no immunoreactivity for VEGF. The immunoreactivity in thyrocytes was confined to the cytoplasm. Negative control sections had no detected staining. The VEGF immunostaining scores ranged from 2 to 6 with a mean value of 4 (Fig. 2). Nuclei immunoreactive for MIB1/Ki-67 were observed in thyroid epithelial cells (less than 1%), absent from vascular endothelium and quite intense in germinal centers (80%).

**Relationship between VEGF immunostaining score and Ki-67 index** Normal thyroid and chronic lymphocytic thyroiditis showed a lower VEGF immunostaining score than thyroid carcinoma (Fig. 2). Their Ki-67 index was significantly lower too and did not vary among the samples we studied (Fig. 3). In contrast, we observed an increase of Ki-67 index that paralleled the VEGF immunostaining score in both papillary and follicular thyroid carcinoma samples (Fig. 3).

**VEGF receptor Flt-1** The majority of normal thyroid tissue, thyroiditis and tumor samples analyzed showed a weak positivity with anti-Flt-1 antibody restricted to endothelial cells (Fig. 1G–I). This staining was observed in a small number of capillaries from normal thyroid tissue, and was stronger, albeit not intense, with a patchy distribution, in carcinoma and thyroiditis tissue.

#### ISH study

The human VEGF antisense probe gave specific labeling in the tissue sections from normal thyroid gland, well-differentiated carcinoma, and chronic lymphocytic

thyroiditis. No specific labeling was obtained with the sense probe in samples of each of these tissues serving as control.

**Normal thyroid tissue** VEGF mRNA was distributed uniformly in all glandular thyroid cells (Fig. 4A), but was absent from the colloid and endothelial and mesenchymal cells. The mild density of silver grains over thyrocytes paralleled the weak immunostaining observed with anti-VEGF antibodies. The mean number of silver grains counted was  $24.9 \pm 9.0$ . The negative control obtained with the sense probe showed no specific labeling (Fig. 4B).

**Tumor samples** In contrast, VEGF mRNA was strongly expressed in carcinoma cells independently of the histological type of tumor (Fig. 4C–E). The mean number of silver grains counted was  $56.1 \pm 12.4$  for papillary malignant thyrocytes ( $P < 0.02$ ), and  $59.9 \pm 13.9$  for follicular malignant thyrocytes ( $P < 0.001$ ). Distant normal thyroid tissue surrounding tumor showed a very similar density in silver grains ( $26.8 \pm 10.2$ ) ( $P$  not significant) versus normal thyroid tissue control. The signal over mesenchymal and endothelial cells did not differ from background.

**Hashimoto's chronic lymphocytic thyroiditis** All the thyrocytes in chronic lymphocytic thyroiditis tissues were labeled, with labeling particularly around the germinal centers (Fig. 4F). In these areas the signal was similar in intensity to the one observed in carcinoma. The mean number of silver grains counted was  $43.6 \pm 6.6$  ( $P < 0.02$ ). In contrast, the germinal centers contained no significant labeling. Neither mesenchymal cells nor endothelial cells expressed VEGF mRNA.

#### Discussion

The present study examined the amounts of VEGF in normal thyroid tissue under basal conditions, in thyroid carcinoma because VEGF is involved in tumor progression, and in thyroiditis because VEGF is implicated in the development of many inflammatory processes. The VEGF gene was actively expressed to produce VEGF protein in both normal and pathological conditions.

Anti-VEGF antibody gave a positive reaction for VEGF protein in the endothelial cells lining some blood vessels of the normal thyroid, thyroid carcinoma and thyroiditis tissue. However, as no ISH staining was observed for VEGF mRNA, these findings suggest local binding of VEGF to specific endothelial receptors without endothelial synthesis of the protein.

VEGF was found, albeit in relatively low amounts, in all the normal thyroid samples studied, in agreement with a previous report (Viglietto *et al.* 1995). This is not surprising since the thyroid has a very rich vasculature. However, regulation of VEGF expression remains unclear since

thyrotropin (TSH), which stimulates thyroid growth and function, promotes VEGF synthesis in thyroid carcinomas (Soh *et al.* 1996) and in thyroid follicles from Graves' disease patients (Sato *et al.* 1995), but not in normal thyrocytes, where the action of TSH is unclear (Soh *et al.* 1996). Furthermore, TSH and VEGF have antagonistic effects on [<sup>3</sup>H]thymidine incorporation (Wang *et al.* 1998). Graves' immunoglobulin G also stimulates the production of VEGF mRNA in thyroid follicles from Graves' disease patient (Sato *et al.* 1995). Large amounts of VEGF are present in thyroid carcinoma cells and in a thin layer of follicles in close contact with tumor cells, suggesting a paracrine control of angiogenesis. The lack of VEGF mRNA in the endothelial cells argues against an autocrine action of angiogenesis in thyroid carcinoma. An intense VEGF production could be the hallmark of an aggressive tumor. Indeed, the higher VEGF immunostaining scores were observed with thyroid carcinomas and more specifically with those with a metastatic spread. This could reflect that angiogenesis and particularly VEGF could play an important role in tumor progression. A VEGF immunostaining score, when higher than 5, could therefore be proposed as a marker for metastatic risk.

In a recent study, Soh *et al.* (1997) using Northern and Western blot analysis observed that thyroid cancers expressed VEGF more intensely than normal thyroid. The patterns of mRNA expression, as well as immunohistochemical staining, were not different between the primary thyroid tumors and respective metastases in lymph nodes or lung. Viglietto *et al.* (1995) concluded that a high tumorigenic potential is associated with an elevated VEGF concentration in human thyroid tumor cell lines. They observed a VEGF overproduction in all of five highly malignant anaplastic carcinomas and intermediate amounts of VEGF mRNA in papillary and follicular carcinoma. Our data agree with these findings, and we observed a significantly higher expression of VEGF mRNA in both papillary and follicular carcinoma than in normal thyroid. However, the presence of VEGF mRNA or the detection of high VEGF concentrations in thyroid nodules is no indicator of malignant proliferation. High concentrations of VEGF have been detected in the cyst fluid of enlarging and recurrent thyroid nodules (Sato *et al.* 1997). Thus, VEGF should not be regarded as a specific marker of malignancy, but rather a marker of disease activity. The higher the VEGF concentration, the greater the risk of progression or relapse of the underlying disease, whether this disease is benign or malignant. The study of tumor cell kinetics using anti-Ki-67 antibody agrees with this, since the labeling index of carcinoma cells paralleled the VEGF concentration. This index did not differ between papillary and follicular carcinoma. These data are in agreement with previous results (Katoh *et al.* 1995). However, Ki-67 antigen labeling index was rather low in comparison with other tumorous processes like lung carcinoma ( $28 \pm 12\%$  in lung carcinoma, a much more aggressive cancer than

differentiated thyroid cancers) (Vignaud *et al.* 1994). The Ki-67 antigen labeling index showed that endothelial cells are actively replicating in thyroid carcinomas, but are quiescent in normal thyroid tissues, indicating an ongoing angiogenesis during thyroid malignancies.

Our data agree with those from a previous study (Viglietto *et al.* 1995) reporting the expression of Flt-1 receptors on blood vessels of normal thyroid tissue and in thyroid tumors. We also found Flt-1 in lymphocytic thyroiditis. An increase in VEGF receptor Flt-1 expression could be a key event in switching on the proliferative response to VEGF in endothelial cells during the development of thyroid cancer and the inflammatory processes that occur during thyroiditis.

Cell proliferation is only mildly enhanced in thyroiditis, as indicated by the immunoperoxidase staining for MIB1/Ki-67 within epithelial structures. These results are in agreement with those of a previous study (Okayasu *et al.* 1995). However, the staining was much less intense than in tumor samples in our study. To the best of our knowledge, the production of VEGF mRNA has never been assessed before in chronic lymphocytic thyroiditis. The immunostaining showed that VEGF is expressed in chronic thyroiditis. Immunostaining was found in the germinal center, which is not unexpected, since inflammatory cells may express VEGF mRNA (Freeman *et al.* 1995, Iijima *et al.* 1996). Activated macrophages, unlike resident non-activated macrophages, also contain VEGF mRNA (Berse *et al.* 1992). However, using ISH, the labeling over lymphocytes from germinal centers was not significantly different from background. The VEGF staining of lymphocytes from germinal centers, by immunohistochemistry, may originate from thyrocytes with local recapture by immunocompetent cells, or it could be relevant to a very fast turnover of VEGF mRNA in lymphocytes. The thyroid follicles in the vicinity of germinal centers also contain large amounts of VEGF immunostaining. The germinal centers could secrete cytokines that stimulate the normal surrounding thyrocytes to produce VEGF and thus favor the inflammatory response. An increase in TSH, known as a stimulator of VEGF production, is not an explanation for the observed VEGF increased expression, since only one patient with thyroiditis was mildly hypothyroid (TSH=11.2 mIU/l) in our study. Nevertheless, VEGF seems to be involved to a lesser extent for angiogenesis in thyroiditis than in carcinomas, since both the immunostaining and ISH are less intense and the endothelial cells do not stain for MIB1/Ki-67.

In summary, the present study shows that VEGF, weakly expressed in normal thyroid tissue, is strongly expressed in thyroid carcinoma as well as in thyrocytes of chronic lymphocytic thyroiditis. An intense VEGF production by differentiated thyroid carcinoma, attested either by a higher immunostaining score or a strong VEGF mRNA expression using ISH, could be a promising

marker of tumor aggressiveness and the trend to metastasise.

## Acknowledgements

We want hereby to acknowledge Prof. Werner Risau and Dr Georg Breier (Max-Planck-Institute, Bad Nauheim, Germany) who generously provided us with celerity and kindness the plasmid for VEGF probes, and Dr J-M Virion, from the Service d'Informatique Médicale, Epidémiologie et Statistiques for statistical assistance. This work was supported by grant from the Programme Hospitalier de Recherche Clinique 95 from Ministère des Affaires Sociales, de la Santé et de la Ville, France.

## References

- Aiello LP, Avery RL, Arrigg PG, Keyt BA, Jampel HD, Shah ST, Pasquale LR, Thieme H, Iwamoto MA, Park JE, Nguyen HV, Aiello LM, Ferrara N & King GL 1994 Vascular endothelial growth factor in ocular fluid of patients with diabetic retinopathy and other retinal disorders. *New England Journal of Medicine* **331** 1480–1487.
- Berse B, Brown LF, Van de Water L, Dvorak HF & Senger DR 1992 Vascular permeability factor (vascular endothelial growth factor) gene is expressed differentially in normal tissues, macrophages, and tumors. *Molecular Biology of the Cell* **3** 211–220.
- Brown LF, Harrist TJ, Yeo KT, Stahle BM, Jackman RW, Berse B, Tognazzi K, Dvorak HF & Detmar M 1995a Increased expression of vascular permeability factor (vascular endothelial growth factor) in bullous pemphigoid, dermatitis herpetiformis, and erythema multiforme. *Journal of Investigative Dermatology* **104** 744–749.
- Brown LF, Olbricht SM, Berse B, Jackman RW, Matsueda G, Tognazzi KA, Manseau EJ, Dvorak HF & Van de Water L 1995b Overexpression of vascular permeability factor (VPF/VEGF) and its endothelial cell receptors in delayed hypersensitivity skin reactions. *Journal of Immunology* **154** 2801–2807.
- Brown LF, Detmar M, Claffey K, Nagy JA, Feng A, Dvorak AM & Dvorak HF 1997 Vascular permeability factor/vascular endothelial growth factor: a multifunctional angiogenic cytokine. In *Regulation of Angiogenesis*, pp 233–269. Eds ID Goldberg & EM Rosen. Basel, Boston, Berlin: Birkhäuser.
- Cox KH, Deleon DV, Angerer LH & Angerer RC 1984 Detection of mRNAs in sea urchin embryo by *in situ* hybridization using asymmetric RNA probes. *Developmental Biology* **101** 485–502.
- De Vries C, Escobedo JA, Ueno H, Houck K, Ferrara N & Williams LT 1992 The fms-like tyrosine kinase, a receptor for vascular endothelial growth factor. *Science* **255** 989–991.
- Dvorak HF, Detmar M, Claffey KP, Nagy JA, Van De Water L & Senger DR 1995 Vascular permeability factor/vascular endothelial growth factor: an important mediator of angiogenesis in malignancy and inflammation. *International Archives of Allergy and Immunology* **107** 233–235.
- Fava RA, Olsen NJ, Spencer GG, Yeo KT, Yeo TK, Berse B, Jackman RW, Senger DR, Dvorak HF & Brown LF 1994 Vascular permeability factor/endothelial growth factor (VPF/VEGF): accumulation and expression in human synovial fluids and rheumatoid synovial tissue. *Journal of Experimental Medicine* **180** 341–346.
- Ferrara N 1995 The role of vascular endothelial growth factor in pathological angiogenesis. *Breast Cancer Research and Treatment* **36** 127–137.
- Ferrara N & Davis-Smyth T 1997 The biology of vascular endothelial growth factor. *Endocrine Reviews* **18** 4–25.
- Ferrara N & Keyt B 1997 Vascular endothelial growth factor: basic biology and clinical implications. In *Regulation of Angiogenesis*, pp 209–232. Eds ID Goldberg & EM Rosen. Basel, Boston, Berlin: Birkhäuser.
- Folkman J 1997 Angiogenesis and angiogenesis inhibition: an overview. In *Regulation of Angiogenesis*, pp 1–8. Eds ID Goldberg & EM Rosen. Basel, Boston, Berlin: Birkhäuser.
- Freeman MR, Schneck FX, Gagnon ML, Corless C, Soker S, Niknejad K, Peoples GE & Klagsbrun M 1995 Peripheral blood T lymphocytes and lymphocytes infiltrating human cancers express vascular endothelial growth factor: a potential role for T cells in angiogenesis. *Cancer Research* **55** 4140–4145.
- Iijima K, Yoshikawa N & Nakamura H 1996 Activation-induced expression of vascular permeability factor by human peripheral T cells: a non-radioisotopic semiquantitative reverse transcription-polymerase chain reaction assay. *Journal of Immunological Methods* **196** 199–209.
- Ito A, Hirota S, Mizuno H, Kawasaki Y, Takemura T, Nishiura T, Kanakura Y, Katayama Y, Nomura S & Kitamura Y 1995 Expression of vascular permeability factor (VPF/VEGF) messenger RNA by plasma cells: possible involvement in the development of edema in chronic inflammation. *Pathology International* **45** 715–720.
- Kamat BR, Brown LF, Manseau EJ, Senger DR & Dvorak HF 1995 Expression of vascular permeability factor/vascular endothelial growth factor by human granulosa and theca lutein cells. Role in corpus luteum development. *American Journal of Pathology* **146** 157–165.
- Katoh R, Bray CE, Suzuki K, Komiyama A, Hemmi A, Kawaoi A, Oyama T, Sugai T & Sasou S 1995 Growth activity in hyperplastic and neoplastic human thyroid determined by an immunohistochemical staining procedure using monoclonal antibody MIB-1. *Human Pathology* **26** 139–146.
- Koch AE, Harlow LA, Haines GK, Amento EP, Unemori EN, Wong WL, Pope RM & Ferrara N 1994 Vascular endothelial growth factor. A cytokine modulating endothelial function in rheumatoid arthritis. *Journal of Immunology* **152** 4149–4156.
- Kondo S, Asano M & Suzuki H 1993 Significance of vascular endothelial growth factor/vascular permeability factor for solid tumor growth, and its inhibition by the antibody. *Biochemical and Biophysical Research Communications* **194** 1234–1241.
- Ku DD, Zaleski JK, Liu S & Brock TA 1993 Vascular endothelial growth factor induces EDRF-dependent relaxation in coronary arteries. *American Journal of Physiology* **265** H586–H592.
- Okayasu I, Saegusa M, Fujiwara M, Hara Y & Rose NR 1995 Enhanced cellular proliferative activity and cell death in chronic thyroiditis and thyroid papillary carcinoma. *Journal of Cancer Research and Clinical Oncology* **121** 746–752.
- Pekala P, Marlow M, Heuvelman D & Connolly D 1990 Regulation of hexose transport in aortic endothelial cells by vascular permeability factor and tumor necrosis factor- $\alpha$ , but not by insulin. *Journal of Biological Chemistry* **265** 18051–18054.
- Plate KH, Breier G, Weich H & Risau W 1992 Vascular endothelial growth factor is a potential tumour angiogenesis factor in human gliomas *in vivo*. *Nature* **359** 845–848.
- Plouet J & Bayard F 1994 Regulations of vasculotropin/vascular endothelial growth factor bioavailability. *Hormone Research* **42** 14–19.
- Sato K, Yamazaki K, Shizume K, Kanaji Y, Obara T, Ohsumi K, Demura H, Yamaguchi S & Shibuya M 1995 Stimulation by thyroid-stimulating hormone and Graves' immunoglobulin G of vascular endothelial growth factor mRNA expression in human thyroid follicles *in vitro* and *in vivo* mRNA expression in the rat thyroid *in vivo*. *Journal of Clinical Investigation* **96** 1295–1302.
- Sato K, Miyakawa M, Onoda N, Demura H, Yamashita T, Miura M, Kasajima T, Yamazaki K & Obara T 1997 Increased concentration



- of vascular endothelial growth factor/vascular permeability factor in cyst fluid of enlarging and recurrent thyroid nodules. *Journal of Clinical Endocrinology and Metabolism* **82** 1968–1973.
- Senger DR, Van de Water L, Brown LF, Nagy JA, Yeo KT, Yeo TK, Berse B, Jackman RW, Dvorak AM & Dvorak HF 1993 Vascular permeability factor (VPF, VEGF) in tumor biology. *Cancer and Metastasis Reviews* **12** 303–324.
- Simon M, Gröne H-J, Jöhren O, Kullmer J, Plate KH, Risau W & Fuchs E 1995 Expression of vascular endothelial growth factor and its receptors in human renal ontogenesis and in adult kidney. *American Journal of Physiology* **268** F240–F250.
- Soh EY, Sobhi SA, Wong MG, Meng YG, Siperstein AE, Clark OH & Duh QY 1996 Thyroid-stimulating hormone promotes the secretion of vascular endothelial growth factor in thyroid cancer cell lines. *Surgery* **120** 944–947.
- Soh EY, Duh QY, Sobhi SA, Young DM, Epstein HD, Wong MG, Garcia YK, Min YD, Grossman RF, Siperstein AE & Clark OH 1997 Vascular endothelial growth factor expression is higher in differentiated thyroid cancer than in normal or benign thyroid. *Journal of Clinical Endocrinology and Metabolism* **82** 3741–3747.
- Viglietto G, Maglione D, Rambaldi M, Cerutti J, Romano A, Trapasso F, Fedele M, Ippolito P, Chiappetta G, Botti G, Fusco A & Persico, MG 1995 Upregulation of vascular endothelial growth factor (VEGF) and downregulation of placenta growth factor (PlGF) associated with malignancy in human thyroid tumors and cell lines. *Oncogene* **11** 1569–1579.
- Vignaud J-M, Marie B, Klein N, Plénat F, Pech M, Borrelly J, Martinet N, Duprez A & Martinet Y 1994 The role of platelet-derived growth factor production by tumor-associated macrophages in tumor stroma formation in lung cancer. *Cancer Research* **54** 5455–5463.
- Wang JF, Milosveski V, Schramek C, Fong GH, Becks GP & Hill DJ 1998 Presence and possible role of vascular endothelial growth factor in thyroid cell growth and function. *Journal of Endocrinology* **157** 5–12.

Received 13 May 1998

Revised manuscript received 9 September 1998

Accepted 4 November 1998