

UC Office of the President

Recent Work

Title

Vascular stroma formation in carcinoma in situ, invasive carcinoma, and metastatic carcinoma of the breast

Permalink

<https://escholarship.org/uc/item/28c8h62g>

Journal

Clinical Cancer Research, 5(5)

ISSN

1078-0432

Authors

Brown, L
Guidi, A
Stuart, SJ
[et al.](#)

Publication Date

2021-06-28

Peer reviewed

Vascular Stroma Formation in Carcinoma *in Situ*, Invasive Carcinoma, and Metastatic Carcinoma of the Breast¹

Lawrence F. Brown,² Anthony J. Guidi,
Stuart J. Schnitt, Livingston Van De Water,
Maria Luisa Iruela-Arispe, Tet-Kin Yeo,
Kathi Tognazzi, and Harold F. Dvorak

Departments of Pathology, Beth Israel Deaconess Medical Center and Harvard Medical School, Boston, Massachusetts 02215

ABSTRACT

The generation of vascular stroma is essential for solid tumor growth and involves stimulatory and inhibiting factors as well as stromal components that regulate functions such as cellular adhesion, migration, and gene expression. In an effort to obtain a more integrated understanding of vascular stroma formation in breast carcinoma, we examined expression of the angiogenic factor vascular permeability factor (VPF)/vascular endothelial growth factor (VEGF); the VPF/VEGF receptors flt-1 and KDR; thrombospondin-1, which has been reported to inhibit angiogenesis; and the stromal components collagen type I, total fibronectin, ED-A+ fibronectin, versican, and decorin by mRNA *in situ* hybridization on frozen sections of 113 blocks of breast tissue from 68 patients including 28 sections of breast tissue without malignancy, 18 with *in situ* carcinomas, 56 with invasive carcinomas, and 8 with metastatic carcinomas. A characteristic expression profile emerged that was remarkably similar in invasive carcinoma, carcinoma *in situ*, and metastatic carcinoma, with the following characteristics: strong tumor cell expression of VPF/VEGF; strong endothelial cell expression of VPF/VEGF receptors; strong expression of thrombospondin-1 by stromal cells and occasionally by tumor cells; and strong stromal cell expression of collagen type I, total fibronectin, ED-A+ fibronectin, versican, and decorin. The formation of vascular stroma preceded invasion, raising the possibility that tumor cells invade not into normal breast stroma but rather into a richly vascular stroma that they have induced. Similarly, tumor cells at sites of metastasis appear to induce the vascular

stroma in which they grow. We conclude that a distinct pattern of mRNA expression characterizes the generation of vascular stroma in breast cancer and that the formation of vascular stroma may play a role not only in growth of the primary tumor but also in invasion and metastasis.

INTRODUCTION

Generation of vascular stroma is an essential feature of solid tumor growth and is, indeed, necessary if tumors are to grow beyond a minimal size (1). A correlation between microvascular density and prognosis has been reported in breast cancer (2, 3). The formation of vascular stroma in breast cancer and other malignancies involves complex interactions among a variety of cell types including tumor cells, endothelial cells, and stromal cells, and there is a balance between factors that enhance and factors that inhibit angiogenesis. Stromal components also play a critical and often underappreciated role in the formation of vascular stroma through the regulation of functions such as cell adhesion, migration, and gene expression and by controlling the availability of growth factors (4-7). Much of the published research on vascular stroma formation has focused on the expression of growth factors that promote the process, but far less has been published on inhibiting factors and stromal components.

In an effort to obtain a more integrated understanding of vascular stroma formation in breast carcinoma, we examined mRNA expression by ISH³ on consecutive frozen sections from 113 blocks of breast tissue from 68 patients. We studied normal breast tissue, benign proliferative lesions, healing biopsy sites, *in situ* carcinomas, invasive carcinomas, and metastatic carcinomas. We examined expression of mRNAs for the angiogenic factor VPF/VEGF and its receptors flt-1 (VEGFR-1) and KDR (VEGFR-2), which have been reported to be up-regulated in a number of human cancers, including breast cancer (for review, see Ref. 8). We also studied expression of TSP-1, which has been reported to have antiangiogenic properties in a variety of systems (9-11). We also studied the stromal components collagen type I, total fibronectin, and ED-A+ fibronectin (a spliced variant of fibronectin strongly expressed in embryonic development). Fibronectins may play an important role in vascular stroma formation because they have been reported to be essential for heart and blood vessel morphogenesis (12), to be chemotactic for endothelial cells (13), to modulate endothelial response to growth factors (14), and to promote the elongation of microvessels during angiogenesis *in vitro* (15). We also studied the expression of the proteoglycans decorin and versican.

Received 8/20/98; revised 1/15/99; accepted 2/8/99.

The costs of publication of this article were defrayed in part by the payment of page charges. This article must therefore be hereby marked *advertisement* in accordance with 18 U.S.C. Section 1734 solely to indicate this fact.

¹ Supported by USPHS NIH Grants CA50453 and CA58845 (to H. F. D.), by grants from the Beth Israel Deaconess Medical Center Pathology Foundation, and by the Nell and Nancy Fund, a Cancer Prevention Fund supported by American Family Life Assurance Company Inc. and The Pine Mountain Benevolent Association (Cason J. Callaway, Jr., President).

² To whom requests for reprints should be addressed, at Department of Pathology, Beth Israel Deaconess Medical Center, 330 Brookline Avenue, Boston, MA 02215. Phone: (617) 667-4344; Fax: (617) 667-3591.

³ The abbreviations used are: ISH, *in situ* hybridization; VPF, vascular permeability factor; VEGF, vascular endothelial growth factor; TSP-1, thrombospondin-1; DCIS, ductal carcinoma *in situ*; LCIS, lobular carcinoma *in situ*.

can. Decorin has been reported to bind growth factors (16, 17) and also to decrease cell proliferation through up-regulation of p21 (18). All tissues studied had been freshly collected and optimally prepared for mRNA ISH. Although some of these components have been studied individually in breast cancer, they have not previously been investigated in an integrated manner.

MATERIALS AND METHODS

Study Material. One hundred thirteen blocks of breast tissue from 68 patients were studied. H&E-stained sections were reviewed by two pathologists (L. F. B. and S. J. S.). Invasive and *in situ* carcinomas were typed and graded according to the Elston and Ellis modification of the Bloom and Richardson system (19).

Twenty-one blocks of normal breast tissue, 2 healing biopsy sites, and 5 benign ductal proliferative lesions were examined. These sections were taken from the specimens with tumors but in areas well away from the tumor, and the absence of tumor in these sections was confirmed microscopically.

Invasive carcinoma was studied in 56 cases, including 43 invasive ductal carcinomas. Twenty-four of the invasive ductal carcinomas were grade III, 18 were grade II, and 1 was grade I. Eight invasive carcinomas with mixed ductal and lobular features, two cases of invasive lobular carcinoma, and three cases of invasive mucinous carcinoma were also studied. The mean age of patients with invasive carcinoma was 59.3 years (range, 28–97 years). The mean tumor diameter was 3.1 cm (range, 1.0–7.0 cm). Thirty-five patients were estrogen receptor positive. Eighteen patients had metastases to axillary lymph nodes. Twenty patients had identifiable lymphatic invasion.

DCIS was studied in 18 cases, LCIS was studied in 3 cases, metastatic carcinoma was studied in lymph nodes in 8 cases, and extensive carcinoma in dermal lymphatics was studied in 1 case.

ISH. Thin (2-mm) slices of fresh breast tissue were fixed in 4% paraformaldehyde in PBS, pH 7.4 (PBS), for 2–4 h at 4°C, transferred to 30% sucrose in PBS overnight at 4°C, frozen in OCT compound (Miles Diagnostics, Elkhart, IN), and stored at –70°C.

ISH was performed on 5- μ m frozen sections with 10 probes in most cases: VPF/VEGF, flt-1 (VEGFR-1), KDR (VEGFR-2), TSP-1, collagen type I, total fibronectin, ED-A+ fibronectin, decorin, versican, and a sense control probe. In a few cases, the amount of tissue was insufficient for study with all probes. The precise number of cases studied with each probe is detailed in “Results.”

Details of ISH have been published previously (20). Briefly, slides were passed through 0.2 M HCl-Tris-EDTA with 1 μ g/ml proteinase K, 0.2% glycine, 4% paraformaldehyde in PBS (pH 7.4), 0.1 M triethanolamine containing 1:200 (v/v) acetic anhydride, and 2 \times SSC. Slides were hybridized overnight at 50°C with ³⁵S-labeled riboprobes in the following mixture: 0.3 M NaCl, 0.01 M Tris (pH 7.6), 5 mM EDTA, 50% formamide, 10% dextran sulfate, 0.1 mg/ml yeast tRNA, and 0.01 M DTT. Posthybridization washes included 2 \times SSC, 50% formamide, and 10 mM DTT at 50°C; 4 \times SSC, 10 mM Tris, and 1 mM EDTA with 20 μ g/ml RNase A at 37°C; and 2 \times SSC, 50% formamide, and 10 mM DTT at 65°C; and 2 \times SSC. Slides were then

dehydrated through graded alcohols containing 0.3 M ammonium acetate, dried, coated with Kodak NTB 2 emulsion, and stored in the dark at 4°C for 2 weeks. The emulsion was developed with Kodak D19 developer, and the slides were counterstained with hematoxylin. Antisense 204-bp single-stranded ³⁵S-labeled VPF/VEGF RNA probe and its sense control were designed by B. Berse (Beth Israel Deaconess Medical Center, Boston, MA) and have been described previously (21). The antisense probe hybridizes specifically with a region of VPF/VEGF mRNA common to all known VPF/VEGF splicing variants. ³⁵S-labeled single-stranded antisense probes targeted to the kinase insert regions and sense RNA probes for the VPF/VEGF receptors flt-1 (225 bp) and KDR (209 bp) were designed by R.W. Jackman (Beth Israel Deaconess Medical Center, Boston, MA) and have been described previously (22). Probes for total fibronectin (270 bp; reacts with all forms of fibronectin) and ED-A+ fibronectin (213 bp; specific to the ED-A domain; Ref. 20) and collagen type I (600 bp; Ref. 23) have also been described previously. The probe for TSP-1 was 354 bp long and targeted to the 5' end of the coding region. The probe for versican was 241 bp long, and the probe for decorin was 277 bp long.

Expression of mRNA for stromal elements (collagen, total fibronectin, ED-A+ fibronectin, versican, and decorin) was often intense and was classified as strong if silver grains were obvious at low power (final magnification, \times 40 under the microscope), moderate if expression was not obvious under low power but could be easily detected under intermediate power (\times 100), and low if expression could only be detected under high power (\times 400). VPF/VEGF mRNA was expressed at much lower levels than mRNAs of stromal elements, and therefore, actual grain counts were performed over tumor cells. VPF/VEGF mRNA expression was rated as strong ($>$ 20 grains per cell), moderate (10–20 grains per cell), or low ($<$ 10 grains per cell). Expression of VPF/VEGF receptors was even less intense and was graded as either strong (\geq 5 grains per cell) or low ($<$ 5 grains per cell). All slides were exposed for 2 weeks before development.

Immunohistochemistry. Staining for factor VIII-related antigen was performed with a rabbit polyclonal antibody (Dako Corporation, Carpinteria, CA) at a dilution of 1:250, after pre-digestion with pepsin, using the peroxidase-antiperoxidase technique and diaminobenzidine as the chromogen.

RESULTS

Breast Tissue without Malignancy

Sections of breast tissue without malignancy were studied in 28 patients. In 21 of these cases, no significant pathology was detected in the histological sections (H&E-stained section Fig. 1a). Of the remaining seven cases, two contained a healing biopsy site that was 1–2 weeks old and five contained benign proliferative lesions with intraductal hyperplasia and variable surrounding inflammatory and stromal changes.

In normal breast tissue (Table 1), expression of VPF/VEGF mRNA by epithelial cells was low in nearly all cases (Fig. 2, a and b). Expression of VPF/VEGF receptors in endothelial cells was low in nearly all cases (Fig. 3, a and b). TSP-1 mRNA was expressed in three locations in normal breast tissue: stromal

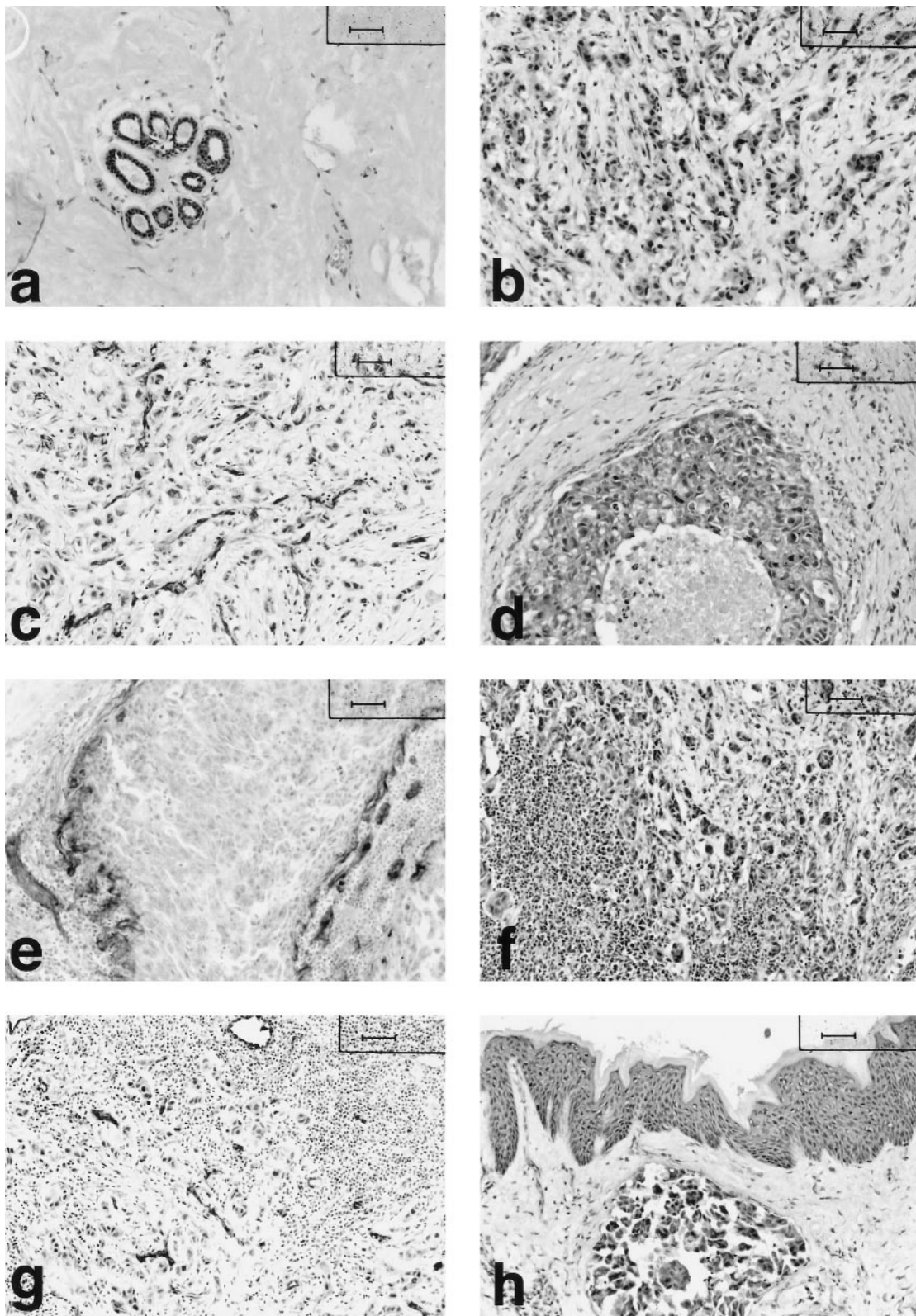


Fig. 1 H&E-stained sections of normal breast tissue (*a*), infiltrating ductal carcinoma (*b*), DCIS (*d*), metastatic carcinoma in a lymph node (*f*), and carcinoma in a dermal lymphatic space (*h*). Factor VIII immunostaining highlights the increased number of small vessels in invasive ductal carcinoma (*c*), rimming DCIS (*e*), and in metastatic carcinoma in a lymph node (*g*). Scale bars, 50 μ m.

Table 1 Results of ISH

Tissue mRNA expression	Normal breast tissue			Invasive ductal carcinoma			P
	Strong	Moderate	Low	Strong	Moderate	Low	
Stromal cells							
Collagen-type I	4	6	5	37	0	0	0.001 ^a
Fibronectin	0	3	16	35	0	0	≤0.001
ED-A + fibronectin	0	0	18	37	4	0	≤0.001
Decorin	16	4	1	35	7	0	0.3
Versican	0	1	16	15	24	1	≤0.001
TSP-1	2	13	4	40	1	0	0.008
Epithelial cells							
VPF/VEGF	0	1	18	23	12	7	≤0.001
TSP-1	3	14	2	4	23	13	0.1
Endothelial cells							
flt-1 (VEGFR-1)	0		14	35		1	≤0.001
KDR (VEGFR-2)	2		12	38		0	≤0.001

^a Fisher exact test comparing normal breast tissue to invasive ductal carcinoma (strong or moderate expression vs. low expression).

cells, ducts, and lobules (by both epithelial and myoepithelial cells), and in the blood vessels (Fig. 4, *a* and *b*). Epithelial expression was moderate in most cases and often very focal, with some cells in a duct expressing significant levels of TSP-1 mRNA and no expression in immediately adjacent cells. In some cases, expression was predominantly seen in epithelial cells, whereas in other cases, expression was predominantly seen in myoepithelial cells. Expression of TSP-1 mRNA in blood vessels and stromal fibroblasts was moderate in most cases. Collagen type I mRNA was variably expressed by stromal cells in normal breast tissue (Fig. 5, *a* and *b*). Total fibronectin mRNA expression by stromal cells in normal breast tissue was much less prominent than that of type I collagen and almost all cases had only low expression (Fig. 6, *a* and *b*). ED-A+ fibronectin mRNA expression by stromal cells was even less prominent (Fig. 7, *a* and *b*), with all cases of normal breast tissue showing only focal low expression. Decorin was the most strongly expressed stromal cell mRNA in normal breast tissue (Fig. 8, *a* and *b*), with strong expression in most cases. Versican expression by stromal cells was low level in nearly all cases (Fig. 9, *a* and *b*).

In both cases of healing biopsy site studied, VPF/VEGF mRNA expression was moderate in epithelial cells, whereas expression of VPF/VEGF receptors by endothelial cells was strong. Stromal expression of TSP-1 was strong in both cases, and epithelial TSP-1 expression was strong in one case and moderate in the other. Stromal cell expression of collagen type I, total fibronectin, ED-A+ fibronectin, and decorin mRNAs was strong in both cases. Stromal cell expression of versican mRNA was strong in one case and moderate in the other.

Expression patterns were more variable in the five cases of benign proliferative lesions studied. Epithelial VPF/VEGF expression was moderate in one case and low in four cases. Expression of VPF/VEGF receptor mRNAs by endothelial cells was strong in four cases and low in one case. Both stromal cell and epithelial expression of TSP-1 mRNA were strong in two cases and moderate in three. All cases showed strong expression of collagen type 1 mRNA by stromal cells. Stromal cell expression of total fibronectin was strong in one case and moderate in the others, whereas expression of ED-A+ fibronectin was mod-

erate in two cases and low in three. Stromal cell expression of decorin was strong in four cases and moderate in one, whereas versican expression was moderate in three cases and low in two.

Invasive Carcinoma

Invasive carcinoma was studied in 56 cases, including 43 cases of infiltrating ductal carcinoma (24 grade III, 18 grade II, and one grade I; Table 1; H&E stain, Fig. 1*b*; Factor VIII-related antigen immunostain, Fig. 1*c*), 8 cases with mixed ductal and lobular features, 2 cases of infiltrating lobular carcinoma, and 3 cases of mucinous carcinoma.

Infiltrating Ductal Carcinoma. No clear differences were seen in mRNA expression between the three grades of infiltrating ductal carcinoma, and the cases are described as a group (Table 1). However, only one case of grade I infiltrating ductal carcinoma was studied, and therefore, generalizations on grade I tumors are not possible.

VPF/VEGF mRNA expression by tumor cells was strong in more than half of cases (Fig. 2, *c* and *d*) and moderate in an additional 12 cases. VPF/VEGF receptor mRNA expression was strong focally in all cases (Fig. 3, *c* and *d*). Expression of TSP-1 mRNA by stromal cells was strong in nearly all cases (Fig. 4, *c* and *d*), whereas expression of TSP-1 by tumor cells was variable. Strong stromal cell expression of collagen (Fig. 5, *c* and *d*), total fibronectin (Fig. 6, *c* and *d*), ED-A+ fibronectin (Fig. 7, *c* and *d*), and decorin (Fig. 8, *c* and *d*) mRNAs was seen in nearly all cases. Versican expression was more variable (Fig. 9, *c* and *d*), with strong expression in 15 cases, moderate expression in 24 cases, and low expression in 2 cases.

Invasive Lobular Carcinoma and Invasive Carcinomas with Mixed Ductal and Lobular Features. Two cases of classic invasive lobular carcinoma were studied. In one case, the pattern was very different from that of invasive ductal carcinoma, with low expression of VPF/VEGF and its receptors, TSP-1, collagen, total fibronectin, ED-A+ fibronectin, and versican mRNAs, and moderate expression of decorin.

The profile of the second case more closely resembled that of invasive ductal carcinoma, with moderate expression of VPF/VEGF and strong expression of VEGF receptors. TSP-1 was strongly expressed by the stromal cells but not the tumor cells.

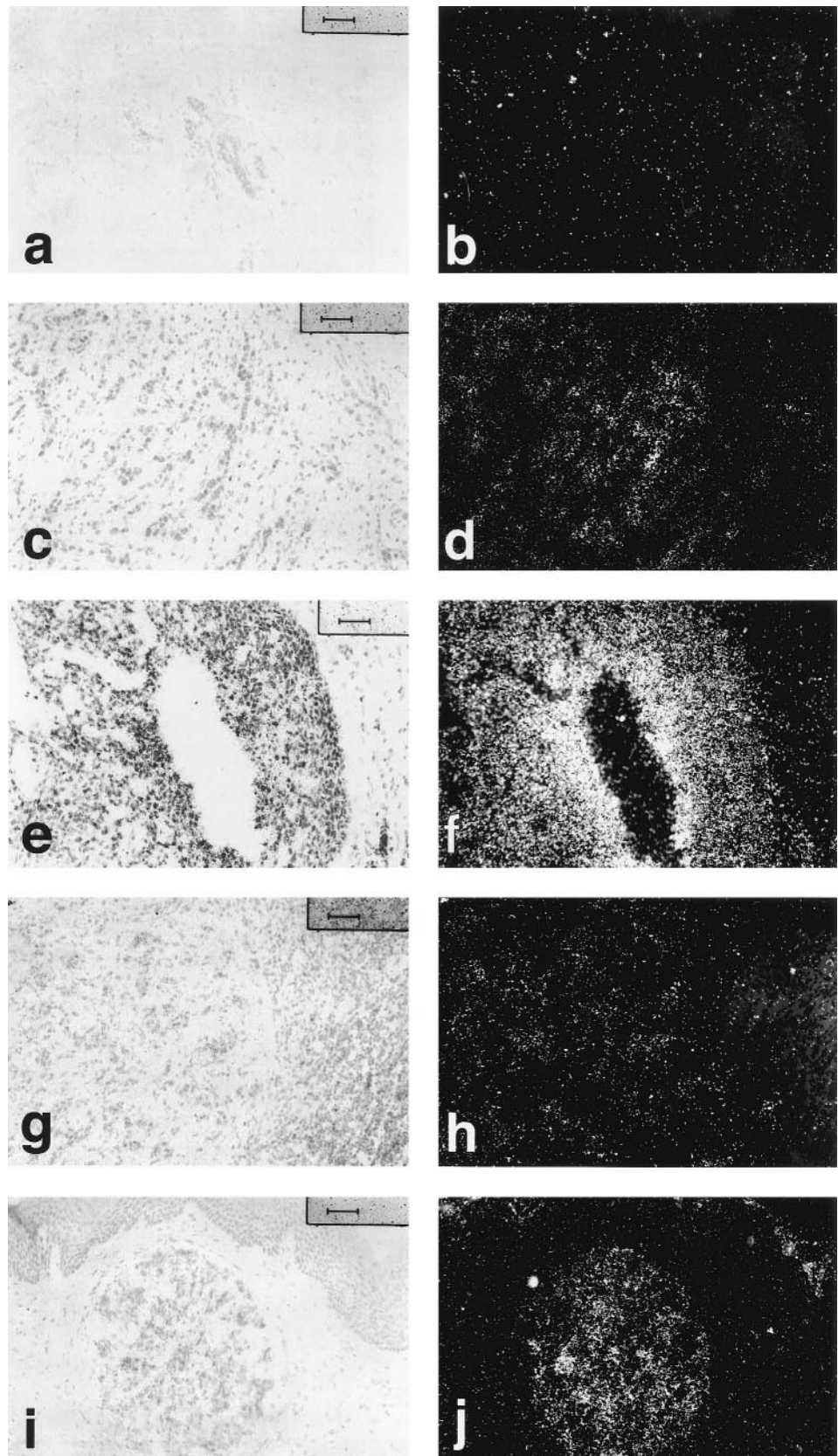


Fig. 2 ISH for VPF/VEGF mRNA. Bright-field and corresponding dark-field photomicrographs of normal breast tissue (*a* and *b*), invasive ductal carcinoma (*c* and *d*), DCIS (*e* and *f*), metastatic carcinoma in a lymph node (*g* and *h*), and carcinoma in a dermal lymphatic space (*i* and *j*). Scale bars, 50 μ m.

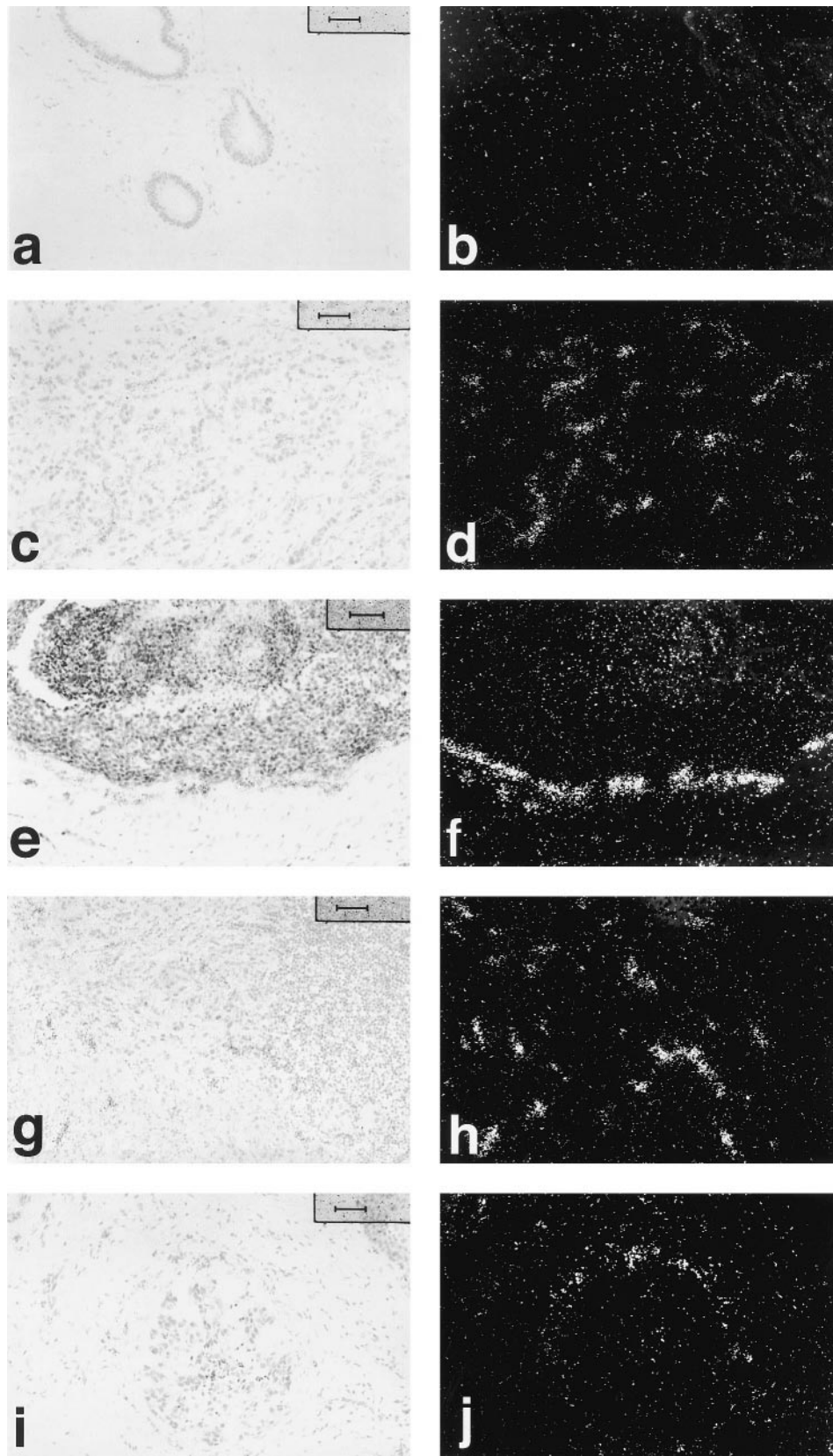
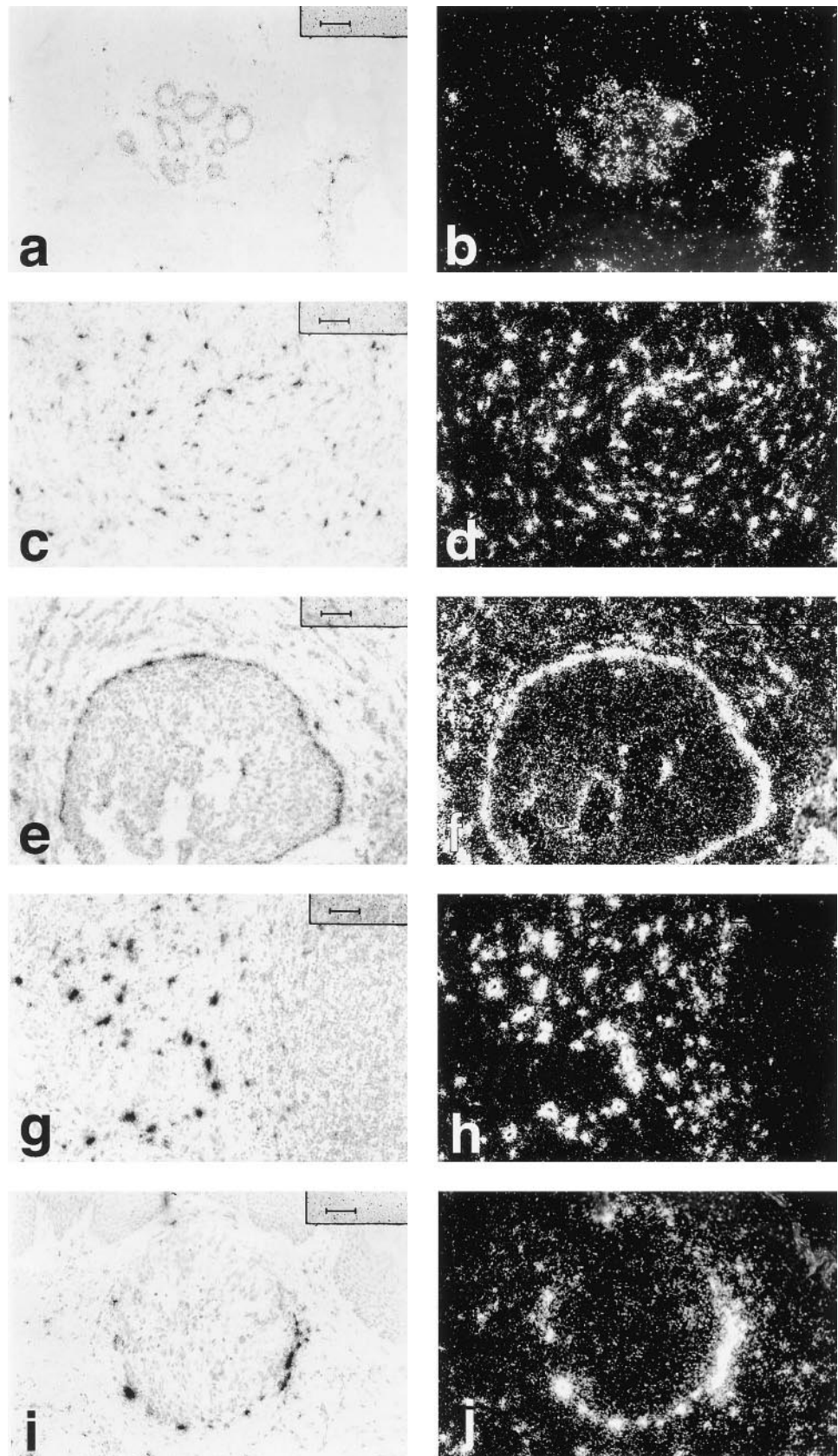


Fig. 3 ISH for *flt-1* mRNA. Bright-field and corresponding dark-field photomicrographs of normal breast tissue (*a* and *b*) showing no distinct expression by endothelial cells, invasive ductal carcinoma (*c* and *d*) with strong expression by endothelial cells in small vessels, DCIS (*e* and *f*) with strong expression by endothelial cells in small vessels immediately adjacent to the DCIS, metastatic carcinoma in a lymph node (*g* and *h*) with strong expression by endothelial cells in small vessels between tumor cells, and carcinoma in a dermal lymphatic space (*i* and *j*) with strong expression by endothelial cells lining small vessels immediately adjacent to the lymphatic space. Scale bars, 50 μ m.

Fig. 4 ISH for TSP-1 mRNA. Bright-field and corresponding dark-field photomicrographs of normal breast tissue (*a* and *b*) showing strong expression by epithelial cells at center, endothelial cells at lower right and scattered stromal cells; invasive ductal carcinoma (*c* and *d*) with strong expression by stromal cells; DCIS (*e* and *f*) with strong expression by myoepithelial cells and surrounding stromal cells; metastatic carcinoma in a lymph node (*g* and *h*) with strong expression by stromal cells between tumor cells; and carcinoma in a dermal lymphatic space (*i* and *j*) with strong expression by stromal cells adjacent to the lymphatic space. Scale bars, 50 μ m.



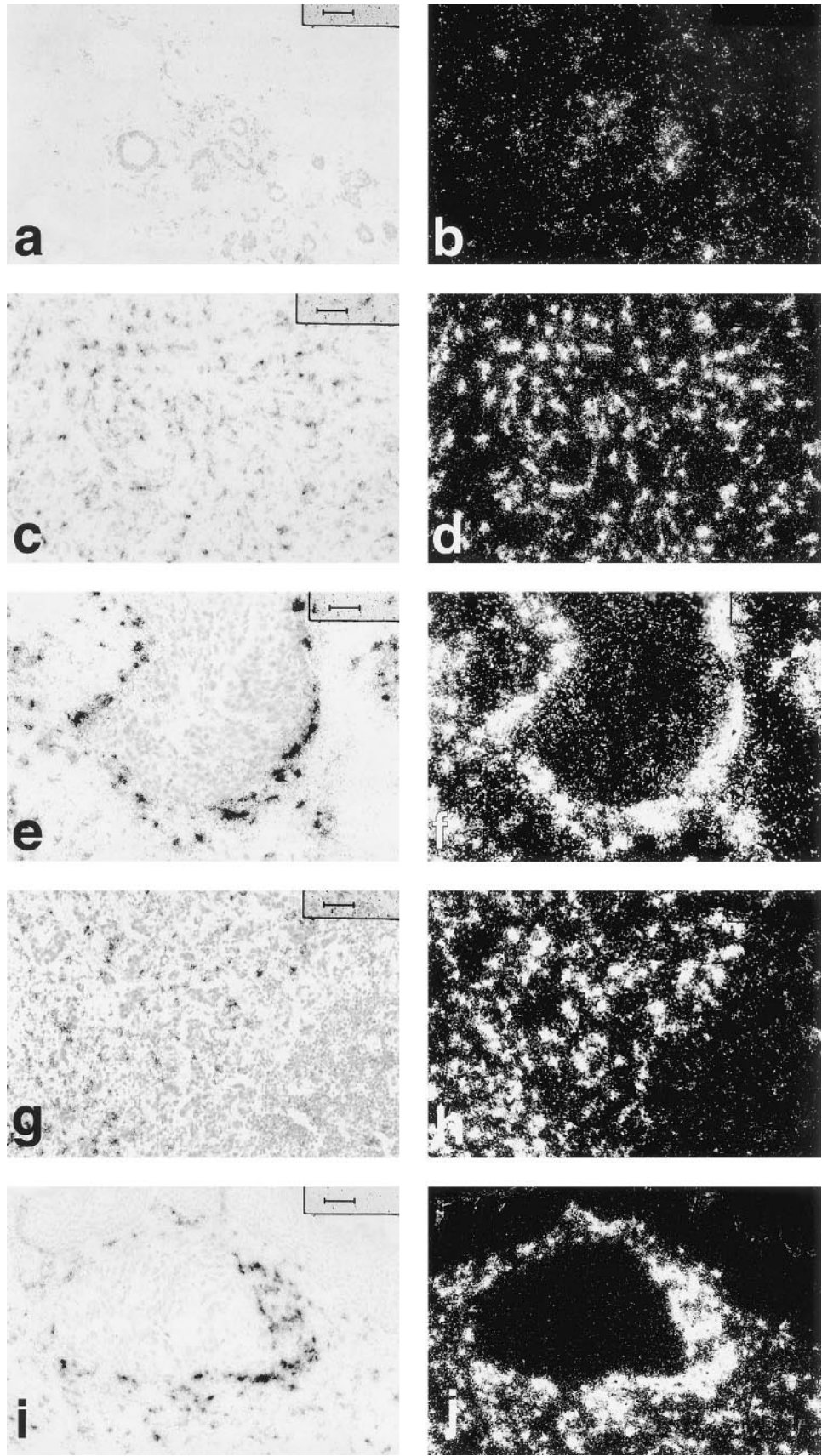


Fig. 5 ISH for collagen type I mRNA. Bright-field and corresponding dark-field photomicrographs of normal breast tissue (*a* and *b*) showing moderate expression by stromal cells, invasive ductal carcinoma (*c* and *d*) with strong expression by stromal cells, DCIS (*e* and *f*) with strong expression by stromal cells rimming the DCIS, metastatic carcinoma in a lymph node (*g* and *h*) with strong expression by stromal cells between the tumor cells, and carcinoma in a dermal lymphatic space (*i* and *j*) with strong expression by stromal cells adjacent to the lymphatic space. Scale bars, 50 μ m.

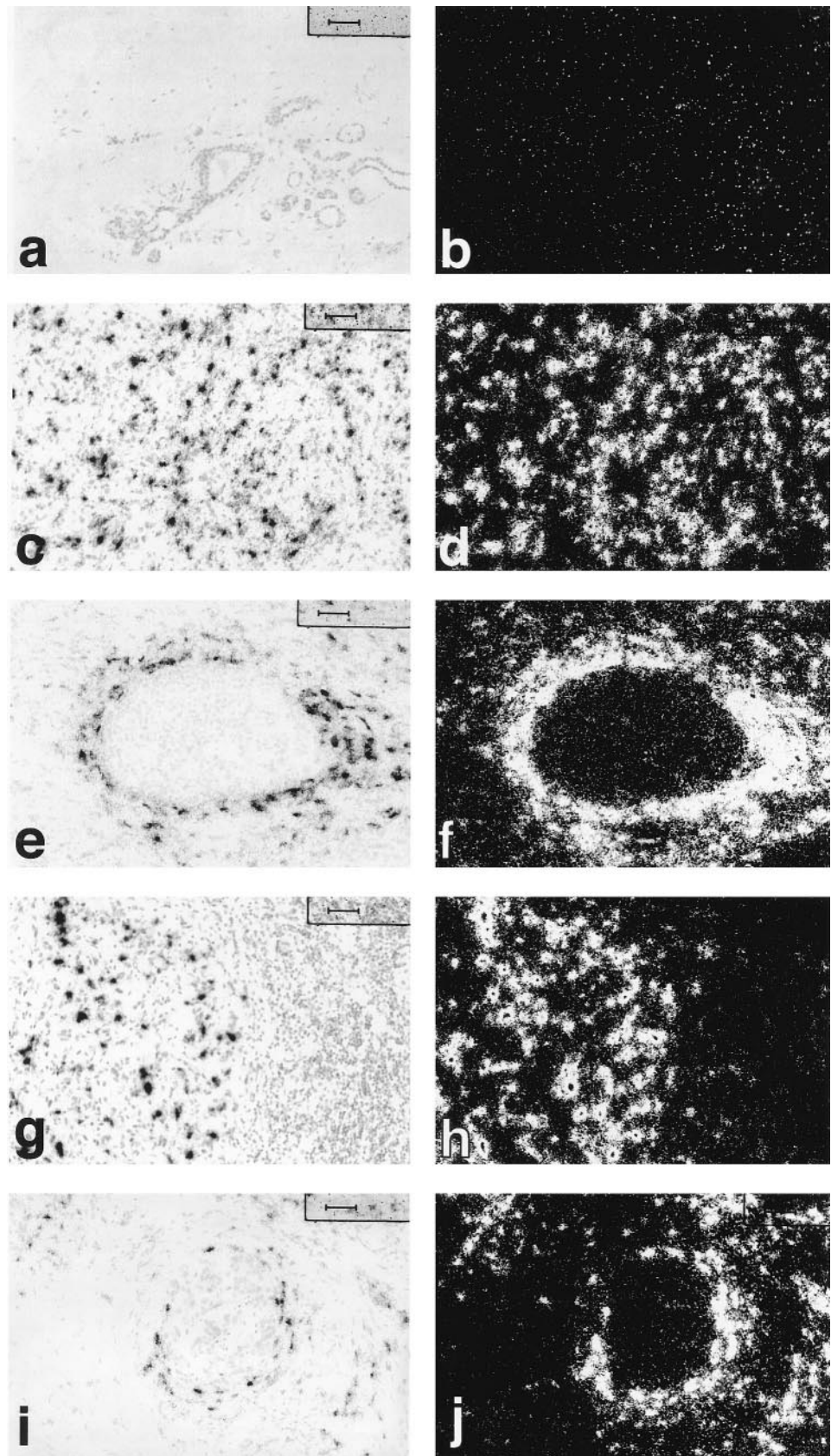


Fig. 6 ISH for total fibronectin mRNA. Bright-field and corresponding dark-field photomicrographs of normal breast tissue (*a* and *b*) showing no significant expression by stromal cells, invasive ductal carcinoma (*c* and *d*) with strong expression by stromal cells, DCIS (*e* and *f*) with strong expression by stromal cells rimming the DCIS, metastatic carcinoma in a lymph node (*g* and *h*) with strong expression by stromal cells between the tumor cells, and carcinoma in a dermal lymphatic space (*i* and *j*) with strong expression by stromal cells adjacent to the lymphatic space. Scale bars, 50 μ m.

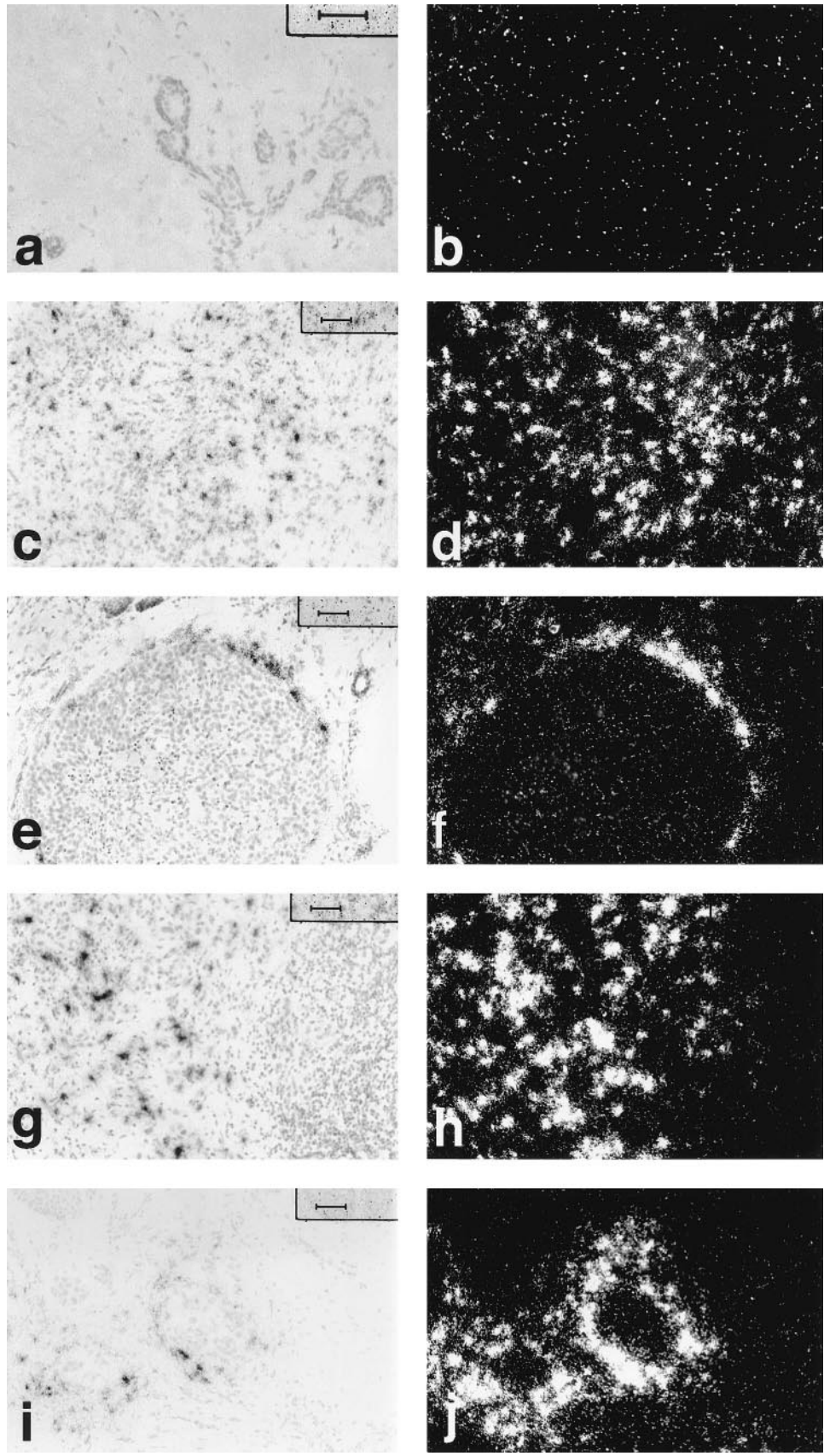


Fig. 7 ISH for ED-A+ fibronectin mRNA. Bright-field and corresponding dark-field photomicrographs of normal breast tissue (*a* and *b*) showing no significant expression by stromal cells, invasive ductal carcinoma (*c* and *d*) with strong expression by stromal cells, DCIS (*e* and *f*) with strong expression by stromal cells rimming the DCIS, metastatic carcinoma in a lymph node (*g* and *h*) with strong expression by stromal cells between the tumor cells, and carcinoma in a dermal lymphatic space (*i* and *j*) with strong expression by stromal cells adjacent to the lymphatic space. Scale bars, 50 μ m.

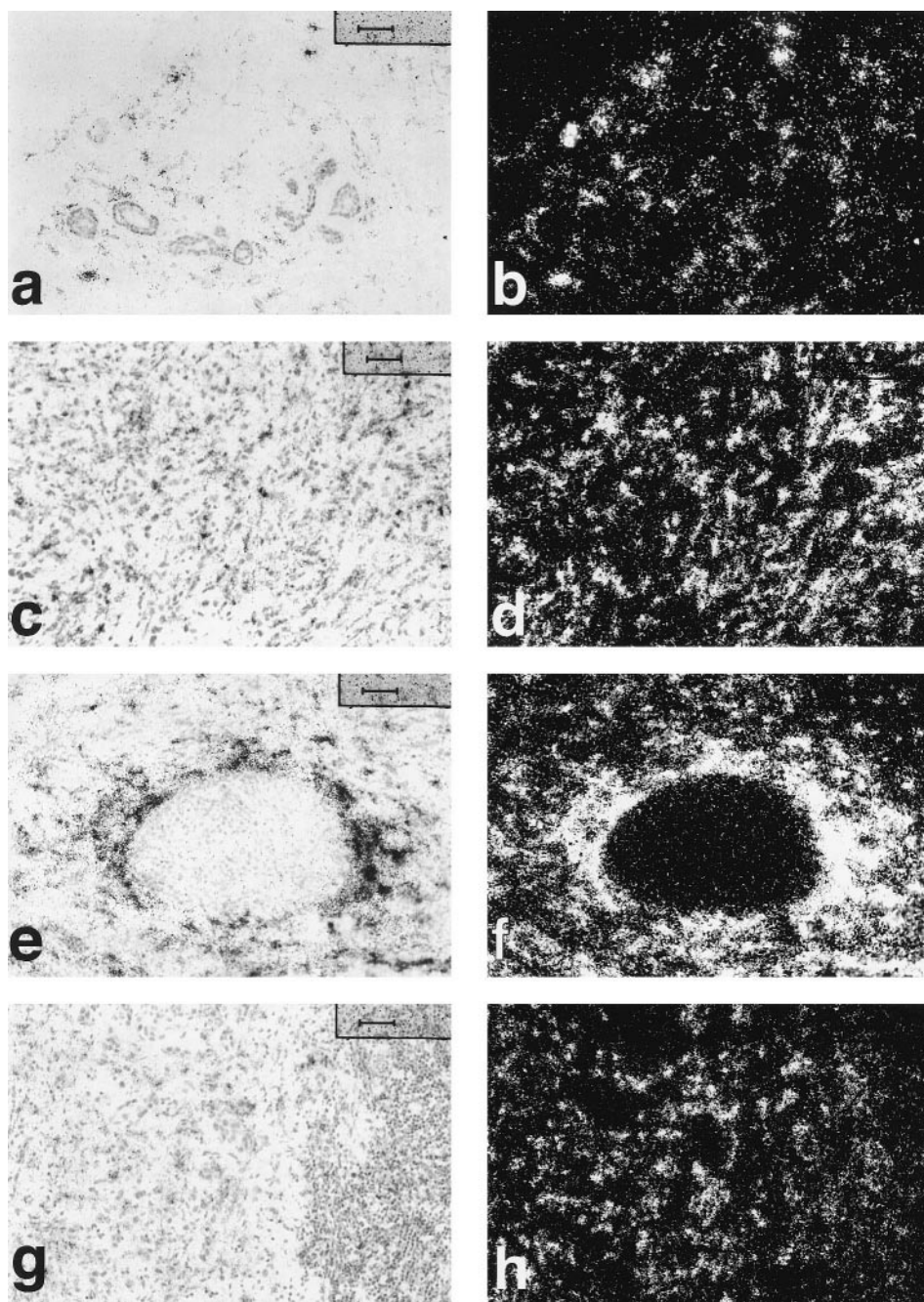


Fig. 8 ISH for decorin mRNA. Bright-field and corresponding dark-field photomicrographs of normal breast tissue (*a* and *b*) showing strong expression by stromal cells, invasive ductal carcinoma (*c* and *d*) with strong expression by stromal cells, DCIS (*e* and *f*) with strong expression by stromal cells that appears further increased in stromal cells rimming the DCIS, and metastatic carcinoma in a lymph node (*g* and *h*) with strong expression by stromal cells between the tumor cells. Scale bars, 50 μ m.

There was strong expression of collagen, total fibronectin, ED-A+ fibronectin, and decorin and moderate expression of versican.

Eight cases of invasive carcinoma with mixed ductal and lobular features were studied. The pattern of mRNA expression was similar to that seen in invasive ductal carcinoma: VPF/VEGF, five moderate and two low; stromal cell TSP-1, four strong and three moderate; tumor cell TSP-1, one strong, four moderate, and two low; collagen, eight strong; total fibronectin, six strong and two moderate; ED-A+ fibronectin, seven strong and one moderate; decorin, seven strong and one moderate;

versican, five moderate and two low; flt-1, six strong and one low; and KDR, six strong and one low.

Mucinous Carcinoma. Three cases of mucinous carcinoma were studied. The mRNA expression patterns were similar to those seen in invasive ductal carcinoma: VPF/VEGF, one moderate and two low; flt-1, two strong; KDR, two strong; stromal cell TSP-1, three strong; and tumor cell TSP-1, one strong, one moderate, and one low; collagen, two strong; total fibronectin, three strong; ED-A+ fibronectin, two strong and one moderate; decorin, three strong; and versican, two moderate.

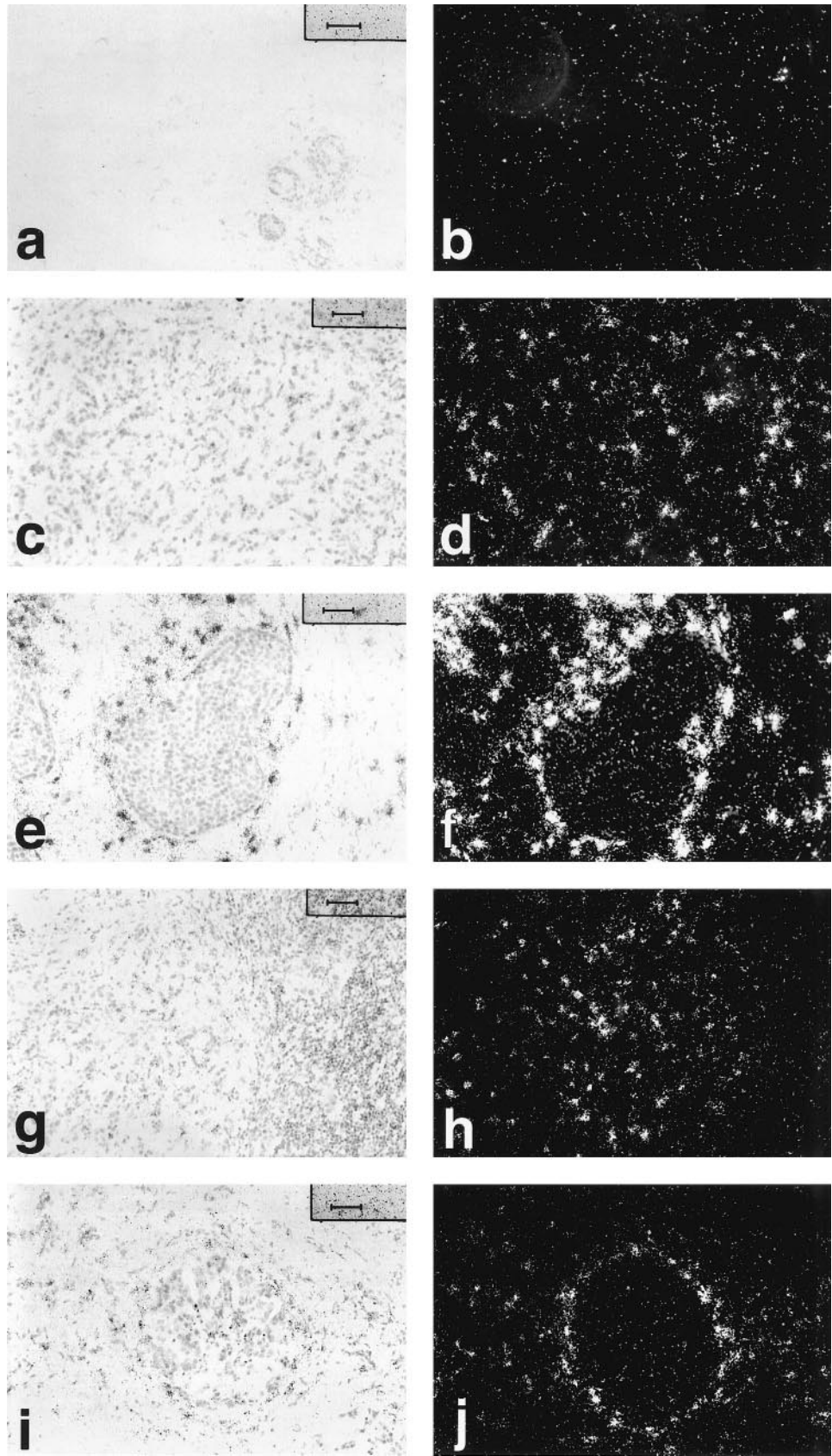


Fig. 9 ISH for versican mRNA. Bright-field and corresponding dark-field photomicrographs of normal breast tissue (*a* and *b*) showing no significant expression by stromal cells, invasive ductal carcinoma (*c* and *d*) with strong expression by stromal cells, DCIS (*e* and *f*) with strong expression by stromal cells rimming the DCIS, metastatic carcinoma in a lymph node (*g* and *h*) with strong expression by stromal cells between the tumor cells, and carcinoma in a dermal lymphatic space (*i* and *j*) with strong expression by stromal cells adjacent to the lymphatic space. Scale bars, 50 μ m.

In Situ Carcinoma

DCIS. Eighteen patients had evaluable DCIS (H&E stain, Fig. 1*d*; Factor VIII-related antigen stain, Fig. 1*e*). Fourteen of these patients had invasive carcinoma, and 4 had DCIS only. In cases that contained a mixture of *in situ* and invasive carcinoma, labeling was considered to be associated with the DCIS only if it clearly stood out from the labeling seen in the invasive component on the slide. Eleven of the 18 DCIS cases were grade III, 6 were grade II, and 1 was grade I.

VPF/VEGF mRNA expression by the epithelial cells in DCIS was strong in nine cases (Fig. 2, *e* and *f*), moderate in four cases and low in five cases. Expression was increased adjacent to central necrosis in DCIS. Expression of mRNAs of the VPF/VEGF receptors (flt-1 and KDR) was evaluable in 16 cases and both receptors were expressed in similar fashion. In nine cases, strong expression of receptor mRNA was seen in endothelial cells of small vessels immediately adjacent to the DCIS, with these small vessels forming a distinct and nearly continuous rim around the DCIS (Fig. 3, *e* and *f*). In four cases, there was strong expression in small vessels near the DCIS, but no distinct rimming pattern was seen. In three cases, no strong expression of receptors was seen in close proximity to the DCIS.

Expression of TSP-1 was distinctive. Strong labeling, visible under low power, was seen in the basal layer of myoepithelial cells in all 18 cases examined (Fig. 4, *e* and *f*). Focal stromal cell expression was also noted adjacent to the DCIS.

Increased collagen (Fig. 5, *e* and *f*), total fibronectin (Fig. 6, *e* and *f*), and ED-A+ fibronectin (Fig. 7, *e* and *f*) mRNA synthesis was detected in the stromal cells immediately adjacent to DCIS in 14 of 15 evaluable cases. In eight of these cases, a distinct rim of strong stromal expression was seen at least focally around the DCIS. In the other six cases, expression was increased adjacent to the DCIS, but a strong continuous rimming pattern was not apparent. In one case, no distinct increase in expression was seen adjacent to the DCIS in comparison to stromal expression in the admixed invasive carcinoma.

In contrast to the other stromal markers, decorin expression showed a distinct rimming pattern in only two cases (Fig. 8, *e* and *f*), an increase adjacent to DCIS but no distinct rimming in seven cases, and no distinct increase above surrounding stroma in nine cases. Versican had a similar pattern (Fig. 9, *e* and *f*), with 2 cases with rimming, 4 cases with an increase near the DCIS without distinct rimming, and 12 cases without a definite increase above surrounding stroma.

LCIS. LCIS was present in three cases. All cases were admixed with invasive carcinoma. The pattern was quite different from that in DCIS. VPF/VEGF expression was moderate in one case and low in two cases. No distinct increase in VPF/VEGF receptor expression was seen adjacent to LCIS. Focal strong expression of TSP-1 was seen in myoepithelial cells in two of the three cases. No distinct increase in collagen, total fibronectin, ED-A+ fibronectin, decorin, or versican expression was seen adjacent to the *in situ* carcinoma in any of the cases.

Metastatic Carcinoma. Eight cases of carcinoma metastatic to axillary lymph nodes were studied (H&E stain, Fig. 1*f*; Factor VIII-related antigen immunostain, Fig. 1*g*). Seven cases were ductal type (five grade III and two grade II), and one case had mixed ductal and lobular features (grade II). Patterns of

mRNA expression were remarkably similar to those seen in invasive breast carcinomas at the primary site: VPF/VEGF, three strong, four moderate, and one low (Fig. 2, *g* and *h*); VPF/VEGF receptors, strong in endothelial cells in all cases (Fig. 3, *g* and *h*); stromal TSP-1, five strong and one moderate (Fig. 4, *g* and *h*); tumor cell expression of TSP-1, one strong, three moderate, and two low; collagen type I, all strong (Fig. 5, *g* and *h*); total fibronectin, all strong (Fig. 6, *g* and *h*); ED-A+ fibronectin, five strong and three moderate (Fig. 7, *g* and *h*); decorin, all strong (Fig. 8, *g* and *h*); and versican, all moderate (Fig. 9, *g* and *h*). Expression of all mRNAs studied decreased sharply at the border with normal lymph node tissue.

Carcinoma in Lymphatics. Our case material included one excellent example of carcinoma cells within the dermal lymphatics of breast skin well away from the primary tumor (H&E stain, Fig. 1*h*). The tumor cells strongly expressed VPF/VEGF mRNA (Fig. 2, *i* and *j*), and small vessels around the lymphatic spaces strongly expressed flt-1 (Fig. 3, *i* and *j*) and KDR. TSP-1 mRNA was strongly expressed by stromal cells surrounding the lymphatics (Fig. 4, *i* and *j*). Stromal cells surrounding the lymphatics also strongly expressed mRNAs for collagen type I (Fig. 5, *i* and *j*), total fibronectin (Fig. 6, *i* and *j*), and ED-A+ fibronectin (Fig. 7, *i* and *j*) and moderately expressed versican mRNA (Fig. 9, *i* and *j*).

DISCUSSION

The formation of vascular stroma, which is essential for tumor growth beyond a minimal size (1), involves complex interactions between a variety of cell types, including malignant epithelial cells, stromal cells of various types, and vascular endothelium. Interactions between cells, stromal components, and growth factors regulate functions such as cell division, adhesion, migration, and differential gene expression (4–7). In an effort to gain a more comprehensive understanding of the formation of vascular stroma in breast cancer, we examined expression of selected cytokines and receptors that promote or inhibit angiogenesis as well as expression of selected stromal components on consecutive frozen sections from 113 blocks of breast tissue from 68 patients. All tissues studied had been freshly collected and optimally prepared for mRNA ISH. Although some of these components have been studied individually in breast cancer (see below), they have not been studied in consecutive sections in relation to each other or in a systematic manner including normal breast tissue, benign proliferative lesions, *in situ* carcinomas, invasive carcinomas, and metastatic carcinomas.

Invasive ductal carcinomas of the breast showed a remarkably consistent pattern of expression of the mRNAs studied. There was strong expression of VPF/VEGF mRNA by tumor cells and strong expression of the VPF/VEGF receptors flt-1 and KDR in the endothelial cells of small vessels in the tumor. There was also marked up-regulation of mRNAs of collagen type I, total fibronectin, ED-A+ fibronectin, versican, and TSP-1 in stromal cells. Decorin was strongly expressed in stromal cells in invasive ductal carcinomas, but strong expression of decorin was also found in stromal cells in many cases of normal breast tissue.

Of interest, the patterns of mRNA expression in DCIS were very similar to those seen in invasive carcinomas. There was

strong expression of VPF/VEGF mRNA by tumor cells and strong expression of VPF/VEGF receptor mRNAs by endothelial cells in small vessels immediately adjacent to foci of DCIS. There was strong expression of mRNAs for collagen type I, total fibronectin, ED-A+ fibronectin, decorin, versican, and TSP-1 immediately adjacent to DCIS. This raises the interesting possibility that, in the progression from *in situ* cancer to invasive cancer, the tumor cells may not be invading into normal breast stroma but rather into a highly vascular, substantially modified stroma that the tumor cells themselves have induced. It is possible that these changes may be a prerequisite to the process of invasion.

Identical patterns of mRNA expression were also seen in metastatic carcinoma in lymph nodes. Therefore, metastatic tumor cells were not growing in the normal lymph node tissue *per se* but rather in a highly vascular and substantially modified stroma that tumor cells had induced locally within the lymph node. Generation of this characteristic vascular stroma may be important or even essential to tumor growth at sites of metastasis.

To our surprise, the same patterns of expression could also be seen immediately adjacent to tumor cells in dermal lymphatics of breast skin in areas away from the primary tumor. The creation of a characteristic vascular stroma appears to be initiated focally, even while the cells are in transit through the lymphatics.

Although these expression patterns may be characteristic of *in situ*, invasive, and metastatic breast carcinoma and critical to the formation of vascular stroma and neoplastic progression, they are not specific for malignancy. Similar patterns of expression were seen in healing biopsy sites and in some benign proliferative lesions. Increased expression of VPF/VEGF and angiogenesis have been noted in both healing wounds and certain types of inflammation (reviewed in Ref. 7).

VPF, also known as VEGF, is an important multifunctional angiogenic cytokine that is strongly expressed in a variety of human tumors (reviewed in Ref. 8). VPF/VEGF binds to endothelial cells by at least two specific cell surface tyrosine kinase receptors, flt-1 and KDR (24, 25). VPF/VEGF induces microvascular permeability, leading to the extravasation of plasma proteins with consequent proangiogenic stromal changes (26, 27). VPF/VEGF is also an endothelial cell mitogen (28–31), and it alters the synthetic profile of endothelial cells in a manner that may promote angiogenesis (32, 33). Angiogenesis and tumor growth have been suppressed by inhibition of VPF/VEGF or its receptors in several experimental models (34, 35). The consistent overexpression of mRNAs for VPF/VEGF and its receptors in the breast cancer specimens in our study indicate an important role in the formation of vascular stroma.

Increased expression of VPF/VEGF, flt-1, and KDR has been described previously in breast cancer (36), and this study confirms and extends those findings in a much larger group of patients. VPF/VEGF expression has been correlated with both vessel count and survival in invasive breast carcinoma (37–39) and with angiogenesis in DCIS (40).

TSP-1 has been reported to have antiangiogenic properties in a variety of systems (9–11). Transfection of TSP-1 into breast cancer cell lines decreased angiogenesis, tumor growth, and metastasis in nude mice (41). Increased staining for TSP-1 has

been reported in the stroma of breast carcinoma (42–44). In addition, TSP-1 mRNA was reported to be increased in invasive breast carcinoma by PCR (45). Our results confirm these findings. There was a marked up-regulation of expression of TSP-1 mRNA by stromal cells in invasive, metastatic and *in situ* breast cancer compared to expression by stromal cells in normal breast tissue. We speculate that increased stromal expression of TSP-1 may be an attempt to inhibit angiogenesis induced by growth factors such as VPF/VEGF. Clearly the balance falls on the side of angiogenesis, but it is not entirely unexpected that expression of angiogenesis inhibitors should be up-regulated as well.

Increased expression of stromal components such as collagen type I (46), proteoglycans (47–51), and fibronectins (52–57) has been described in breast cancer. Various matrix components can bind growth factors and either enhance or block their activity. For example, decorin has been reported to bind transforming growth factor- β (16, 17). Decorin has also been reported to inhibit cell proliferation by up-regulation of p21, an inhibitor of cyclin-dependent kinases (18). However, although decorin was strongly expressed by stromal cells in most tumors studied, it was also strongly expressed in most normal breast tissue that we studied.

The fibronectins are a family of alternatively spliced proteins differing in three domains in humans: ED-A, ED-B, and IIICS (58). The fibronectin isoforms are expressed at low levels in normal adult tissues, but increased expression has been reported during wound healing, cardiac hypertrophy, liver fibrosis, pulmonary fibrosis, glomerulonephritis, and cardiac transplantation (reviewed in Ref. 59). Fibronectins likely play an essential role in the process of vascular stroma formation. Fibronectins have been reported to be essential for heart and blood vessel morphogenesis (12), to be chemotactic for endothelial cells (13), to modulate endothelial response to TGF- β (14), and to promote the elongation of microvessels during angiogenesis *in vitro* (15). ED-A+ fibronectin has also been reported to be expressed by stromal cells in colon cancer (60). Consistent with an important role in the formation of vascular stroma in breast cancer, total fibronectin and ED-A+ fibronectin were strongly expressed in virtually all tumors studied but only weakly expressed in normal breast tissue.

In summary, the formation of vascular stroma in breast carcinoma is a process that involves complex reciprocal interactions among tumor cells, endothelial cells, and stromal cells. Although the process is complex, a characteristic mRNA expression profile was identified in this study that was remarkably similar in carcinoma *in situ*, invasive carcinoma, carcinoma in lymphatic spaces, and metastatic carcinoma. This study provides insight into the process of vascular stroma formation in malignancy and the possible role that vascular stroma may play in neoplastic progression.

REFERENCES

1. Folkman, J., and Shing, Y. Angiogenesis. *J. Biol. Chem.*, 267: 10931–10934, 1992.
2. Weidner, N., Semple, J. P., Welch, W. R., and Folkman, J. Tumor angiogenesis and metastasis: correlation in invasive breast carcinoma. *N. Engl. J. Med.*, 324: 1–8, 1991.
3. Weidner, N., Folkman, J., Possa, F., Bevilacqua, P., Allred, E. N., Moore, D. H., Meli, S., and Gasparini, G. Tumor angiogenesis: a new

- significant and independent prognostic indicator in early-stage breast carcinoma. *J. Natl. Cancer Inst. (Bethesda)*, *84*: 1875–1887, 1992.
4. Ashkenas, J., Muschler, J., and Bissell, M. J. The extracellular matrix in epithelial biology: shared molecules and common themes in distant phyla. *Dev. Biol.*, *180*: 433–444, 1996.
 5. Iozzo, R. V. Tumor stroma as a regulator of neoplastic behavior. *Lab. Invest.*, *73*: 157–160, 1995.
 6. Senger, D. R. Molecular framework for angiogenesis: a complex web of interactions between extravasated plasma proteins and endothelial cell proteins induced by angiogenic cytokines. *Am. J. Pathol.*, *149*: 1–7, 1996.
 7. Dvorak, H. F., Nagy, J. A., and Dvorak, A. M. Structure of solid tumors and their vasculature: implications for therapy with monoclonal antibodies. *Cancer Cells*, *3*: 77–85, 1991.
 8. Dvorak, H. F., Brown, L. F., Detmar, M., and Dvorak, A. M. Vascular permeability factor/vascular endothelial growth factor, microvascular hyperpermeability and angiogenesis. *Am. J. Pathol.*, *146*: 1029–1039, 1995.
 9. Good, D. J., Polverini, P. J., Rastinejad, F., Le Beau, M. M., Lemons, R. S., Frazier, W. A., and Bouck, N. P. A tumor suppressor-dependent inhibitor of angiogenesis is immunologically and functionally indistinguishable from a fragment of thrombospondin. *Proc. Natl. Acad. Sci. USA*, *87*: 6624–6628, 1990.
 10. Iruela-Arispe, M. L., Bornstein, P., and Sage, H. Thrombospondin exerts an antiangiogenic effect on tube formation by endothelial cells *in vitro*. *Proc. Natl. Acad. Sci. USA*, *88*: 5026–5030, 1991.
 11. Tolsma, S. S., Volpert, O. V., Good, D. J., Frazier, W. A., Polverini, P. J., and Bouck, N. Peptides derived from two separate domains of the matrix protein thrombospondin-1 have anti-angiogenic activity. *J. Cell Biol.*, *122*: 497–511, 1993.
 12. George, E. L., Baldwin, H. S., and Hynes, R. O. Fibronectins are essential for heart and blood vessel morphogenesis but are dispensable for initial specification of precursor cells. *Blood*, *90*: 3073–3081, 1997.
 13. Bowersox, J. C., and Sorgente, N. Chemotaxis of aortic endothelial cells in response to fibronectin. *Cancer Res.*, *42*: 2547–2551, 1982.
 14. Madri, J. A., Pratt, B. M., and Tucker, A. M. Phenotypic modulation of endothelial cells by transforming growth factor- β depends upon the composition of the extracellular matrix. *J. Cell Biol.*, *106*: 1375–1384, 1988.
 15. Nicosia, R. F., Bonnano, E., and Smith, M. Fibronectin promotes the elongation of microvessels during angiogenesis *in vitro*. *J. Cell. Physiol.*, *154*: 654–661, 1993.
 16. Yamaguchi, Y., Mann, D. M., and Rouslahti, E. Negative regulation of transforming growth factor- β by the proteoglycan decorin. *Nature (Lond.)*, *346*: 281–284, 1990.
 17. Takeuchi, Y., Kodama, Y., and Matsumoto, T. Bone matrix decorin binds transforming growth factor- β and enhances its bioactivity. *J. Biol. Chem.*, *269*: 32634–32638, 1994.
 18. De Luca, A., Santra, M., Baldi, A., Giordano, A., and Iozzo, R. V. Decorin-induced growth suppression is associated with up-regulation of p21, an inhibitor of cyclin-dependent kinases. *J. Biol. Chem.*, *271*: 18961–18965, 1996.
 19. Elston, C. W., and Ellis, I. O. Pathological prognostic factors in breast cancer. 1. The value of histologic grade in breast cancer. Experience from a large study with long term follow-up. *Histopathology*, *19*: 403–410, 1991.
 20. French-Constant, C., Van De Water, L., Dvorak, H. F., and Hynes, R. O. Reappearance of an embryonic pattern of fibronectin splicing during wound healing in the adult rat. *J. Cell Biol.*, *109*: 903–914, 1989.
 21. Brown, L. F., Berse, B., Tognazzi, K., Manseau, E. J., Van De Water, L., Senger, D., Dvorak, H., and Rosen, S. Vascular permeability factor mRNA and protein expression in human kidney. *Kidney Int.*, *42*: 1457–1461, 1992.
 22. Brown, L. F., Berse, B., Jackman, R. W., Tognazzi, K., Manseau, E. J., Senger, D. R., and Dvorak, H. F. Expression of vascular permeability factor (vascular endothelial growth factor) and its receptors in adenocarcinomas of the gastrointestinal tract. *Cancer Res.*, *53*: 4727–4735, 1993.
 23. Brown, L. F., Dubin, D., Lavigne, L., Logan, B., Dvorak, H. F., and Van De Water, L. Macrophages and fibroblasts express embryonic fibronectins during cutaneous wound healing. *Am. J. Pathol.*, *142*: 793–801, 1993.
 24. de Vries, C., Escobedo, J. A., Ueno, H., Houck, K., Ferrara, N., and Williams, L. T. The fms-like tyrosine kinase, a receptor for vascular endothelial growth factor. *Science (Washington DC)*, *255*: 989–991, 1992.
 25. Terman, B. I., Dougher Vermazen, M., Carrion, M. E., Dimitrov, D., Armellino, D. C., Gospodarowicz, D., and Bohlen, P. Identification of the KDR tyrosine kinase as a receptor for vascular endothelial growth factor. *Biochem. Biophys. Res. Commun.*, *187*: 1579–1586, 1992.
 26. Dvorak, H. F., Orenstein, N. S., Carvalho, A. C., Churchill, W. H., Dvorak, A. M., Galli, S. J., Feder, J., Bitzer, A. M., Rypysc, J., and Giovinco, P. Induction of a fibrin-gel investment: an early event in line 10 hepatocarcinoma growth mediated by tumor-secreted products. *J. Immunol.*, *122*: 166–174, 1979.
 27. Senger, D. R., Galli, S. J., Dvorak, A. M., Perruzzi, C. A., Harvey, V. S., and Dvorak, H. F. Tumor cells secrete a vascular permeability factor that promotes accumulation of ascites fluid. *Science (Washington DC)*, *219*: 983–985, 1983.
 28. Keck, P. J., Hauser, S. D., Krivi, G., Sanzo, K., Warren, T., Feder, J., and Connolly, D. T. Vascular permeability factor, an endothelial cell mitogen related to PDGF. *Science (Washington DC)*, *246*: 1309–1312, 1989.
 29. Leung, D. W., Cachianes, G., Kuang, W. J., Goeddel, D. V., and Ferrara, N. Vascular endothelial growth factor is a secreted angiogenic mitogen. *Science (Washington DC)*, *246*: 1306–1309, 1989.
 30. Gospodarowicz, D., Abraham, J. A., and Schilling, J. Isolation and characterization of a vascular endothelial cell mitogen produced by pituitary-derived folliculo stellate cells. *Proc. Natl. Acad. Sci. USA*, *86*: 7311–7315, 1989.
 31. Ferrara, N., and Henzel, W. J. Pituitary follicular cells secrete a novel heparin-binding growth factor specific for vascular endothelial cells. *Biochem. Biophys. Res. Commun.*, *161*: 851–858, 1989.
 32. Pepper, M. S., Ferrara, N., Orci, L., and Montesano, R. Vascular endothelial growth factor (VEGF) induces plasminogen activators and plasminogen activator inhibitor-1 in microvascular endothelial cells. *Biochem. Biophys. Res. Commun.*, *181*: 902–906, 1991.
 33. Unemori, E. N., Ferrara, N., Bauer, E. A., and Amento, E. P. Vascular endothelial growth factor induces interstitial collagenase expression in human endothelial cells. *J. Cell Physiol.*, *153*: 557–562, 1992.
 34. Kim, K. J., Li, B., Winer, J., Armanini, M., Gillet, N., Phillips, H. S., and Ferrara, N. Inhibition of vascular endothelial growth factor induced angiogenesis suppresses tumor growth *in vivo*. *Nature (Lond.)*, *362*: 841–844, 1993.
 35. Millauer, B., Shawver, L. K., Plate, K. H., Risau, W., and Ullrich, A. Glioblastoma growth inhibited *in vivo* by a dominant-negative Flk-1 mutant. *Nature (Lond.)*, *367*: 576–579, 1994.
 36. Brown, L. F., Berse, B., Jackman, R. W., Tognazzi, K., Guidi, A. J., Dvorak, H. F., Senger, D. R., Connolly, J. L., and Schnitt, S. J. Expression of vascular permeability factor (vascular endothelial growth factor) and its receptors in breast cancer. *Hum. Pathol.*, *26*: 86–91, 1995.
 37. Toi, M., Hoshina, S., Takayanagi, T., and Tominaga, T. Association of vascular endothelial growth factor expression with tumor angiogenesis and with early relapse in primary breast cancer. *Jpn. J. Cancer Res.*, *85*: 1045–1049, 1994.
 38. Anan, K., Morisaki, T., Katano, M., Ikubo, A., Kitsuki, H., Uchiyama, A., Kuroki, S., Tanaka, M., and Torisu, M. Vascular endothelial growth factor and platelet derived growth factor are potential angiogenic and metastatic factors in human breast cancer. *Surgery (St. Louis)*, *119*: 333–339, 1996.
 39. Gasparini, G., Toi, M., Gion, M., Verderio, P., Dittadi, R., Hanatani, M., Matsubara, I., Vinante, O., Bonoldi, E., and Boracchi, P.

- Prognostic significance of vascular endothelial growth factor protein in node negative breast carcinoma. *J. Natl. Cancer Inst. (Bethesda)*, *89*: 139–147, 1997.
40. Guidi, A. J., Schnitt, S. J., Fischer, L., Tognazzi, K., Harris, J. R., Dvorak, H. F., and Brown, L. F. Vascular permeability factor (vascular endothelial growth factor) expression and angiogenesis in patients with ductal carcinoma *in situ* of the breast. *Cancer (Phila.)*, *80*: 1945–1953, 1997.
41. Weinstat-Saslow, D. L., Zabrenetzky, V. S., VanHoutte, K., Frazier, W. A., Roberts, D. D., and Steeg, P. S. Transfection of thrombospondin I complementary DNA into a human breast carcinoma cell line reduces primary tumor growth, metastatic potential, and angiogenesis. *Cancer Res.*, *54*: 6504–6511, 1994.
42. Wong, S. Y., Purdie, A. T., and Han, P. Thrombospondin and other possible related matrix proteins in malignant and benign breast disease. An immunohistochemical study. *Am. J. Pathol.*, *140*: 1473–1482, 1992.
43. Tuszynski, G. P., and Nicosia, R. F. Localization of thrombospondin and its cysteine-serine-valine-threonine-cysteine-glycine-specific receptor in human breast carcinoma. *Lab. Invest.*, *70*: 228–233, 1994.
44. Clezardin, P., Frappart, L., Clerget, M., Pechoux, C., and Delmas, P. D. Expression of thrombospondin (TSP1) and its receptors (CD36 and CD51) in normal, hyperplastic and neoplastic human breast. *Cancer Res.*, *53*: 1421–1430, 1993.
45. Bertin, N., Clezardin, P., Kubiak, R., and Frappart, L. Thrombospondin-1 and -2 messenger RNA expression in normal, benign, and neoplastic human breast tissue: correlation with prognostic factors, tumor angiogenesis, and fibroblastic desmoplasia. *Cancer Res.*, *57*: 396–399, 1997.
46. Legace, R., Grimaud, J. A., Schurch, W., and Seemayer, T. A. Myofibroblastic stromal reaction in carcinoma of the breast: variations of collagenous matrix and structural glycoproteins. *Virchows Arch. A Pathol. Anat. Histopathol.*, *408*: 49–59, 1985.
47. Olsen, E. B., Trier, K., Eldov, K., Ammitzball, T., and Ammitzball, T. Glycosaminoglycans in human breast cancer. *Acta Obstet. Gynecol. Scand.*, *67*: 539–542, 1988.
48. Marotta, M., Vecchione, R., Martino, G., D'Armiento, F. P., De Cesare, M., and Rosati, P. Glycosaminoglycan enriched extracellular matrix surrounds intraductal carcinoma of the breast. *Appl. Pathol.*, *3*: 179–185, 1985.
49. Takeuchi, J., Sobue, M., Sato, E., Shamoto, M., and Miura, K. Variation in glycosaminoglycan components of breast tumors. *Cancer Res.*, *36*: 2133–2139, 1976.
50. Nara, Y., Kato, Y., Torii, Y., Tsuji, Y., Nakagaki, S., Goto, S., Isobe, H., Nakashima, N., and Takeuchi, J. Immunohistochemical localization of extracellular matrix components in human breast tumors with special reference to PG-M/versican. *Histochem. J.*, *29*: 21–30, 1997.
51. Alini, M., and Losa, G. A. Partial characterization of proteoglycans isolated from neoplastic and nonneoplastic human breast tissue. *Cancer Res.*, *51*: 1443–1447, 1991.
52. Cristensen, L. The distribution of fibronectin, laminin and tetranection in human breast cancer with special attention to the extracellular matrix. *Acta Pathol. Microbiol. Scand. Suppl.*, *26*: 1–39, 1992.
53. Gould, V. E., Koukoulis, G. K., and Virtanen, I. Extracellular matrix proteins and their receptors in the normal, hyperplastic and neoplastic breast. *Cell Differ. Dev.*, *32*: 409–416, 1990.
54. Koukoulis, G. K., Howedy, A. A., Korhonen, M., Virtanen, I., and Gould, V. E. Distribution of tenascin, cellular fibronectins and integrins in the normal, hyperplastic and neoplastic breast. *J. Submicrosc. Cytol. Pathol.*, *25*: 285–295, 1993.
55. Kaczmarek, J., Castellani, P., Nicolo, G., Spina, B., Allemanni, G., and Zardi, L. Distribution of oncofetal fibronectin isoforms in normal, hyperplastic and neoplastic human breast tissues. *Int. J. Cancer*, *59*: 11–16, 1994.
56. Yoshida, T., Matsumoto, E., Hanamura, N., Kalembeiyi, I., Katsuta, K., Ishihara, A., and Sakakura, T. Co-expression of tenascin and fibronectin in epithelial and stromal cells of benign lesions and ductal carcinomas in the human breast. *J. Pathol.*, *182*: 421–428, 1997.
57. Lorke, D., and Moller, P. The early appearance of fibronectin in the course of metastatic tumor growth in lymph nodes. *J. Cancer Res. Clin. Oncol.*, *109*: 65–71, 1985.
58. Hynes, R. O. Fibronectins. In: A. Rich (ed.), *Springer Series in Molecular Biology*, p. 546. New York: Springer-Verlag, 1990.
59. French-Constant, C. Alternative splicing of fibronectin: many different proteins but few different functions. *Exp. Cell Res.*, *221*: 261–271, 1995.
60. Pujuguet, P., Hammann, A., Moutet, M., Samuel, J. L., Martin, F., and Martin, M. Expression of fibronectin EDA+ and EDB+ isoforms by human and experimental colorectal cancers. *Am. J. Pathol.*, *148*: 579–592, 1996.

Clinical Cancer Research

Vascular Stroma Formation in Carcinoma *in Situ*, Invasive Carcinoma, and Metastatic Carcinoma of the Breast

Lawrence F. Brown, Anthony J. Guidi, Stuart J. Schnitt, et al.

Clin Cancer Res 1999;5:1041-1056.

Updated version Access the most recent version of this article at:
<http://clincancerres.aacrjournals.org/content/5/5/1041>

Cited articles This article cites 59 articles, 22 of which you can access for free at:
<http://clincancerres.aacrjournals.org/content/5/5/1041.full#ref-list-1>

Citing articles This article has been cited by 55 HighWire-hosted articles. Access the articles at:
<http://clincancerres.aacrjournals.org/content/5/5/1041.full#related-urls>

E-mail alerts [Sign up to receive free email-alerts](#) related to this article or journal.

Reprints and Subscriptions To order reprints of this article or to subscribe to the journal, contact the AACR Publications Department at pubs@aacr.org.

Permissions To request permission to re-use all or part of this article, use this link
<http://clincancerres.aacrjournals.org/content/5/5/1041>.
Click on "Request Permissions" which will take you to the Copyright Clearance Center's (CCC) Rightslink site.