

Vectorcardiographic monitoring to assess early vessel patency after reperfusion therapy for acute myocardial infarction

M. DELLBORG, P. G. STEG*, M. SIMOONS†, R. DIETZ‡, S. SEN§, M. VAN DEN BRAND†, U. LOTZE§, S. HAUCK‡, R. VAN DEN WIEKEN¶, D. HIMBERT*, A-M. SVENSSON AND K. SWEDBERG

From the Department of Medicine, Östra Hospital, Göteborg University, Göteborg, Sweden; *Department of Cardiology, Hopital Bichat-Claude Bernard, Paris, France; †Department of Cardiology, Thoraxcenter, Rotterdam, The Netherlands; ‡Department of Cardiology, University of Heidelberg, Heidelberg, Germany; §Medizinische Universitätsklinik und Poliklinik, Innere Medizin III, Homburg-Saar, Germany; ¶Onze Lieve Vrouwe Gasthuis, Amsterdam, The Netherlands

KEY WORDS: Patency, vectorcardiography, thrombolysis, angiography.

Reperfusion therapy has lowered mortality in patients suffering from acute myocardial infarction. Failure to reperfuse is associated with an increased short- and long-term mortality. In a prospective study we used dynamic vectorcardiography to monitor 96 patients with acute myocardial infarction treated with reperfusion therapy to non-invasively assess coronary patency. The results from continuous monitoring were compared to those obtained from angiography. By using trend-analysis of QRS vector difference and ST vector magnitude, we were able to correctly identify 58 of the 70 patients (83%) with a reperfused infarct-related artery, and 19 of the 26 patients (73%) with a persistently occluded artery demonstrated at an early angiogram (diagnostic accuracy 80%). In patients with high-grade collateral flow to the infarct-related area, the results of the vectorcardiographic monitoring and of angiography showed the largest disagreement, whereas the accuracy of vectorcardiographic monitoring was high: 88% among patients without collaterals. The present results suggest that QRS complex and ST segment vectorcardiographic monitoring is a useful tool for assessing early coronary artery patency, and that dynamic vectorcardiography may help in identifying candidates for emergency coronary angiography.

Introduction

Reperfusion therapy has lowered mortality in patients suffering from acute myocardial infarction^[1–3]. The beneficial effect seems related to reperfusion of the ischaemic myocardium. Patients with an open infarct-related artery after thrombolytic therapy do not benefit from further acute intervention^[4–6] but failure to acutely reopen the infarct-related artery is associated with a significantly higher risk of short- and long-term mortality^[5,7–9]. Although the association between infarct artery patency and long-term mortality is less prominent if corrected for left ventricular function^[10], patients with persistent occlusion of the infarct-related artery represent a high risk subset who may be eligible for additional measures including more aggressive treatment regimens or rescue angioplasty. Therefore, accurate determination of vessel patency is important during the acute phase of a myocardial infarction. Coronary angiography is costly and carries some risk. Thus, accurate non-invasive detection of patency should be valuable. Standard 12-lead electrocardiography (ECG) has a moderate diagnostic accuracy if one uses >50% recovery of summated ST

segment deviation to identify patency. Similar results have been reported using a lower limit of 20% ST recovery^[11,12]. Superior accuracy of non-invasive determination of coronary artery patency has been reported using continuous 12-lead electrocardiographic monitoring of ST segment changes^[13]. In a previous pilot study we used dynamic vectorcardiography to non-invasively assess coronary artery patency in patients with acute myocardial infarction treated with reperfusion therapy^[14]. The present article reports the findings from a prospective, blind study comparing dynamic vectorcardiography with coronary angiography to detect coronary patency after reperfusion therapy for acute myocardial infarction. The primary objective of the study was to assess the diagnostic accuracy of dynamic vectorcardiography using predefined criteria for determining vessel patency and using coronary angiography as a reference. Secondary objectives were to determine whether QRS monitoring, ST monitoring or both provide the most useful information for non-invasive detection of patency, and to define possible improvements in the criteria for future studies.

Methods

VECTORCARDIOGRAPHY

We used a computerized system for on-line, dynamic recording and analysis of QRS complex and ST segment changes (MIDA1000, Ortivus Medical, Täby, Sweden).

Submitted for publication on 9 August 1993, and in final revised form 1 July 1994.

Supported by a grant from AFA, the Labour Market Insurance Company, Stockholm, Sweden, the Heart-Lung Foundation, Stockholm, Sweden and Ortivus Medical, Täby, Sweden.

Correspondence: Mikael Dellborg, MD, Department of Medicine, Östra Hospital, Göteborg University, 416 85 Göteborg, Sweden.

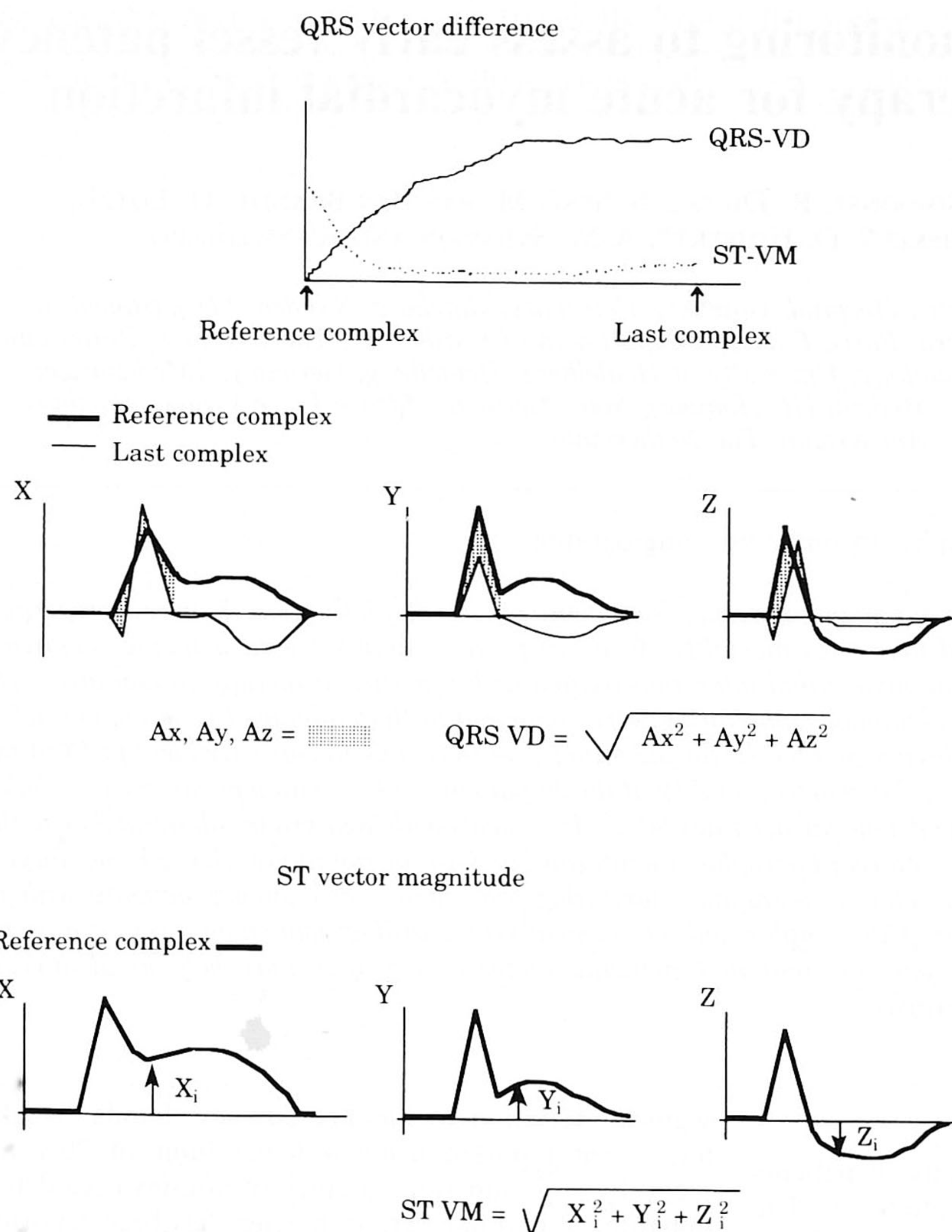


Figure 1 The upper panel shows a trend curve with time on the horizontal axis and QRS vector difference and ST vector magnitude on the vertical axis. A trend curve from a patient with an acute myocardial infarction is illustrated, showing a slow evolution of electrocardiographic changes. The reference mean QRS complex and current mean QRS complex are shown plotted above each other. The hatched area (A_x , A_y , A_z) is the QRS vector difference in leads X, Y and Z, respectively, added according to the formula to form the total QRS vector difference. Lower panel: The arrows indicate the deviation from baseline of the ST segment 20 ms after the termination of the QRS complex in each of the three leads; assigned X_i , Y_i and Z_i . Added according to the formula, these deviations form the ST vector magnitude, illustrated by the initial ST vector magnitude on the trend curve above. QRS VD=QRS vector difference. ST VM=ST vector magnitude.

The method, which has been described in detail elsewhere^[15], involves the use of eight electrodes placed according to Frank^[16] to continuously monitor and analyse the three orthogonal leads X, Y and Z. The signals are averaged over 1-min periods to obtain mean vectorcardiographic complexes. All calculations are done in real time and the results are presented on a computer screen. Changes for every patient are related to the initial 1-min mean complex for that patient. The results are presented as continuously updated trend curves on the computer screen. The two vectorcardiographic parameters studied were QRS vector difference and ST vector magnitude (Fig. 1). The QRS vector

difference at any given time can be described as the total change within the QRS complex from start of recording until that point in time. The ST vector magnitude is the deviation from zero of the ST segment 20 ms after termination of the QRS complex, measured and summated for all three leads.

PATIENT SERIES

Patients with suspected acute myocardial infarction admitted to any of the participating centres, the coordinating centre excepted (Göteborg), were eligible for inclusion. Inclusion criteria were: (1) Chest pain lasting

for >30 min but less than 4 h with a strong suspicion of acute myocardial infarction, (2) ST segment elevation >1 mm in >1 lead or ST segment depression of the precordial leads V₁-V₄ consistent with posterior wall damage, and (3) thrombolytic treatment started within 4 h of onset of chest pain or acute angioplasty performed within 4 h of onset of chest pain. Patients with a QRS duration ≥ 0.12 s, third degree AV-block or idioventricular rhythm on admission were excluded. Cardiac catheterization was performed as close as possible to 90 min from the start of thrombolysis. At least 30 min of vectorcardiographic monitoring should precede angiography. The choice of thrombolytic drug regimen and adjunctive therapy as well as the decision to perform angioplasty was at the discretion of the local investigator.

DATA HANDLING AND ANALYSIS

Patients were monitored by vectorcardiography for at least 12 but preferably 24 h. The vectorcardiographic recordings were stored on floppy disks and sent to Östra Hospital in Göteborg for central analysis. The time of the first injection of contrast medium into the infarct-related artery (generally the first artery to be injected) was noted. In Göteborg, the vectorcardiographic recordings were copied and blanked so that only data up to the time of the first injection of contrast medium were available to the interpreter. The complete, original recordings were kept safe by an independent person who was not a member of the study group. All coronary angiograms were analysed centrally (Thoraxcenter) by one experienced angiographer who was unaware of the results of the vectorcardiographic evaluation.

ASSESSMENT OF VECTORCARDIOGRAPHIC RECORDINGS

Patients with third degree AV block or who had idioventricular rhythm for more than 6 of the first 24 h and/or more than 30 min of the first 2 h of vectorcardiographic recordings were excluded from the study.

Based on previous experience the following changes were assumed to reflect the perfusion state of the infarct-related artery^[14,17]. First, a rate of increase of QRS vector difference of $\geq 0.10 \mu\text{Vs} \cdot \text{min}^{-1}$ from 30 min before angiography to first injection of contrast medium was considered indicative of a patent coronary artery corresponding to TIMI-grade 2-3, while $< 0.10 \mu\text{Vs} \cdot \text{min}^{-1}$ was thought to reflect an occluded coronary artery corresponding to TIMI 0-1. Secondly, a rate of decline of ST vector magnitude (straight line) of $\geq 0.83 \mu\text{V} \cdot \text{min}^{-1}$ from 30 min before angiography to first injection of contrast medium was considered indicative of a patent coronary artery corresponding to TIMI-grade 2-3, while $< 0.83 \mu\text{V} \cdot \text{min}^{-1}$ was thought to reflect an occluded coronary artery corresponding to TIMI 0-1. The rate of increase in the QRS vector difference and the rate of decline in the ST vector magnitude were determined by drawing a straight line

from the time of first injection of contrast medium to the point on the trend curve 30 min earlier.

A blind evaluation of the overall trend curve up to the time of the first injection of contrast medium was also part of the protocol. This evaluation not only took into consideration the rate of increase of the QRS vector difference and the rate of decline of the ST vector magnitude, but also considered changes in these two parameters immediately prior to angiography in relation to the time of onset of chest pain, the start of thrombolysis and the start of vectorcardiographic recording. The evaluation, performed by one experienced observer, classified the vectorcardiographic recording as indicating either 'probably patent artery' or 'probably closed artery' at the time of first injection of contrast medium. Percent ST recovery was defined as the difference between the maximum ST vector magnitude at any preceding time during the recording and the ST vector magnitude immediately before the angiography, divided by the maximum ST vector magnitude $\times 100$.

ANGIOGRAPHIC EVALUATION

The cineangiograms were evaluated for the infarct-related segment, TIMI grade flow in the infarct-related segment (TIMI 0-3)^[8] and collateral blood flow (none, minimal, moderate, large)^[18] to the infarct area. TIMI flow grade 0-1 was used to define an occluded coronary artery, TIMI flow grade 2-3 to define an open artery.

STATISTICS

Proportions were compared using a χ^2 -test. The positive predictive value was obtained by dividing the number of accurate positive predictions by the total number of positive findings. The negative predictive value was obtained by dividing the number of accurate negative predictions by the total number of negative findings. Diagnostic accuracy was defined as the number of correct assessments divided by the total number of assessments performed and was expressed as a percentage. Values are given as mean \pm standard deviation.

Results

Between September 1990 and April 1992 a total of 127 patients were included at the five participating centres. For various reasons, 31 of these patients were excluded from further analysis (monitoring period preceding the angiography <30 min, n=20; vectorcardiographic recording started later than 4 h from onset of symptoms; n=7; computer problems; n=4). Therefore, 96 patients were available for evaluation, 77 men and 19 women with a mean age of 57 ± 10 years. Clinical data and therapy are presented in Table 1. The infarct-related artery was the right coronary artery in 45 patients (47%), the left anterior descending artery in 39 patients (41%) and the left circumflex artery in 11 patients (12%). In one case the infarct-related artery could not be determined; this patient was considered to have a patent artery. The

Table 1 Cardiovascular history and treatment (n=96)

	n	%
Hypertension	26	26
Diabetes mellitus	9	9
Previous AMI	13	14
Angina pectoris	43	44
Previous CABG/PTCA	3	3
Thrombolytic drug used		
APSAC	1	1
rt-PA	54	56
rt-PA+ProUK	22	23
SK	11	11
UK+ProUK	4	4
Primary angioplasty	4	4
Adjunctive therapy during initial 4 h		
i.v. nitroglycerin	89	93
Calcium antagonist	14	15
Beta-blocker	56	58
Aspirin	55	57
Time (min) from		
onset of chest pain to start of thrombolysis	168 ± 82 (range 24–335)	
start of thrombolysis to start of VCG	15 ± 22 (range 5–82)	
start of thrombolysis to first injection of contrast	105 ± 34 (range 43–249)	
start of VCG to first injection of contrast	90 ± 40 (range 8–239)	

AMI=acute myocardial infarction; CABG=coronary artery by-pass grafting; PTCA=percutaneous transluminal coronary angioplasty; APSAC=anisoylated plasminogen-streptokinase activator complex; rt-PA=recombinant tissue-type plasminogen activator; SK=streptokinase; ProUK=pro-urokinase; UK=urokinase; i.v. intravenous; VCG=vectorcardiographic monitoring.

Table 2 Patency assessment by vectorcardiography using ST- and/or QRS changes in relation to angiographic results

		90 min angiographic patency					
		All patients (n=96)		Patients with* collaterals (n=20)		Patients without* collaterals (n=73)	
		Open	Closed	Open	Closed	Open	Closed
VCG monitoring (ST and/or QRS)	Open	58	7	5	5	52	1
	Closed	12	19	3	7	8	12
Diagnostic accuracy of VCG		77/96=80%		12/20=60%		64/73=88%	

P<0.05 between groups

*In three patients it was not possible to assess the presence or absence of collaterals. VCG=vectorcardiography.

mean initial ST vector magnitude of the patient population was $255 \pm 169 \mu\text{V}$ (range 37–1046 μV) and the maximal ST vector magnitude at any time prior to angiography was $332 \pm 203 \mu\text{V}$ (range 71–1065 μV).

PATENCY

The acute angiogram revealed an occluded coronary artery in 26 patients (28%), of which 20 had a TIMI 0 grade flow and six a TIMI 1 grade flow. In 70 patients (73%) the infarct-related artery was patent, with 12 patients having TIMI 2 grade flow and 58 patients TIMI 3. The results from the blinded evaluation of the vectorcardiographic recordings are given in Table 2. The

results are presented for both the total population and separately for patients with or without collaterals. The overall diagnostic accuracy using vectorcardiographic monitoring, considering both ST and QRS changes was 80%. Of the 70 patients with a patent artery, 58 were correctly classified and of the 26 patients with an occluded artery, 19 were correctly classified. Thus, vectorcardiography had a sensitivity of 73% and a specificity of 83% for detection of persistent occlusion. The positive predictive value for patency was 89%, the negative predictive value 61% and thus the positive and negative predictive value for occlusion were 89 and 61%, respectively. The prospectively established limits for rate of increase of QRS vector difference, rate of decrease of

Table 3 Results of vectorcardiographic monitoring using fixed definitions of ST vector magnitude declination or QRS vector difference evolution in relation to angiographic findings

	90 min angiographic patency (n=92)		Diagnostic accuracy
	Open	Closed	
ST VM decline/30 min			
$\geq 0.83 \mu\text{V} \cdot \text{min}^{-1}$ (open)	33	12	45/92=49%
$< 0.83 \mu\text{V} \cdot \text{min}^{-1}$ (closed)	35	12	
QRS VD increase/30 min			
$\geq 0.10 \mu\text{Vs} \cdot \text{min}^{-1}$ (open)	38	15	47/92=51%
$< 0.10 \mu\text{Vs} \cdot \text{min}^{-1}$ (closed)	30	9	
ST recovery			
$\geq 50\%$ (open)	38	4	60/96=63%
$< 50\%$ (closed)	32	22	
ST recovery			
$\geq 20\%$ (open)	64	11	78/96=81%
$< 20\%$ (closed)	5	14	

In four patients the rate of evolution/decline of the QRS vector difference and the ST vector magnitude could not be accurately computed according to the protocol.

ST vector magnitude and % ST recovery, in relation to angiographic results are given in Table 3. An ST recovery of $> 50\%$ at the time of angiography correctly identified 22 of 26 patients with a non-patent artery.

A retrospective analysis was performed on patients with an initial ST vector magnitude $< 150 \mu\text{V}$, $n=31$. A rate of QRS vector difference evolution of $< 0.2 \mu\text{V} \cdot \text{min}^{-1}$ showed a 100% sensitivity for detecting persistent occlusion (five of five patients) while specificity was 32%. The overall diagnostic accuracy was thus 37%.

COLLATERALS

Collateral flow to the infarct-related segment was absent in 73 patients (78%), minimal in 12 (13%), moderate in six (6%) and large in two (2%). Collateral flow could not be assessed in three patients, two of whom had a patent artery and one an occluded artery at early angiography. The diagnostic accuracy of vectorcardiographic monitoring was 88% for patients without collaterals and 60% for patients with collaterals, a significant difference between groups ($P < 0.05$, Table 2). Among patients without collaterals $< 50\%$ ST recovery correctly identified all 13 patients with an occluded artery.

Discussion

In the present study, coronary patency was correctly assessed by vectorcardiographic monitoring in 77 of 96 patients (80%); these results are similar to those reported using other electrocardiographic techniques^[11,19-24]. The results of vectorcardiographic monitoring were more accurate among patients without collateral flow to the infarct-related zone. Specifically, in patients with a persistent occlusion, but with some degree of collateral flow

to the infarct-related zone, the infarct-related artery was frequently classified as patent by vectorcardiographic monitoring. This is consistent with the results obtained by continuous monitoring with 12-lead ECG^[23]. Previous studies have also indicated that a high degree of ST recovery is associated with a limitation of infarct size, preservation of left ventricular function and favourable prognosis, even if it occurs in patients with an occluded artery at early angiography^[11]. In a recent report, Ito and co-workers reported a lack of perfusion, as demonstrated by contrast echocardiography, despite TIMI 3 flow of the infarct-related artery at early angiography^[25]. Thus, in addition to the presence of collaterals, the absence of perfusion despite adequate flow in the epicardial arteries may explain some of the discrepancy between angiographic patency assessment and more physiological markers such as the electrocardiogram.

OTHER NON-INVASIVE METHODS FOR MONITORING REPERFUSION

Enzymatic methods may detect reperfusion with a high accuracy but their ability to detect ischaemia or intermittent, brief episodes of coronary perfusion is limited^[26-29]. Moreover, despite recent advances, enzymatic methods do not have true real-time capacity. The combined use of clinical information including chest pain and the results of electrocardiography and enzyme analysis may further improve the ability to non-invasively monitor myocardial perfusion. Until now, the results from this combined approach have varied^[30,31]. However, none of these investigations have used sophisticated multilead monitoring or highly specific rapid-assay enzymatic methods. Such a combined approach may lead to even more accurate assessment of myocardial perfusion but further studies are required.

CONTINUOUS MONITORING VS POINT MEASUREMENTS

The concept of the rapidly varying perfusion status of the infarct-related artery is relatively new^[32,33]. With continuous dynamic monitoring of the electrocardiogram sudden changes in the status of infarct vessel patency can be illustrated and documented. Such changes have been reported in a large proportion of patients with acute myocardial infarction^[15,34,35]. Fixed measurement of ST vector change over time or QRS vector difference evolution, on the other hand, are misleading for some period of time immediately after any change in vessel perfusion status. Thus, in the present trial, visual, blind interpretation of the trend curves illustrating the ST vector magnitude and the QRS vector difference proved more accurate than the fixed-rate indices of QRS and ST evolution described in the protocol. The %ST recovery also gave more accurate results presumably because the %ST recovery is not limited to any specific time window but identifies recovery whenever it occurs prior to angiography. Our more time-specific indices (i.e. rate of evolution/decline during the 30 min preceding angiography) may not

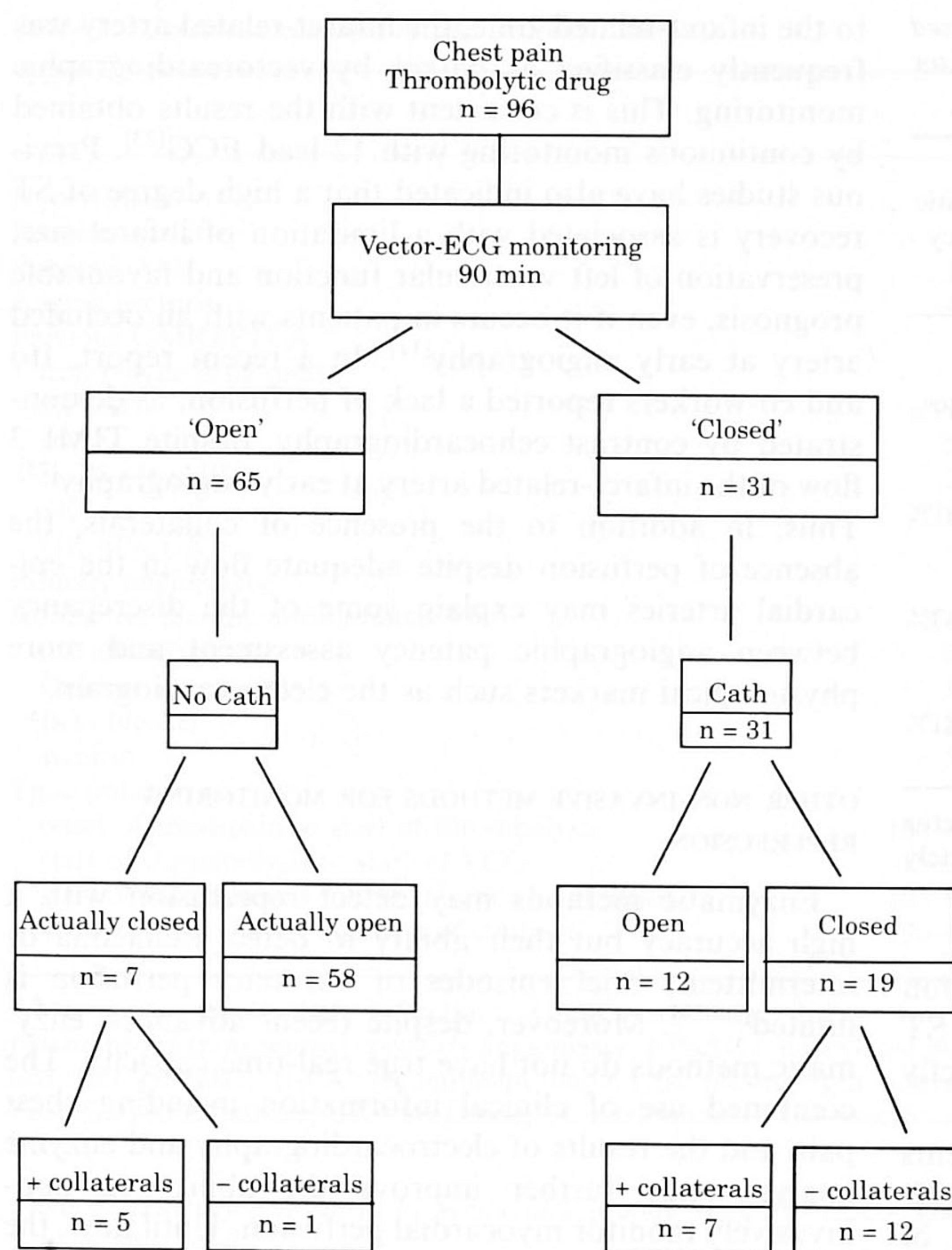


Figure 2 A simulation of the results of using vectorcardiograph monitoring to screen patients for acute angiography to identify patients eligible for rescue angioplasty. In one patient with a persistent occlusion it was not possible to assess the presence or absence of collaterals.

accurately detect early reperfusion occurring within 30–45 min after the initiation of thrombolytic therapy.

QRS- VS ST-MONITORING

The vectorcardiographic system uses Frank leads and monitors changes in the ST segment in addition to changes in the QRS complex. The present study indicates only a marginal benefit from monitoring the QRS vector changes in addition to ST changes, namely for patients with minor ST changes i.e. $<150\% \mu\text{V}$ in the initial ST vector magnitude. In that specific case, which occurred in almost a third of the patients, a QRS vector difference evolution rate of $<0.2 \mu\text{Vs} \cdot \text{min}^{-1}$ was more accurate as a sign of persistent occlusion than any of the ST parameters. More importantly, an evolution rate of the QRS vector difference above $0.20 \mu\text{Vs} \cdot \text{min}^{-1}$ excluded patients with persistent occlusion. This finding of our post-hoc analysis requires independent validation before it can be used in making clinical decisions.

Conventional 12-lead ECG has low sensitivity for detecting lateral and posterior ischaemia^[36]. The Frank lead system used by the MIDA-monitoring system may

be more sensitive to ischaemia in these locations but the results in the present study are in close agreement with the results from studies using conventional 12-lead ECG.

We have previously reported that monitoring of QRS vector difference evolution seems to be more informative than ST vector monitoring alone^[14]. The reason for the discrepancy between our previous findings and those of the present study may be that the present trial included patients earlier after the onset of symptoms and the initiation of thrombolytic therapy. In earlier studies we found that the ST vector magnitude in patients with acute myocardial infarction treated with intravenous streptokinase or rt-PA, returned to baseline a mean of 15 min before evolution of the QRS vector difference was completed^[15,17]. In contrast, the ST vector magnitude in patients not given thrombolysis returned to baseline 1 h and 20 min before the QRS vector difference evolution was completed. Thus, trend analysis of QRS vector difference may expand the time window for electrocardiographic analysis of the dynamic process of development of myocardial ischaemia and necrosis.

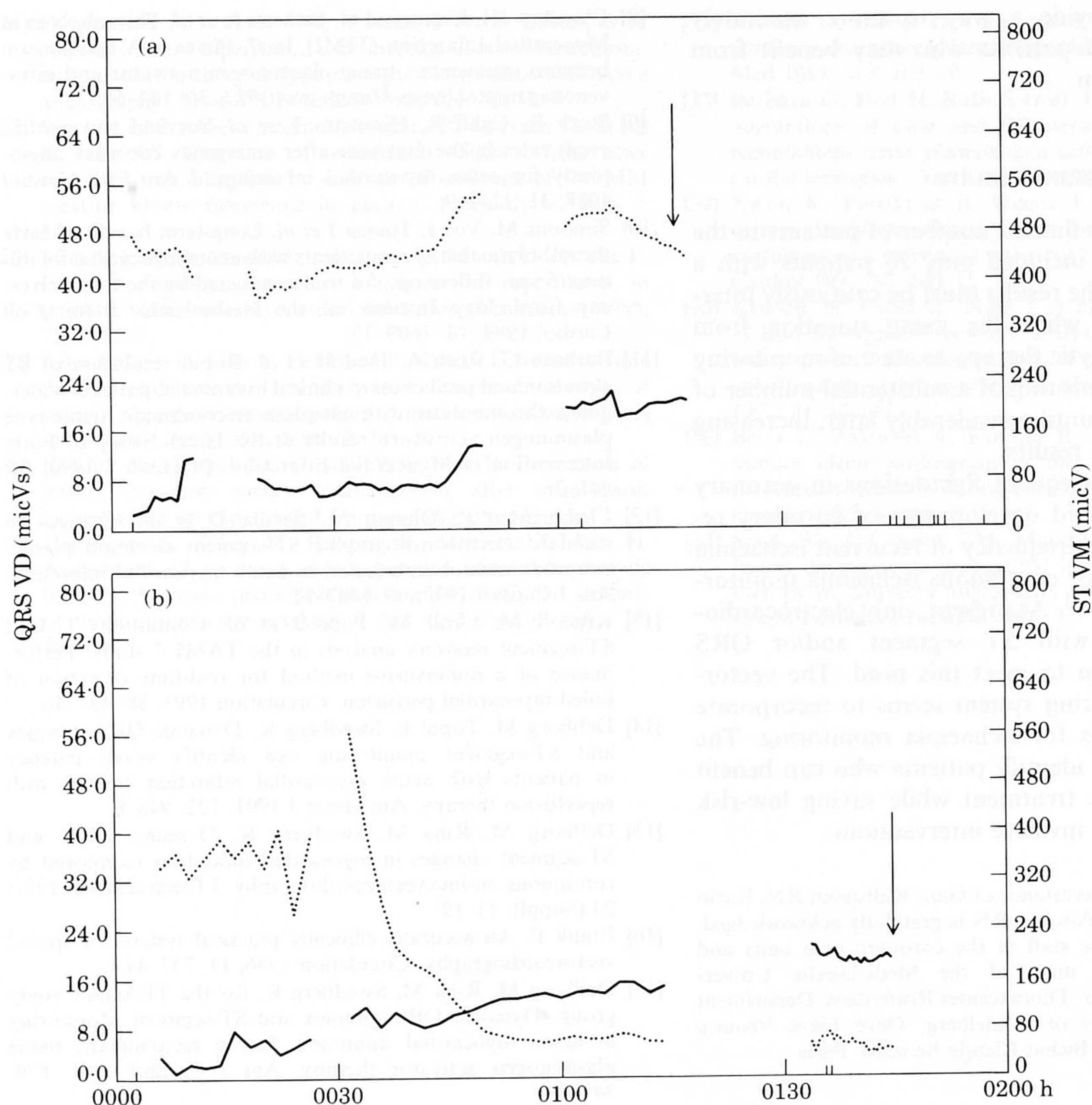


Figure 3 (a) An unedited computer printout from a patient with persistent occlusion (TIMI grade 0 flow) at the time of first injection of contrast medium (arrow). QRS VD: QRS vector difference. ST VM: ST vector magnitude. (b) An unedited computer printout from a patient with a fully patent coronary artery (TIMI grade 3 flow) at the time of first injection of contrast medium (arrow).

VECTORCARDIOGRAPHIC MONITORING TO IDENTIFY FAILED THROMBOLYSIS

Failed thrombolysis is associated with a comparatively high short- and long-term mortality^[5,7,8,37]. If thrombolytic failure can be accurately identified, therapeutic interventions such as rescue angioplasty can be targeted to this subset of patients. For patients with successful thrombolysis, who exhibit early reestablishment of coronary flow, a strategy of 'watchful waiting' has been advocated^[4,6]. Based on the blind evaluation of the vectorcardiographic recordings from this trial, Fig. 2 simulates the use of vectorcardiographic monitoring in patients with acute myocardial infarction treated at an institution with 24-h catheterization facilities. If the vectorcardiographic recording indicates a 'patent' vessel, angiography should not be performed acutely whereas if the artery is considered 'occluded' angiography should be performed. As this figure shows, vectorcardiographic monitoring would have indicated a need for acute

angiography in 31 of 96 patients (32%). These results indicate that vectorcardiographic monitoring may reduce the need for acute coronary angiography by approximately 60–70%, thereby reducing both costs and morbidity associated with acute coronary angiography in patients receiving thrombolytic therapy. Vectorcardiographic monitoring of patients with persistent occlusion will incorrectly classify vessels as 'probably opened' in some cases. Most of these patients, however, (5 of 7 in the present study) will have collaterals supplying the infarct zone. In patients with persistent occlusion, rescue angioplasty has not been shown to provide any definite benefit although the value of rescue angioplasty is being tested prospectively in a multicentre randomized trial. The data presented by Barbash and co-workers indicate that patients with persistent occlusions who have collaterals supplying the infarct zone have a more favourable outcome than patients with total occlusion without collaterals^[11]. Continuous electrocardiographic

monitoring may provide a way to more accurately identify subgroups of patients who may benefit from aggressive intervention.

LIMITATIONS OF THE PRESENT STUDY

Given the relatively limited number of patients in the present study, which included only 26 patients with a persistent occlusion, the results must be cautiously interpreted. In addition, while the mean duration from initiation of thrombolytic therapy to start of monitoring was only 15 min, monitoring of a substantial number of patients did not start until considerably later, increasing the uncertainty of the results.

In conclusion, the frequent fluctuations in coronary perfusion^[32,33], the rapid development of coronary re-occlusion and the high frequency of recurrent ischaemia underscore the need for continuous ischaemia monitoring of infarct patients^[35]. At present, only electrocardiographic monitoring with ST segment and/or QRS complex analysis seem to meet this need. The vectorcardiographic monitoring system seems to incorporate many of the demands for ischaemia monitoring. The system may also help identify patients who can benefit from more aggressive treatment while saving low-risk candidates from early invasive interventions.

The excellent technical assistance of Gerd Källström RN, Karin Nijssen RN and Claudia Pöschke RN is gratefully acknowledged, as is the assistance of the staff at the coronary care units and coronary catheterization units of the Medizinische Universitätsklinik, Homburg-Saar, Thoraxcenter Rotterdam, Department of Cardiology, University of Heidelberg, Onze Lieve Vrouwe Gasthuis and the Hopital Bichat-Claude Bernard, Paris.

References

- [1] Gruppo Italiano per lo Studio della Streptochinasi nell'infarto miocardico (GISSI). Effectiveness of intravenous thrombolytic treatment in acute myocardial infarction. *Lancet* 1986; 1: 397-401.
- [2] ISIS-2 Collaborative group. Randomised trial of intravenous streptokinase, oral aspirin, both or neither among 17187 cases of suspected acute myocardial infarction: ISIS-2. *Lancet* 1988; ii: 349-60.
- [3] Wilcox RG, von der Lippe G, Olsson CG *et al.* Trial of tissue plasminogen activator for mortality reduction in acute myocardial infarction. *Lancet* 1988; 2: 525-30.
- [4] Simoons M, Betriu A, Col J *et al.* Thrombolysis with tissue plasminogen activator in acute myocardial infarction: No additional benefit from immediate percutaneous coronary angioplasty. *Lancet* 1988; i: 197-203.
- [5] Topol EJ, Califf RM, George BS *et al.* A randomized trial of immediate versus delayed elective angioplasty after intravenous tissue plasminogen activator in acute myocardial infarction. *N Engl J Med* 1987; 317: 581-8.
- [6] TIMI Study Group. Comparison of invasive and conservative strategies following intravenous tissue plasminogen activator in acute myocardial infarction: Results of the Thrombolysis in Myocardial Infarction (TIMI) phase II trial. *N Engl J Med* 1989; 320: 618-28.
- [7] Kennedy JW, Ritchie JL, Davis KB, Stadius ML, Maynard C, Fritz JK. The Western Washington randomized trial of intracoronary streptokinase in acute myocardial infarction. *N Engl J Med* 1985; 312: 1073-8.
- [8] Chesebro JH, Knatterud G, Roberts R *et al.* Thrombolysis in Myocardial Infarction (TIMI) Trial, Phase I. A comparison between intravenous tissue plasminogen activator and intravenous streptokinase. *Circulation* 1987; 76: 142-54.
- [9] Stack R, Califf R, Hinohara T *et al.* Survival and cardiac event rates in the first year after emergency coronary angioplasty for acute myocardial infarction. *J Am Coll Cardiol* 1988; 11: 1141-9.
- [10] Simoons M, Vos J, Tjissen J *et al.* Long-term benefit of early thrombolytic therapy in patients with acute myocardial infarction: 5 year follow-up of a trial conducted by the Interuniversity Cardiology Institute of the Netherlands. *J Am Coll Cardiol* 1989; 14: 1609-15.
- [11] Barbash G, Roth A, Hod H *et al.* Rapid resolution of ST elevation and prediction of clinical outcome in patients undergoing thrombolysis with alteplase (recombinant tissue-type plasminogen activator): results of the Israeli Study of Early Intervention in Myocardial Infarction. *Br Heart J* 1990; 64: 241-7.
- [12] Clemmensen P, Ohman M, Sevilla D *et al.* Changes in standard electrocardiographic ST-segment elevation predictive of successful reperfusion in acute myocardial infarction. *Am J Cardiol* 1990; 66: 1407-11.
- [13] Krucoff M, Croll M, Pope J *et al.* Continuous 12-lead ST-segment recovery analysis in the TAMI 7 study: Performance of a noninvasive method for real-time detection of failed myocardial perfusion. *Circulation* 1993; 88: 437-46.
- [14] Dellborg M, Topol E, Swedberg K. Dynamic QRS-complex and ST-segment monitoring can identify vessel patency in patients with acute myocardial infarction treated with reperfusion therapy. *Am Heart J* 1991; 122: 943-8.
- [15] Dellborg M, Riha M, Swedberg K. Dynamic QRS- and ST-segment changes in myocardial infarction monitored by continuous on-line vectorcardiography. *J Electrocardiol* 1991; 23 (Suppl): 11-19.
- [16] Frank E. An accurate, clinically practical system for spatial vectorcardiography. *Circulation* 1956; 13: 737-44.
- [17] Dellborg M, Riha M, Swedberg K, for the TEAHAT study group. Dynamic QRS-complex and ST-segment Monitoring in acute myocardial infarction during recombinant tissue plasminogen activator therapy. *Am J Cardiol* 1991; 67: 343-9.
- [18] Rentrop P, Cohen M, Blanke H, Philips R. Changes in collateral channel filling immediately after controlled coronary artery occlusion by an angioplasty balloon in human subjects. *J Am Coll Cardiol* 1985; 5: 587-92.
- [19] Krucoff M, Green C, Satler L *et al.* Noninvasive detection of coronary artery patency using continuous ST-segment monitoring. *Am J Cardiol* 1986; 57: 916-22.
- [20] Hackworthy R, Vogel M, Harris P. Influence of infarct artery patency on the relation between initial ST segment elevation and final infarct size. *Br Heart J* 1986; 56: 222-5.
- [21] Hackworthy R, Bernard M, Vogel B, Harris P. Relationship between changes in ST segment elevation and patency of the infarct-related coronary artery in acute myocardial infarction. *Am Heart J* 1986; 112: 279-84.
- [22] Hogg K, Hornung R, Howie C, Hockings N, Dunn F, Hillis W. Electrocardiographic prediction of coronary artery patency after thrombolytic treatment in acute myocardial infarction: Use of the ST segment as a non-invasive marker. *Br Heart J* 1988; 60: 275-80.
- [23] Krucoff M, Croll M, Granger C *et al.* Prospective blinded noninvasive detection of failed thrombolysis using digital trending from continuous 12-lead ST segment monitoring. (Abstract). *Circulation* 1990; 82: 254.
- [24] Saran R, Been M, Furniss S, Hawkins T, Reid D. Reduction in ST segment elevation after thrombolysis predicts either coronary reperfusion or preservation of left ventricular function. *Br Heart J* 1990; 64: 113-17.
- [25] Ito H, Tomooka T, Sakai N *et al.* Lack of myocardial perfusion immediately after successful thrombolysis. *Circulation* 1992; 85: 1699-1705.

- [26] Garabedian HD, Gold HK, Yasuda T *et al.* Detection of coronary artery reperfusion with creatine kinase-MB determinations during thrombolytic therapy: Correlation with acute angiography. *J Am Coll Cardiol* 1988; 111: 729-34.
- [27] Seacord LM, Absendschein D, Nohara R, Hartzler G, Sobel B, Jaffe AS. Detection of reperfusion within 1 hour after coronary recanalization by analysis of isoforms of the MM creatine kinase isoenzyme in plasma. *Fibrinolysis* 1988; 2: 151-6.
- [28] Ellis A, Little T, Masud Z, Liberman H, Morris D, Klocke F. Early noninvasive detection of successful reperfusion in patients with acute myocardial infarction. *Circulation* 1988; 78: 1352-7.
- [29] Absendschein D, Ellis A, Eisenberg P, Klocke F, Sobel B, Jaffe A. Prompt detection of coronary recanalization by analysis of rates of change of concentrations of macromolecular markers in plasma. *Cor Art Dis* 1991; 2: 201-12.
- [30] Kircher RJ, Topol EJ, O'Neill WW, Pitt B. Prediction of infarct coronary artery recanalization after intravenous thrombolytic therapy. *Am J Cardiol* 1987; 59: 513-15.
- [31] Hohnloser S, Zabel M, Kasper W, Meinertz T, Just H. Assessment of coronary artery patency after thrombolytic therapy: Accurate prediction utilizing the combined analysis of three noninvasive markers. *J Am Coll Cardiol* 1991; 18: 44-9.
- [32] Hackett D, Davies G, Chierchia S, Maseri, A. Intermittent coronary occlusion in acute myocardial infarction. *N Engl J Med* 1987; 317: 1055-9.
- [33] Barbash G, Hod H, Rath S *et al.* Intermittent, dose-related fluctuations of pain and ST elevation during infusion of recombinant tissue plasminogen activator during acute myocardial infarction. *Am J Cardiol* 1989; 64: 225-8.
- [34] Kwon K, Freedman B, Wilcox I *et al.* The unstable ST segment early after thrombolysis for acute infarction and its usefulness as a marker of recurrent coronary occlusion. *Am J Cardiol* 1991; 67: 109-15.
- [35] Krucoff M, Croll M, Pope J *et al.* Continuously updated 12-lead ST-segment recovery analysis for myocardial infarct artery patency assessment and its correlation with multiple simultaneous early angiographic observations. *Am J Cardiol* 1993; 71: 145-51.
- [36] Berry C, Zalewski A, Kovach R, Savage M, Goldberg S. Surface electrocardiogram in the detection of transmural myocardial ischemia during coronary artery occlusion. *Am J Cardiol* 1989; 63: 21-6.
- [37] Stack RS, O'Connor CM, Mark DB *et al.* Coronary perfusion during acute myocardial infarction with a combined therapy of coronary angioplasty and high-dose intravenous streptokinase. *Circulation* 1988; 77: 151-61.