

## Thoughts and Progress

### Venovenous Extracorporeal Membrane Oxygenation (ECMO) Using a Double-Lumen Cannula

*Alice French Andrews,  
Joseph B. Zwischenberger, Robert E. Cilley, and  
Kenneth L. Drake from Westland Medical Center,  
Westland, Michigan, and the University of  
Michigan Medical Center,  
Ann Arbor, Michigan, U.S.A.*

**Abstract:** Extracorporeal membrane oxygenation (ECMO) can support neonates with severe respiratory failure. Currently, the most common application of ECMO requires venoarterial access. Venovenous (VV) ECMO is desirable to avoid common carotid artery ligation. However, the best technique of venous access for VV ECMO is not established. Using a single cannula with a double-lumen (DLC) in the right atrium for simultaneous drainage and infusion of blood, VV ECMO provided total respiratory support for six apneic puppies for 3 h each. Mean systemic arterial oxygenation was lower with DLC VV (50 torr) compared to VA ECMO (247 torr), but a physiologic pH (mean 7.34) was maintained on DLC VV bypass. Higher mean bypass flow was required on DLC VV (124 ml/kg/min) compared to VA flow (101 ml/kg/min) because of recirculation of oxygenated blood. The position of the DLC in the right atrium needed to be closely monitored. Hemorrhage was noted in the myocardium after use of DLC VV ECMO. **Key Words:** Double-lumen cannula—ECMO—Respiratory support.

Neonatal extracorporeal membrane oxygenation (ECMO) provides respiratory support for infants with severe respiratory failure (1-3). Venoarterial (VA) ECMO has been used most commonly, utilizing the right internal jugular vein for venous drainage and the right common carotid artery for infusion of oxygenated blood. Although no neurologic sequelae directly attributable to ligation of the right common carotid artery have been found in ne-

onates, a method sparing the carotid artery would be desirable.

Venovenous (VV) ECMO in neonates using two cannulas (2C VV ECMO) has provided respiratory support and has resulted in long-term survival (4). In VV ECMO, the venous blood is drained from the right internal jugular vein as with VA ECMO, but perfusion of oxygenated blood has been through a cannula in either the umbilical vein (5) or the femoral vein (4). There have been no reported survivors using the umbilical vein for perfusion. Using the femoral vein adds both to the length of initial cannulation time and to patient morbidity (slow incision site healing in the groin and varying degrees of lower extremity venous insufficiency) (6).

Venovenous ECMO has been successful in supporting fetal lambs using a single cannula in the right atrium (7). This method uses a single-lumen cannula, alternating drainage and infusion of blood similar to hemodialysis. An alternative to bidirectional flow through a single lumen catheter is a double-lumen cannula, which allows simultaneous drainage and infusion. The purpose of this study was to evaluate the respiratory support provided by double-lumen cannula (DLC) VV ECMO.

#### Materials and methods

Custom-built thin-walled cannulas, sizes 12-16 French (F), were designed for end-infusion and multiple side-hole drainage (Fig. 1). Cannulas were metal, metal with a plastic tip, or all plastic in construction.

Six mixed-breed puppies, weighing 1.8-5.4 kg, were placed on DLC VV ECMO (Table 1). A standard neonatal ECMO circuit (4) was used: 1/4-inch tubing, a servo-controlled roller pump (Picker International, Ossining, NY, U.S.A.), a 0.8-m<sup>2</sup> Kolobow membrane lung (SciMed Life Systems Inc., Minneapolis, MN, U.S.A.), and a heat exchanger (SciMed). The circuit was flushed with carbon dioxide, followed by crystalloid, which was then displaced by fresh dog blood with added supplements of sodium bicarbonate, heparin, and calcium gluconate.

The puppies were anesthetized, intubated, and a femoral arterial catheter was placed for blood pres-

Received September 1985; revised August 1986.

Address correspondence and reprint requests to Dr. J. B. Zwischenberger at the University of Texas Medical Branch, Division of Cardiothoracic Surgery, Room 6.126 (E-31), Galveston, TX 77550, U.S.A.

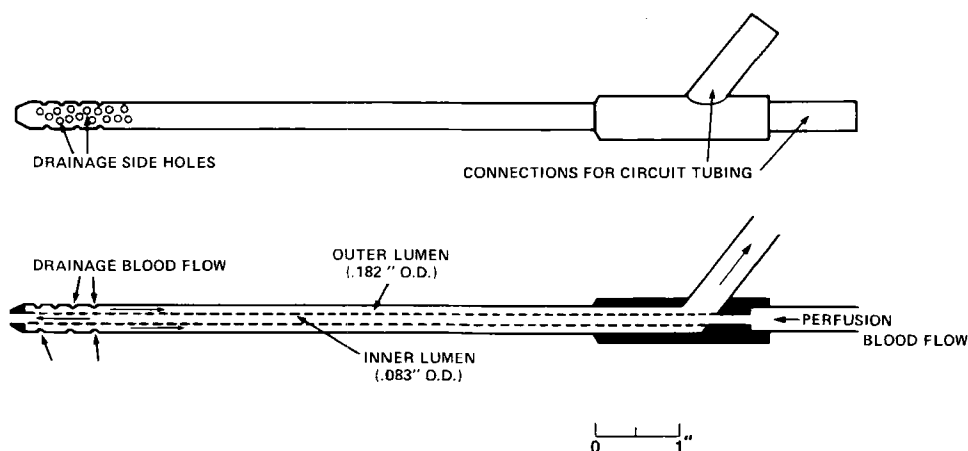


FIG. 1. Double-lumen cannula for venovenous ECMO. Scale drawing of the 14F stainless steel DLC. Cannulas varied in size and in materials for construction, but all had similar proportions.

sure monitoring and blood sampling. Baseline blood pressure and hematocrit were recorded. The double-lumen cannula was inserted into the external jugular vein and advanced into the right atrium. Extracorporeal circulation was begun, and DLC VV ECMO was maintained continuously for 3 h.

While on ECMO, the puppies were kept anesthetized, paralyzed with pancuronium, and fully heparinized (activated clotting time  $>800$  s). The endotracheal tube was clamped throughout the experiment. Bypass pump flow was kept as high as possible to achieve maximum membrane lung gas exchange. The pH,  $PO_2$  from femoral arterial blood, and pre- and postoxygenerator sites, as well as hematocrit, were measured every 20 min. Simultaneous pump bypass flow was recorded. Blood transfusions were given to maintain a systolic blood pressure  $>80$  mm Hg and to keep the hematocrit above 30%. Sodium bicarbonate was given if metabolic acidosis developed. Temperature was maintained at  $38.5^\circ\text{C}$ .

Following 3 h of DLC VV ECMO, the mode of perfusion was changed to either VA (using an 8F common carotid artery catheter) or 2 CVV (using an 8F femoral vein catheter) for 1 h. This served as a control period, during which adequate respiratory support was expected using a proven method ECMO. All values are given as the mean  $\pm$  1 SD. Statistical significance was evaluated by a two-tailed  $t$  test for comparing means.

### Results

Mean baseline hematocrit was  $31 \pm 5\%$ , and mean baseline systolic blood pressure was  $100 \pm 24$  mm Hg. Each dog required 50 ml/kg/h of blood replacement while on ECMO to maintain hematocrit and blood pressure. The dogs had a final systolic blood pressure of  $94 \pm 40$  mm Hg (difference not significant compared to initial). Dogs B and F required no sodium bicarbonate. The other four received a mean of 3 meq/kg during 4 h of ECMO.

Using double-lumen cannula VV ECMO, adequate systemic  $P_aO_2$ ,  $PCO_2$ , and pH was maintained

TABLE 1. Mean blood gas volumes and flows for six puppies on ECMO

Dog	Weight (kg)	DLC description	DLC VV				VA			
			pH	$PCO_2$	$PO_2$	Flow <sup>a</sup>	pH	$PCO_2$	$PO_2$	Flow
A	4.1	14F stainless steel	7.26	47	55	123	7.40	33	576	86
B	5.4	16F stainless steel, plastic tip	7.30	46	49	80	7.43	25	219	81
C	3.6	12F stainless steel	7.32	41	44	125	7.44	31	95	120
D	3.6	12F stainless steel	7.35	40	50	128	7.41	30	173	112
2C VV										
E	3.6	14F plastic	7.30	58	54	113	7.23	51	66	112
F	1.8	14F plastic	7.56	22	50	170	7.38	26	67	207

<sup>a</sup> ml/kg/min.

in all six puppies (Table 1). The mean arterial pH was  $7.35 \pm 0.11$ , the mean  $P_{aO_2}$  was  $50 \pm 4$  torr, and the mean  $PCO_2$  was  $42 \pm 12$  at a mean bypass flow of  $123 \pm 29$  ml/kg/min. On VA ECMO, the mean arterial pH was  $7.42 \pm 0.02$ , the  $P_{aO_2}$  was  $266 \pm 213$  torr, and the mean  $PCO_2$  was  $30 \pm 3$  torr with a mean bypass flow of  $100 \pm 19$  ml/kg/min. On 2C VV ECMO, the mean arterial pH was  $7.30 \pm 0.11$ , the mean  $P_{aO_2}$  was  $67 \pm 1$  torr, and the mean  $PCO_2$  was  $38 \pm 18$  torr with a mean bypass flow of  $159 \pm 67$  ml/kg/min. Blood gas values for DLC VV ECMO has a significantly lower  $P_{aO_2}$  than 2 C VV ECMO. For VA ECMO,  $P_{aO_2}$  and  $PCO_2$  differed significantly compared to DLC VV ( $p < 0.10$ ). In dog F, a thoracotomy allowed inspection of the venous cannula during the experiment. It was noted that decreased blood pressure was associated with the cannula tip slipping into the inferior vena cava.

At necropsy, the thorax, abdomen, and brain were evaluated. On cardiac examination, each heart had significant hemorrhages, except for the heart in which the cannula was monitored by direct vision during bypass. There were no major hemorrhages in organs other than the heart and inferior vena cava. On abdominal evaluation, dog D had mild ascites and dog E had liver engorgement.

#### Discussion

This study demonstrates that a single cannula with a double-lumen in the right atrium of an animal on venovenous ECMO can provide complete respiratory support for 3 h. During venovenous ECMO, some of the oxygenated blood will be recirculated by the venous drainage cannula without reaching the animal's arterial system. This recirculation of oxygenated blood back through the ECMO circuit means that higher bypass flow is required to add the same volume of oxygen as can be added at a lower bypass flow to the more desaturated venous blood of VA ECMO. In the four puppies on both DLC VV and VA ECMO, mean bypass flow with DLC VV was approximately 20% greater than the flow required on VA bypass (not significant in this sample size). This is the same increase in mean flow that was seen in comparing 2C VV with VA ECMO in sheep (8).

As seen with two-cannula VV ECMO in sheep (8) and in infants (4), the systemic arterial  $PO_2$  is lower on DLC VV as compared to VA ECMO, despite higher bypass flows. However, a  $P_{aO_2}$  of 50 will still allow the hemoglobin to be adequately saturated; thus, the oxygen content of the perfused blood will provide adequate oxygen delivery for metabolic needs.

On both 2C and DLC VV ECMO, the perfusion pressure into the venous system would be expected to increase the pressure in the abdominal veins and the inferior vena cava. With 2C VV, using the femoral vein for perfusion, the flow of blood is directed with the natural flow of the venous blood returning to the heart. With DLC VV, the perfused flow is directed into the right atrium, possibly directed against the right atrial wall or against the flow of blood from the inferior vena cava. This may partly explain the cardiac wall hemorrhages and abdominal distention found in the puppies. Proper placement of the cannula in the right atrium appears to be essential. Without monitoring the cannula position, it is difficult to know if hypotension during ECMO is due to decreased intravascular volume or to poor cannula position interfering with venous return to the heart. The large blood and fluid requirements, as well as the need for small doses of sodium bicarbonate, are frequently seen in canine models of extracorporeal circulation.

Venoarterial ECMO can provide cardiac as well as respiratory support, whereas venovenous ECMO depends on cardiac function. In the dogs with cardiac hemorrhages, deterioration with time may have occurred if VV ECMO continued. In the dog with the most extensive cardiac hemorrhages (dog E), the final blood pressure prior to death decreased more from baseline than was seen in the other dogs.

Although DLC VV ECMO provided adequate respiratory support in these animals for 3 h, all but one had significant myocardial hemorrhage. The relative contribution of total anticoagulation to this phenomenon is unknown; however, there may be direct myocardial damage as a result of the infusion into the right atrium. The importance of precise catheter placement with DLC VV ECMO was emphasized by this experiment. As high flows are required, the cannula must be positioned to allow adequate venous drainage without obstructing IVC blood return. We conclude that respiratory support can be achieved using a DLC VV ECMO system. Prior to clinical application of this technique, further study is needed to determine whether or not long-term support can be provided and if different catheter designs and materials will result in less myocardial damage.

**Acknowledgment:** The authors wish to acknowledge the assistance of the following people: Albert R. Petkus, Theodore Z. Polley, Patrick J. DePonio, Cynthia A. Nixon, and Robert H. Bartlett.

## References

1. Bartlett RH, Andrews AF, Toomasian JM, Haiduc NJ, Gazzaniga AB. Extracorporeal membrane oxygenation for newborn respiratory failure: forty-five cases. *Surgery* 1982;92:425-32.
2. Kirkpatrick BV, Krummel TM, Mueller DG, Ormazabal MA, Greenfield LJ, Salzberg AM. Use of extracorporeal membrane oxygenation for respiratory failure in term infants. *Pediatrics* 1983;72:872-6.
3. Hardesty RL, Griffith BP, Debski RF, Jeffries MR, Borovetz HS. Extracorporeal membrane oxygenation: successful treatment of persistent fetal circulation following repair of congenital diaphragmatic hernia. *J Thorac Cardiovasc Surg* 1981;81:556-63.
4. Andrews AF, Klein MD, Toomasian JM, Roloff DW, Bartlett RH. Venovenous extracorporeal membrane oxygenation in neonates with respiratory failure. *J Pediatr Surg* 1983;18:339-46.
5. White JJ, Andrews HG, Risemberg H, Mazur D, Haller JA. Prolonged respiratory support in newborn infants with a membrane oxygenator. *Surgery* 1971;70:288-96.
6. Klein MD, Andrews AF, Wesley JR, Toomasian J, Nixon C, Roloff D, Bartlett RH. Venovenous perfusion in ECMO for newborn respiratory insufficiency. *Ann Surg* 1985;201:520-6.
7. Kolobow T, Fumagalli R, Arosio P, Chen V, Buckhold DK, Pierce JE. The use of the extracorporeal membrane lung in the successful resuscitation of severely hypoxic and hypercapnic fetal lambs. *Trans Am Soc Artif Intern Organs* 1982;28:365-8.
8. Andrews AF, Toomasian J, Oram A, Bartlett RH. Total respiratory support with venovenous (VV) ECMO. *Trans Am Soc Artif Intern Organs* 1982;28:350-2.