

Verteporfin Therapy for Subfoveal Choroidal Neovascularization in Age-Related Macular Degeneration

Three-Year Results of an Open-Label Extension of 2 Randomized Clinical Trials—TAP Report No. 5

Treatment of Age-Related Macular Degeneration With Photodynamic Therapy (TAP) Study Group

Objective: To report vision and safety outcomes from an extension of a 2-year investigation evaluating verteporfin photodynamic therapy in patients with age-related macular degeneration with subfoveal choroidal neovascularization (CNV).

Design and Setting: Open-label extension of selected patients from 2 multicenter, double-masked, placebo-controlled, randomized clinical trials, the Treatment of Age-Related Macular Degeneration With Photodynamic Therapy (TAP) Investigation, at 22 ophthalmology practices in Europe and North America.

Participants: Patients enrolled in the TAP Investigation and followed up for at least 24 months in whom verteporfin therapy to CNV might reduce the risk of further vision loss.

Methods: Before receiving verteporfin therapy in the extension, eligible patients signed a written informed consent form accompanied by an oral consent process approved by local institutional review boards. Methods were similar to those described for 1- and 2-year results, with follow-up examinations beyond 2 years continuing at 3-month intervals with a few exceptions, including that extension patients with fluorescein leakage from CNV were to receive open-label verteporfin therapy *irrespective* of their original treatment assignment.

Results: Of 402 patients in the verteporfin group, 351 (87.3%) completed the month 24 examination; 320 (91.2%) of these enrolled in the extension study. The enrolled participants included 124 (78.0%) of the 159 verteporfin-treated patients with lesions composed of predominantly classic CNV at baseline, of whom 105 (84.7%) completed the month 36 examination. Verteporfin-treated patients with this lesion composition at baseline who participated in the extension study, with or without a month 36 examination, appeared more likely to have a younger age, better level of

visual acuity, absence of fluorescein leakage from classic CNV, or no progression of classic CNV beyond the baseline boundaries of the lesion at the month 24 examination compared with those who did not enroll in the extension. For the 105 patients with a predominantly classic baseline lesion composition who completed the month 36 examination, an average of 1.3 treatments were given from the month 24 examination up to, but not including, the month 36 examination. A letter score loss in the study eye of at least 15 from baseline for these patients occurred in 39 (37.5%) at the month 24 examination compared with 44 (41.9%) of these patients at the month 36 examination. Visual acuity changed little from the month 24 examination (mean, -1.9 lines) to the month 36 examination (mean, -2.0 lines) for these eyes. Verteporfin-treated patients had little change in the mean visual acuity lost and few or no additional instances of infusion-related back pain or photosensitivity reactions from month 24 to month 36. Two patients originally assigned to placebo had acute severe vision decrease within 7 days after verteporfin treatment during the extension. One patient originally assigned to verteporfin had acute severe vision decrease after verteporfin treatment of the fellow eye during the extension.

Conclusions: Vision outcomes for verteporfin-treated patients with predominantly classic lesions at baseline remained relatively stable from month 24 to month 36, although only approximately one third of the verteporfin-treated patients originally enrolled with this lesion composition had a month 36 examination. From these results, the TAP Study Group identified no safety concerns to preclude repeating photodynamic therapy with verteporfin. Additional treatment was judged likely to reduce the risk of further vision loss. Caution appears warranted in the absence of comparison with an untreated group during the extension and since not all patients in the TAP Investigation participated in the TAP Extension.

Arch Ophthalmol. 2002;120:1307-1314

Author affiliations are listed at the end of this article.

THE TREATMENT of Age-Related Macular Degeneration With Photodynamic Therapy (TAP) Study Group reported 1-year¹ and 2-year² results from 2 randomized clinical

trials evaluating photodynamic therapy with verteporfin (Visudyne; Novartis Ophthalmics AG, Bülach, Switzerland) among patients with subfoveal choroidal neovascularization (CNV) caused by age-related macular degeneration (AMD) in

which the baseline lesion composition on fluorescein angiography was to include a component of classic CNV. At the time of enrollment, patients were assigned randomly to intravenous verteporfin or a placebo (dextrose in water) followed by application of laser light to activate verteporfin or serve as a sham treatment for patients given a placebo. A visual acuity benefit through at least 2 years was demonstrated for the study group assigned to verteporfin therapy and was even stronger for subfoveal lesions that were predominantly classic (in which the area of classic CNV was at least 50% of the area of the entire lesion). On the basis of these outcomes, verteporfin therapy has been recommended for treatment of patients with AMD with predominantly classic CNV lesions, with or without occult CNV, and has received regulatory approval for this indication in more than 50 countries, including the United States, Canada, the European Union, and Australia.

An open-label extension of the TAP Investigation beyond 2 years of follow-up was designed after the beneficial 1-year outcomes were recognized.¹ The extension enabled longer-term visual acuity and safety outcomes in patients originally assigned to verteporfin therapy to be obtained and offered verteporfin therapy to selected patients originally assigned to placebo therapy and followed up without verteporfin therapy for 2 years. The purpose of this report is 2-fold: first, to describe detailed vision outcomes between the month 24 and month 36 follow-up examination for verteporfin-treated patients who had a predominantly classic lesion at baseline, a group in the TAP Investigation for whom verteporfin therapy is recommended; and second, to describe safety information during this follow-up period for all patients enrolled, regardless of baseline lesion composition or treatment assignment (verteporfin or placebo).

METHODS

The highlights of the protocol for the TAP Investigation are described in earlier reports.^{1,2} Patients enrolled in the TAP Investigation had subfoveal CNV caused by AMD in which the greatest linear dimension of the lesion was no greater than 5400 μm on the retina and in which the lesion included a component of classic CNV associated with a best-corrected visual acuity letter score between 73 and 34 (equivalent to an approximate Snellen acuity of 20/40 to 20/200).

Enrolled patients were randomly assigned (in a 2:1 ratio) to either verteporfin therapy or placebo sham therapy. Verteporfin therapy included infusion of 6 mg/m^2 of body surface area of verteporfin in a 30-mL solution during 10 minutes followed by activation with a 689-nm diode laser light at an irradiance of 600 mW/cm^2 for 83 seconds producing a fluence of 50 J/cm^2 applied to a spot size 1000 μm greater than the lesion's greatest linear dimension. Placebo sham therapy included infusion of 30 mL of dextrose in water with the same light application to serve as a sham procedure.

Patients were asked to return every 3 months (± 2 weeks) for 24 months and were to be retreated with either verteporfin or placebo (whatever was assigned at baseline) at any of the 3-month follow-up visits when fluorescein leakage from CNV was noted. The procedure for retreatment was the same as the procedure for the initial treatment as outlined in the preceding paragraph except that the spot size was 1000 μm greater than the greatest linear dimension of fluorescein leakage from CNV plus any hyperfluorescence from a serous detachment of

the retinal pigment epithelium, plus any blood contiguous to these features that was judged by the treating ophthalmologist to be thick enough to obscure additional hyperfluorescence from these features. Hypofluorescence not corresponding to blood (presumably from hyperpigmentation or fibrosis) that was contiguous with leakage was included as part of the lesion to be treated during the first application of verteporfin therapy, but was not included as part of the area to be treated at any follow-up examination. All personnel involved in the investigation were masked to the treatment assignment except for the person preparing and performing the infusion who had no role in vision measurements, light treatments, assessment of adverse events, or evaluation of retinal photographs.

Before a patient in the TAP Investigation could be enrolled into the extension study at a center, the extension study design was reviewed by a study advisory group (members of the TAP Study Group who advise the study sponsors on the scientific aspects of the investigation), the institutional review board of the participating clinical center, and the TAP Investigation's data and safety monitoring committee that was independent of the study sponsors and the TAP Study Group. The extension study was administered as protocol amendments that allowed for extended follow-up of patients in the TAP Investigation initially to 48 months and subsequently to 60 months. Monitoring of the clinical centers (including visual acuity examiners) and the Fundus Photograph Reading Center (Wilmer Ophthalmological Institute, Baltimore, Md) continued during the extension.

PATIENT SELECTION AND ENTRY EVALUATIONS

All 22 clinical centers from the TAP Investigation could participate in the extension. Patients were enrolled in the extension from December 3, 1998, through January 13, 2000.

Patient Selection and Patient Enrollment

Ophthalmologists at each clinical center certified to enroll and treat study participants determined whether patients fulfilled eligibility criteria to enroll. Patients eligible to participate in the open-label extension had to have completed the month 24 examination in the TAP Investigation, but could be enrolled regardless of whether the patient was assigned originally to placebo or verteporfin, and regardless of the lesion composition at enrollment into the TAP Investigation. Patients who missed the month 24 examination but returned for a subsequent follow-up examination also could be enrolled in the extension study.

In addition, the enrolling ophthalmologist had to determine that the study eye had the following conditions: (1) met the same criteria required to receive retreatment in the first 24 months of the TAP Investigation (specifically, evidence of fluorescein leakage from CNV in the absence of a serious ocular adverse event) and (2) in the investigators' opinion, had the potential to benefit from verteporfin therapy (for example, excluding lesions that were very large and associated with such a low level of visual acuity such that additional treatment was judged unlikely to prevent further deterioration, and hence unlikely to have a positive impact on the patient's quality of life), or (3) that the study eye had a potential to benefit from verteporfin therapy in the future (for example, a relatively small lesion not associated with very poor vision that did not have fluorescein leakage from CNV at the month 24 examination, but might benefit from verteporfin therapy if fluorescein leakage from CNV was noted at a follow-up examination after the month 24 examination). In addition, patients who reached the month 24 examination could be offered verteporfin therapy in their fellow eye if that fellow eye had a CNV lesion that met the origi-

nal TAP Investigation inclusion criteria¹ except that the lower level of the visual acuity criteria was extended to a letter score of 24 (approximate Snellen equivalent of 20/320).

Patients eligible to participate in the TAP Extension reviewed and signed a written informed consent form accompanied by an oral consent process with a certified investigator (ophthalmologist) for the TAP Extension before they received verteporfin therapy. Although patients and treating ophthalmologists were unmasked to their treatment assignment in the TAP Investigation after all data for these clinical trials had been finalized by February 2000, most patients were enrolled into the TAP Extension before they or their treating ophthalmologist knew what their treatment assignment was during the 2 years of the TAP Investigation.

TAP Extension Design

At the month 24 examination, after assessments were completed for the TAP Investigation (which did *not* include treatment with verteporfin therapy), patients eligible to participate in the TAP Extension who enrolled after signing a written consent form regarding the extension then could begin to receive verteporfin therapy to either the study eye or the fellow eye, or both eyes, depending on whether treatment or retreatment criteria were met. Follow-up examinations were scheduled every 3 months; additional verteporfin treatments were to be applied at those follow-up visits as often as every 3 months for an additional 36 months if leakage from CNV was detected on fluorescein angiography as determined by the treating ophthalmologist.

Vision Testing, Photographs, Other Medical Aspects, and Study Entry

Vision testing, stereoscopic color fundus photographs, fluorescein angiograms, and other medical aspects were described in detail previously¹ with 2 exceptions. First, fundus photographs and fluorescein angiograms taken at every 3-month follow-up visit were evaluated by the Fundus Photograph Reading Center only if the photographs documented specific ocular adverse events during the extension study. Second, no medical history, physical examination, electrocardiogram, vital sign measurements, or blood tests were performed at entry to or during the extension.

STATISTICAL METHODS

Visual acuity and safety data were summarized from study entry of the TAP Investigation to the month 36 examination of the TAP Extension for patients who received verteporfin therapy in the TAP Investigation and continued follow-up in the TAP Extension. Visual acuity and safety data also were summarized for patients who received placebo therapy in the TAP Investigation and then were enrolled in the TAP Extension and received verteporfin therapy in the TAP Extension for either the study eye (in which verteporfin therapy was delayed for at least 2 years from presentation with a lesion eligible to participate in the TAP Investigation) or the fellow eye. Outcomes were not adjusted for missing data at follow-up visits; unlike reports in the TAP Investigation,^{1,2} the last observation carried forward was not used to impute for any missing values at follow-up visits during the extension study.

DATA MONITORING AND REPORTING

Data monitoring was continued by the same Data and Safety Monitoring Committee as often as every 12 months.¹ No safety concerns regarding this extension study were voiced by the com-

mittee at its reviews on March 22, 2000, and February 6, 2001. The database for this report includes all data through the month 36 examination of the TAP Extension, which was locked as of February 27, 2001.

RESULTS

Of the 609 patients enrolled in the TAP Investigation, 207 were assigned to placebo therapy (all received placebo therapy at baseline) and 402 to verteporfin therapy (all received verteporfin therapy at baseline). No placebo-assigned patient received verteporfin and no verteporfin-assigned patient received a placebo therapy during the 24 months of follow-up in the TAP Investigation.

One hundred seventy-eight (86.0%) of the 207 patients in the placebo group completed the month 24 examination; 156 (87.6%) of these 178 patients enrolled in the extension study and 129 (72.5%) were treated with verteporfin therapy at some time during the extension study by the month 36 examination. Thus, 129 (62.3%) of the original 207 patients assigned to placebo in the TAP Investigation were treated with verteporfin therapy in the extension study by the month 36 examination. Three hundred fifty-one (87.3%) of the 402 patients in the verteporfin group completed the month 24 examination; 320 (91.2%) of these 351 patients or 79.6% of the initial 402 verteporfin-treated patients enrolled in the extension study. These 320 verteporfin-treated patients who enrolled in the TAP Extension Study included 124 (78.0%) of the initial 159 verteporfin-treated patients with lesions composed of predominantly classic CNV at baseline.

Verteporfin-treated patients with a predominantly classic lesion composition at baseline who did enroll in the extension ($n=124$), with or without a month 36 examination, compared with those who did not enroll ($n=35$), appeared more likely at the month 24 examination to have a better mean change from baseline in visual acuity letter score ($P=.02$), approximate Snellen equivalent visual acuity distribution in favor of better levels of acuity ($P=.03$ by Wilcoxon rank sum test), younger age ($P=.01$), absence of leakage from classic CNV ($P=.01$), and no evidence of progression of classic CNV beyond the area of the lesion defined at baseline ($P=.049$) (**Table 1**).

VISION OUTCOMES FOR PREDOMINANTLY CLASSIC LESIONS ORIGINALLY ASSIGNED TO VERTEPORFIN AND FOLLOWED UP TO MONTH 36

One hundred five (84.7%) of the 124 TAP Extension patients originally assigned to verteporfin therapy who had a predominantly classic lesion at baseline (or 66.0% of the original 159 verteporfin-treated patients with a predominantly classic lesion at enrollment) enrolled in the extension study and completed the month 36 examination. For the other 19 patients who did not complete the month 36 examination, 8 (6.5%) of the 124 missed the month 36 visit but were still participating in the study, 6 (4.8%) requested to be withdrawn, 3 (2.4%) discontinued for other reasons, 2 (1.6%) died, and none were lost to follow-up. An average of 1.3 of a maximum pos-

Table 1. Patient and Lesion Characteristics for Patients Who Did and Did Not Enroll in the TAP Extension With Lesions Composed of Predominantly Classic CNV at Baseline*

Characteristic at Month 24 Examination	Enrolled in Extension (n = 124)	Enrolled in Extension and Had Month 36 Follow-up (n = 105)	Did Not Enroll in Extension (n = 35)
Mean age, y	76	75	80
Women	61 (49.2)	52 (49.5)	17 (48.6)
Mean change in visual acuity letter score from baseline to month 24 examination	-10.0	-9.5	-17.6
Letter score (visual acuity†) in study eye			
>20/40	7 (5.6)	6 (5.7)	0
20/40-20/80	18 (14.5)	16 (15.2)	3 (8.6)
20/100-20/200	49 (39.5)	42 (40.0)	12 (34.3)
20/250-20/400	47 (37.9)	38 (36.2)	17 (48.6)
<20/400	3 (2.4)	3 (2.9)	3 (8.6)
Letter score (visual acuity†) in fellow eye			
>20/40	34 (27.4)	32 (30.5)	11 (31.4)
20/40-20/80	16 (12.9)	12 (11.4)	4 (11.4)
20/100-20/200	25 (20.2)	22 (21.0)	7 (20.0)
20/250-20/400	34 (27.4)	26 (24.8)	7 (20.0)
<20/400	15 (12.1)	13 (12.4)	6 (17.1)
Lesion size, MPS disc areas	(n = 122)	(n = 104)	(n = 19)
≤3	18 (14.8)	16 (15.4)	3 (15.8)
>3 to ≤6	50 (41.0)	41 (39.4)	5 (26.3)
>6 to ≤9	32 (26.2)	30 (28.8)	0
>9	15 (12.3)	13 (12.5)	4 (21.1)
Cannot grade or unknown	7 (5.7)	4 (3.8)	7 (36.8)
Fluorescein leakage from classic CNV	(n = 121)	(n = 104)	(n = 15)
None	65 (53.7)	55 (52.9)	3 (20.0)
Minimal/moderate	23 (19.0)	21 (20.2)	3 (20.0)
Progression	28 (23.1)	25 (24.0)	7 (46.7)
Cannot grade	5 (4.1)	3 (2.9)	2 (13.3)

*Unless otherwise indicated, values are given as number (percentage). TAP indicates Treatment of Age-Related Macular Degeneration With Photodynamic Therapy; CNV, choroidal neovascularization; and MPS, Macular Photocoagulation Study. For patients who did not enroll in the extension study, values are with last observation carried forward.

†Approximate Snellen equivalent.

sible 4 treatments were given from the month 24 examination (inclusive) up to, but not including, the month 36 follow-up examination. The actual number treated at each visit during this period is shown in **Figure 1**. The distribution of change in visual acuity for this group of lesions at the month 36 examination shows very little change from the distribution at the month 24 examination (**Table 2**). At the month 36 examination, 9 (8.6%) of the 105 patients had at least moderate visual acuity improvement (≥ 15 -letter increase or ≥ 3 -line increase over the baseline examination). Forty-four patients (41.9%) had at least moderate visual acuity loss (≥ 15 -letter loss or ≥ 3 -line loss over the baseline examination), including 13 (12%) with severe visual acuity loss (≥ 30 -letter loss or ≥ 6 -line loss over the baseline examination).

The distribution of actual visual acuity scores at the month 36 examination for this group of lesions shows very little change from the month 24 examination (**Table 3**). At both times, 22 (21%) of the patients had visual acuity of 20/80 or better. The percentage of eyes with visual acuity of 20/200 or worse was similar at both times, including 41 (39.4%) of 104 eyes at the month 24 examination and 45 (42.9%) of 105 eyes at the month 36 examination. The average visual acuity letter score also was similar at both times, 41 (approximate Snellen equivalent of 20/160+1) at the month 24 examination and 40

(approximate Snellen equivalent of 20/160) at the month 36 examination.

SAFETY BASED ON VISION OUTCOMES FOR ALL PARTICIPANTS IN EXTENSION STUDY

The mean change from baseline in visual acuity score, without last observation carried forward, was evaluated as a safety measurement for all TAP Investigation patients participating in the TAP Extension. For the cases enrolled in the TAP Extension that were predominantly classic lesions at baseline, the mean change from baseline in visual acuity score was relatively stable in the second and third years. Specifically, these cases had an approximately 1-letter loss between the month 15 and month 36 examinations (**Figure 2**). Similarly, for 162 patients in the TAP Extension originally assigned to verteporfin therapy who had a minimally classic lesion at baseline, the mean change from baseline in visual acuity letter score between the month 24 and month 36 examinations was relatively stable (Figure 2). Only 34 patients originally assigned to verteporfin therapy who participated in the extension study had no classic CNV at the baseline examination. The mean change from baseline in visual acuity letter score for this group changed from -9.5 to -9.7 between the month 24 and month 36 examinations.

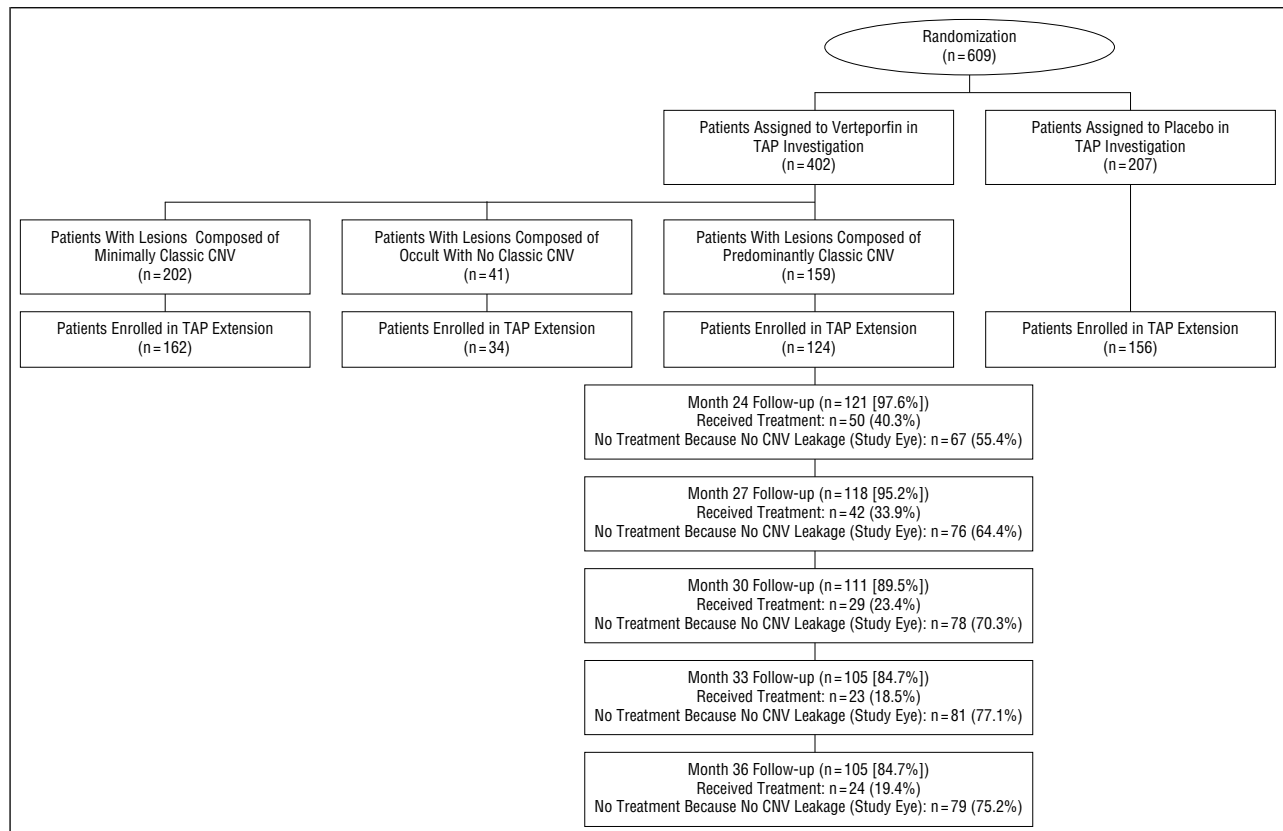


Figure 1. Profile of participants enrolled in the Treatment of Age-Related Macular Degeneration With Photodynamic Therapy (TAP) Extension from the TAP Investigation who had a lesion composed of predominantly classic choroidal neovascularization (CNV) at baseline, randomized to verteporfin therapy at baseline, and who subsequently completed follow-up (at least a protocol visual acuity assessment) through the month 36 examination. The percentage of patients receiving retreatment is expressed as a percentage of the total number of patients with lesions composed of predominantly classic (CNV) at baseline who were enrolled in the TAP Extension. The percentage of patients who did not receive treatment is expressed as a percentage of the total number of patients followed up at that visit.

Table 2. Frequency Distribution of Changes in Visual Acuity From Baseline at the Month 24 and Month 36 Follow-up Examinations for Lesions Composed of Predominantly Classic CNV at Baseline Assigned to Verteporfin Therapy, Participating in TAP Extension, and Having a Month 36 Examination*

Change in Visual Acuity†	No. (%) of Patients	
	Month 24 (n = 104)	Month 36 (n = 105)
≥6-Line increase	2 (1.9)	3 (2.9)
≥3-Line to <6-line increase	9 (8.7)	6 (5.7)
≥1-Line to <3-line increase	7 (6.7)	11 (10.5)
No change	21 (20.2)	17 (16.2)
≥1-Line to <3-line decrease	26 (25.0)	24 (22.9)
≥3-Line to <6-line decrease	25 (24.0)	31 (29.5)
≥6-Line decrease	14 (13.5)	13 (12.4)
Mean No. of lines (letters) lost	1.9 (9.5)	2.0 (10.1)

*TAP indicates Treatment of Age-Related Macular Degeneration With Photodynamic Therapy; CNV, choroidal neovascularization.

†Values are approximate; there are 5 letters per line. One patient enrolled in the Extension Study who returned for the month 36 examination did not have a protocol visual acuity determination at the month 24 examination.

For the 129 patients originally assigned to placebo in the TAP Investigation who were treated with verteporfin therapy in the TAP Extension by the month 36 examination, 103 (79.8%) received their first treatment

Table 3. Visual Acuity Categories in Study Eyes at the Month 24 and Month 36 Follow-up Examinations for Lesions Composed of Predominantly Classic CNV at Baseline Assigned to Verteporfin Therapy, Participating in TAP Extension, and Having a Month 36 Examination*

Visual Acuity, Letter Score†	No. (%) of Patients	
	Month 24 (n = 104)	Month 36 (n = 105)
>73 (>20/40)	6 (5.8)	6 (5.7)
73-54 (20/40-20/80)	16 (15.4)	16 (15.2)
53-34 (20/100-20/160)	41 (39.4)	38 (36.2)
33-14 (20/200-20/500)	38 (36.5)	44 (41.9)
<14 (<20/500)	3 (2.9)	1 (1.0)
Mean	41 (20/160 + 1)	40 (20/160)

*TAP indicates Treatment of Age-Related Macular Degeneration With Photodynamic Therapy; CNV, choroidal neovascularization.

†Approximate Snellen equivalent. One patient enrolled in the Extension Study who returned for the month 36 examination did not have a protocol visual acuity determination at the month 24 examination.

with verteporfin at the month 24 examination and provided 12 months of follow-up after initiation of therapy in the extension study. The other 26 patients originally assigned to placebo received treatment at a follow-up after the month 24 examination and, therefore, had less than 12 months of follow-up after initiation of therapy in the extension study. For these 129 patients assigned

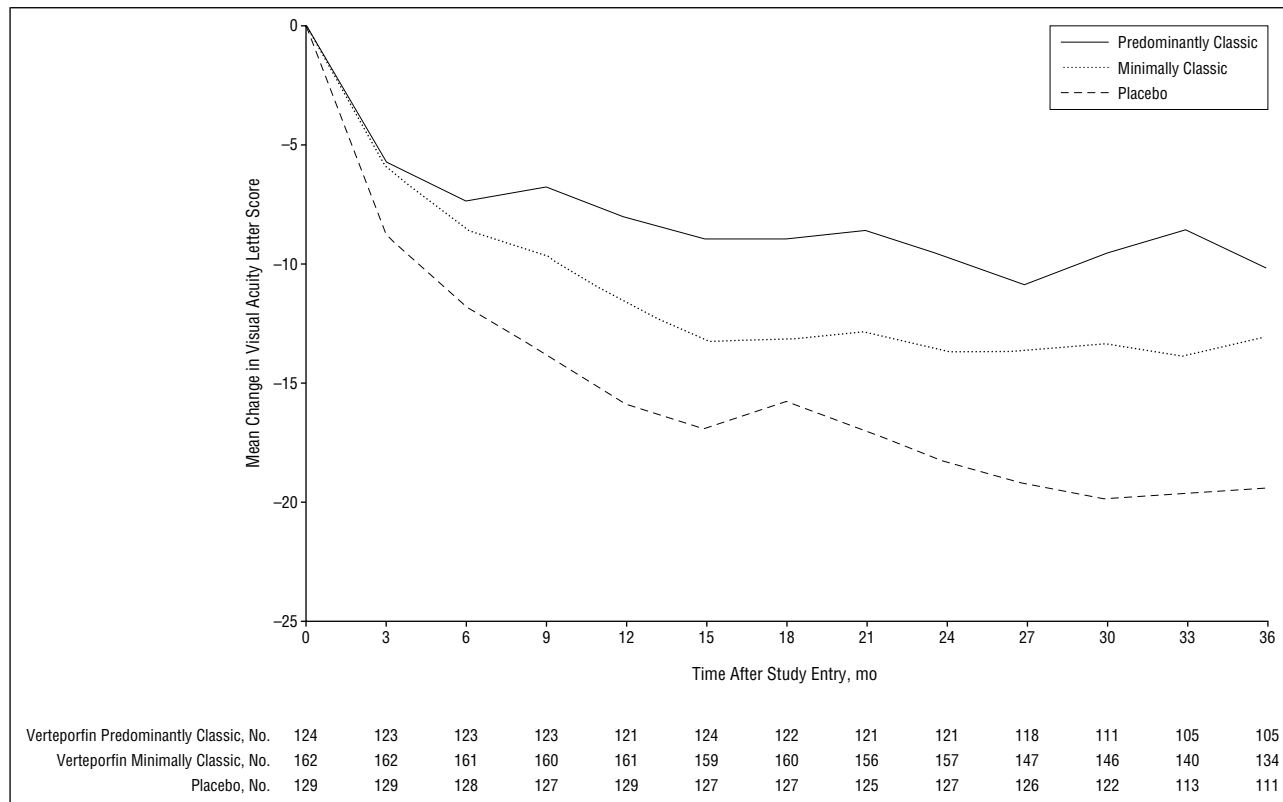


Figure 2. Mean change from baseline in visual acuity scores for patients enrolled in the Treatment of Age-Related Macular Degeneration With Photodynamic Therapy Extension who had a lesion composed of predominantly classic choroidal neovascularization and assigned to verteporfin therapy or a lesion composed of minimally classic choroidal neovascularization and assigned to verteporfin therapy or placebo therapy, regardless of lesion composition. Number of participants providing data for each group are given below each follow-up visit.

to placebo in the TAP Investigation who were treated with verteporfin therapy in the TAP Extension, again there was relatively little change in the mean change from baseline in visual acuity score between the month 24 and month 36 examinations (Figure 2).

OTHER SAFETY OUTCOMES FOR ALL PARTICIPANTS IN EXTENSION STUDY

For the 320 patients originally assigned to verteporfin therapy who participated in the TAP Extension, the percentage who had clinically relevant adverse events by the month 36 examination was similar to the percentage of these patients who had such an event at the month 24 examination² except for visual disturbance events. Specifically, for these 320 patients by the month 36 examination, 57 (17.8%) had experienced an injection site adverse event, 9 (2.8%) had experienced infusion-related back pain, and 8 (2.5%) had experienced a photosensitivity reaction. Cumulative visual disturbance events had increased from 89 (22.1%) of 402 patients by the month 24 examination² to 93 (29.1%) of 320 patients by the month 36 examination. There were no instances of acute severe visual acuity decrease (documented loss of at least 20 letters within 7 days after treatment compared with the visual acuity just before the treatment) in these study eyes originally assigned to verteporfin therapy in the TAP Investigation that then participated in the extension study. However, one of the patients originally assigned to verteporfin therapy in the TAP Investigation who received

verteporfin therapy in a fellow eye during the extension study had an instance of acute severe visual acuity decrease in that fellow eye.

For the 129 patients originally assigned to placebo who were treated with verteporfin therapy in the TAP Extension, visual disturbance events were noted in 12 (9.3%), injection site adverse events in 13 (10.1%), infusion-related back pain in 1 (0.8%), and photosensitivity reaction in 1 (0.8%). There were 2 instances of acute severe vision decrease in the study eye of patients originally assigned to placebo who participated in the extension study. In 1 of these 2 patients, the severe vision decrease occurred after the patient's first verteporfin treatment during the extension study (no verteporfin treatments were given before participation in the extension study); in the other patient, the severe vision decrease occurred after the patient's second verteporfin treatment during the extension study (no verteporfin treatments were given before participation in the extension study).

COMMENT

Previous reports indicated that the vision outcomes with verteporfin therapy^{1,2} in patients with subfoveal CNV in AMD who had a lesion composed of predominantly classic CNV at baseline enrolled in the TAP Investigation were sustained through 2 years of follow-up. On the basis of these results, verteporfin therapy has been recommended for the treatment of patients with AMD with pre-

dominantly classic CNV lesions. The results from an additional year of follow-up show minimal change in vision outcomes for these patients between the month 24 and month 36 examinations. Furthermore, the only additional safety concern for any of the patients enrolled in the extension study, regardless of initial lesion composition or original assignment to verteporfin therapy or sham therapy with placebo, was the development of acute severe vision decrease in the study eye of 2 of the patients originally assigned to placebo and in the fellow eye of 1 patient originally assigned to verteporfin therapy.

The data in Tables 2 and 3 on patients who had a predominantly classic lesion at baseline and participated in the extension study excludes 19 cases in the extension study that did not have both a month 24 and month 36 examination. This method was chosen as one way of trying to report changes in visual acuity for patients with predominantly classic lesions at baseline who participated in the extension study and deal with missing data between these 2 points. The mean visual acuity change at these points in Table 2 for 105 patients with both a month 24 and a month 36 examination is similar to the mean visual acuity change from baseline at these points in Figure 2. Figure 2 includes the 105 patients in Table 2 plus 19 patients who participated in the extension study but did not have both a month 24 and a month 36 examination. The similarity suggests that the exclusion of these 19 patients from Tables 2 and 3 likely did not have a large impact on the estimates given in these tables.

Some caution in the interpretation of the vision results in Tables 2 and 3 is indicated. Specifically, verteporfin-treated patients with a lesion composition that was predominantly classic at baseline who did not enroll in the extension study and are not included in these tables appeared more likely to have a greater age, poorer level of visual acuity, evidence of fluorescein leakage from classic CNV, or evidence of progression of classic CNV at the month 24 examination compared with those included in these tables. Since some of the patients with the worst visual acuity at the month 24 examination did not participate in the extension study, the actual month 36 visual outcomes for all patients from the TAP Investigation who had a predominantly classic lesion at baseline and were assigned to verteporfin therapy may be somewhat worse than that reported in these tables. On the other hand, although these cases probably had more vision to lose during the extension study, since they had better mean levels of visual acuity at the month 24 examination compared with the cases that did not participate in the extension study (20/160 vs 20/250+2), the relatively stable visual acuity suggests an even better outcome than might have been expected if the visual acuity had been lower. Specifically, with lower levels of visual acuity (for example, 20/400), one might expect that further loss of vision would be less likely than at higher levels of acuity (for example, 20/100).

Of note, the average number of applications of verteporfin treatment per year continued to decrease through the third year for the 105 lesions described in Table 1 that were predominantly classic at baseline and that had a month 36 follow-up, from 3.6 during the first year of

follow-up to 2.4 during the second year of follow-up to 1.3 during the third year of follow-up. The limited additional visual loss in the third year of follow-up does not mean that the few retreatments performed during this follow-up were unnecessary. Without retreatment to the cases that had fluorescein leakage from CNV during the third year of follow-up, it is possible that the minimal change in visual outcomes between the month 24 and month 36 examinations might not have been obtained. This study was not designed to determine whether these retreatments were necessary. This information could be obtained only if outcomes with retreatments were compared with outcomes without retreatments during this extension.

As noted in Figure 2, most of the visual acuity loss in either the verteporfin-treated or placebo-treated group occurred in the first year. The minimal additional visual acuity loss noted during both the second and third years of follow-up suggests that similarly treated patients might expect this process to stabilize within 1 year after initiating therapy, with vision usually remaining stable at least through 3 years of follow-up. Since the average age of patients developing these lesions may be approximately 75 years (based on the demographics of patients participating in the TAP Investigation¹ and the Macular Photocoagulation Study of subfoveal CNV caused by AMD³), this period of stability may represent a significant portion of the patient's remaining lifetime.

Two additional limitations must be recognized in the interpretation of these results. First, in the absence of a control group, it is impossible to know for certain whether these outcomes at the month 36 examination would have been better than the outcomes for cases assigned to placebo, since patients originally assigned to placebo could be offered verteporfin therapy after completing the month 24 vision assessments. However, the average visual acuity for patients assigned to placebo showed no improvement for 24 months before the extension study. There is little reason to suspect that improvement should have begun at the month 24 examination.

Second, not all patients participating in the TAP Investigation participated in the TAP Extension. The enrolling ophthalmologist had to determine that the study eye had evidence of fluorescein leakage from CNV at the month 24 examination with a potential to benefit from additional treatment as judged by the treating ophthalmologist, or had no fluorescein leakage from CNV at the month 24 examination but had the potential to need treatment in the future, again as judged by the treating ophthalmologist. For the placebo-treated patients in the TAP Investigation who enrolled in the TAP Extension, without the last observation carried forward to impute for missing values, visual outcomes were marginally worse at the month 36 examination compared with the month 24 examination. However, 2 of these patients had acute severe decrease in vision after verteporfin therapy (1 after the first treatment, 1 after the second treatment). It is unknown how these patients assigned to placebo in the TAP Investigation and subsequently able to receive verteporfin therapy during the extension study would have fared if no verteporfin therapy had been available to them dur-

Writing Committee for TAP Report No. 5

The following members of the TAP Investigation Study Group take authorship responsibility for TAP Report No. 5: Mark S. Blumenkranz, MD; Neil M. Bressler, MD; Susan B. Bressler, MD; Guy Donati, MD; Gary Edd Fish, MD; Laurie A. Haynes*; Hilel Lewis, MD; Joan W. Miller, MD; Jordi M. Monés, MD; Michael J. Potter, MD; Constantin Pournaras, MD; Al Reaves, PhD; Philip J. Rosenfeld, MD, PhD; Andrew P. Schachat, MD; Ursula Schmidt-Erfurth, MD; Michel Sickenberg, MD; Lawrence J. Singerman, MD; Jason S. Slakter, MD; H. Andrew Strong, PhD*; Stéphane Vannier.*

*Indicates members of the writing committee who are employees of QLT Inc or Novartis Ophthalmics AG, which sponsored the trial.

ing the extension study. Therefore, no conclusions regarding efficacy of verteporfin therapy can be made in eyes with fluorescein leakage from subfoveal CNV that has been documented for at least 2 years before the initiation of verteporfin therapy.

CONCLUSIONS

The 3-year visual outcomes for patients with subfoveal CNV enrolled in the TAP Extension show little change from the 2-year outcomes for patients with lesions that were composed of predominantly classic CNV and assigned to verteporfin therapy at baseline. Caution in the interpretation of these results appears warranted in the absence of comparison with an untreated group between the month 24 and month 36 examinations. Furthermore, not all patients in the TAP Investigation participated in the TAP Extension; only approximately one third of the verteporfin-treated patients originally enrolled with this lesion composition had a month 36 examination. Treated patients with predominantly classic lesions at baseline who did participate appeared more likely at the month 24 examination to have a younger age, higher level of visual acuity, absence of fluorescein leakage from classic CNV, and less progression of classic CNV. Continued safety of verteporfin therapy based on mean change in visual acuity and adverse events was maintained through the third year of follow-up in the TAP Investigation. The results provide additional evidence that the benefits of this therapy were sustained through at least 3 years in patients with subfoveal CNV caused by AMD in whom additional therapy is contemplated at the month 24 examination or at some later time beyond the month

24 examination. On the basis of these results, the TAP Study Group identified no safety concerns to preclude repeating photodynamic therapy with verteporfin if fluorescein leakage from CNV was noted beyond 24 months of initiating therapy and additional treatment was judged likely to reduce the risk of further vision loss compared with no therapy. Caution in the interpretation of these results appears warranted in the absence of comparison with an untreated group during the extension and since not all patients in the TAP Investigation participated in the TAP Extension.

Submitted for publication December 18, 2001; final revision received May 20, 2002; accepted June 13, 2002.

A complete list of the participants in the Treatment of Age-Related Macular Degeneration With Photodynamic Therapy Study Group was published in *Arch Ophthalmol*. 1999;117:1343-1344, with updates in *Arch Ophthalmol*. 2001; 119:206.

This study was supported financially by Novartis Ophthalmics AG, Bülach, Switzerland, and QLT Inc, Vancouver, British Columbia.

Drs N. M. Bressler, Potter, and Sickenberg have been paid as consultants to QLT Inc or Novartis Ophthalmics or both (which also may include travel expenses at meetings or participation in a speakers bureau). The terms of this agreement for Dr N. M. Bressler are being managed by The Johns Hopkins University in accordance with its conflict-of-interest policies. Drs S. B. Bressler, Monés, and Slakter have received support for travel expenses at meetings or participation in a speakers bureau. Drs Miller and Schmidt-Erfurth have a patent interest in verteporfin. Dr Slakter has equity ownership of QLT Inc. Detailed statements are on file with the ARCHIVES office.

Corresponding author: Neil M. Bressler, MD, Suite 115, 550 N Broadway, Baltimore, MD 21205-2002 (e-mail: nmboffice@jhmi.edu).

Reprints: Medical Information, Novartis Ophthalmics, 11460 Johns Creek Pkwy, Duluth, GA 30097.

REFERENCES

1. Treatment of Age-Related Macular Degeneration With Photodynamic Therapy (TAP) Study Group. Photodynamic therapy of subfoveal choroidal neovascularization in age-related macular degeneration with verteporfin: one-year results of 2 randomized clinical trials—TAP Report 1. *Arch Ophthalmol*. 1999;117:1329-1345.
2. Treatment of Age-Related Macular Degeneration With Photodynamic Therapy (TAP) Study Group. Photodynamic therapy of subfoveal choroidal neovascularization in age-related macular degeneration with verteporfin: two-year results of 2 randomized clinical trials—TAP Report 2. *Arch Ophthalmol*. 2001;119:198-207.
3. Macular Photocoagulation Study Group. Laser photocoagulation of subfoveal neovascular lesions of age-related macular degeneration: updated findings from two clinical trials. *Arch Ophthalmol*. 1993;111:1200-1209.