

Video assisted thoracoscopic excision of mediastinal ectopic parathyroid adenomas: a UK regional experience

Khalid Amer¹, Ali Zamir Khan¹, David Rew², Nicholas Lagattolla³, Neeta Singh⁴

¹Thoracic Surgeons; ²Endocrine and General Surgeon, Southampton General Hospital, Southampton, UK; ³Endocrine and General Surgeon, Dorset County Hospital, Dorchester, UK; ⁴Histopathologist, Southampton General Hospital, Southampton, UK

Correspondence to: Mr. Khalid Amer, FRCS (CTh). The Cardiovascular and Thoracic Centre, Southampton General Hospital, Tremona Road, Southampton SO16 6YD, UK. Email: khalid.amer@btinternet.com; Khalid.amer@uhs.nhs.uk.

Background: To report the first series of video-assisted thoracoscopic surgery (VATS) resection of mediastinal ectopic parathyroid adenomas (MEPAs) in the UK.

Methods: A case series of seven cases undergoing VATS between 2004 and 2009 to treat single gland hyperparathyroidism. Methylene blue (MB) was used in 5/7 cases immediately before exploration to identify the adenomas. Carbon dioxide (CO₂) up to pressures of 10 mmHg was used safely to deflate the lung in two cases.

Results: There were five women and two men with a mean age of 53 years (range, 27-72 years). Histopathology confirmed successful resection of the parathyroid adenoma in 6/7 cases. There was one conversion to open thoracotomy due to bleeding from the azygos vein resulting from excessive traction. Despite marked MB uptake, this patient proved to have tuberculoid adenopathy and no parathyroid tissue was identified. Postoperative plasma calcium returned to normal in 6/7 patients and parathyroid hormone (PTH) level in 6/7 patients. The median hospital stay was 2 days and there was no mortality in this series.

Conclusions: MEPAs can be safely resected using VATS with minimal surgical morbidity, short drainage time and short hospital stay. CO₂ insufflation and the intraoperative use of MB are safe and help to accurately localise the ectopic adenoma. VATS should be considered as the first-line approach for resection of MEPAs.

Keywords: Ectopic parathyroid adenoma; video-assisted thoracoscopic surgery (VATS); videoscopic; hyperparathyroidism; parathyroidectomy



Submitted May 20, 2015. Accepted for publication Sep 01, 2015.

doi: 10.3978/j.issn.2225-319X.2015.09.04

View this article at: <http://dx.doi.org/10.3978/j.issn.2225-319X.2015.09.04>

Introduction

Mediastinal ectopic parathyroid adenomas (MEPAs) are rare tumors, constituting 1-2% of all parathyroid adenomas (1-3). Thorough understanding of the anatomy and embryology of the parathyroid glands is required by endocrine and thoracic surgeons to maximise chances of cure from hyperparathyroidism (4-6). It is also of paramount importance that clinicians should be aware of the advancements in preoperative parathyroid localization, intraoperative parathyroid hormone (PTH) monitoring and the different surgical accesses

for MEPAs, including 'focused' parathyroidectomy, bilateral surgical neck exploration, video-assisted neck exploration, radioguided parathyroidectomy, feeding vessel embolization, bronchoscopic ablation, open thoracotomy, median sternotomy and video-assisted thoracoscopic surgery (VATS). The dictum that 'the best treatment of hyperparathyroidism is to locate a qualified surgeon' still holds true (7). Surgical exploration of the neck by endocrine surgeons is very popular, and many patients are referred to thoracic or specialised endocrine surgeons only after one or bilateral failed neck explorations. The traditional approach to MEPAs has been a trans-sternal approach or lateral

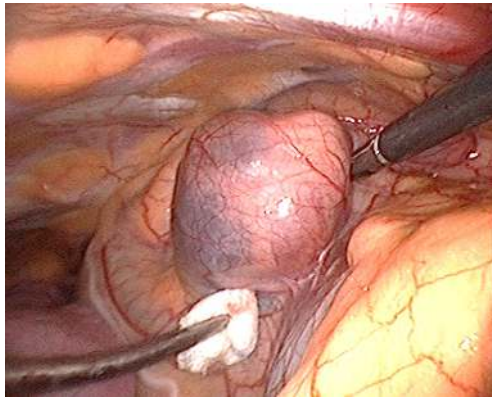


Figure 1 Intraoperative video-assisted thoracoscopic surgery (VATS) image: methylene blue (MB) stained parathyroid adenoma.

thoracotomy (1-3). VATS is now an established minimally invasive technique for the resection of intra-thoracic lesions (8,9). We report our regional experience with seven patients, six of whom underwent successful VATS excision of MEPAs.

Methods

Between January 2004 and December 2009, seven patients presented with mediastinal single gland ectopic hyperparathyroidism. Six patients had primary hyperparathyroidism and one had tertiary hyperparathyroidism. All patients had computed tomography (CT) scans of the chest. In addition, four patients had a Tc^{99m}-Sestamibi scan and single photon emission computed tomography (SPECT) scans.

Excision was performed via VATS with the patient in the supine position, arms by the side, except for two patients with right paratracheal adenoma who were approached in the full lateral position. Single lung ventilation was established via a double lumen tube, while lung collapse was assisted by carbon dioxide (CO₂) insufflation in two patients. Intrapleural pressure was maintained at 10 mmHg at low flow, with the anesthetist continuously monitoring hemodynamics. Three ports were fashioned for access: 10 mm for the camera, 5 mm for instruments and 10 mm utility port.

Intravenous methylene blue (MB) at a dose of 0.5 mg/kg body weight in a 500 mL bag of 5% dextrose/saline was started intravenously at induction of anesthesia and finished just before exploration (*Figures 1,2*) (10). MEPAs preferentially took up the dye and were made easily



Figure 2 Video assisted thoracoscopic excision of mediastinal ectopic parathyroid adenomas: a UK regional experience (10).

Available online: <http://www.asvide.com/articles/721>

identifiable at operation. In 5/7 cases, the chest was drained overnight with a single intercostal tube. One patient had no drain and the converted case had two drains. Morphine was used to maintain postoperative analgesia through intravenous patient controlled analgesia (PCA), and local port blocks using bupivacaine 0.5%. The endocrine medical team were closely involved with the postoperative care of patients, with corrected calcium and PTH serum level monitored immediately after the operation. The serum calcium level was measured daily until the patient was discharged (1-7 days), and the family doctor was instructed to repeat measurements of the calcium level on discharge.

Results

There were five women and two men with a mean age of 53 years (range, 27-72 years). *Table 1* summarises their demographic characteristics. Three patients had undergone prior cervical explorations. There was one conversion to open thoracotomy due to brisk bleeding caused by excessive traction on a slung azygos vein. All patients were extubated shortly after surgery and none required escalated monitoring in the intensive care or high dependency unit. Postoperative plasma calcium returned to normal in all six patients with preoperative hypercalcemia. The PTH level returned to normal in 6/7 patients but remained consistently high in the seventh. This patient had unsuspected and extensive tuberculous lymphadenopathy which concentrated the MB throughout the mediastinal lymph nodal chain. An adenoma could not be found either by VATS or on open conversion. Histopathology

Table 1 Demographics of patients undergoing VATS parathyroid adenectomy between 2004-2009 and their outcomes

Patient (NO)	Age (years)	Sex	Symptoms	Preoperative PTH (range, 0.5-6.4 pmol/L)	Preoperative corrected calcium (range, 2.15-2.6)	CT scan	Tc99m-Sestamibi scan / SPECT	Previous neck exploration	Access, laterality & number of ports	MB uptake	Reason for conversion	Drain dwell time	Histology	Adenoma dimension & site	LOS	Follow up & remarks
1	49	F	Tertiary hyperparathyroidism. Chronic renal failure. Nausea vomiting, recurrent renal stones	258	2.35	Yes	Yes	Bilateral neck exploration, parathyroid adenoma resected. Hypercalcaemia persisted	Right lateral: 3 ports	Yes	Accidental injury to Azygos vein	2 drains: 2 days	Tuberculous lymphadenitis	9 cm x 2 cm: extended from thoracic inlet, retro tracheal, infra azygos into the subcarinal space.	7	Medically treated. No further surgery. Remained asymptomatic. Ca =2.55, PTH =413
2	50	F	Primary hyperparathyroidism Asymptomatic hypercalcaemia. Incidental following CT for thyroid goitre	62.6	4.08	Yes	Yes	No	Left lateral: 3 ports	Yes	n/a	1 drain: 1 day	Parathyroid adenoma	2 cm x 2 cm: right paratracheal. Inferior to subclavian A, supra azygos	1	Cured
3	72	F	Primary hyperparathyroidism Asymptomatic hypercalcaemia	22.3	3.58	Yes	Yes	No	Right supine: 3 ports. CO ₂ used	Yes	n/a	1 drain: 1 day	Parathyroid adenoma	2 cm x 3 cm edge of thymus over pericardium, anterior mediastinum	1	Cured
4	27	F	Primary hyperparathyroidism Symptomatic hypercalcaemia	104	3.42	No	No	Bilateral neck exploration, parathyroid adenoma resected. Hypercalcaemia persisted	Left supine: 3 ports	Yes	n/a	1 day: 1 day	Parathyroid adenoma	1 cm x 1 cm: intra thymic over pericardium anterior mediastinum	1	Cured
5	70	M	Primary hyperparathyroidism Symptomatic hypercalcaemia. Lethargy, Bone and abdominal pains	45.6	2.99	Yes	Yes (negative)	Yes	Right supine: 3 ports	No	n/a	1 drain: 1 day	Parathyroid adenoma	1.5 cm, 4 g right para oesophageal level T3, Inferior to subclavian A, posterior mediastinum	4	Cured
6	66	F	Primary hyperparathyroidism Symptomatic hypercalcaemia: lethargy, mood swings, abdominal pains, thirst	63.5	3.3	Yes	No	No	Right supine: 3 ports	No	n/a	None: 1 day	Parathyroid adenoma	3 cm, 12 g anterior to ascending aorta, Inferior to subclavian A, Superior mediastinum	1	Cured
7	66	M	Primary hyperparathyroidism Recurrent renal calculi. Asymptomatic hypercalcaemia	56.4	3.6	Yes	No	No	Right lateral: 3 ports. CO ₂ used	Yes	n/a	1 drain: 1 day	Parathyroid adenoma	2 cm: right paratracheal, Inferior to subclavian A, supra azygos. Superior mediastinum	1	Cured

VATS, video-assisted thoroscopic surgery; CT, computed tomography; MB, methylene blue; F, female; M, male; CO₂, carbon dioxide; PTH, parathyroid hormone; LOS, length of hospital stay.

Table 2 Surgical access and histology of all parathyroidectomy operations performed in a tertiary referral centre between 2004-2009

Access/histology	2004	2005	2006	2007	2008	2009
Access						
Neck exploration	35	29	28	17	13	10
Median sternotomy	1	0	1	0	0	0
VATS mediastinal exploration	1	4	1	0	0	1
Histology						
Normal gland	0	1	0	1	0	0
Hyperplasia	0	1	1	0	1	0
Adenoma	37	31	28	16	12	11
Carcinoma	0	0	1	0	0	0
Total	37	33	30	17	13	11

VATS, video-assisted thoracoscopic surgery.

confirmed a successfully resected parathyroid adenoma in the other six cases.

The median hospital stay was 2 days with a range of 1-7 days. Apart from the technical azygos bleeding, there were no procedure related complications such as hemothorax, pneumonia, wound infection, arrhythmia, hypocalcaemic tetany, recurrent laryngeal nerve palsy, or MB toxicity.

Table 2 shows the cohort of patients with parathyroidism who underwent surgical operations during the same time frame [2005-2009] at Southampton General Hospital, a tertiary referral centre. A total of 141 patients were operated upon for hyperparathyroidism in 6 years. Of these, 132 had either unilateral or bilateral neck exploration. Two had median sternotomy, and seven underwent VATS (this series). Histology showed that the adenoma was missed in two cases, and was malignant in only one case. Interestingly, this malignant case had recurrence of hypercalcaemia after bilateral successful neck and chest exploration.

Discussion

Parathyroid glands were first described in humans by a medical student from Uppsala-Sweden called Ivar Sandström in 1879 (7). They are usually four in number, bean shaped, yellow-tan in colour, 5 mm across and less than 35 g in weight. They consist of three cell types: the chief cell, the oxyphil cell, and the clear cell. The chief and oxyphil cells produce PTH and the function of the clear cells is unknown. They develop roughly around the second month of gestation under the base of the skull, around the developing thymus and thyroid glands. They migrate down

the neck and attain a position related to the inferior poles of thyroid gland in the neck. They are usually found within the capsule of the thyroid, surrounded by adipose tissue, and can be difficult to identify. If they fail to descend, they are found high in the neck under the mandible (undescended). On the other hand, if they descend too far, they are found within the mediastinum (ectopic). The superior parathyroid glands undergo very little migration, and their location is rather constant whereas the inferior ones migrate with the thymic primordium and can be ectopic. Supernumerary parathyroid glands can exist within thymic tissue. The commonest ectopic sites are on or near the thymus, superior and anterior mediastinum and aortopulmonary window (APW).

Parathyroid glands secrete PTH, which regulates calcium and phosphate levels in blood. Hyperparathyroidism can be primary due to diseased parathyroid glands, or secondary due to disease elsewhere, usually kidneys. Primary hyperparathyroidism can result from benign parathyroid adenomas, hyperplasia of one or more parathyroid glands or rarely cancerous gland. Eighty percent of patients are asymptomatic or have minor symptoms related to hypercalcaemia, such as fatigue, loss of appetite, nausea, constipation, excessive thirst, mild depression and loss of concentration. With high calcium levels, patients may develop bilateral recurrent renal stones, bone resorption and fractures, and rheumatological complications. Secondary hyperparathyroidism refers to the excessive secretion of PTH by the parathyroid glands in response to hypercalcaemia and is associated with hyperplasia of the glands. This disorder is especially seen in patients with

chronic renal failure. Tertiary hyperparathyroidism, is a state of excessive secretion of PTH resulting from a long period of secondary hyperparathyroidism culminating in autonomous (unregulated) parathyroid function.

In reported series of primary hyperparathyroidism, the incidence of MEPAs is about 1-2% (1-3). The Mayo clinic reported 33 cases of mediastinal parathyroidectomy between March 1980 and September 2010, a 30 years span (8). The two hospitals involved in this report serve a population of 3.3 million in the South West of the United Kingdom and report seven cases in six years (*Table 2*). In the same reporting period, there have been 132 cases of cervical exploration for hyperthyroidism and two sternotomies for MEPAs.

There is no consensus on specific tests that should be routinely performed in hyperparathyroidism, however. MEPAs can be detected by a range of localising techniques including imaging and selective venous sampling for high levels of PTH. Ultrasonography, CT scan, magnetic resonance imaging (MRI), positron emission tomography (PET), and recently Technetium (Tc99m-Sestamibi) scan are becoming standard. SPECT is combined with sestamibi scintigraphy to provide three-dimensional imaging. The reported sensitivity of Tc99m-Sestamibi is up to 90% (11-15). Three-dimensional Multi Planar Reconstruction of images could also be reconstructed from CT scans.

Until recently, bilateral neck exploration was the gold standard operation for primary hyperparathyroidism, without localisation imaging. The Scholz-Purnell report from the Mayo Clinic in 1971 and the Kaiser report by Rubinoff in 1983 concluded that: *“our recommendation for patients whose clinical and laboratory studies support the diagnosis of primary hyperparathyroidism has been and continues to be surgical exploration by an experienced parathyroid surgeon.”* There is general agreement that an experienced parathyroid surgeon should perform a minimum of nine to ten explorations annually (16,17). Bilateral neck exploration aims at identifying all four parathyroid glands and removing all abnormal parathyroid tissue. Despite a high cure rate approaching 70%, neck exploration is related to failure, morbidities and difficult second surgeries, not to mention the large unsightly incision. Edis *et al.* suggested that the main reason for failed exploration is *“failure on the part of the surgeon to appreciate the nuances and variations of normal parathyroid anatomy”* (18). This trend is retracting, as precise preoperative localisation studies and intraoperative PTH monitoring coupled with the advent of keyhole surgery (VATS) have managed to improve cure

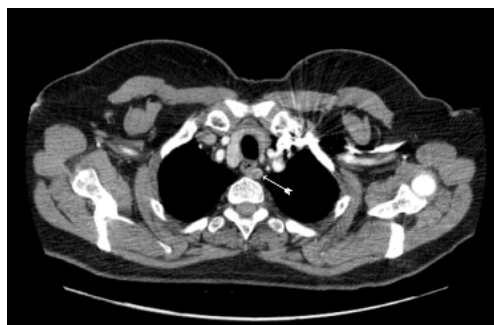

Figure 3 Superior mediastinal mediastinal ectopic parathyroid adenoma (MEPA) in a left para-esophageal location, at the level of vena cava, azygos vein, and higher than origin of left subclavian artery, approached successfully by cervical exploration.

rates to 95-98%. Such a novel and precise approach for a single gland hyperparathyroidism renders exploration of the normal glands unnecessary.

Anatomical mediastinal location of the tumor has dictated the surgical approach. Traditionally before the introduction of VATS, mediastinal MEPAs were resected by thoracotomy or median sternotomy (1-3,19). VATS offers significant advantages over both (8,9). It allows better visualisation of the tumor, a shorter operative time, shorter tube dwell time and shorter hospital stay. Informed patients prefer the superior cosmetic result compared to sternotomy and thoracotomy scars. We encountered the ectopic adenomas within the thymus tissue or closely related to it (*Figure 2*), as could be expected from the embryological close relationship of the two organs (10). On the right, it was also seen in a paratracheal position within the superior triangle (bound by the superior vena cava, azygos vein and vagus nerve). The triangle is occupied by the fibro-fatty-nodal block that contains R2-4 nodes. Discoloration by MB differentiated it from lymph nodes in the area (*Figure 2*) (10). *Figure 2* shows the adenoma could be directly related to the pericardium (10). This absence of thymic tissue raises the possibility that the ectopic parathyroids of the middle mediastinum arose from parathyroid IV. Gilmour noted that parathyroid IV is in contact with the pericardium in the 3 mm embryo and it is possible that some parathyroid precursor cells may retain this relationship and develop in the middle mediastinum (5).

All adenomas in this series would have been outside the remit of cervical access. However; there is no clear ‘cut off’ landmark favouring VATS over cervical access. Liaison between an expert endocrine surgeon and a

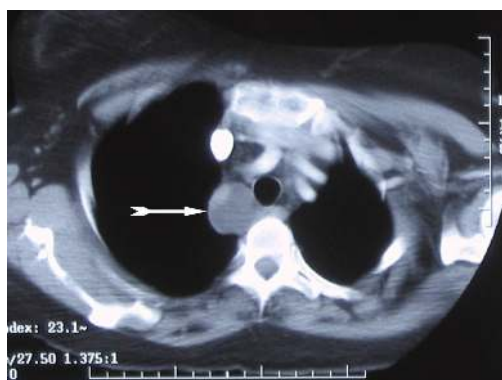

Figure 4 Superior mediastinal ectopic parathyroid adenoma (MEPA) in a right para-tracheal location, supra-azygos, approached successfully by triportal video-assisted thoracoscopic surgery (VATS).

thoracic surgeon expert in VATS mediastinal surgery is recommended. Roughly, MEPAs higher than the right innominate artery or the origin of the left subclavian artery are likely to be accessible by a cervical approach (*Figure 3*). However, it is to be emphasized that there is little evidence to support this generalisation. Wheeler *et al.* (Cardiff-1988) described the challenges of the middle mediastinal parathyroid adenomas (20). The three cases described in their series would have been the domain of VATS nowadays without the need for open sternotomy (*Figure 4*).

Other unusual sites in the chest have been reported. Ali *et al.* and Arnault *et al.* reported MEPAs in the APW, using CT and superselective sampling of inferior thyroid venous blood (21,22). They successfully treated these adenomas by embolization of the feeding artery, which is usually a bronchial artery. MEPAs can rarely be endobronchial, masquerading as asthma and treated by laser ablation or bronchoplastic procedure (23).

MB injected at induction of anesthesia is our preferred method of intraoperative localisation of the ectopic adenoma. Dudley *et al.* used it as early as 1971 to identify the parathyroids intraoperatively (24). It has proven to be a simple and safe method of intraoperative visual localisation of MEPAs. MB is a cationic thiazine dye with a variety of uses including treatment of drug-induced methaemoglobinaemia, septic shock, treatment and prevention of ifosfamide-induced encephalopathy (25,26). It is primarily excreted in the urine after reduction by glucose-6 phosphate dehydrogenase (G6PD) (27). MB effectively functions as a potent competitive inhibitor of monoamine oxidase A (MAOI) and the combination of MB

with a serotonergic drug predisposes to serotonin toxicity, therefore such medication should be avoided if MB were to be used. We used infusions of up to 200 mg in 500 mL of 5% dextrose/saline started on induction of anesthesia and finished before surgical exploration. Tummers *et al.* advocate a dose of 0.5 mg/kg as safe (28). We have not encountered any of the possible complications such as confusional state, hypoxia or allergic reactions (29). Liker has reported prolonged time of recovery from anesthesia after intravenous MB infusion in patients undergoing parathyroidectomy (30). Unfortunately, the specificity of MB in our experience was not 100%, as a tuberculous node confounded the results in one patient. However, in the majority of cases these adenomas are too obvious to miss, and we speculate that MB would be a useful adjunct in locating small adenomas found within lymph nodal field such as the APW. This technique is helpful visual marker but does not replace intraoperative PTH (ioPTH) monitoring when dissecting around nodes in the APW.

IOPTH monitoring consists of analysis of preoperative, pre-excision, and post-excision hormonal assay of PTH at 5 and 10 min following surgical removal of suspected adenoma. Blood samples are obtained from a peripheral vein or the internal jugular vein. The positive predictive criteria for prediction of cure are a drop in ioPTH by >50% of pre-excision values. Lack of adequate drop after targeted resection should trigger continued exploration (6,31). The turn round time in theatre of this hormonal assay is usually about 20 min. There is still some controversy about the criteria of ioPTH assay that can predict cure.

Case number 1 demonstrates that failed exploration could be followed by successful biochemical control of mild symptoms. This is in keeping with The National Institute for Health and Clinical Excellence (NICE) guidelines (32). The presumed MEPA proved to be a tuberculous lymph node and the patient received anti-tuberculous medication. She never proceeded to a second exploration despite high levels of PTH. She is alive and well 10 years after the operation.

MEPAs are rare tumors and as such should be dealt within a specialist tertiary referral centre. NICE has published an interventional procedure consultation document on thoracoscopic excision of mediastinal parathyroid tumors in 2007 (32). It has concluded that the evidence on VATS safety is very limited in quantity, and in view of potential complications of the procedure it should only be used with special arrangements for clinical governance, consent, audit and research. Better patient

outcomes have been reported when complex surgical procedures are performed at high-volume hospitals and centres of excellence. This phenomenon was first noted in 1979, when Luft *et al.* reported that the mortality rate for certain surgeries was inversely proportional to the number of procedures performed (33). Because of a paucity of cases, experience should be concentrated within tertiary referral hospitals. The choice between access with the patient supine or on the lateral decubitus position is subtle and reflects the need for such experience. Intraoperative experience with CO₂ insufflation and monitoring of hemodynamics is another example. Which cases would require MB and ioPTH monitoring for completion of resection is not readily appreciated by the occasional operator. Detailed knowledge of the anatomy of APW and relations of the left recurrent laryngeal nerve remains the domain of thoracic surgeons competent in mediastinal VATS surgery.

We conclude that MEPAs can be safely resected by VATS with minimal surgical morbidity, short procedure and short hospital stay. Chest drainage is either not necessary or could be as short as few hours postoperatively. CO₂ insufflation and intraoperative use of MB are safe and help to accurately localise the ectopic parathyroid tissue. Patients with mediastinal adenoma differ substantially from cervical cases and require a specific strategy. VATS should be considered as the first line approach for resection of these ectopic tumors.

Acknowledgements

None.

Footnote

Conflicts of Interest: The authors have no conflicts of interest to declare.

References

1. Conn JM, Goncalves MA, Mansour KA, et al. The mediastinal parathyroid. *Am Surg* 1991;57:62-6.
2. Russell CF, Edis AJ, Scholz DA, et al. Mediastinal parathyroid tumors: experience with 38 tumors requiring mediastinotomy for removal. *Ann Surg* 1981;193:805-9.
3. Downey NJ, McGuigan JA, Dolan SJ, et al. Median sternotomy for parathyroid adenoma. *Ir J Med Sci* 1999;168:13-6.
4. Weller G. Development of the thyroid, parathyroid and thymus glands in man. *Contrib Embryol* 1933;24:93-142.
5. Gilmour JR. The embryology of the parathyroid glands, the thymus and certain associated rudiments. *The Journal of Pathology and Bacteriology* 2005;45:507-22.
6. Phitayakorn R, McHenry CR. Parathyroidectomy: overview of the anatomic basis and surgical strategies for parathyroid operations. *Clin Rev Bone Miner Metab* 2007;5:89-102.
7. Organ CH Jr. The history of parathyroid surgery, 1850-1996: the Excelsior Surgical Society 1998 Edward D Churchill Lecture. *J Am Coll Surg* 2000;191:284-99.
8. Said SM, Cassivi SD, Allen MS, et al. Minimally invasive resection for mediastinal ectopic parathyroid glands. *Ann Thorac Surg* 2013;96:1229-33.
9. Sukumar MS, Komanapalli CB, Cohen JI. Minimally invasive management of the mediastinal parathyroid adenoma. *Laryngoscope* 2006;116:482-7.
10. Amer K, Khan AZ, Rew D, et al. Video assisted thoroscopic excision of mediastinal ectopic parathyroid adenomas: a UK regional experience. *Asvide* 2015;2:144. Available online: <http://www.asvide.com/articles/721>.
11. Krausz Y, Bettman L, Guralnik L, et al. Technetium-99m-MIBI SPECT/CT in primary hyperparathyroidism. *World J Surg* 2006;30:76-83.
12. Rubello D, Pagetta C, Piotta A, et al. Efficacy of sequential double tracer subtraction and SPECT parathyroid imaging in the precise localization of a low mediastinal parathyroid adenoma successfully removed surgically. *Clin Nucl Med* 2004;29:662-3.
13. Smith JR, Oates ME. Radionuclide imaging of the parathyroid glands: patterns, pearls, and pitfalls. *Radiographics* 2004;24:1101-15.
14. Amar L, Guignat L, Tissier F, et al. Video-assisted thoroscopic surgery as a first-line treatment for mediastinal parathyroid adenomas: strategic value of imaging. *Eur J Endocrinol* 2004;150:141-7.
15. Rubello D, Pelizzo MR, Boni G, et al. Radioguided surgery of primary hyperparathyroidism using the low-dose 99mTc-sestamibi protocol: multi-institutional experience from the Italian Study Group on Radioguided Surgery and Immunoscintigraphy (GISCRIS). *J Nucl Med* 2005;46:220-6.
16. Purnell DC, Smith LH, Scholz DA, et al. Primary hyperparathyroidism: a prospective clinical study. *Am J Med* 1971;50:670-8.
17. Rubinoff H, McCarthy N, Hiatt RA. Hypercalcemia: long-term follow-up with matched controls. *J Chronic Dis* 1983;36:859-68.

18. Edis AJ, Sheedy PF, Beahrs OH, et al. Results of reoperation for hyperparathyroidism, with evaluation of preoperative localization studies. *Surgery* 1978;84:384-93.
19. Obara T, Fujimoto Y, Tanaka R, et al. Mid-mediastinal parathyroid lesions: preoperative localization and surgical approach in two cases. *Jpn J Surg* 1990;20:481-6.
20. Curley IR, Wheeler MH, Thompson NW, et al. The challenge of the middle mediastinal parathyroid. *World J Surg* 1988;12:818-24.
21. Ali M, Kumpe DA. Embolization of bronchial artery-supplied ectopic parathyroid adenomas located in the aortopulmonary window. *J Vasc Interv Radiol* 2014;25:138-43.
22. Arnault V, Beaulieu A, Lifante JC, et al. Multicenter study of 19 aortopulmonary window parathyroid tumors: the challenge of embryologic origin. *World J Surg* 2010;34:2211-6.
23. Özgül MA, Seyhan EC, Özgül G, et al. Endotracheal ectopic parathyroid adenoma mimicking asthma. *Respir Med Case Rep* 2014;13:28-31.
24. Dudley NE. Methylene blue for rapid identification of the parathyroids. *Br Med J* 1971;3:680-1.
25. Rowley M, Riutort K, Shapiro D, et al. Methylene blue-associated serotonin syndrome: a 'green' encephalopathy after parathyroidectomy. *Neurocrit Care* 2009;11:88-93.
26. Vutskits L, Briner A, Klauser P, et al. Adverse effects of methylene blue on the central nervous system. *Anesthesiology* 2008;108:684-92.
27. Clifton J 2nd, Leikin JB. Methylene blue. *Am J Ther* 2003;10:289-91.
28. Tummers QR, Schepers A, Hamming JF, et al. Intraoperative guidance in parathyroid surgery using near-infrared fluorescence imaging and low-dose Methylene Blue. *Surgery* 2015;158:1323-30.
29. Khan MA, North AP, Chadwick DR. Prolonged postoperative altered mental status after methylene blue infusion during parathyroidectomy: a case report and review of the literature. *Ann R Coll Surg Engl* 2007;89:W9-11.
30. Licker M, Diaper J, Robert J, et al. Effects of methylene blue on propofol requirement during anaesthesia induction and surgery. *Anaesthesia* 2008;63:352-7.
31. Sagan D, Goździuk K. Surgical treatment of mediastinal parathyroid adenoma: rationale for intraoperative parathyroid hormone monitoring. *Ann Thorac Surg* 2010;89:1750-5.
32. NICE interventional procedure guidance. Thoracoscopic excision of mediastinal parathyroid tumours. 2007. Available online: <http://www.nice.org.uk/guidance/ipg247>
33. Luft HS, Bunker JP, Enthoven AC. Should operations be regionalized? The empirical relation between surgical volume and mortality. *N Engl J Med* 1979;301:1364-9.

Cite this article as: Amer K, Khan AZ, Rew D, Lagattolla N, Singh N. Video assisted thoracoscopic excision of mediastinal ectopic parathyroid adenomas: a UK regional experience. *Ann Cardiothorac Surg* 2015;4(6):527-534. doi: 10.3978/j.issn.2225-319X.2015.09.04