

## Virulence of *Entamoeba histolytica* According to the Strains in Korea

### I. Comparison of Indirect Fluorescent Antibody Test and Immobilization Test for the Sero-Diagnosis of Amoebiasis\*

Kee-Mok Cho and Chin-Thack Soh

Department of Parasitology College of Medicine and Institute of Tropical Medicine, Yonsei University  
Seoul, Korea

(Received for Publication : 29, Dec., 1969)

#### ABSTRACT

Indirect fluorescent antibody and immobilization tests on *Entamoeba histolytica* have been carried out using the sera of 84 Cheju-islanders, a highly endemic area of amebiasis in Korea. The sera were divided into seven groups; 1) liver abscess (*E. histolytica* in liver), 2) liver abscess (*E. histolytica* in stool), 3) liver abscess (*E. histolytica* not demonstrated by examinations of abscess and stool), 4) hepatomegaly (*E. histolytica* in stool), 5) hepatomegaly (*E. histolytica* not found in stool), 6) cyst carrier, symptomless healthy individuals and 7) control group.

1. The indirect fluorescent antibody test, 100 per cent of cases with group 1 and group 2, 40 per cent with group 3 and group 4, 33.3 per cent with group 5, 50 per cent with group 6 and 5.9 per cent with control group were found positive at 1:16 or higher. Higher titers were manifested in proved liver abscess, but lower titres were in cyst

carrier and control group.

2. The immobilization test, 100 per cent of sera in group 1, 2 and 3, 80 per cent in group 4, 90.5 per cent in group 5, 40 per cent in cyst carrier and 23.5 per cent in control group showed positive.

3. Both tests were positive in all sera of group 1 and 2, six sera out of 15 in group 3, four out of 10 in group 4, seven out of 21 in group 5, two out of 10 in cyst carriers and one out of 17 in controls.

4. Indirect F-A titers were not correlated with the rate of immobilization. Therefore it is suggestive that the two methods will be preferable for the diagnosis of suspicious cases of amoebiasis.

#### INTRODUCTION

Along with the rapid development of newer serologic techniques for the study of antibody response in *Entamoeba histolytica* infection, comparison of the techniques has been discussed by several investigators (Maddison, 1965; Maddison et al., 1965; Kessel et al., 1965; Krupp, 1966; Cuadrado et al., 1967; Halpern et al., 1967; Kahn and Meerovitch, 1968).

Since indirect fluorescent antibody test has been

\* This research was supported by the U.S. Army Research and Development Group (Far East), Department of the Army under Grant No. DA-CRD-AFE-S92-544-69-G143. The paper was presented at the 1st Seminar on Tropical Medicine at Seoul (May, 1969), at the 11th Annual Meeting of the Korean Society for Parasitology (October, 1969) and at the 8th Annual Meeting of the Korean Society for Infectious Diseases (November, 1969).

employed first by Goldman (1966) for the epidemiological study of amebiasis, it has also been evaluated from point of view of interpretation, specificity, sensitivity and reproducibility by different workers (Goldman and Cannon, 1967; Couderdt et al., 1967; Boonpucknavig and Nairn, 1967; Maddison et al., 1968), and regarded as of value for routine diagnosis. In the previous report (Hong et al., 1968), the authors attempted to examine the serological response of amebiasis patients by means of immobilization reaction of the parasite.

The present work was undertaken for the comparative study of indirect fluorescent antibody test (I-FA) and immobilization test (I-R) using the sera of 84 Cheju-islanders, a highly endemic area of amebiasis in Korea. The Formalin-NH<sub>4</sub>OH-Tween 80 fixation method was applied for I-FA technique and Evans Blue was used as counter stain (Goldman; 1966).

## MATERIALS AND METHODS

### a) Ameba strain:

YS9-strain was used through-out the study. The strain was originated from the cyst in the stool of 51-year-old man suffering with liver abscess at Cheju-island in September 1966. The parasite was maintained on a diphasic medium with calf serum and penicillin G media (Cho, 1968) in the presence of unknown bacteria. Through experiments, the strain was confirmed highly invasive to the membrane of cecum of rabbits and rats.

### b) Sera:

The 84 sera were prepared routinely at the local laboratory in Cheju-island and shipped via air-freight to our laboratory. It took about 2 hours, and all of them were stored at -20°C until utilization.

The sera were divided into seven groups according to the clinical and laboratory findings.

- (1) 5 sera from liver abscess—*E. histolytica* in liver,
- (2) 6 sera from liver abscess—*E. histolytica* in stool,

(3) 15 sera from liver abscess—*E. histolytica* neither in liver nor in stool,

(4) 10 sera from hepatomegaly—*E. histolytica* in stool,

(5) 21 sera from hepatomegaly cases—*E. histolytica* not found in stool,

(6) 10 sera from cyst carrier—symptomless healthy individuals, and

(7) 17 sera from control group—without clinical manifestations attributable to amebiasis, and the parasite was not found by stool examination.

### c) Indirect fluorescent antibody test:

#### Antigen

The sediments from 2~3 media of 48-hour cultures of YS9-strain were pooled in 12 ml centrifuge tube, and added 10 ml of cold saline. It was left at room temperature for an hour, and then centrifuged at 2,000 rpm for five minutes. The supernate was discarded, and 5 ml of 10 per cent formalin in saline was added in the sediment. The suspension was stirred and was allowed to fix for 30 minutes. Saline was added up to 10 ml and the tube was spinned as before. The supernate was discarded and the sediment was mixed with 1 ml of 1 per cent NH<sub>4</sub>OH solution for 5 minutes, and then saline was added to 10 ml and spinned as before. The supernate was decanted and 1 ml of 3 per cent Tween 80 in water was added in the sediments. After 5 minutes, the sediment was washed by two centrifugations with 10 ml saline each time. The sediment was resuspended in saline, and this stock antigen was stored at 5°C.

#### Antisera

All sera were heated at 56°C for 30 minutes, before being screened at the dilution of 1:16. Positive sera were retested at higher titers to determine the end point.

#### Fluorescent antibody

A single lot of Fluorescein conjugated goat anti (human IgG)-globulin (Microbiological Associates) was used. The globulin powder was dissolved with 5 ml of distilled water. This stock solution was diluted to 1:16 with 2.5 per cent bovine serum

albumin in barbital buffer solution at pH 7.5.

#### *Fluorescent Microscopy*

Microscope illuminator, Fluorescence, Fluorolume (A.O.), and microscope, Fluorestar (A.O.) were used. The primary filter was A.O., No. 702 passing UV-blue radiation and barrier filter was a yellow, A.O., No. 724.

#### *Performance of test*

Two circles were drawn with water-repellent pencil onto slide, and a drop of antigen suspension was delivered in each circle. When antigen was dried, the slide was immersed in distilled water for a few minutes, then removed and dried. A drop of saline diluted test serum was delivered to the smear in one circle, and control serum was prepared in another circle. The slides were incubated in a moist chamber at 35°C for an hour and immersed in saline for 10 minutes. Then, rinsed them in distilled water and dried. Conjugated dilution was delivered onto smears, incubated, immersed, washed and dried as before. The slide was immersed in 0.1 per cent aqueous Evans Blue solution for 5 minutes, and rinsed in two changes of distilled water. The slide was left in 0.01 M phosphate buffered saline (pH 7.5) for 10 minutes, and rinsed in distilled water. The slide was dried and mounted in 90 per cent glycerol buffered solution at pH 7.3.

#### **d) Immobilization test:**

Frozen sera were liquefied in room temperature, and a drop of 48-hour-culture amebae was combined with a drop of serum on a clean slide. A cover slip was placed on this mixture and sealed with melted paraffin. The slide was then placed in an incubator at 37°C for 45 minutes. The slide was read by examining 100 amebae and counted the number of immobile parasites. At the same time, another slide was prepared with amebae, and used isotonic solution in place of serum as control for spontaneous immobilization. The rate of immobile parasites over 51 was determined as immobilization reaction positive.

## RESULTS

Positive fluorescent antibody reaction varied from 4+ to 1+. In the intensively positive serum, the yellow green fluorescence showed uniformly on the entire surface of amebae with no red by the non-specific Evans Blue counter stain (Fig. 1). On the other hand, the fluorescence was restricted to the periphery of the amebae in the weekly positive serum, and was sometimes observed as granule-like knobs showing red in center portion (Fig. 2 & 3). In the negative or control sera, ameba appeared completely red (Fig. 4). Higher titers were tested by and by at the intensively positive cases.

The reactivities of *E. histolytica* by indirect fluorescent antibody test (I-FA) and immobilization test (I-R) were various according to differences of clinical and laboratory findings (Table 1). Group 1 (Liver abscess, *E. histolytica* present in liver) and Group 2 (Liver abscess, *E. histolytica* present in stool) showed 100 per cent positive. Group 3 (Liver abscess, *E. histolytica* absent) showed 100 per cent positive by I-R, but 40 per cent by I-FA. Group 4 (Hepatomegaly, *E. histolytica* present in stool) showed 40 per cent positive by I-FA and 80 per cent by I-R. Among Group 5 (Hepatomegaly, *E. histolytica* absent) 33.3 per cent were positive by I-FA and 90.5 per cent by I-R. Group 6 (asymptomatic, *E. histolytica* present in stool) showed positive 50 per cent by I-FA and 40 per cent by I-R. In contrast to the above results, the control group showed positive only 5.9 per cent by I-FA and 23.5 per cent by I-R.

The results of I-FA and I-R were compared (Table 2). Among liver abscess group, I-FA and I-R showed all positive only in cases which were positive of *E. histolytica* either in stool or in abscess. Whereas, another 15 liver abscess cases which were negative of *E. histolytica* either in stool or in abscess showed only positive in 6 by both tests and 9 by I-R. Among 10 hepatomegaly cases, which *E. histolytica* were positive in stool,

**Table 1. Reactivity of Indirect FA and Immobilization Tests on *Entamoeba histolytica* (YS-9) with the Sera of Amoebiasis Cases in Cheju-island**

Group	Clinical status	No. of tested	Indirect FA test					Immobilization test		
			Neg. (%)	Positive titers				<50 (%)	>51 (%)	
				1:16	1:64	1:256	1:1024			Total (%)
1	Liver abscess <i>E. histolytica</i> present in liver	5		1	3	1		5 (100)	5 (100)	
2	Liver abscess <i>E. histolytica</i> present in stool	6		2	4			6 (100)	6 (100)	
3	Liver abscess <i>E. histolytica</i> absent	15	9 (60)	2		3	1	6 (40)	15 (100)	
4	Hepatomegaly <i>E. histolytica</i> present in stool	10	6 (60)	3	1			4 (40)	2 (20)	8 (80)
5	Hepatomegaly <i>E. histolytica</i> absent	21	14 (66.7)	5	2			7 (33.3)	2 (9.5)	19 (90.5)
6	Asymptomatic <i>E. histolytica</i> present in stool	10	5 (50)	5				5 (50)	6 (60)	4 (40)
7	Control	17	16 (94.1)	1				1 (5.9)	13 (76.5)	4 (23.5)
Total		84	50 (59.5)	19	10	4	1	34 (40.5)	23 (27.4)	61 (73.6)

**Table 2. Comparisons of Indirect FA and Immobilization Tests in Sera of Amoebiasis Cases in Cheju-island**

Diagnosis	Total	Indirect FA(F) and Immobilization(I) tests			
		F+	F-	F+	F-
		I+	I-	I+	I+
Liver abscess					
1) <i>E. histolytica</i> present in liver	5	5			
2) <i>E. histolytica</i> present in stool	6	6			
3) <i>E. histolytica</i> absent	15	6		9	
Hepatomegaly					
1) <i>E. histolytica</i> present in stool	10	4	2	4	
2) <i>E. histolytica</i> absent	21	7	2	12	
Asymptomatic					
<i>E. histolytica</i> present in stool	10	2	3	3	2
Control	17	1	13		3
Total	84	31	20	3	30

4 showed both positive, 2 both negative and 4 positive only by I-R. The 21 *E. histolytica* absent hepatomegaly group, only 7 showed both positive two were both negative and 12 were positive only by I-R. Among 10 asymptomatic *E. histolytica* carriers, 2 showed both positive, 3 both nega-

tive, 3 positive only by I-FA and 2 positive only by I-R. In control group, one was both positive and 3 were only I-R positive out of 17 cases.

### DISCUSSION

The major purpose of the present study was to compare I-FA and I-R test using *E. histolytica* YS9-strain as antigen. Among newly developed serologic tests to the infection of *E. histolytica*, both I-FA and I-R methods seem to have the advantage of using crude cultured ameba as antigen which may be contaminated with unknown bacteria, though other techniques are invariably required for the use of non-contaminated antigen by axenic or monoxenic cultivation of the parasite. The other methods with non-contaminated antigen have been introduced; Ouchterlony double agar-gel diffusion by Maddison & Elsdon-Dew (1961) and Maddison et al. (1965), immuno-electrophoresis by Krupp (1965) and Goldman (1965), indirect hemagglutination test by Kessel et al. (1965), soluble antigen fluorescent antibody test by Gore & Sadun (1968), and intradermal test by Maddison et al. (1968). Jeans (1964) and Beltran et al. (1965) applied the I-FA test first for the immuno-

diagnosis of amebic infection, but the diversity of dyeing and non-specific green fluorescence reserved the method as reliable diagnostic tool until Goldman (1966) improved it. Goldman (1966) applied the goat anti (human globulin)-globulin for I-FA test to diagnose the hepatic amebiasis and resulted 85.7 per cent positive. In the present study, the authors used fluorescent conjugated goat anti (human IgG)-globulin and found 100 per cent positive from the hepatic amebic abscess cases. It means that the human IgG is more satisfactory than human globulin. The results coincide the report by Maddison et al. (1968) who found IgG globulins were more reactive among  $\gamma$ -globulin fractions in all the serologic tests in *E. histolytica* infection.

For the minimum threshold of positive titers of the both tests, the authors applied the criteria which were made by Goldman (1966) for I-FA and Biagi-F (1961) for I-R. In the present result, the author observed one positive case of confirmed liver abscess showed titer at 1:16 in I-FA test and one case which showed 51 immobile amebae in I-R as shown Table 1. Goldman (1966) reported that only the high fluorescence titre was not indicative for the diagnosis of amebic involvement of liver, though Biagi-F & Buentello (1961) considered that I-R positive was enough to determine hepatic amebic abscess. In the present study, we found that the concomitant utilization of both methods by putting negative control sera were more effective to diagnose the hepatic abscess.

The duration of infection necessary for the development of detectable antibodies is not yet known, but Table 2 shows that titers in I-FA test were considerably higher in liver abscess than other groups. It suggests that antibody titers are correlated with the degree and location of organ involvement.

Although the positive results of both tests are almost analogous to other reports (Biagi-F & Buentello, 1961; Goldman, 1966; Jeans, 1966; Coudert et al., 1967; Boonpucknavig & Nairn, 1967; Hong et al., 1968; Maddison et al., 1968), positive

results of I-R was remarkably higher than that of I-FA in the present observation, in contradiction to Beltran et al. (1965) who concluded that the immunofluorescent test was the more sensitive of the two. As shown in Table 2, one-sided I-R positive appeared among *E. histolytica* abscent liver abscess, hepatomegaly, asymptomatic and control groups, and one-sided I-FA in asymptomatic. It may need more time to reach clear-cut conclusion which one is more reliable of the two tests. However, there were 3 I-R positives in control group, whereas only one positive was appeared by both test which might be the elapsed cases of amebiasis. It does mean that I-FA is rather reliable than I-R.

Through the present study, the following tentative suggestions may be attained.

- 1) Concomitant positive of I-FA and I-R tests with the sera of liver abscess or hepatomegaly would support the diseases were originated from amebic infection.
- 2) Concomitant negative of the two tests would indicate the liver diseases were non-amebic in origin.
- 3) Negative I-FA with positive I-R or positive I-FA with negative I-R would need clinical findings for reliable diagnosis, or, if possible, repeated test should be preferable.

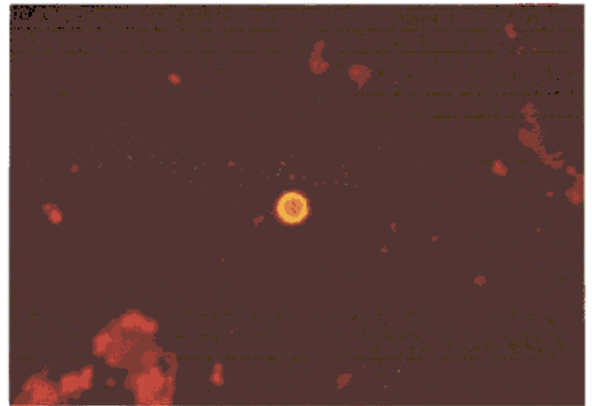

**ACKNOWLEDGEMENT** Gratitudes are paid to Dr. Yong Woo Lee for his technical guidances on fluorescent microscopy.

## REFERENCES

- Beltran H.F., Biagi-F.F., Ortega, P.S. and Rivas, C.: *Revta Gastroent. Mex.*, **30**(179):491, 1965; *Abstract: Trop. Dis. Bull.*, **62**(2):130, 1969.
- Biagi-F.F. and Buentello, L.: *Exp. Parasit.*, **11**:188, 1961.
- Boonpucknavig, S. and Nairn, R.C.: *J. Clin. Path.*, **20**(6):875, 1967.
- Cho, K.M.: *J. Korean Modern Med.*, **8**(1):57, 1968.
- Coudert, J., Garin, J.P., Ambroise-Thomas, P. and Georget, J.P.: *Bull. Soc. Path. Exot.*, **60**(1):


- 44, 1967; *Abstract: Trop. Dis. Bull.*, **65**(5):627, 1968.
- Cuadrado, R. R., Florey, C. du V., Walls, K.W. and Kagan, I.G.: *Amer. J. Epidem.*, **86**:673, 1967.
- Goldman, M.: *Am. J. Trop. Med. & Hyg.*, **15**(5):694, 1966.
- Goldman, M. and Cannon, L.T.: *Am. J. Trop. Med. & Hyg.*, **16**(3):245, 1967.
- Gore, R.W. and Sadun, E.H.: *Exp. Parasit.*, **22**:316, 1968.
- Halpern, B., Young, J.J., Dolkart, J., Armour, III P.D. and Dolkart, R.E.: *J. Lab. Clin. Med.*, **69**:467, 1967.
- Hong, S.O., Cho, K.M., Chung, P.R. and Soh, C.T.: *Yonsei Med. J.*, **9**(2):127, 1968.
- Jeans, A.L.: *Brit. M. J.*, **5501**:1464, 1966.
- Kahn, Z.A. and Meerovitch, E.: *Am. J. Trop. Med. & Hyg.*, **17**(4):528, 1968.
- Kessel, J.F., Lewis, W.P., Pasquel, C.M. and Turner, J.A.: *Am. J. Trop. Med. & Hyg.*, **14**(4):540, 1965.
- Krupp, I.M.: *Am. J. Trop. Med. & Hyg.*, **15**(6):849, 1966.
- Maddison, S.E. and Elsdon-Dew, R.: *Exp. Parasit.*, **11**:90, 1961.
- Maddison, S.E.: *Exp. Parasit.*, **16**:224, 1965.
- Maddison, S.E., Powell, S.J. and Elsdon-Dew, R.: *Am. J. Trop. Med. & Hyg.*, **14**:551, 1965.
- Maddison, S.E., Kagan, I.G. and Norman, L.: *J. Immun.*, **100**(1):217, 1968.
- Maddison, S.E., Kagan, I.G. and Elsdon-Dew, R.: *J. Trop. Med. & Hyg.*, **17**:540, 1968.
-

## Legend for Figures




**Fig. 1** Highly fluorescent ameba, showing the yellow green fluorescence uniformly on the entire surface of the parasite with no red by the non-specific Evans Blue counter stain.

**Fig. 2.** Moderately fluorescent ameba. The fluorescence is restricted to the periphery of the ameba, showing red in the center portion.



**Fig. 3** Weakly fluorescent ameba. The fluorescence is observed as knob granules on periphery of the parasite.



**Fig. 4** Indirect fluorescent antibody test negative ameba. The parasite appears completely red.